

# World Journal of *Clinical Cases*

*World J Clin Cases* 2024 May 6; 12(13): 2138-2292



## EDITORIAL

- 2138 Parenteral iron therapy in children with iron deficiency anemia  
*Roganovic J*
- 2143 Treatment-induced neuroendocrine prostate cancer and *de novo* neuroendocrine prostate cancer: Identification, prognosis and survival, genetic and epigenetic factors  
*Wishahi M*
- 2147 Perioperative cardiac risks in myasthenia gravis  
*Nag DS, Chatterjee A, Mahanty PR, Sam M, Bharadwaj MK*
- 2151 Management of geriatric acetabular fractures: Contemporary treatment strategies  
*Tosounidis T, Chalidis B*
- 2157 Pioneering role of machine learning in unveiling intensive care unit-acquired weakness  
*Dragonieri S*

## ORIGINAL ARTICLE

## Case Control Study

- 2160 Detection and analysis of serum bile acid profile in patients with colonic polyps  
*Ji X, Chen H*
- 2173 Clinical analysis of colistin sulfate in the treatment of pneumonia caused by carbapenem-resistant Gram-negative bacteria  
*Xu HC, Cui Y, Wang XY, Wu HB, Li W, Wang D, Lin N, Lin L, Zhang YH*

## Retrospective Cohort Study

- 2182 Establishment and evaluation of a prognostic model for patients with unresectable gastric cancer liver metastases  
*Chang ZY, Gao WX, Zhang Y, Zhao W, Wu D, Chen L*

## Retrospective Study

- 2194 Therapeutic effect of Wendan Decoction combined with mosapride on gastroesophageal reflux disease after esophageal cancer surgery  
*Zhang YJ, Wu SP*

## Clinical Trials Study

- 2201 Yiwei Xiaoyu granules for treatment of chronic atrophic gastritis with deficiency syndrome of the spleen and stomach  
*Chen WQ, Fan QF, He YJ, Li F, Wu X, Li YP, Yang XJ*

**Observational Study**

- 2210** Relationship between clinical belonging, professional identity, and nursing information ability among nursing interns: Model construction  
*Zhang G, Huang SJ, Li SF*

**META-ANALYSIS**

- 2218** Efficacy and safety of Yangxinshi tablet for chronic heart failure: A systematic review and meta-analysis  
*Lu SH, Yu YF, Dai SS, Hu YQ, Liu JH*

**CASE REPORT**

- 2231** Intra-thyroid esophageal duplication cyst: A case report  
*Lin HG, Liu M, Huang XY, Liu DS*
- 2237** Magnetic resonance imaging findings of radiation-induced breast angiosarcoma: A case report  
*Wu WP, Lee CW*
- 2243** Rim <sup>18</sup>F-fluorodeoxyglucose uptake of hepatic cavernous hemangioma on positron emission tomography/computed tomography: A case report  
*Hu YA, Guo YX, Huang QF*
- 2248** Recovering from prolonged cardiac arrest induced by electric shock: A case report  
*Zhang J, Qiao YR, Yang YD, Pan GZ, Lv CQ*
- 2254** Young patient with a giant gastric bronchogenic cyst: A case report and review of literature  
*Lu XR, Jiao XG, Sun QH, Li BW, Zhu QS, Zhu GX, Qu JJ*
- 2263** Airway management of a patient with linear immunoglobulin A bullous dermatosis: A case report  
*Nin OC, Hutnik R, Chheda NN, Hutchinson D*
- 2269** Deferred revascularization in diabetic patient according to combined invasive functional and intravascular imaging data: A case report  
*Al Nooryani A, Aboushokka W, Beleslin B, Nedeljkovic-Beleslin B*
- 2275** Thymic carcinoid with multiple bone metastases: A case report  
*Chen CQ, Huang MY, Pan M, Chen QQ, Wei FF, Huang H*
- 2281** Atypical presentation of a posterior fossa tumour: A case report  
*Narotam A, Archary M, Naidoo P, Naidoo Y, Naidu V*
- 2286** Refractory autoimmune hemolytic anemia in a patient with systemic lupus erythematosus and ulcerative colitis: A case report  
*Chen DX, Wu Y, Zhang SF, Yang XJ*

**ABOUT COVER**

Peer Reviewer of *World Journal of Clinical Cases*, Konosuke Nakaji, FACP, MD, Doctor, Endoscopy Center, Aishinkai Nakae Hospital, Wakayama-shi 640-8461, Japan. parupurikopui@yahoo.co.jp

**AIMS AND SCOPE**

The primary aim of *World Journal of Clinical Cases* (WJCC, *World J Clin Cases*) is to provide scholars and readers from various fields of clinical medicine with a platform to publish high-quality clinical research articles and communicate their research findings online.

WJCC mainly publishes articles reporting research results and findings obtained in the field of clinical medicine and covering a wide range of topics, including case control studies, retrospective cohort studies, retrospective studies, clinical trials studies, observational studies, prospective studies, randomized controlled trials, randomized clinical trials, systematic reviews, meta-analysis, and case reports.

**INDEXING/ABSTRACTING**

The WJCC is now abstracted and indexed in Science Citation Index Expanded (SCIE, also known as SciSearch®), Journal Citation Reports/Science Edition, Current Contents®/Clinical Medicine, PubMed, PubMed Central, Reference Citation Analysis, China Science and Technology Journal Database, and Superstar Journals Database. The 2023 Edition of Journal Citation Reports® cites the 2022 impact factor (IF) for WJCC as 1.1; IF without journal self cites: 1.1; 5-year IF: 1.3; Journal Citation Indicator: 0.26; Ranking: 133 among 167 journals in medicine, general and internal; and Quartile category: Q4.

**RESPONSIBLE EDITORS FOR THIS ISSUE**

Production Editor: Si Zhao; Production Department Director: Xiang Li; Cover Editor: Jin-Lei Wang.

**NAME OF JOURNAL**

*World Journal of Clinical Cases*

**ISSN**

ISSN 2307-8960 (online)

**LAUNCH DATE**

April 16, 2013

**FREQUENCY**

Thrice Monthly

**EDITORS-IN-CHIEF**

Bao-Gan Peng, Salim Surani, Jerzy Tadeusz Chudek, George Kontogeorgos, Maurizio Serati

**EDITORIAL BOARD MEMBERS**

<https://www.wjgnet.com/2307-8960/editorialboard.htm>

**PUBLICATION DATE**

May 6, 2024

**COPYRIGHT**

© 2024 Baishideng Publishing Group Inc

**INSTRUCTIONS TO AUTHORS**

<https://www.wjgnet.com/bpg/gerinfo/204>

**GUIDELINES FOR ETHICS DOCUMENTS**

<https://www.wjgnet.com/bpg/GerInfo/287>

**GUIDELINES FOR NON-NATIVE SPEAKERS OF ENGLISH**

<https://www.wjgnet.com/bpg/gerinfo/240>

**PUBLICATION ETHICS**

<https://www.wjgnet.com/bpg/GerInfo/288>

**PUBLICATION MISCONDUCT**

<https://www.wjgnet.com/bpg/gerinfo/208>

**ARTICLE PROCESSING CHARGE**

<https://www.wjgnet.com/bpg/gerinfo/242>

**STEPS FOR SUBMITTING MANUSCRIPTS**

<https://www.wjgnet.com/bpg/GerInfo/239>

**ONLINE SUBMISSION**

<https://www.f6publishing.com>



## Rim <sup>18</sup>F-fluorodeoxyglucose uptake of hepatic cavernous hemangioma on positron emission tomography/computed tomography: A case report

Yong-An Hu, Ya-Xin Guo, Qi-Feng Huang

**Specialty type:** Nuclear science and technology

**Provenance and peer review:**

Unsolicited article; Externally peer reviewed.

**Peer-review model:** Single blind

**Peer-review report's scientific quality classification**

Grade A (Excellent): 0  
Grade B (Very good): B  
Grade C (Good): 0  
Grade D (Fair): 0  
Grade E (Poor): 0

**P-Reviewer:** Kupeli S, Türkiye

**Received:** November 28, 2023

**Revised:** February 21, 2024

**Accepted:** April 3, 2024

**Published online:** May 6, 2024



Yong-An Hu, Ya-Xin Guo, Qi-Feng Huang, Department of Nuclear Medicine, Jinhua Hospital of Zhejiang University, Jinhua Municipal Central Hospital, Jinhua 321000, Zhejiang Province, China

**Corresponding author:** Qi-Feng Huang, MD, Doctor, Department of Nuclear Medicine, Jinhua Hospital of Zhejiang University, Jinhua Municipal Central Hospital, No. 365 Renmin East Road, Jinhua 321000, Zhejiang Province, China. [1156225010@qq.com](mailto:1156225010@qq.com)

### Abstract

#### BACKGROUND

Peripheral FDG accumulation in a hepatic hemangioma presenting in a patient with prolonged fever is rare. Therefore, clinicians should pay close attention to patients with hepatic mass.

#### CASE SUMMARY

A 54-year-old woman with a 4-wk history of daily fevers was admitted to our hospital. A whole body <sup>18</sup>F-Fluorodesoxyglucose (PET-FDG) positron emission tomography/computed tomography (PET/CT) was performed to elucidate the source of the fever. However, whole body <sup>18</sup>F-FDG PET/CT raised the suspicion of a malignant lesion because of peripheral FDG accumulation (SUVmax 3.5 g/mL) higher than that of the normal liver parenchyma (SUVmax 1.6 g/mL) surrounding a hypoactive area, and no other abnormalities were showed. Subsequently, the patient underwent liver mass resection. Histopathology showed a hepatic cavernous hemangioma with fatty infiltration around the lesion. The fever disappeared four days after surgery and the patient did not present any complications during follow-up.

#### CONCLUSION

Fatty infiltration in the peripheral parts of hepatic cavernous hemangioma may lead to subacute inflammation which further activate the Kupffer cells. This may cause prolonged fever and peripheral rim FDG accumulation on PET/CT.

**Key Words:** <sup>18</sup>F-Fluorodesoxyglucose positron emission tomography/computed tomography; Hepatocellular carcinoma; Fever; Fatty infiltration; Case report

©The Author(s) 2024. Published by Baishideng Publishing Group Inc. All rights reserved.

**Core Tip:** Most of the hepatic cavernous hemangiomas (HCHs) are small, asymptomatic, and detected incidentally. The typical characteristics of HCHs on computed tomography or magnetic resonance imaging make their diagnosis straightforward. It has been suggested that low uptake of fluorodeoxyglucose could be useful to distinguish between benign hemangioma and malignant liver lesions. However, in the case presented here, a pathologically confirmed hepatic cavernous hemangioma showed a SUVmax (maximum standardized uptake value) in the margin of the lesion which was higher than that of the normal liver parenchyma. Therefore, clinicians should pay close attention to patients with hepatic mass.

**Citation:** Hu YA, Guo YX, Huang QF. Rim  $^{18}\text{F}$ -fluorodeoxyglucose uptake of hepatic cavernous hemangioma on positron emission tomography/computed tomography: A case report. *World J Clin Cases* 2024; 12(13): 2243-2247

**URL:** <https://www.wjgnet.com/2307-8960/full/v12/i13/2243.htm>

**DOI:** <https://dx.doi.org/10.12998/wjcc.v12.i13.2243>

## INTRODUCTION

Cavernous hemangioma is the most common benign hepatic tumor, with a prevalence of 0.4% to 20% in the general population and is believed to arise from vascular malformations although some studies have suggested it might originate from hepatic areas of focal necrosis and regeneration[1,2]. It can occur in any age group, but is most prevalent in middle-aged women (the female to male ratio is 5:1)[3]. Hepatic cavernous hemangioma usually presents as a solitary lesion, but 2%-30% of patients may present with multiple lesions. Most of the hepatic cavernous hemangiomas are small, asymptomatic, and detected incidentally, but large ones can occasionally cause symptoms or complications such as fever, jaundice, nausea, vomiting, rupture. Giant lesions can stretch the Glissonean capsule causing pain that may influence the patient's quality of life[4].

The typical characteristics of hepatic cavernous hemangiomas on computed tomography (CT) or magnetic resonance imaging (MRI) are progressive peripheral nodal enhancement at dynamic imaging and delayed centripetal fill-in, making their diagnosis straightforward[5]. Stable appearances on serial imaging and the absence of vascular flow on Doppler ultrasound are also helpful diagnostic cues for hepatic cavernous hemangiomas. However, atypical hemangiomas can be confused with malignant lesions such as intrahepatic cholangiocarcinoma, hepatocellular carcinoma, mixed hepatocellular-cholangiocarcinoma, and angiosarcoma[6]. Fluorodesoxyglucose (FDG) uptake of hepatic cavernous hemangiomas is usually low[7]. Thus,  $^{18}\text{F}$ -FDG positron emission tomography/CT (PET/CT) is suggested to distinguish benign lesions from malignant lesions when CT and MRI suspect cavernous hepatic hemangioma but cannot exclude malignancy because of its larger size and degeneration[8]. Treatment depends on the size of the tumor and the symptoms. Asymptomatic patients and patients with hepatic lesion size  $\leq 5$  cm or with growth rate  $\leq 3$  mm per year do not require treatment[9]. Otherwise, therapy most often is surgical resection of the lesion, after which recurrence or growth of residual small lesions is rare[10]. A few cases were reported of orthotopic liver transplantation for large or diffuse bilateral lesions[11]. Transcatheter arterial embolization and radiation therapy are alternatives in patients unfit for surgery[12,13].

## CASE PRESENTATION

### Chief complaints

A 54-year-old woman with a 4-wk history of daily fevers was admitted to our hospital.

### History of present illness

The patient had daily fevers (up to 39.2 °C) for 4 wk of unknown origin.

### History of past illness

She was in good health and her past medical history was unremarkable.

### Personal and family history

The patient denied any family history of malignancy.

### Physical examination

Body temperature was 38.4 °C, blood pressure was 117/82 mmHg, heart rate was 85 beats/min, respiratory rate was 20 breaths/min and her oxygen saturation was 98%.

### Laboratory examinations

Blood tests indicated an elevation in neutrophils (81.5%), C-reactive protein (118.2 mg/L), alkaline phosphatase (147.0 IU/L), and  $\gamma$ -glutamyl transpeptidase (59.9 U/L).

### Imaging examinations

Abdominal ultrasound was performed showed a 10.0 cm × 7.0 cm heterogeneous hyperechoic mass in the left liver lobe. On dynamic contrast-enhanced CT, peripheral nodular enhancement in the arterial phase and gradual fill-in in the delayed phase were seen in the mass, which are findings typical for cavernous hemangioma (Figure 1). A whole body 18F-FDG PET/CT was performed to elucidate the source of the fever. However, whole body 18F-FDG PET/CT raised the suspicion of a malignant lesion because of peripheral FDG accumulation (SUVmax 3.5 g/mL) higher than that of the normal liver parenchyma (SUVmax 1.6 g/mL) surrounding a hypoactive area, and no other abnormalities were showed (Figure 2).

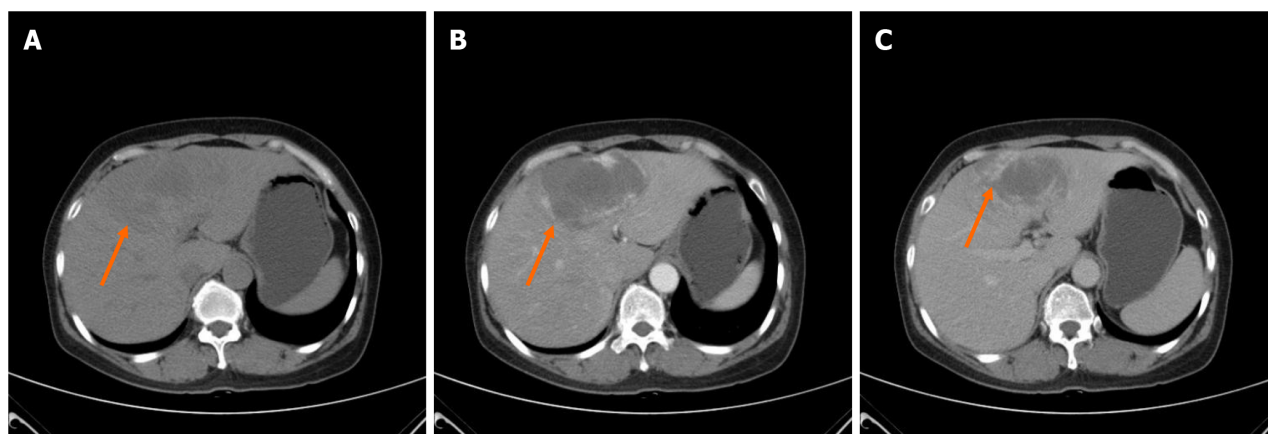


Figure 1 Abdominal computed tomography pre-operation showed a slightly low intensity mass of 10.0 cm × 7.0 cm (orange arrow) was seen in the left liver lobe on plain computed tomography with peripheral nodular enhancement in the arterial phase and gradual fill-in in the delayed phase. A: Plain computed tomography; B: The arterial phase; C: The delayed phase.

### FINAL DIAGNOSIS

Hepatic cavernous hemangioma.

### TREATMENT

Preoperative needle biopsy was not undertaken given the risk of bleeding because the tumor was highly vascular. Subsequently, the patient underwent liver mass resection. At gross examination, the tumor was a dark red mass of 10 cm in diameter. Histopathology showed a hepatic cavernous hemangioma with fatty infiltration around the lesion (Figure 3).

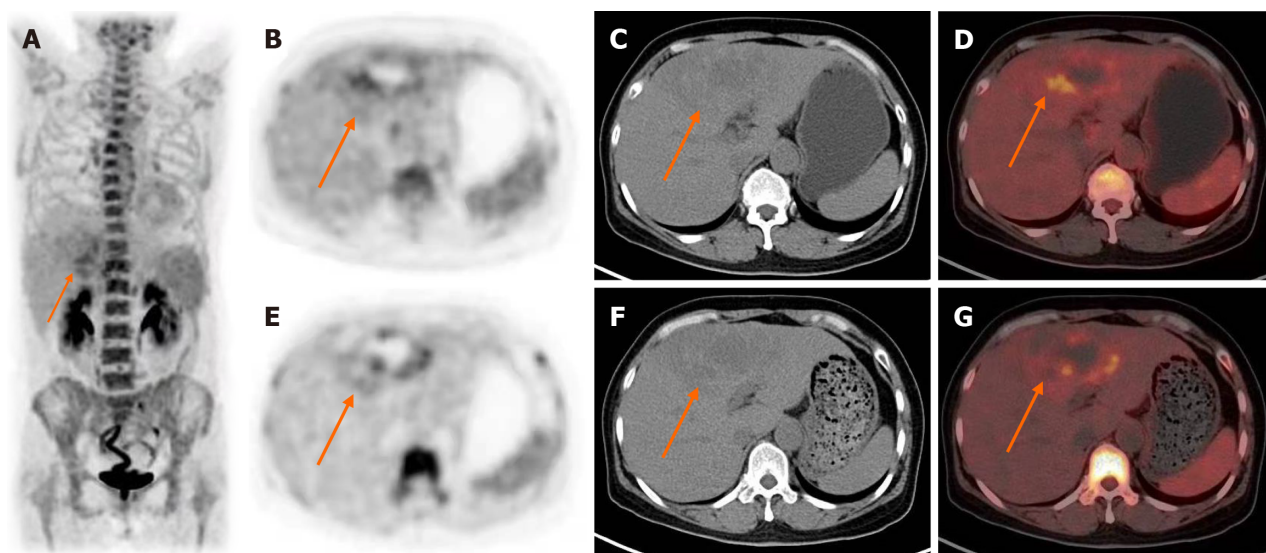
### OUTCOME AND FOLLOW-UP

The fever disappeared four days after surgery and the patient did not present any complications during follow-up.

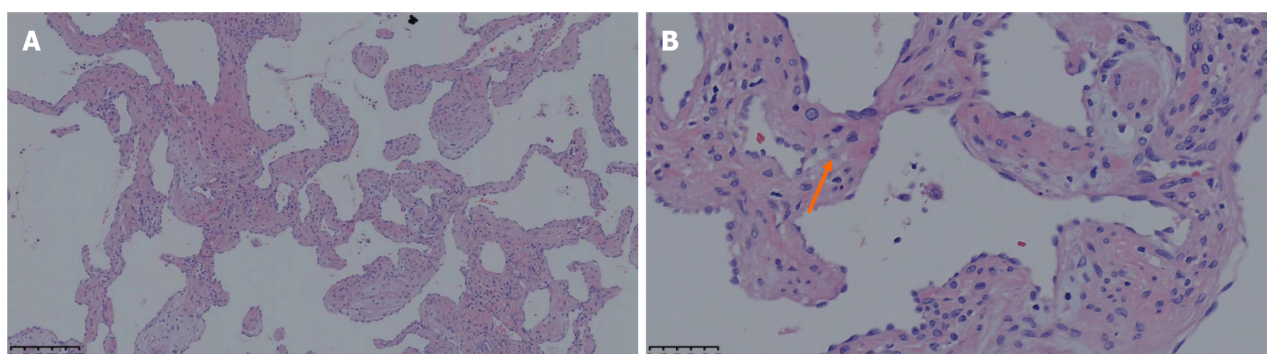
### DISCUSSION

While it has been suggested that low uptake of FDG could be useful to distinguish between benign hemangioma and malignant liver lesions, in the case presented here, a pathologically confirmed hepatic cavernous hemangioma showed a SUVmax (maximum standardized uptake value) in the margin of the lesion which was higher than that of the normal liver parenchyma[7,8,14]. We suspect that this may result from the fatty infiltration. Uptake of FDG in focal fatty infiltration of the liver has been reported and has been attributed to activation of Kupffer cells[15]. A mouse model provided evidence that lipid accumulation in the liver leads to subacute hepatic 'inflammation' through nuclear factor (NF)-kappa activation and downstream cytokine production and that Kupffer cells may activated[16]. However, as the latter reference mentions, the approximately twofold activation of hepatic NF-κB is in contrast to the much greater, many-fold activation that typifies acute inflammatory reactions. Therefore, it remains speculative whether the fever in the patient described here could have been related to the uptake of FDG in the hemangioma. Fever has seldom been reported in hepatic hemangioma[17]. One study suggested that necrotic changes within the hemangioma may cause fever[18]. However, necrotic changes have not been seen in our patient. Moreover, no histologic evidence was found of infection of the hemangioma, which conceivably would constitute a differential explanation of the fever and of the FDG accumulation. Moreover, the peripheral nature of the FDG accumulation would be unexpected in case of infection and it seems unlikely





**Figure 2**  $^{18}\text{F}$ -Fluorodesoxyglucose positron emission tomography/computed tomography pre-operation showed the liver lesion (orange arrow) with peripheral fluorodeoxyglucose accumulation (SUVmax 3.5) higher than that of the normal liver parenchyma (SUVmax 1.6) surrounds a hypoactive area. A: Whole body  $^{18}\text{F}$ -Fluorodesoxyglucose positron emission tomography; B and E: Axial positron emission tomography; C and F: Computed tomography; D and G: Combined positron emission tomography/computed tomography slices.



**Figure 3** The result of histopathological examination. Hematoxylin and Eosin staining showed numerous dilated blood vessels adjacent to hepatocytes with fatty cell (orange arrow). A: Under low magnification ( $\times 40$ ); B: Under high magnification ( $\times 100$ ).

that any inflammatory infiltrate would have cleared entirely. Still, this we cannot formally rule out this possibility.

## CONCLUSION

Fatty infiltration in the peripheral parts of hepatic cavernous hemangioma may lead to subacute inflammation which further activate the Kupffer cells. This may cause prolonged fever and peripheral rim FDG accumulation. We observed peripheral FDG accumulation in a hepatic hemangioma presenting in a patient with prolonged fever. This probably relates to fatty infiltration at the border of the hemangioma and resulting Kupffer cell activation. Since the fever disappeared after resection of the hemangioma, this might suggest that it may have been caused by inflammation induced by the hemangioma.

## FOOTNOTES

**Author contributions:** All authors were involved in the preparation of this manuscript. Hu YA participated in data collection and wrote the manuscript; Guo YX participated in literature search and wrote the manuscript; Huang QF wrote and revised the manuscript; all authors have read and agreed to the published version of the manuscript.

**Supported by** Zhejiang Province Public Welfare Technology Application Research Project, No. LGF21H180007.

**Informed consent statement:** Written informed consent has been obtained from the patient to publish this paper.



**Conflict-of-interest statement:** All authors declare that they have no conflicts of interest.

**CARE Checklist (2016) statement:** The authors have read the CARE Checklist (2016), and the manuscript was prepared and revised according to the CARE Checklist (2016).

**Open-Access:** This article is an open-access article that was selected by an in-house editor and fully peer-reviewed by external reviewers. It is distributed in accordance with the Creative Commons Attribution NonCommercial (CC BY-NC 4.0) license, which permits others to distribute, remix, adapt, build upon this work non-commercially, and license their derivative works on different terms, provided the original work is properly cited and the use is non-commercial. See: <https://creativecommons.org/licenses/by-nc/4.0/>

**Country/Territory of origin:** China

**ORCID number:** Qi-Feng Huang 0000-0002-1611-207X.

**S-Editor:** Liu JH

**L-Editor:** A

**P-Editor:** Zhao S

## REFERENCES

- Ojili V, Tirumani SH, Gunabushanam G, Nagar A, Surabhi VR, Chintapalli KN, Ryan J. Abdominal Hemangiomas: A Pictorial Review of Unusual, Atypical, and Rare Types. *Can Assoc Radiol J* 2013; **64**: 18-27 [DOI: [10.1016/j.carj.2011.08.004](https://doi.org/10.1016/j.carj.2011.08.004)]
- Brogna A, Ferrara R, Bucceri AM, Virgilio C, Scalisi G. An atypical case of hepatic cavernous hemangioma. *Cases J* 2009; **2**: 181 [PMID: [19946491](https://pubmed.ncbi.nlm.nih.gov/19946491/) DOI: [10.1186/1757-1626-2-181](https://doi.org/10.1186/1757-1626-2-181)]
- Choi BY, Nguyen MH. The diagnosis and management of benign hepatic tumors. *J Clin Gastroenterol* 2005; **39**: 401-412 [PMID: [15815209](https://pubmed.ncbi.nlm.nih.gov/15815209/) DOI: [10.1097/01.mcg.0000159226.63037.a2](https://doi.org/10.1097/01.mcg.0000159226.63037.a2)]
- Abdel Wahab M, El Nakeeb A, Ali MA, Mahdy Y, Shehta A, Abdulrazek M, El Desoky M, Abdel Wahab R. Surgical Management of Giant Hepatic Hemangioma: Single Center's Experience with 144 Patients. *J Gastrointest Surg* 2018; **22**: 849-858 [PMID: [29488123](https://pubmed.ncbi.nlm.nih.gov/29488123/) DOI: [10.1007/s11605-018-3696-y](https://doi.org/10.1007/s11605-018-3696-y)]
- Oldhafer KJ, Habbel V, Horling K, Makridis G, Wagner KC. Benign Liver Tumors. *Visc Med* 2020; **36**: 292-303 [PMID: [33005655](https://pubmed.ncbi.nlm.nih.gov/33005655/) DOI: [10.1159/000509145](https://doi.org/10.1159/000509145)]
- Lin S, Zhang L, Li M, Cheng Q, Zheng S. Atypical hemangioma mimicking mixed hepatocellular cholangiocarcinoma: Case report. *Medicine (Baltimore)* 2017; **96**: e9192 [PMID: [29390333](https://pubmed.ncbi.nlm.nih.gov/29390333/) DOI: [10.1097/MD.00000000000009192](https://doi.org/10.1097/MD.00000000000009192)]
- Higashiyama S, Kawabe J, Hayashi T, Kurooka H, Oe A, Kotani J, Kawamura E, Shiomi S. A case of cavernous hemangioma in which malignancy was preoperatively excluded by FDG-PET. *Ann Nucl Med* 2008; **22**: 327-330 [PMID: [18535885](https://pubmed.ncbi.nlm.nih.gov/18535885/) DOI: [10.1007/s12149-007-0101-4](https://doi.org/10.1007/s12149-007-0101-4)]
- Shimada K, Nakamoto Y, Isoda H, Saito H, Arizono S, Shibata T, Togashi K. FDG PET for giant cavernous hemangioma: important clue to differentiate from a malignant vascular tumor in the liver. *Clin Nucl Med* 2010; **35**: 924-926 [PMID: [21206221](https://pubmed.ncbi.nlm.nih.gov/21206221/) DOI: [10.1097/RLU.0b013e3181f9de11](https://doi.org/10.1097/RLU.0b013e3181f9de11)]
- Jiang H, Chen Z, Prasoon P, Wu H, Zeng Y. Surgical Management for Giant liver Hemangiomas Greater Than 20 cm in Size. *Gut Liver* 2011; **5**: 228-233 [PMID: [21814606](https://pubmed.ncbi.nlm.nih.gov/21814606/) DOI: [10.5009/gnl.2011.5.2.228](https://doi.org/10.5009/gnl.2011.5.2.228)]
- Leon M, Chavez L, Surani S. Hepatic hemangioma: What internists need to know. *World J Gastroenterol* 2020; **26**: 11-20 [PMID: [31933511](https://pubmed.ncbi.nlm.nih.gov/31933511/) DOI: [10.3748/wjg.v26.i1.11](https://doi.org/10.3748/wjg.v26.i1.11)]
- Prodromidou A, Machairas N, Garoufalia Z, Kostakis ID, Tsaparas P, Paspala A, Stamopoulos P, Sotiropoulos GC. Liver Transplantation for Giant Hepatic Hemangioma: A Systematic Review. *Transplant Proc* 2019; **51**: 440-442 [PMID: [30879561](https://pubmed.ncbi.nlm.nih.gov/30879561/) DOI: [10.1016/j.transproceed.2019.01.018](https://doi.org/10.1016/j.transproceed.2019.01.018)]
- Hanks BA, Suhocki PV, DeLong DM, Doan PL, Liu E, Tsai AL, Burke CT, Bernard SA, O'Neil BH, Morse MA. The efficacy and tolerability of transarterial chemo-embolization (TACE) compared with transarterial embolization (TAE) for patients with unresectable hepatocellular carcinoma (HCC). *J Clin Oncol* 2008; **26** [DOI: [10.1200/jco.2008.26.15\\_suppl.4595](https://doi.org/10.1200/jco.2008.26.15_suppl.4595)]
- Shimizu S, Mizumoto M, Okumura T, Li Y, Baba K, Murakami M, Ishida T, Nakamura M, Hiroshima Y, Iizumi T, Saito T, Numajiri H, Nakai K, Hata M, Sakurai H. Proton beam therapy for a giant hepatic hemangioma: A case report and literature review. *Clin Transl Radiat Oncol* 2021; **27**: 152-156 [PMID: [33665385](https://pubmed.ncbi.nlm.nih.gov/33665385/) DOI: [10.1016/j.ctro.2021.01.014](https://doi.org/10.1016/j.ctro.2021.01.014)]
- Mergo PJ, Ros PR. Benign lesions of the liver. *Radiol Clin North Am* 1998; **36**: 319-331 [PMID: [9520985](https://pubmed.ncbi.nlm.nih.gov/9520985/) DOI: [10.1016/s0033-8389\(05\)70025-7](https://doi.org/10.1016/s0033-8389(05)70025-7)]
- Kim YH, Kim JY, Jang SJ, Chung HW, Jang KS, Paik SS, Song SY, Choi YY. F-18 FDG uptake in focal fatty infiltration of liver mimicking hepatic malignancy on PET/CT images. *Clin Nucl Med* 2011; **36**: 1146-1148 [PMID: [22064098](https://pubmed.ncbi.nlm.nih.gov/22064098/) DOI: [10.1097/RLU.0b013e3182335f60](https://doi.org/10.1097/RLU.0b013e3182335f60)]
- Cai D, Yuan M, Frantz DF, Melendez PA, Hansen L, Lee J, Shoelson SE. Local and systemic insulin resistance resulting from hepatic activation of IKK-beta and NF-kappaB. *Nat Med* 2005; **11**: 183-190 [PMID: [15685173](https://pubmed.ncbi.nlm.nih.gov/15685173/) DOI: [10.1038/nm1166](https://doi.org/10.1038/nm1166)]
- Yoshimizu C, Ariizumi S, Kogiso T, Sagawa T, Taniiai M, Honda G, Egawa H, Tokushige K. Giant Hepatic Hemangioma Causing Prolonged Fever and Indicated for Resection. *Intern Med* 2022; **61**: 1849-1856 [PMID: [34803101](https://pubmed.ncbi.nlm.nih.gov/34803101/) DOI: [10.2169/internalmedicine.8405-21](https://doi.org/10.2169/internalmedicine.8405-21)]
- Yang YG, Chen WF, Mai WH, Li XF, Zhou HL, Liu LJ, Li MY. Spontaneous intracapsular hemorrhage of a giant hepatic cavernous hemangioma: a rare case report and literature review. *BMC Gastroenterol* 2021; **21**: 84 [PMID: [33622256](https://pubmed.ncbi.nlm.nih.gov/33622256/) DOI: [10.1186/s12876-021-01666-z](https://doi.org/10.1186/s12876-021-01666-z)]



Published by **Baishideng Publishing Group Inc**  
7041 Koll Center Parkway, Suite 160, Pleasanton, CA 94566, USA

**Telephone:** +1-925-3991568

**E-mail:** [office@baishideng.com](mailto:office@baishideng.com)

**Help Desk:** <https://www.f6publishing.com/helpdesk>

<https://www.wjgnet.com>

