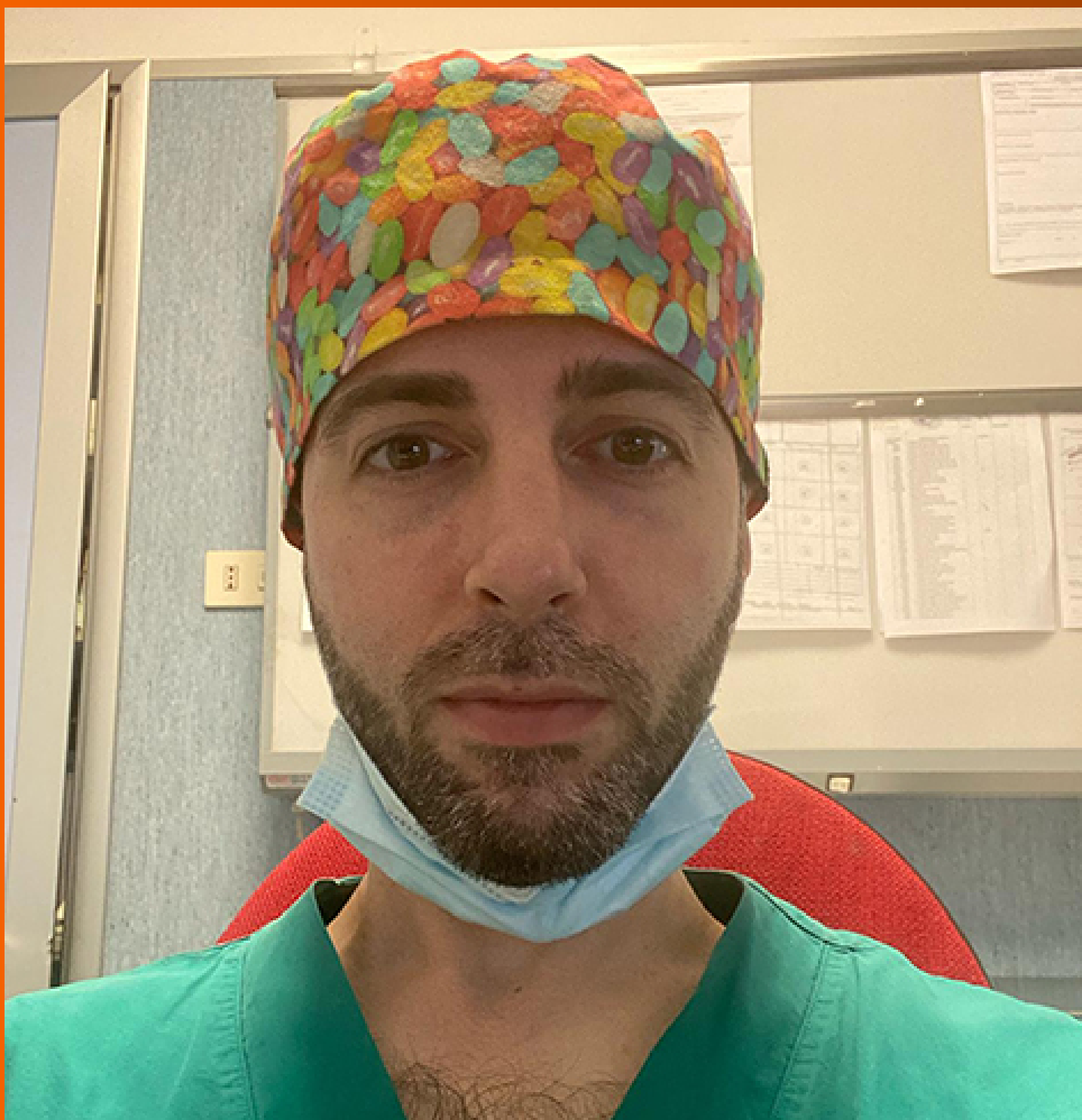

# World Journal of *Clinical Oncology*

*World J Clin Oncol* 2024 March 24; 15(3): 360-463



## EDITORIAL

- 360 Leveraging electrochemical sensors to improve efficiency of cancer detection  
*Fu L, Karimi-Maleh H*
- 367 Mechanisms and potential applications of COPS6 in pan-cancer therapy  
*Wu T, Ji MR, Luo LX*
- 371 High-dose methotrexate and zanubrutinib combination therapy for primary central nervous system lymphoma  
*Yadav BS*
- 375 Role of targeting ferroptosis as a component of combination therapy in combating drug resistance in colorectal cancer  
*Xie XT, Pang QH, Luo LX*
- 378 Approaches and challenges in cancer immunotherapy pathways  
*Kapritsou M*

## MINIREVIEWS

- 381 Current interventional options for palliative care for patients with advanced-stage cholangiocarcinoma  
*Makki M, Bentaleb M, Abdulrahman M, Suhood AA, Al Harthi S, Ribeiro Jr MA*

## ORIGINAL ARTICLE

## Retrospective Study

- 391 Ferroptosis biomarkers predict tumor mutation burden's impact on prognosis in HER2-positive breast cancer  
*Shi JY, Che X, Wen R, Hou SJ, Xi YJ, Feng YQ, Wang LX, Liu SJ, Lv WH, Zhang YF*

## Observational Study

- 411 Clinical application of reserved gastric tube in neuroendoscopic endonasal surgery for pituitary tumor  
*Chen X, Zhang LY, Wang ZF, Zhang Y, Yin YH, Wang XJ*

## Prospective Study

- 419 Nomogram based on multimodal magnetic resonance combined with B7-H3mRNA for preoperative lymph node prediction in esophagus cancer  
*Xu YH, Lu P, Gao MC, Wang R, Li YY, Guo RQ, Zhang WS, Song JX*

**Clinical and Translational Research**

- 434** Establishment of a prognosis predictive model for liver cancer based on expression of genes involved in the ubiquitin-proteasome pathway  
*Li H, Ma YP, Wang HL, Tian CJ, Guo YX, Zhang HB, Liu XM, Liu PF*

**META-ANALYSIS**

- 447** Transarterial chemoembolization plus stent placement for hepatocellular carcinoma with main portal vein tumor thrombosis: A meta-analysis  
*Sui WF, Li JY, Fu JH*

**CASE REPORT**

- 456** PD-1 antibody in combination with chemotherapy for the treatment of SMARCA4-deficient advanced undifferentiated carcinoma of the duodenum: Two case reports  
*Shi YN, Zhang XR, Ma WY, Lian J, Liu YF, Li YF, Yang WH*

ABOUT COVER

Peer Reviewer of *World Journal of Clinical Oncology*, Alessandro Posa, MD, Department of Diagnostic Imaging, Oncologic Radiotherapy and Hematology, Fondazione Policlinico Universitario A. Gemelli - IRCCS, Rome 00168, RM, Italy. [alessandro.posa@policlinicogemelli.it](mailto:alessandro.posa@policlinicogemelli.it)

AIMS AND SCOPE

The primary aim of *World Journal of Clinical Oncology* (*WJCO*, *World J Clin Oncol*) is to provide scholars and readers from various fields of oncology with a platform to publish high-quality basic and clinical research articles and communicate their research findings online.

*WJCO* mainly publishes articles reporting research results and findings obtained in the field of oncology and covering a wide range of topics including art of oncology, biology of neoplasia, breast cancer, cancer prevention and control, cancer-related complications, diagnosis in oncology, gastrointestinal cancer, genetic testing for cancer, gynecologic cancer, head and neck cancer, hematologic malignancy, lung cancer, melanoma, molecular oncology, neurooncology, palliative and supportive care, pediatric oncology, surgical oncology, translational oncology, and urologic oncology.

INDEXING/ABSTRACTING

The *WJCO* is now abstracted and indexed in PubMed, PubMed Central, Emerging Sources Citation Index (Web of Science), Reference Citation Analysis, China Science and Technology Journal Database, and Superstar Journals Database. The 2023 Edition of Journal Citation Reports® cites the 2022 impact factor (IF) for *WJCO* as 2.8; IF without journal self cites: 2.8; 5-year IF: 3.0; Journal Citation Indicator: 0.36.

RESPONSIBLE EDITORS FOR THIS ISSUE

Production Editor: *Si Zhao*; Production Department Director: *Xu Guo*; Editorial Office Director: *Xu Guo*.

NAME OF JOURNAL

*World Journal of Clinical Oncology*

ISSN

ISSN 2218-4333 (online)

LAUNCH DATE

November 10, 2010

FREQUENCY

Monthly

EDITORS-IN-CHIEF

Hiten RH Patel, Stephen Safe, Jian-Hua Mao, Ken H Young

EDITORIAL BOARD MEMBERS

<https://www.wjgnet.com/2218-4333/editorialboard.htm>

PUBLICATION DATE

March 24, 2024

COPYRIGHT

© 2024 Baishideng Publishing Group Inc

INSTRUCTIONS TO AUTHORS

<https://www.wjgnet.com/bpg/gerinfo/204>

GUIDELINES FOR ETHICS DOCUMENTS

<https://www.wjgnet.com/bpg/GerInfo/287>

GUIDELINES FOR NON-NATIVE SPEAKERS OF ENGLISH

<https://www.wjgnet.com/bpg/gerinfo/240>

PUBLICATION ETHICS

<https://www.wjgnet.com/bpg/GerInfo/288>

PUBLICATION MISCONDUCT

<https://www.wjgnet.com/bpg/gerinfo/208>

ARTICLE PROCESSING CHARGE

<https://www.wjgnet.com/bpg/gerinfo/242>

STEPS FOR SUBMITTING MANUSCRIPTS

<https://www.wjgnet.com/bpg/GerInfo/239>

ONLINE SUBMISSION

<https://www.f6publishing.com>



## Current interventional options for palliative care for patients with advanced-stage cholangiocarcinoma

Maryam Makki, Malak Bentaleb, Mohammed Abdulrahman, Amal Abdulla Suhood, Salem Al Harthi, Marcelo AF Ribeiro Jr

**Specialty type:** Gastroenterology and hepatology

**Provenance and peer review:**

Invited article; Externally peer reviewed.

**Peer-review model:** Single blind

**Peer-review report's scientific quality classification**

Grade A (Excellent): 0  
Grade B (Very good): B  
Grade C (Good): 0  
Grade D (Fair): 0  
Grade E (Poor): 0

**P-Reviewer:** Chen SY, China

**Received:** December 11, 2023

**Peer-review started:** December 11, 2023

**First decision:** January 4, 2024

**Revised:** January 18, 2024

**Accepted:** February 27, 2024

**Article in press:** February 27, 2024

**Published online:** March 24, 2024



**Maryam Makki, Marcelo AF Ribeiro Jr**, Department of Surgery, Division of Trauma, Critical Care and Acute Care Surgery, Sheikh Shakhbout Medical City, Abu Dhabi 11001, United Arab Emirates

**Malak Bentaleb, Mohammed Abdulrahman, Marcelo AF Ribeiro Jr**, Department of Surgery, College of Medicine and Health Sciences, Khalifa University, Abu Dhabi 11001, United Arab Emirates

**Amal Abdulla Suhood, Salem Al Harthi**, Department of Surgery, Division of Hepato-Pancreato-Biliary (HPB) Surgery, Sheikh Shakhbout Medical City, Abu Dhabi 91888, United Arab Emirates

**Corresponding author:** Marcelo AF Ribeiro Jr, FAASLD, FACS, MD, PhD, Chief Physician, Professor, Surgeon, Department of Surgery, Division of Trauma, Critical Care and Acute Care Surgery, Sheikh Shakhbout Medical City, PO Box 11001, Abu Dhabi 11001, United Arab Emirates. [drmrribeiro@gmail.com](mailto:drmrribeiro@gmail.com)

### Abstract

Primary biliary tract tumors are malignancies that originate in the liver, bile ducts, or gallbladder. These tumors often present with jaundice of unknown etiology, leading to delayed diagnosis and advanced disease. Currently, several palliative treatment options are available for primary biliary tract tumors. They include percutaneous transhepatic biliary drainage (PTBD), biliary stenting, and surgical interventions such as biliary diversion. Systemic therapy is also commonly used for the palliative treatment of primary biliary tract tumors. It involves the administration of chemotherapy drugs, such as gemcitabine and cisplatin, which have shown promising results in improving overall survival in patients with advanced biliary tract tumors. PTBD is another palliative treatment option for patients with unresectable or inoperable malignant biliary obstruction. Biliary stenting can also be used as a palliative treatment option to alleviate symptoms in patients with unresectable or inoperable malignant biliary obstruction. Surgical interventions, such as biliary diversion, have traditionally been used as palliative options for primary biliary tract tumors. However, biliary diversion only provides temporary relief and does not remove the tumor. Primary biliary tract tumors often present in advanced stages, making palliative treatment the primary option for improving the quality of life of patients.

**Key Words:** Cholangiocarcinoma; Palliative care; Endoscopic treatment; Surgery; Complications; Interventional radiology

©The Author(s) 2024. Published by Baishideng Publishing Group Inc. All rights reserved.

**Core Tip:** Nowadays, we still see a high incidence of primary biliary tract tumors arriving at emergency departments with a clinical picture of jaundice of unknown etiology. Unfortunately, when jaundice is diagnosed, most patients already show signs of advanced disease. It is up to the attending physician to offer the best alternatives for palliative treatment for a better quality of life of patients. The aim of this study is to evaluate the interventional palliative treatment options currently used to clinically improve symptoms and their results and related complications.

**Citation:** Makki M, Bentaleb M, Abdulrahman M, Suhood AA, Al Harthi S, Ribeiro Jr MA. Current interventional options for palliative care for patients with advanced-stage cholangiocarcinoma. *World J Clin Oncol* 2024; 15(3): 381-390

**URL:** <https://www.wjgnet.com/2218-4333/full/v15/i3/381.htm>

**DOI:** <https://dx.doi.org/10.5306/wjco.v15.i3.381>

## INTRODUCTION

Cholangiocarcinoma (CCA) is a malignant tumor of the epithelial cells of the biliary tract[1]. CCAs can be divided into three forms: intrahepatic CCA (iCCA), distal extrahepatic CCA (eCCA), and perihilar pCCA[2,3]. Similarities exist among these three forms, but key differences lead to distinct outcomes[3]. CCA is considered a very aggressive tumor that presents with a poor prognosis by the time it is diagnosed[4]. Surgical resection is the only meaningful option for the possible treatment of CCA. Patients who are not candidates for surgery are considered for palliative care treatment[4].

The main goal of palliative care is to enhance the quality of life of patients[5]. Only a few patients who present with CCA are candidates for surgical treatment[6]. It has been reported that less than 20% of patients diagnosed with iCCA are eligible for surgical resection[7]. Appropriate palliative care treatments in CCA are influenced by the classification of the tumor[8]. Current palliative options include biliary stenting, chemotherapy, radiofrequency ablation, and photodynamic therapy[8]. Adverse effects are associated with some of these palliative treatments[8], and a full comprehensive understanding of the benefits and risks of current palliative treatment options will help clinicians determine the most appropriate course of action.

## RISK FACTORS

The risk factors for the incidence of CCA include primary sclerosing cholangitis, parasitic infections, toxins, bile duct cysts, hepatolithiasis, hepatic cirrhosis, and viral hepatitis[9,10]. In addition, there may be evidence that certain genetic polymorphisms regulate the risk of CCA[10]. Diabetes and heavy alcohol ingestion may increase the risk of CCA[9]. CCA in Asian countries is significantly associated with the liver flukes *Clonorchis sinensis* and *Opisthorchis viverrini*[11]. The effects of hepatitis B and hepatitis C on the incidence of CCA have not been completely studied[11]. Surveillance of risk factors for CCA needs to be established as it may facilitate better prognosis for patients.

## EPIDEMIOLOGY

The epidemiology of CCA differs depending on factors such as geography, risk factors, and age. The largest incidence of CCA is in Asia, with the highest occurring in parts of Thailand[12]. The incidence rates in Western countries are lower than those in Asian countries[12].

The prognosis of CCA is poor, with the only curative option being surgical resection in early-stage tumors[13]. The mortality rate of CCA has increased significantly in recent years, up to a 36% increase in mortality from 1999 to 2014 in a United States-based study[14]. The 5-year survival rates for certain CCAs range from 5% to 10%[15]. Some studies have described the percentage of resectable CCAs. In a cohort study describing hilar CCAs, research has shown that only 26% of hilar CCAs are resectable[16]. It has also been reported that only 15% of patients with iCCA present with a resectable tumor at the time of diagnosis[17]. Therefore, the importance of palliative care in CCA cannot be understated and must be fully explored and understood to deliver the most appropriate individualized care for each patient.

## CLINICAL PRESENTATION

The clinical presentation of CCA depends on the type, stage, and location of the tumor. The most common presentation of

CCA is jaundice, which manifests as a yellowish pigmentation of the skin and mucous membranes[18]. However, in iCCA, because tumor growth is intrahepatic, patients are usually asymptomatic and jaundice only manifests at later stages because obstruction is less frequent[19]. Studies have shown that jaundice is reported as an initial symptom of iCCA in only 10%-15%[18] of cases and that the diagnosis of early-stage iCCA represents an incidental finding in almost 25% of cases[20]. Other clinical symptoms associated with the onset of iCCA are nonspecific and include the following: Malaise, cachexia, dull right upper quadrant abdominal pain, and night sweats[20]. Conversely, most eCCAs and pCCAs are associated with biliary obstruction. It has been estimated that 90% of eCCA cases present with symptoms of obstructive jaundice[21], which include jaundice, pale stools, dark urine, and pruritis. A cohort study demonstrated that bilirubin levels are significantly more elevated in eCCA and pCCAs than in iCCA because of the larger frequency of biliary obstruction[22]. During the course of the disease, patients with eCCA present with nonspecific symptoms similar to iCCA, such as weight loss, abdominal pain, night sweats, fatigue, emesis, vomiting, and loss of appetite, in addition to an increase in cholestasis laboratory findings[23].

On physical examination, eCCA is characterized by jaundice, hepatomegaly, and a palpable gallbladder (Courvoisier sign) whereas iCCA usually presents mainly with right upper quadrant tenderness[24]. CCA has also been associated with rare cutaneous manifestations, including sweet syndrome, erythema multiforme, and porphyria cutanea tarda[24]. However, these findings are nonspecific and can be found in other pathologies. Therefore, a definitive diagnosis of CCA requires further laboratory and imaging investigations.

## DIAGNOSIS

The diagnosis and early detection of CCA remain challenging. It is important to check bilirubin, alkaline phosphatase (ALP), gamma-glutamyl transpeptidase (GGT), alanine transaminase (ALT), and aspartate aminotransferase (AST) levels in all suspected patients. In patients with eCCA, bilirubin, ALP, and GGT levels are elevated, whereas in patients with iCCA, ALP level is atypical, but the other values are within normal ranges[24]. In the early stages of CCA, ALT and AST levels are normal, but as the disease progresses, they increase because of the hepatocellular damage caused by cholestasis [24]. Blood biomarkers are also useful for detecting CCA. Cancer antigen 19-9 (CA 19-9) is an important prognostic factor at presentation and has been associated with poor prognosis[22]. However, the use of CA 19-9 is limited as it has low specificity in distinguishing malignant from benign pathologies, and it is absent in patients with deficient Lewis antigen [24]. Carcinoembryonic antigen and alpha fetoprotein can also be used, but both have shown limited specificity and sensitivity.

The diagnosis of CCA relies heavily on imaging modalities. Transabdominal ultrasound is often employed as an initial imaging modality for CCA diagnosis in patients with obstructive jaundice because it is beneficial for examining the origins of bile duct obstruction and characterizing liver lesions[25]. In addition to detecting CCA, this allows the exclusion of more common etiologies for obstruction jaundice such as choledocholithiasis. With new advancements in technology, the use of contrast-enhanced ultrasound has demonstrated significant potential in assessing both luminal and extraluminal masses in the diagnosis of CCA[25]. Computed tomography (CT) is conducted in 90% of cases with possible CCA diagnosis[25]. CT plays an important role during the initial evaluation of CCA: It demonstrates features such as the extent of the tumor, it ascertains the potential of surgical resectability, and it allows the estimation of prognostic pathological factors, including vascular infiltration and the presence of lymph node metastasis[25]. The two most commonly used imaging techniques after the identification of the tumor are endoscopic retrograde cholangiopancreatography (ERCP) and magnetic resonance cholangiopancreatography (MRCP)[21]. MRCP is the preferred modality because it allows the accurate assessment of tumor resectability[26]. Endoscopic ultrasound (EUS) and fine needle aspiration guided by EUS have also been reported to help with the diagnosis and staging of CCA[26]. ERCP is still widely used and preferred by some physicians and surgeons because it allows cytological sampling and histological confirmation of the malignancy[21,24].

## PALLIATIVE TREATMENT DEFINITION

Palliative care is a medical holistic approach that aims to enhance the well-being of patients who are confronting challenges related to incurable life-threatening illnesses by preventing and alleviating physical, psychological, and spiritual suffering[27]. Palliative care should involve interdisciplinary teams with excellent communication skills to support patients and their families[27]. In patients with CCA with a locally advanced, unresectable, or recurrent tumor, palliative care goals are to relieve symptoms of obstructive jaundice, pain, and pruritis[26].

In this review, we summarize recent findings on interventional procedures for the palliative care management of CCA. Different interventional options that are currently available and their benefits and complications are discussed. Systemic treatment, although available, is beyond the scope of this review.

## MANAGEMENT

Palliative biliary drainage is used in advanced-stage CCA to alleviate symptoms such as pain, severe pruritus, and cholangitis. Patients with jaundice who are asymptomatic and have a life expectancy of less than 3 months are generally

**Table 1 Palliative treatment options for cholangiocarcinoma and their associated techniques, indications, and complications**

Type	Technique	Indication	Complications
Percutaneous drainage	PTBD	Proximal malignant biliary obstructions (particularly Bismuth type III and IV perihilar CCA patients)	Catheter-related complications: wound care, hygiene maintenance, catheter dislodgement, and PTBD blockages  Acute cholangitis, bleeding, and peri catheter leakage
	PTBS	Specific patients with malignant biliary obstruction	No catheter-related complications (due to no external drainage)  Cholangitis, pancreatitis, bleeding, stent dysfunction, cholecystitis, duodenal perforation, stent obstruction (due to tumor overgrowth)
Endoscopic drainage	ERCP with biliary stenting	Patients with incurable conditions ( <i>e.g.</i> Unresectable tumors, malignant hilar obstruction)	Stent occlusion or dysfunction (mainly due to tumor ingrowth)
	EUS-EBD	Cases where ERCP may be difficult due to anatomical variations, altered anatomy from prior surgeries or tumor infiltration	Minimal complications including pancreatitis and cholecystitis
Surgical Drainage (only considered as a final option after failure of other approaches)	Choledochojejunostomy	Distal CCA	High perioperative morbidity and mortality
	Intrahepatic bile duct bypass	Peri hilar CCA	
	Extrahepatic bile duct bypass	Distal obstruction or Bismuth type I	High perioperative morbidity and mortality  Frequently ineffective due to inadequacy of a single anastomosis to drain a sufficient volume of functioning liver
	Left hepaticojejunostomy	Bismuth type IIIa	
	Right hepaticojejunostomy	Bismuth type IIIb	
	Right or left sectoral duct bypass	Bismuth type IV	

PTBD: Percutaneous transhepatic biliary drainage; PTBS: Percutaneous transhepatic biliary stenting; ERCP: Endoscopic retrograde cholangiopancreatography; EUS-EBD: Endoscopic ultrasound guided endoscopic biliary drainage; CCA: Cholangiocarcinoma.

not candidates for biliary drainage procedures. Other purposes of palliative biliary drainage include improving functional status and liver function to enable subsequent systemic chemotherapy. This procedure encompasses three methods: percutaneous, endoscopic, and surgical bypass (Table 1).

## PERCUTANEOUS PALLIATIVE BILIARY DRAINAGE

The percutaneous method for palliative biliary drainage involves a guided puncture using ultrasonography aiming to place a catheter into the dilated bile ducts. This approach includes two techniques: percutaneous transhepatic biliary drainage (PTBD) and percutaneous transhepatic biliary stenting (PTBS). Palliative PTBD plays a crucial role in decompressing the biliary system specially in proximal obstructions, particularly in cases of Bismuth type III and IV perihilar CCA. Research suggests that PTBD has a higher success rate in therapy with fewer complications related to cholangitis compared with the endoscopic approach[28]. However, wound care, catheter displacement, blockages, and even hygiene maintenance may represent a challenge for some patients. To address these challenges, patients receive catheter care training before hospital discharge[28,29]. Complications may include acute cholangitis, bleeding, and pericatheter leakage.

Palliative PTBS is a procedure aimed at managing jaundice and serves as an optional treatment for specific patients with malignant biliary obstruction. The main advantage of this procedure is to restore the physiological pathway to the biliary drainage to the duodenum and minimize the loss of bile salts and electrolytes. This is achieved using either plastic or metallic stents. Studies have indicated that PTBS, particularly with the implantation of self-expandable metallic stents (SEMS), has better efficacy than catheter drainage. PTBS can effectively reduce complications associated with catheter usage and can improve the overall quality of life of patients by eliminating the need for external drainage. Metal stents have a larger diameter, present a better long-term patency, and are more cost-effective compared with plastic ones. In the palliative care of advanced hilar CCA (Bismuth III and IV), percutaneous stenting outcomes exceed those by endoscopy [30-33].

The PTBS procedure is performed under local anesthesia and moderate sedation. This procedure involves inserting a 0.035 in guidewire into the previously placed PTBD and then replacing the PTBD catheter with 5 French diagnostic catheters (specifically Cobra catheters). The tract passing through the obstructed region into the duodenum is cannulated using a 0.035 in guidewire, followed by the introduction of a metallic stent. Typically, pre stent dilation of malignant biliary strictures is avoided to prevent tumoral bleeding that might result in early stent blockage[34]. After stent placement, an internal-external drainage catheter (temporary close catheter hub) is inserted as a precautionary measure in case of stent malfunction. Follow-up after biliary stenting includes clinical assessment and laboratory investigations at the two-week mark. A cholangiogram through the internal-external drainage catheter is performed after two weeks to assess stent patency, followed by the removal of the internal-external drainage catheter.

The most frequent early complications after percutaneous procedures are cholangitis, pancreatitis, and bleeding. Stent dysfunction, bleeding, cholecystitis, and less frequently, duodenal perforation are usually the most frequent late ones. The major complication of biliary stenting is recurrent jaundice or cholangitis resulting from stent obstruction. Biliary sludge and tumor ingrowth through the stent are the primary causes of obstruction[35].

## ENDOSCOPIC APPROACH

Selecting the type of stent for palliative drainage involves different factors to be considered, like the location of the obstruction, the patient's prognosis, the risk of potential stent complications such as blockage or movement, the preference of the endoscopist, and the availability of different stent types. In cases where hilar obstruction is presented like in hilar tumors, multidisciplinary teamwork is a must for its management. Relieve the obstruction of the bile ducts in advanced unresectable hilar tumors may be challenge and usually requires multiple endoscopic and/or percutaneous procedures[36,37].

Typically for the cases with hilar obstruction ERCP with uncovered SEMS represents the standard of care to prevent drainage blockage from the opposite biliary system. Similarly, in the treatment of hilar obstruction, the use of uncovered SEMS is recommended to prevent blockage of the left or right hepatic duct[37].

Uncovered SEMS offer notable advantages over plastic stents, primarily due to their wire mesh design that remains open and does not obstruct the side branches of the intrahepatic bile duct. They also feature a delivery system that allows passage through tight biliary strictures, such as a sharp tip, enabling the use of stents with reduced diameter sizes, which is particularly beneficial for lesions located proximally[37,38].

Several studies demonstrated that for patients with hilar obstructions SEMS provides higher clinical success rates as well as less need for reinterventions when compared to plastic stents[31,38-42]. In one trial involving 188 patients diagnosed with unresectable hilar CCA, the rates of success using SEMS comparing with plastic stents regarding drainage was 70% *vs* 46% and the authors also observed a prolonged overall survival (median 126 *vs* 49 d)[42]. Another study with 60 patients demonstrated that SEMS had superior patency rates at six months (81% *vs* 20%) and required fewer reinterventions (0.63 *vs* 1.80 interventions per patient)[39].

In cases of unresectable cancer with obstructed hilar regions, the placement of bilateral SEMS represents the standard approach when technically feasible to optimize biliary drainage, particularly when both liver lobes are affected by obstruction. Before the ERCP procedure, imaging techniques such as CT or MRCP must be available to identify the dominant biliary system, allowing the endoscopy team to plan, in case the bilateral stenting is not possible, to which of the ducts the stent should place to provide adequate bile drainage.

The efficacy of drainage is affected by the amount of drained liver volume[33,43,44]. Previously, it was commonly accepted that draining a minimum of 25% of the liver volume was required to relieve jaundice. However, recent research suggests that draining more than 50% of the total liver volume (assessed *via* CT) is associated with enhanced overall survival. If a single stent fails to alleviate symptoms by draining more than 50% of the total liver volume, the consideration of ERCP-guided bilateral stenting and/or percutaneous drainage may be warranted[44].

For certain patients, the placement of a single, unilateral stent provides adequate drainage and relief from symptoms. However, it remains uncertain whether bilateral drainage offers superior outcomes compared with unilateral placement [45-47]. A meta-analysis of seven studies involving more than 600 patients diagnosed with tumoral hilar obstruction suggested that bilateral stenting did not significantly differ from unilateral stenting in terms of clinical response rates, stent occlusion, cholangitis, or patient mortality[45]. Nevertheless, another study involving 133 patients that were treated with SEMS revealed that patients that had bilateral stents had a lower chance of failure when compared to unilateral ones. (hazard ratio, 0.30; 95%CI, 0.17-0.52)[46].

The primary long-term complication encountered after placing SEMS for malignant biliary obstruction is stent occlusion. The diagnosis of stent dysfunction typically involves the presence of two of the following three specified criteria:

Dilatation of the bile duct system demonstrated by ultrasound.

Abnormal elevation of serum bilirubin levels ( $\geq 2$  mg/dL) with an increase of  $\geq 1$  mg/dL compared with the value following the initial successful drainage.

Increase in ALP/gamma-glutamyl transferase to more than double the upper limit of normal values with an increase of at least 30 U/L.

### Manifestations of cholangitis[47]

Tumor ingrowth represents the main reason for stent occlusion and it is more related to uncovered SEMS[42]. Furthermore, this overgrowth, will involves the blockage of the stent's proximal or distal ends, contributes to long-term

stent occlusion. Occasionally, obstruction due to sludge, mucus, or debris may occur, but it typically occurs together with the progression of the tumor itself.

The average functional duration of this prosthesis ranges between 5 and 6 months[48,49] before obstruction occurs. Managing occluded stents involves various methods such as balloon mechanical cleaning, placement of plastic or metallic stents, and endobiliary radiofrequency ablation. Mechanical cleaning is suitable for debris occlusion but should be combined with other procedures when tumor ingrowth is present. Placement of a second plastic stent has a shorter patency period, typically lasting 60-90 d, compared with the patency period of 100 d for second SEMS placements[42]. Endobiliary radiofrequency ablation is an innovative intervention used to safely ablate ingrown tumors within the stent lumen, leading to long-term patency comparable to SEMS placement[49]. The advantage of this procedure is to not compromise the stent lumen and represents a benefit comparing to the placement of a second stent that may decrease its diameter.

Retrospective studies that compare the safety and effectiveness of percutaneous treatment *vs* endoscopic treatment for obstructed hilar bile ducts have shown that percutaneous interventions lead to a faster therapeutic decrease in bilirubin levels, fewer instances of infections, and reduced need for repeated drainage procedures[50-53]. Among patients with tumors in the hilar region who undergo endoscopic treatment, those who receive a unilateral stent-particularly when both sides of the liver's bile ducts have been visualized with contrast-experience notably poorer survival rates compared to patients with bilateral stents[54]. Furthermore, the risk of post endoscopy cholangitis increases with the extent of isolation caused by the hilar tumor, with Bismuth I patients having only a 4% risk and Bismuth III and IV patients having a nearly 60% risk[55]. Another study comparing the outcome of endoscopic *vs* percutaneous drainage in patients with advanced type III or IV hilar CCA concluded that the percutaneous SEMS group exhibited a notably higher success rate in biliary decompression compared to the endoscopic SEMS group (92.7% *vs* 77.3%, respectively,  $P = 0.049$ ). Although the overall occurrence of procedure-related complications was comparable between both groups, one fatality resulting from biliary sepsis was recorded in the endoscopic SEMS group. Patients who initially achieved successful biliary drainage, regardless of the procedure used, experienced substantially longer median survival than those for whom biliary drainage failed (8.7 *vs* 1.8 months, respectively,  $P < 0.001$ ). Once successful biliary decompression was attained, and the median survival and duration of stent patency were similar in both study groups[52].

In cases of advanced malignant hilar strictures (Bismuth III and IV), the percutaneous method for biliary drainage is favored over the endoscopic approach because of its notably higher success rate (93% compared to 77%, with a  $P$  value of 0.049) and reduced incidence of cholangitis related to the procedure. In addition, the percutaneous approach enables the precise selection of the affected lobe for drainage[52].

## EUS GUIDED ENDOSCOPIC BILIARY DRAINAGE

EUS provides real-time imaging with high resolution and has the ability to visualize the bile ducts and adjacent structures in great detail. EUS guided endoscopic biliary drainage (EUS-EBD) combines the advantages of EUS and biliary drainage, allowing the accurate placement of stents or drainage catheter under direct visualization. This technique is valuable in cases where conventional ERCP may be challenging because of anatomical variations, altered anatomy from prior surgeries, or tumor infiltration.

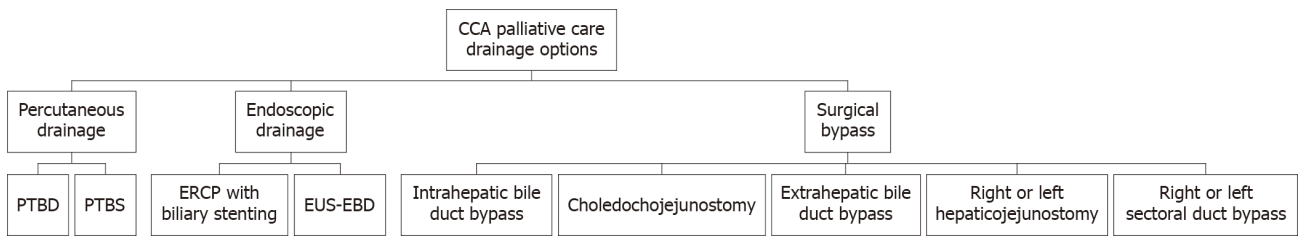
The EUS-EBD procedure involves passing an echoendoscope through the gastrointestinal tract to access the duodenum and visualize the biliary tree using ultrasound. Once the target area is identified, a guidewire is advanced through the obstructed bile duct under EUS guidance. Following successful guidewire placement, a biliary stent or drainage catheter is deployed to relieve the obstruction and alleviate symptoms such as jaundice and pruritus. The main benefits of EUS-EBD are improved visualization, precise guidance, real-time ultrasound guidance, enhanced precision of wire placement, reduced risk of complications, overcoming anatomical challenges, and permitting navigation through anatomical variations or distorted anatomy caused by the tumor, making it a valuable option in complex cases.

Several studies have demonstrated the efficacy and safety of EUS-EBD in the palliative care of patients with advanced CCA. Notable outcomes include successful drainage, symptom relief, and improved quality of life. Comparative studies have shown that EUS-EBD can be as effective as or even superior to traditional ERCP in certain cases[56,57].

### Surgical approach

Surgical bypass procedures have demonstrated a significant increase in perioperative mortality, ranging from 0% to 17%, and morbidity, with rates between 17% and 55%[58]. Nowadays the surgical approach will only be considered if other options like percutaneous and/or endoscopic treatments are not available or fail. In instances where laparotomy reveals distant metastases, surgical bypass may be considered. Choledochojejunostomy is a feasible surgical bypass procedure for distal obstructions, whereas intrahepatic bile duct bypass is appropriate for perihilar CCA. Extrahepatic bile duct bypass, although technically less challenging, is associated with lower morbidity and is suitable for distal obstructions or Bismuth type I in the perihilar region. Palliative surgical bypass for perihilar CCA involves intricate surgeries tailored to each tumor type. According to the location of the tumoral obstruction, left or right main ducts, the surgeon will proceed with either a left or right hepaticojejunostomy. Bismuth type IV may require right or left sectoral duct bypass. However, surgical bypass for this type of tumors are often ineffective because of the inadequacy of a single anastomosis to drain a sufficient volume of functioning liver. Therefore, in cases of Bismuth IV, a bilateral hepaticojejunostomy bypass should be considered with exceptional selectivity[58].

Three randomized trials[59-61] that compared surgical bypass to endoscopic drainage demonstrated similar effectiveness in alleviating symptoms. However, endoscopic drainage exhibited fewer early complications, whereas surgical



**Figure 1** Current management options for palliative care of advanced cholangiocarcinoma. PTBD: Percutaneous transhepatic biliary drainage; PTBS: Percutaneous transhepatic biliary stenting; ERCP: Endoscopic retrograde cholangiopancreatography; EUS-EBD: Endoscopic ultrasound guided endoscopic biliary drainage; CCA: Cholangiocarcinoma.

bypass presented fewer late complications. It is important to note that these trials focused on patients with a lower end block caused by pancreatic and periampullary carcinoma, which limits the direct extrapolation of these findings to patients with a hilar block. In the case of locally advanced gallbladder cancer with an average survival of 3-6 months, nonoperative methods might be more effective in alleviating symptoms[62]. Two randomized trials evaluated endoscopic and percutaneous drainage methods for malignant biliary obstruction[62,63]. Speer *et al*[63] demonstrated that endoscopic drainage surpassed percutaneous drainage in terms of successful drainage (81% *vs* 61%) and lower 30-d mortality (15% *vs* 33%). This trial included 75 patients, but only 29 had a hilar block. However, the less favorable outcomes associated with percutaneous stenting might be attributed to the use of a rigid external percutaneous transhepatic catheter for drainage, leading to increased morbidity and mortality. By contrast, Piñol *et al*[64] showed different results with higher successful drainage (71% *vs* 42%,  $P = 0.03$ ) but more complications (61% *vs* 35%) with PTBD compared to endoscopic drainage. The median survival time significantly favored the PTBD group (3.7 *vs* 2 months,  $P = 0.02$ ). In addition, they compared a metal stent placed percutaneously with a plastic stent placed endoscopically (Figure 1).

## CONCLUSION

The basis for the palliative treatment of advanced CCA relies on the alleviation of the obstructive symptoms related to the drainage of the biliary tract. Proper management must be defined by a multidisciplinary team that considers the radiological features of the tumor and the resources available in the institution. The results of systemic treatment for palliative care can be improved if the patient's biliary tract has been properly drained using one of the presented techniques.

## FOOTNOTES

**Author contributions:** Ribeiro Jr MA supervise the project and analyzed the data; Makki M, Bentaleb M, and Abdulrahman M contributed equally to this work; Ribeiro Jr MA designed the research study; Makki M, Bentaleb M, and Abdulrahman M performed the research; Suhool AA, Al Harthi S contributed reviewing the data and performing critical analysis; Makki M, Bentaleb M, Abdulrahman M wrote the manuscript; All authors have read and approve the final manuscript.

**Conflict-of-interest statement:** All the authors report no relevant conflicts of interest for this article.

**Open-Access:** This article is an open-access article that was selected by an in-house editor and fully peer-reviewed by external reviewers. It is distributed in accordance with the Creative Commons Attribution NonCommercial (CC BY-NC 4.0) license, which permits others to distribute, remix, adapt, build upon this work non-commercially, and license their derivative works on different terms, provided the original work is properly cited and the use is non-commercial. See: <https://creativecommons.org/licenses/by-nc/4.0/>

**Country/Territory of origin:** United Arab Emirates

**ORCID number:** Marcelo AF Ribeiro Jr 0000-0001-9826-4722.

**S-Editor:** Li L

**L-Editor:** A

**P-Editor:** Yuan YY

## REFERENCES

- 1 Ustundag Y, Bayraktar Y. Cholangiocarcinoma: a compact review of the literature. *World J Gastroenterol* 2008; **14**: 6458-6466 [PMID: 19030196 DOI: 10.3748/wjg.14.6458]

- 2 Halder R, Amarani A, Shroff RT. Cholangiocarcinoma: a review of the literature and future directions in therapy. *Hepatobiliary Surg Nutr* 2022; **11**: 555-566 [PMID: [36016753](#) DOI: [10.21037/hbsn-20-396](#)]
- 3 Banales JM, Cardinale V, Carpino G, Marziani M, Andersen JB, Invernizzi P, Lind GE, Folseraas T, Forbes SJ, Fouassier L, Geier A, Calvisi DF, Mertens JC, Trauner M, Benedetti A, Maroni L, Vaquero J, Macias RI, Raggi C, Perugorria MJ, Gaudio E, Boberg KM, Marin JJ, Alvaro D. Expert consensus document: Cholangiocarcinoma: current knowledge and future perspectives consensus statement from the European Network for the Study of Cholangiocarcinoma (ENS-CCA). *Nat Rev Gastroenterol Hepatol* 2016; **13**: 261-280 [PMID: [27095655](#) DOI: [10.1038/nrgastro.2016.51](#)]
- 4 Zamani Z, Fatima S. Biliary Tract Cancer. Treasure Island (FL): StatPearls Publishing, 2023
- 5 Teoli D, Schoo C, Kalish VB. Palliative Care. Treasure Island (FL): StatPearls Publishing, 2023
- 6 Patel T. Cholangiocarcinoma--controversies and challenges. *Nat Rev Gastroenterol Hepatol* 2011; **8**: 189-200 [PMID: [21460876](#) DOI: [10.1038/nrgastro.2011.20](#)]
- 7 Bath NM, Pawlik TM. Narrative review: current management and novel targeted therapies in intrahepatic cholangiocarcinoma. *Chin Clin Oncol* 2023; **12**: 5 [PMID: [36922354](#) DOI: [10.21037/cco-22-109](#)]
- 8 Mohammad T, Kahaleh M. Comparing palliative treatment options for cholangiocarcinoma: photodynamic therapy vs. radiofrequency ablation. *Clin Endosc* 2022; **55**: 347-354 [PMID: [35578751](#) DOI: [10.5946/ce.2021.274](#)]
- 9 Tyson GL, El-Serag HB. Risk factors for cholangiocarcinoma. *Hepatology* 2011; **54**: 173-184 [PMID: [21488076](#) DOI: [10.1002/hep.24351](#)]
- 10 Khan SA, Tavoroli S, Brandi G. Cholangiocarcinoma: Epidemiology and risk factors. *Liver Int* 2019; **39**: 19-31 [PMID: [30851228](#) DOI: [10.1111/liv.14095](#)]
- 11 Shin HR, Oh JK, Masuyer E, Curado MP, Bouvard V, Fang YY, Wiangnon S, Sripa B, Hong ST. Epidemiology of cholangiocarcinoma: an update focusing on risk factors. *Cancer Sci* 2010; **101**: 579-585 [PMID: [20085587](#) DOI: [10.1111/j.1349-7006.2009.01458.x](#)]
- 12 Qurashi M, Vithayathil M, Khan SA. Epidemiology of cholangiocarcinoma. *Eur J Surg Oncol* 2023; 107064 [PMID: [37709624](#) DOI: [10.1016/j.ejso.2023.107064](#)]
- 13 Mosconi S, Beretta GD, Labianca R, Zampino MG, Gatta G, Heinemann V. Cholangiocarcinoma. *Crit Rev Oncol Hematol* 2009; **69**: 259-270 [PMID: [18977670](#) DOI: [10.1016/j.critrevonc.2008.09.008](#)]
- 14 Yao KJ, Jabbour S, Parekh N, Lin Y, Moss RA. Increasing mortality in the United States from cholangiocarcinoma: an analysis of the National Center for Health Statistics Database. *BMC Gastroenterol* 2016; **16**: 117 [PMID: [27655244](#) DOI: [10.1186/s12876-016-0527-z](#)]
- 15 Garikipati SC, Roy P. Biliary Tract Cholangiocarcinoma. Treasure Island (FL): StatPearls Publishing, 2023
- 16 Ruys AT, van Haelst S, Busch OR, Rauws EA, Gouma DJ, van Gulik TM. Long-term survival in hilar cholangiocarcinoma also possible in unresectable patients. *World J Surg* 2012; **36**: 2179-2186 [PMID: [22569746](#) DOI: [10.1007/s00268-012-1638-5](#)]
- 17 Buettner S, van Vugt JL, IJzermans JN, Groot Koerkamp B. Intrahepatic cholangiocarcinoma: current perspectives. *Oncotargets Ther* 2017; **10**: 1131-1142 [PMID: [28260927](#) DOI: [10.2147/OTT.S93629](#)]
- 18 Forner A, Vidili G, Rengo M, Bujanda L, Ponz-Sarvisé M, Lamarca A. Clinical presentation, diagnosis and staging of cholangiocarcinoma. *Liver Int* 2019; **39**: 98-107 [PMID: [30831002](#) DOI: [10.1111/liv.14086](#)]
- 19 Zori AG, Yang D, Draganov PV, Cabrera R. Advances in the management of cholangiocarcinoma. *World J Hepatol* 2021; **13**: 1003-1018 [PMID: [34630871](#) DOI: [10.4254/wjh.v13.i9.1003](#)]
- 20 Cardinale V, Bragazzi MC, Carpino G, Di Matteo S, Overi D, Nevi L, Gaudio E, Alvaro D. Intrahepatic cholangiocarcinoma: review and update. *Hepatoma Res* 2018; **4**: 20 [DOI: [10.20517/2394-5079.2018.46](#)]
- 21 Vasilieva L, Papadimitriou SI, Alexopoulou A, Kostopoulos I, Papiris K, Pavlidis D, Xinopoulos D, Romanos A, Dourakis SP. Clinical presentation, diagnosis, and survival in cholangiocarcinoma: A prospective study. *Arab J Gastroenterol* 2016; **17**: 181-184 [PMID: [27914884](#) DOI: [10.1016/j.ajg.2016.10.003](#)]
- 22 Singal AG, Rakoski MO, Salgia R, Pelletier S, Welling TH, Fontana RJ, Lok AS, Marrero JA. The clinical presentation and prognostic factors for intrahepatic and extrahepatic cholangiocarcinoma in a tertiary care centre. *Aliment Pharmacol Ther* 2010; **31**: 625-633 [PMID: [20003093](#) DOI: [10.1111/j.1365-2036.2009.04218.x](#)]
- 23 Plentz RR, Malek NP. Clinical presentation, risk factors and staging systems of cholangiocarcinoma. *Best Pract Res Clin Gastroenterol* 2015; **29**: 245-252 [PMID: [25966425](#) DOI: [10.1016/j.bpg.2015.02.001](#)]
- 24 Shin DW, Moon SH, Kim JH. Diagnosis of Cholangiocarcinoma. *Diagnostics (Basel)* 2023; **13** [PMID: [36673043](#) DOI: [10.3390/diagnostics13020233](#)]
- 25 Olthof SC, Othman A, Clasen S, Schraml C, Nikolaou K, Bongers M. Imaging of Cholangiocarcinoma. *Visc Med* 2016; **32**: 402-410 [PMID: [28229074](#) DOI: [10.1159/000453009](#)]
- 26 Tantau AI, Mandruti A, Pop A, Zaharie RD, Crisan D, Preda CM, Tantau M, Mercea V. Extrahepatic cholangiocarcinoma: Current status of endoscopic approach and additional therapies. *World J Hepatol* 2021; **13**: 166-186 [PMID: [33708349](#) DOI: [10.4254/wjh.v13.i2.166](#)]
- 27 Raksataya A, Ahoja A, Krangkong V, Jareanrat A, Titapun A, Khuntikeo N. Palliative Care in Cholangiocarcinoma. In: Khuntikeo N, Andrews RH, Petney TN, Khan SA, editors. Liver Fluke, Opisthorchis viverrini Related Cholangiocarcinoma. Cham: Springer International Publishing 2023; 245-267
- 28 Zhao XQ, Dong JH, Jiang K, Huang XQ, Zhang WZ. Comparison of percutaneous transhepatic biliary drainage and endoscopic biliary drainage in the management of malignant biliary tract obstruction: a meta-analysis. *Dig Endosc* 2015; **27**: 137-145 [PMID: [25040581](#) DOI: [10.1111/den.12320](#)]
- 29 Zhang GY, Li WT, Peng WJ, Li GD, He XH, Xu LC. Clinical outcomes and prediction of survival following percutaneous biliary drainage for malignant obstructive jaundice. *Oncol Lett* 2014; **7**: 1185-1190 [PMID: [24944690](#) DOI: [10.3892/ol.2014.1860](#)]
- 30 Bai AG, Zheng CS, Zhou GF, Liang HM, Feng GS. Comparison of the therapeutic effects of PTBD and PTBS in treatment of malignant obstructive jaundice. *Zhonghua Zhong Liu Za Zhi* 2010; **32**: 456-458 [PMID: [20819490](#)]
- 31 Sangchan A, Kongkasame W, Pughkhem A, Jenwitheesuk K, Mairiang P. Efficacy of metal and plastic stents in unresectable complex hilar cholangiocarcinoma: a randomized controlled trial. *Gastrointest Endosc* 2012; **76**: 93-99 [PMID: [22595446](#) DOI: [10.1016/j.gie.2012.02.048](#)]
- 32 Sangchan A, Chaiyakunapruk N, Supakunkunti S, Pughkhem A, Mairiang P. Cost utility analysis of endoscopic biliary stent in unresectable hilar cholangiocarcinoma: decision analytic modeling approach. *Hepatogastroenterology* 2014; **61**: 1175-1181 [PMID: [25436278](#)]
- 33 Rerknimitr R, Angsuwatcharakon P, Ratanachu-ek T, Khor CJ, Ponnudurai R, Moon JH, Seo DW, Pantongrag-Brown L, Sangchan A, Pisessongsa P, Akaraviputh T, Reddy ND, Maydeo A, Itoi T, Pausawasdi N, Punamiya S, Attasanya S, Devereaux B, Ramchandani M, Goh KL; Asia-Pacific Working Group on Hepatobiliary Cancers. Asia-Pacific consensus recommendations for endoscopic and interventional

- management of hilar cholangiocarcinoma. *J Gastroenterol Hepatol* 2013; **28**: 593-607 [PMID: 23350673 DOI: 10.1111/jgh.12128]
- 34 Inal M, Aksungur E, Akgül E, Oguz M, Seydaoglu G. Percutaneous placement of metallic stents in malignant biliary obstruction: one-stage or two-stage procedure? *Cardiovasc Intervent Radiol* 2003; **26**: 40-45 [PMID: 12491022 DOI: 10.1007/s00270-002-2647-9]
  - 35 Sohn SH, Park JH, Kim KH, Kim TN. Complications and management of forgotten long-term biliary stents. *World J Gastroenterol* 2017; **23**: 622-628 [PMID: 28216968 DOI: 10.3748/wjg.v23.i4.622]
  - 36 Dumonceau JM, Tringali A, Papanikolaou IS, Blero D, Mangiavillano B, Schmidt A, Vanbiervliet G, Costamagna G, Devière J, García-Cano J, Gyökeres T, Hassan C, Prat F, Siersema PD, van Hooft JE. Endoscopic biliary stenting: indications, choice of stents, and results: European Society of Gastrointestinal Endoscopy (ESGE) Clinical Guideline - Updated October 2017. *Endoscopy* 2018; **50**: 910-930 [PMID: 30086596 DOI: 10.1055/a-0659-9864]
  - 37 Lee TH, Moon JH, Park SH. Biliary stenting for hilar malignant biliary obstruction. *Dig Endosc* 2020; **32**: 275-286 [PMID: 31578770 DOI: 10.1111/den.13549]
  - 38 Perdue DG, Freeman ML, DiSario JA, Nelson DB, Fennerty MB, Lee JG, Overby CS, Ryan ME, Bochna GS, Snady HW, Moore JP; ERCP Outcome Study ERCPST Group. Plastic versus self-expanding metallic stents for malignant hilar biliary obstruction: a prospective multicenter observational cohort study. *J Clin Gastroenterol* 2008; **42**: 1040-1046 [PMID: 18719507 DOI: 10.1097/MCG.0b013e31815853e0]
  - 39 Mukai T, Yasuda I, Nakashima M, Doi S, Iwashita T, Iwata K, Kato T, Tomita E, Moriwaki H. Metallic stents are more efficacious than plastic stents in unresectable malignant hilar biliary strictures: a randomized controlled trial. *J Hepatobiliary Pancreat Sci* 2013; **20**: 214-222 [PMID: 22415652 DOI: 10.1007/s00534-012-0508-8]
  - 40 Raju RP, Jaganmohan SR, Ross WA, Davila ML, Javle M, Raju GS, Lee JH. Optimum palliation of inoperable hilar cholangiocarcinoma: comparative assessment of the efficacy of plastic and self-expanding metal stents. *Dig Dis Sci* 2011; **56**: 1557-1564 [PMID: 21222156 DOI: 10.1007/s10620-010-1550-5]
  - 41 Wagner HJ, Knyrim K, Vakil N, Klose KJ. Plastic endoprotheses versus metal stents in the palliative treatment of malignant hilar biliary obstruction. A prospective and randomized trial. *Endoscopy* 1993; **25**: 213-218 [PMID: 7686100 DOI: 10.1055/s-2007-1010295]
  - 42 Liberato MJ, Canena JM. Endoscopic stenting for hilar cholangiocarcinoma: efficacy of unilateral and bilateral placement of plastic and metal stents in a retrospective review of 480 patients. *BMC Gastroenterol* 2012; **12**: 103 [PMID: 22873816 DOI: 10.1186/1471-230X-12-103]
  - 43 Takahashi E, Fukasawa M, Sato T, Takano S, Kadokura M, Shindo H, Yokota Y, Enomoto N. Biliary drainage strategy of unresectable malignant hilar strictures by computed tomography volumetry. *World J Gastroenterol* 2015; **21**: 4946-4953 [PMID: 25945008 DOI: 10.3748/wjg.v21.i16.4946]
  - 44 Vienne A, Hobeika E, Gouya H, Lapidus N, Fritsch J, Choury AD, Chrysostalis A, Gaudric M, Pelletier G, Buffet C, Chaussade S, Prat F. Prediction of drainage effectiveness during endoscopic stenting of malignant hilar strictures: the role of liver volume assessment. *Gastrointest Endosc* 2010; **72**: 728-735 [PMID: 20883850 DOI: 10.1016/j.gie.2010.06.040]
  - 45 Sawas T, Al Halabi S, Parsi MA, Vargo JJ. Self-expandable metal stents versus plastic stents for malignant biliary obstruction: a meta-analysis. *Gastrointest Endosc* 2015; **82**: 256-267.e7 [PMID: 25982849 DOI: 10.1016/j.gie.2015.03.1980]
  - 46 Lee TH, Kim TH, Moon JH, Lee SH, Choi HJ, Hwangbo Y, Hyun JJ, Choi JH, Jeong S, Kim JH, Park DH, Han JH, Park SH. Bilateral versus unilateral placement of metal stents for inoperable high-grade malignant hilar biliary strictures: a multicenter, prospective, randomized study (with video). *Gastrointest Endosc* 2017; **86**: 817-827 [PMID: 28479493 DOI: 10.1016/j.gie.2017.04.037]
  - 47 Schmidt A, Riecken B, Rische S, Klinger C, Jakobs R, Bechtler M, Kähler G, Dormann A, Caca K. Wing-shaped plastic stents vs. self-expandable metal stents for palliative drainage of malignant distal biliary obstruction: a randomized multicenter study. *Endoscopy* 2015; **47**: 430-436 [PMID: 25590188 DOI: 10.1055/s-0034-1391232]
  - 48 Ridditid W, Rerknimitr R. Management of an occluded biliary metallic stent. *World J Gastrointest Endosc* 2012; **4**: 157-161 [PMID: 22624066 DOI: 10.4253/wjge.v4.i5.157]
  - 49 Kang H, Chung MJ, Cho IR, Jo JH, Lee HS, Park JY, Park SW, Song SY, Bang S. Efficacy and safety of palliative endobiliary radiofrequency ablation using a novel temperature-controlled catheter for malignant biliary stricture: a single-center prospective randomized phase II TRIAL. *Surg Endosc* 2021; **35**: 63-73 [PMID: 32488654 DOI: 10.1007/s00464-020-07689-z]
  - 50 Saluja SS, Gulati M, Garg PK, Pal H, Pal S, Sahni P, Chattopadhyay TK. Endoscopic or percutaneous biliary drainage for gallbladder cancer: a randomized trial and quality of life assessment. *Clin Gastroenterol Hepatol* 2008; **6**: 944-950.e3 [PMID: 18585976 DOI: 10.1016/j.cgh.2008.03.028]
  - 51 Kloek JJ, van der Gaag NA, Aziz Y, Rauws EA, van Delden OM, Lameris JS, Busch OR, Gouma DJ, van Gulik TM. Endoscopic and percutaneous preoperative biliary drainage in patients with suspected hilar cholangiocarcinoma. *J Gastrointest Surg* 2010; **14**: 119-125 [PMID: 19756881 DOI: 10.1007/s11605-009-1009-1]
  - 52 Paik WH, Park YS, Hwang JH, Lee SH, Yoon CJ, Kang SG, Lee JK, Ryu JK, Kim YT, Yoon YB. Palliative treatment with self-expandable metallic stents in patients with advanced type III or IV hilar cholangiocarcinoma: a percutaneous versus endoscopic approach. *Gastrointest Endosc* 2009; **69**: 55-62 [PMID: 18657806 DOI: 10.1016/j.gie.2008.04.005]
  - 53 Walter T, Ho CS, Horgan AM, Warkentin A, Gallinger S, Greig PD, Kortan P, Knox JJ. Endoscopic or percutaneous biliary drainage for Klatskin tumors? *J Vasc Interv Radiol* 2013; **24**: 113-121 [PMID: 23182938 DOI: 10.1016/j.jvir.2012.09.019]
  - 54 Chang WH, Kortan P, Haber GB. Outcome in patients with bifurcation tumors who undergo unilateral versus bilateral hepatic duct drainage. *Gastrointest Endosc* 1998; **47**: 354-362 [PMID: 9609426 DOI: 10.1016/s0016-5107(98)70218-4]
  - 55 Rerknimitr R, Kladcharoen N, Mahachai V, Kullavanijaya P. Result of endoscopic biliary drainage in hilar cholangiocarcinoma. *J Clin Gastroenterol* 2004; **38**: 518-523 [PMID: 15220688 DOI: 10.1097/01.mcg.0000123204.36471.be]
  - 56 Khashab MA, Valeshabad AK, Afghani E, Singh VK, Kumbhari V, Messallam A, Saxena P, El Zein M, Lennon AM, Canto MI, Kalloo AN. A comparative evaluation of EUS-guided biliary drainage and percutaneous drainage in patients with distal malignant biliary obstruction and failed ERCP. *Dig Dis Sci* 2015; **60**: 557-565 [PMID: 25081224 DOI: 10.1007/s10620-014-3300-6]
  - 57 Artifon EL, Aparicio D, Paione JB, Lo SK, Bordini A, Rabello C, Otoch JP, Gupta K. Biliary drainage in patients with unresectable, malignant obstruction where ERCP fails: endoscopic ultrasonography-guided choledochoduodenostomy versus percutaneous drainage. *J Clin Gastroenterol* 2012; **46**: 768-774 [PMID: 22810111 DOI: 10.1097/MCG.0b013e31825f264c]
  - 58 Witzigmann H, Lang H, Lauer H. Guidelines for palliative surgery of cholangiocarcinoma. *HPB (Oxford)* 2008; **10**: 154-160 [PMID: 18773044 DOI: 10.1080/13651820801992567]
  - 59 Shepherd HA, Royle G, Ross AP, Diba A, Arthur M, Colin-Jones D. Endoscopic biliary endoprosthesis in the palliation of malignant obstruction of the distal common bile duct: a randomized trial. *Br J Surg* 1988; **75**: 1166-1168 [PMID: 2466520 DOI: 10.1002/bjs.1800751207]

- 60 **Smith AC**, Dowsett JF, Russell RC, Hatfield AR, Cotton PB. Randomised trial of endoscopic stenting versus surgical bypass in malignant low bileduct obstruction. *Lancet* 1994; **344**: 1655-1660 [PMID: 7996958 DOI: 10.1016/s0140-6736(94)90455-3]
- 61 **Andersen JR**, Sørensen SM, Kruse A, Rokkjaer M, Matzen P. Randomised trial of endoscopic endoprosthesis versus operative bypass in malignant obstructive jaundice. *Gut* 1989; **30**: 1132-1135 [PMID: 2475392 DOI: 10.1136/gut.30.8.1132]
- 62 **Lai EC**, Chu KM, Lo CY, Fan ST, Lo CM, Wong J. Choice of palliation for malignant hilar biliary obstruction. *Am J Surg* 1992; **163**: 208-212 [PMID: 1371206 DOI: 10.1016/0002-9610(92)90102-w]
- 63 **Speer AG**, Cotton PB, Russell RC, Mason RR, Hatfield AR, Leung JW, MacRae KD, Houghton J, Lennon CA. Randomised trial of endoscopic versus percutaneous stent insertion in malignant obstructive jaundice. *Lancet* 1987; **2**: 57-62 [PMID: 2439854 DOI: 10.1016/s0140-6736(87)92733-4]
- 64 **Piñol V**, Castells A, Bordas JM, Real MI, Llach J, Montaña X, Feu F, Navarro S. Percutaneous self-expanding metal stents versus endoscopic polyethylene endoprosthesis for treating malignant biliary obstruction: randomized clinical trial. *Radiology* 2002; **225**: 27-34 [PMID: 12354980 DOI: 10.1148/radiol.2243011517]



Published by **Baishideng Publishing Group Inc**  
7041 Koll Center Parkway, Suite 160, Pleasanton, CA 94566, USA

**Telephone:** +1-925-3991568

**E-mail:** [office@baishideng.com](mailto:office@baishideng.com)

**Help Desk:** <https://www.f6publishing.com/helpdesk>

<https://www.wjgnet.com>

