

World Journal of *Gastroenterology*

World J Gastroenterol 2014 December 14; 20(46): 17265-17692



**TOPIC HIGHLIGHT**

- 17265 Health care-associated hepatitis C virus infection
Pozzetto B, Memmi M, Garraud O, Roblin X, Berthelot P
- 17279 Locally advanced rectal cancer: The importance of a multidisciplinary approach
Berardi R, Maccaroni E, Onofri A, Morgese F, Torniai M, Tiberi M, Ferrini C, Cascinu S
- 17288 Early-onset colorectal cancer: A separate subset of colorectal cancer
Osorio Silla I, Rueda D, Rodríguez Y, García JL, Cruz Vigo F, Perea J
- 17297 Current status of function-preserving surgery for gastric cancer
Saito T, Kurokawa Y, Takiguchi S, Mori M, Doki Y
- 17305 Alternative splicing of DNA damage response genes and gastrointestinal cancers
Rahmutulla B, Matsushita K, Nomura F
- 17314 Genetic and phenotypic heterogeneity in tropical calcific pancreatitis
Paliwal S, Bhaskar S, Chandak GR
- 17324 Oxidative stress and inflammatory signaling in cerulein pancreatitis
Yu JH, Kim H
- 17330 Video capsule endoscopy: Perspectives of a revolutionary technique
Bouchard S, Ibrahim M, Van Gossum A

REVIEW

- 17345 Computed tomography perfusion imaging as a potential imaging biomarker of colorectal cancer
Hayano K, Fujishiro T, Sahani DV, Satoh A, Aoyagi T, Ohira G, Tochigi T, Matsubara H, Shuto K
- 17352 Anti-tumour necrosis factor agent and liver injury: Literature review, recommendations for management
Rossi RE, Parisi I, Despott EJ, Burroughs AK, O'Beirne J, Conte D, Hamilton MI, Murray CD

- 17360** Hepatitis B and human immunodeficiency virus co-infection

Phung BC, Sogni P, Launay O

- 17368** Hematopoietic stem cell transplantation for non-malignant gastrointestinal diseases

Al-toma A, Nijeboer P, Bouma G, Visser O, Mulder CJJ

ORIGINAL ARTICLE

- 17376** Pea3 expression promotes the invasive and metastatic potential of colorectal carcinoma

Mesci A, Taeb S, Huang X, Jairath R, Sivaloganathan D, Liu SK

- 17388** Epidemiology of upper gastrointestinal symptoms in Brazil (EpiGastro): A population-based study according to sex and age group

Rosário Dias de Oliveira Latorre M, Medeiros da Silva A, Chinzon D, Eisig JN, Dias-Bastos TRP

- 17399** Hybrid bioartificial liver support in cynomolgus monkeys with D-galactosamine-induced acute liver failure

Zhang Z, Zhao YC, Cheng Y, Jian GD, Pan MX, Gao Y

RESEARCH REPORT

- 17407** Hepatoprotective effect of nitric oxide in experimental model of acute hepatic failure

Saracyn M, Brytan M, Zdanowski R, Ząbkowski T, Dyrła P, Patera J, Wojtuś S, Kozłowski W, Wańkowicz Z

- 17416** T₃-induced liver AMP-activated protein kinase signaling: Redox dependency and upregulation of downstream targets

Videla LA, Fernández V, Cornejo P, Vargas R, Morales P, Ceballo J, Fischer A, Escudero N, Escobar O

- 17426** Lobaplatin inhibits growth of gastric cancer cells by inducing apoptosis

Yin CY, Lin XL, Tian L, Ye M, Yang XY, Xiao XY

- 17434** Oesophageal flap valvuloplasty and wrapping suturing prevent gastroesophageal reflux disease in dogs after oesophageal anastomosis

Dai JG, Liu QX, Den XF, Min JX

- 17439** miR-374b-5p suppresses RECK expression and promotes gastric cancer cell invasion and metastasis

Xie J, Tan ZH, Tang X, Mo MS, Liu YP, Gan RL, Li Y, Zhang L, Li GQ

**EVIDENCE-BASED
MEDICINE**

- 17448** Pancreaticoduodenectomy with vascular reconstruction for adenocarcinoma of the pancreas with borderline resectability
Cheung TT, Poon RTP, Chok KSH, Chan ACY, Tsang SHY, Dai WC, Chan SC, Fan ST, Lo CM

CASE CONTROL STUDY

- 17456** Case-control study of diabetes-related genetic variants and pancreatic cancer risk in Japan
Kuruma S, Egawa N, Kurata M, Honda G, Kamisawa T, Ueda J, Ishii H, Ueno M, Nakao H, Mori M, Matsuo K, Hosono S, Ohkawa S, Wakai K, Nakamura K, Tamakoshi A, Nojima M, Takahashi M, Shimada K, Nishiyama T, Kikuchi S, Lin Y

RETROSPECTIVE STUDY

- 17463** Extraintestinal manifestations in a large series of Italian inflammatory bowel disease patients
Zippi M, Corrado C, Pica R, Avallone EV, Cassieri C, De Nitto D, Paoluzi P, Vernia P
- 17468** Outcome of endotherapy for pancreas divisum in patients with acute recurrent pancreatitis
Mariani A, Di Leo M, Petrone MC, Arcidiacono PG, Giussani A, Zupparado RA, Cavestro GM, Testoni PA
- 17476** Verification of gene expression profiles for colorectal cancer using 12 internet public microarray datasets
Chang YT, Yao CT, Su SL, Chou YC, Chu CM, Huang CS, Terng HJ, Chou HL, Wetter T, Chen KH, Chang CW, Shih YW, Lai CH
- 17483** Prognostic factors for survival after transarterial chemoembolization combined with microwave ablation for hepatocellular carcinoma
Ni JY, Sun HL, Chen YT, Luo JH, Chen D, Jiang XY, Xu LF
- 17491** Analysis of risk factors for postoperative pancreatic fistula following pancreaticoduodenectomy
Liu QY, Zhang WZ, Xia HT, Leng JJ, Wan T, Liang B, Yang T, Dong JH

CLINICAL TRIALS STUDY

- 17498** Genomic landscape of pancreatic neuroendocrine tumors
Gebauer N, Schmidt-Werthern C, Bernard V, Feller AC, Keck T, Begum N, Rades D, Lehnert H, Brabant G, Thorns C

OBSERVATIONAL STUDY

- 17507** Endoscopic non-technical skills team training: The next step in quality assurance of endoscopy training
Matharoo M, Haycock A, Sevdalis N, Thomas-Gibson S

- 17516** Cytokine production in patients with cirrhosis and *TLR4* polymorphisms
Nieto JC, Sánchez E, Román E, Vidal S, Oliva L, Guarner-Argente C, Poca M, Torras X, Juárez C, Guarner C, Soriano G
- 17525** Clinical epidemiology of ulcerative colitis in Arabs based on the Montréal classification
Alharbi OR, Azzam NA, Almalki AS, Almadi MA, Alswat KA, Sadaf N, Aljebreen AM
- 17532** Plasma cathepsin L: A prognostic marker for pancreatic cancer
Singh N, Das P, Gupta S, Sachdev V, Srivasatava S, Datta Gupta S, Pandey RM, Sahni P, Chauhan SS, Saraya A
- 17541** Significance of downregulation of liver fatty acid-binding protein in hepatocellular carcinoma
Inoue M, Takahashi Y, Fujii T, Kitagawa M, Fukusato T
- 17552** Laterally spreading tumors: Limitations of computed tomography colonography
Togashi K, Utano K, Kijima S, Sato Y, Horie H, Sunada K, Lefor AT, Sugimoto H, Yasuda Y
- 17558** Three-Tesla magnetic resonance elastography for hepatic fibrosis: Comparison with diffusion-weighted imaging and gadoxetic acid-enhanced magnetic resonance imaging
Park HS, Kim YJ, Yu MH, Choe WH, Jung SI, Jeon HJ

PROSPECTIVE STUDY

- 17568** Upper-gastrointestinal bleeding secondary to peptic ulcer disease: Incidence and outcomes
Quan S, Frolkis A, Milne K, Molodecky N, Yang H, Dixon E, Ball CG, Myers RP, Ghosh S, Hilsden R, van Zanten SV, Kaplan GG
- 17578** Introducing an enhanced recovery after surgery program in colorectal surgery: A single center experience
Bona S, Molteni M, Rosati R, Elmore U, Bagnoli P, Monzani R, Caravaca M, Montorsi M
- 17588** Prevalence, histologic and clinical characteristics of heterotopic gastric mucosa in Chinese patients
Fang Y, Chen L, Chen DF, Ren WY, Shen CF, Xu Y, Xia YJ, Li JW, Wang P, Zhang AR, Shao SZ, Yu XN, Peng GY, Fang DC

- SYSTEMATIC REVIEWS**
- 17595 Costs of laparoscopic and open liver and pancreatic resection: A systematic review
Limongelli P, Vitiello C, Belli A, Pai M, Tolone S, del Genio G, Bruscianno L, Docimo G, Habib N, Belli G, Jiao LR, Docimo L
- 17603 Effects of laparoscopic cholecystectomy on lung function: A systematic review
Bablekos GD, Michaelides SA, Analitis A, Charalabopoulos KA
- 17618 Epidemiology of *Helicobacter pylori* infection among the healthy population in Iran and countries of the Eastern Mediterranean Region: A systematic review of prevalence and risk factors
Eshraghian A

- META-ANALYSIS**
- 17626 Meta-analysis of laparoscopic vs open cholecystectomy in elderly patients
Antoniou SA, Antoniou GA, Koch OO, Pointner R, Granderath FA
- 17635 *Helicobacter pylori* infection and atopic diseases: Is there a relationship? A systematic review and meta-analysis.
Lionetti E, Leonardi S, Lanzafame A, Garozzo MT, Filippelli M, Tomarchio S, Ferrara V, Salpietro C, Pulvirenti A, Francavilla R, Catassi C
- 17648 Is concomitant radiotherapy necessary with gemcitabine-based chemotherapy in pancreatic cancer?
Zhang X, Huang HJ, Feng D, Yang DJ, Wang CM, Cai QP

- CASE REPORT**
- 17656 Late onset fulminant Wilson's disease: A case report and review of the literature
Weitzman E, Pappo O, Weiss P, Frydman M, Haviv-Yadid Y, Ben Ari Z
- 17661 Rare combination of familial adenomatous polyposis and gallbladder polyps
Mori Y, Sato N, Matayoshi N, Tamura T, Minagawa N, Shibao K, Higure A, Nakamoto M, Taguchi M, Yamaguchi K
- 17666 Hirschsprung's disease in twin to twin transfusion syndrome: A case report
Park HW, Cho MJ, Kim WY, Kwak BO, Kim MH
- 17670 Emergency laparoscopic partial splenectomy for ruptured spleen: A case report
Cai YQ, Li CL, Zhang H, Wang X, Peng B

- 17674** Focal autoimmune pancreatitis and chronic sclerosing sialadenitis mimicking pancreatic cancer and neck metastasis

Sun L, Zhou Q, Brigstock DR, Yan S, Xiu M, Piao RL, Gao YH, Gao RP

- 17680** Sclerosing cholangitis secondary to bleomycin-iodinated embolization for liver hemangioma

Jin S, Sun XD, Shi XJ, Wang SY, Wang GY

- LETTERS TO THE EDITOR 17686** Reversal of IgM deficiency following a gluten-free diet in seronegative celiac disease

Montenegro L, Piscitelli D, Giorgio F, Covelli C, Fiore MG, Losurdo G, Iannone A, Ierardi E, Di Leo A, Principi M

- 17690** Diagnostically untypable hepatitis C virus variants: It is time to resolve the problem

Afzal MS, Khan MY, Ammar M, Anjum S, Zaidi NSS

APPENDIX I-VI Instructions to authors

ABOUT COVER Editorial Board Member of *World Journal of Gastroenterology*, Daniel E Freedberg, MD, Academic Fellow, Division of Digestive and Liver Diseases, Department of Medicine, Columbia University, College of Physicians and Surgeons, New York, NY 10032, United States

AIMS AND SCOPE *World Journal of Gastroenterology* (*World J Gastroenterol*, *WJG*, print ISSN 1007-9327, online ISSN 2219-2840, DOI: 10.3748) is a peer-reviewed open access journal. *WJG* was established on October 1, 1995. It is published weekly on the 7th, 14th, 21st, and 28th each month. The *WJG* Editorial Board consists of 1362 experts in gastroenterology and hepatology from 67 countries.

The primary task of *WJG* is to rapidly publish high-quality original articles, reviews, and commentaries in the fields of gastroenterology, hepatology, gastrointestinal endoscopy, gastrointestinal surgery, hepatobiliary surgery, gastrointestinal oncology, gastrointestinal radiation oncology, gastrointestinal imaging, gastrointestinal interventional therapy, gastrointestinal infectious diseases, gastrointestinal pharmacology, gastrointestinal pathophysiology, gastrointestinal pathology, evidence-based medicine in gastroenterology, pancreatology, gastrointestinal laboratory medicine, gastrointestinal molecular biology, gastrointestinal immunology, gastrointestinal microbiology, gastrointestinal genetics, gastrointestinal translational medicine, gastrointestinal diagnostics, and gastrointestinal therapeutics. *WJG* is dedicated to become an influential and prestigious journal in gastroenterology and hepatology, to promote the development of above disciplines, and to improve the diagnostic and therapeutic skill and expertise of clinicians.

INDEXING/ABSTRACTING *World Journal of Gastroenterology* is now indexed in Current Contents®/Clinical Medicine, Science Citation Index Expanded (also known as SciSearch®), Journal Citation Reports®, Index Medicus, MEDLINE, PubMed, PubMed Central, Digital Object Identifier, and Directory of Open Access Journals. ISI, Journal Citation Reports®, Gastroenterology and Hepatology, 2013 Impact Factor: 2.433 (36/74); Total Cites: 20957 (6/74); Current Articles: 1205 (1/74); and Eigenfactor® Score: 0.05116 (6/74).

FLYLEAF I-IX Editorial Board

EDITORS FOR THIS ISSUE

Responsible Assistant Editor: *Xiang Li*
Responsible Electronic Editor: *Shuai Ma*
Proofing Editor-in-Chief: *Lian-Sheng Ma*

Responsible Science Editor: *Yuan Qi*
Proofing Editorial Office Director: *Xiu-Xia Song*

NAME OF JOURNAL
World Journal of Gastroenterology

ISSN
ISSN 1007-9327 (print)
ISSN 2219-2840 (online)

LAUNCH DATE
October 1, 1995

FREQUENCY
Weekly

EDITORS-IN-CHIEF
Damian Garcia-Olmo, MD, PhD, Doctor, Professor, Surgeon, Department of Surgery, Universidad Autonoma de Madrid; Department of General Surgery, Fundacion Jimenez Diaz University Hospital, Madrid 28040, Spain

Salah A Naser, PhD, Professor, Burnett School of Biomedical Sciences, College of Medicine, University of Central Florida, Orlando, FL 32816, United States

Stephen C Strom, PhD, Professor, Department of Laboratory Medicine, Division of Pathology, Karolinska Institutet, Stockholm 141-86, Sweden

Andrzej S Tarnawski, MD, PhD, DSc (Med), Professor of Medicine, Chief Gastroenterology, VA Long Beach Health Care System, University of California, Irvine, CA, 5901 E. Seventh Str., Long Beach, CA 90822, United States

EDITORIAL OFFICE
Jin-Lei Wang, Director
Xiu-Xia Song, Vice Director
World Journal of Gastroenterology
Room 903, Building D, Ocean International Center, No. 62 Dongsihuan Zhonglu, Chaoyang District, Beijing 100025, China
Telephone: +86-10-59080039
Fax: +86-10-85381893
E-mail: editorialoffice@wjgnet.com
Help Desk: <http://www.wjgnet.com/esps/helpdesk.aspx>
<http://www.wjgnet.com>

PUBLISHER
Baishideng Publishing Group Inc
8226 Regency Drive,
Pleasanton, CA 94588, USA
Telephone: +1-925-223-8242
Fax: +1-925-223-8243
E-mail: bpgoffice@wjgnet.com
Help Desk: <http://www.wjgnet.com/esps/helpdesk.aspx>

<http://www.wjgnet.com>

PUBLICATION DATE
December 14, 2014

COPYRIGHT
© 2014 Baishideng Publishing Group Inc. Articles published by this Open-Access journal are distributed under the terms of the Creative Commons Attribution Non-commercial License, which permits use, distribution, and reproduction in any medium, provided the original work is properly cited, the use is non commercial and is otherwise in compliance with the license.

SPECIAL STATEMENT
All articles published in journals owned by the Baishideng Publishing Group (BPG) represent the views and opinions of their authors, and not the views, opinions or policies of the BPG, except where otherwise explicitly indicated.

INSTRUCTIONS TO AUTHORS
Full instructions are available online at http://www.wjgnet.com/1007-9327/g_info_20100315215714.htm

ONLINE SUBMISSION
<http://www.wjgnet.com/esps/>

Oesophageal flap valvuloplasty and wrapping suturing prevent gastroesophageal reflux disease in dogs after oesophageal anastomosis

Ji-Gang Dai, Quan-Xing Liu, Xu-Feng Den, Jia-Xin Min

Ji-Gang Dai, Quan-Xing Liu, Xu-Feng Deng, Jia-Xin Min, Department of Thoracic Surgery, Xinqiao Hospital, the Third Military Medical University, Chongqing 400037, China

Author contributions: Dai JG contributed substantially to study conception and design and gave final approval of the version to be published; Liu QX contributed to analysis and interpretation of all the data and drafted the article; Deng XF and Min JX revised the article critically for important intellectual content.

Correspondence to: Jia-Xin Min, MD, Department of Thoracic Surgery, Xinqiao Hospital, the Third Military Medical University, Xinqiao Street Shapingba District, Chongqing 400037, China. daijigang400037@163.com

Telephone: +86-23-68774724 Fax: +86-23-68774724

Received: March 8, 2014 Revised: August 16, 2014

Accepted: September 18, 2014

Published online: December 14, 2014

Abstract

AIM: To examine the efficiency of oesophageal flap valvuloplasty and wrapping suturing technique in decreasing the rate of postoperative gastroesophageal reflux disease in a dog model.

METHODS: We operated on 10 dogs in this study. First, we resected a 5-cm portion of the distal oesophagus and then restored the continuity of the oesophageal and gastric walls by end-to-end anastomosis. A group of five dogs was subjected to the oesophageal flap valvuloplasty and wrapping suturing technique, whereas another group (control) of five dogs was subjected to the stapling technique after oesophagectomy. The symptom of gastroesophageal reflux was recorded by 24-h pH oesophageal monitoring. Endoscopy and barium swallow examination were performed on all dogs. Anastomotic leakage was observed by X-ray imaging, whereas benign anastomotic stricture and mucosal damage were observed by endoscopy.

RESULTS: None of the 10 dogs experienced anasto-

motric leakage after oesophagectomy. Four dogs in the new technology group resumed regular feeding, whereas only two of the dogs in the control group tolerated solid food intake. pH monitoring demonstrated that 25% of the dogs in the experimental group exhibited reflux and that none had mucosal damage consistent with reflux. Conversely, both reflux and mucosal damage were observed in all dogs in the control group.

CONCLUSION: The oesophageal flap valvuloplasty and wrapping suturing technique can improve the postoperative quality of life through the long-term elimination of reflux oesophagitis and decreased stricture formation after primary oesophageal anastomosis.

© 2014 Baishideng Publishing Group Inc. All rights reserved.

Key words: Oesophageal anastomosis; Oesophagectomy; Gastroesophageal reflux

Core tip: This study describes the use of the oesophageal flap valvuloplasty and wrapping suturing technique to decrease the rate of postoperative gastroesophageal reflux disease in a dog model after oesophagectomy. None of the 10 dogs experienced anastomotic leakage after oesophagectomy. Four dogs in the new technology group resumed regular feeding, whereas only two of the dogs in the control group tolerated solid food intake. pH monitoring demonstrated that 25% of the dogs in the experimental group exhibited reflux and that none had mucosal damage consistent with reflux. This technique may provide a good alternative method for preventing gastroesophageal reflux after anastomosis following oesophagogastrrectomy for oesophageal cancer.

Dai JG, Liu QX, Den XF, Min JX. Oesophageal flap valvuloplasty and wrapping suturing prevent gastroesophageal reflux disease in dogs after oesophageal anastomosis. *World J*

Gastroenterol 2014; 20(46): 17434-17438 Available from: URL: <http://www.wjgnet.com/1007-9327/full/v20/i46/17434.htm> DOI: <http://dx.doi.org/10.3748/wjg.v20.i46.17434>

INTRODUCTION

The use of oesophagectomy to treat oesophageal cancer is associated with high morbidity and perioperative complications^[1,2]. Even after undergoing oesophagectomy, cancer patients remain uncured and have a low quality of life^[3]. The status of patients after oesophagectomy correlates with the severity of physical symptoms, which is limited by the refinements in surgical technique^[4]. Approximately 60% to 80% of patients suffer from reflux of duodenal and gastric contents after subtotal oesophagectomy and reconstruction with a gastric conduit^[5].

To avoid these complications, the factors leading to reflux and the measures taken to limit or prevent it have been explored for decades. Reflux after subtotal oesophagectomy is caused by resection or disruption of the normal anti-reflux mechanisms (angle of His and diaphragmatic hiatus). Furthermore, the negative intra-thoracic pressure and the positive intra-abdominal pressure conspire to promote reflux across the anastomosis. This phenomenon could only be overcome by a method that will enhance the lower oesophageal pressure and form anti-reflux flaps in the distal oesophagus.

Many surgical manoeuvres have been previously described to prevent reflux after oesophagectomy^[6]. Intercostal muscle grafts with segmental vessels have been fashioned to act as anti-reflux valves^[7]. However, this method is seldom used at present because of its complex construction and better suitability to low intra-thoracic anastomoses. Many studies have attempted to create valve-like anastomoses by tunnelling the oesophagus through the muscular layer of the stomach^[8,9].

However, the use of these techniques is limited for two reasons. First, they are commonly used for limited resection because a substantial length of the oesophagus is required. In addition, these methods are not easily applicable in standard oncological resections because of the limited availability of the oesophagus^[10].

An anastomosis procedure in which a “globe” is fashioned by invagination of the gastric wall behind the oesophagus has been proven to control reflux. The mechanism of this procedure is similar to that of a posterior fundoplication, in which the gastric fundus is wrapped around the distal oesophagus to act as a valve^[11-13].

The use of the oesophageal flap valvuloplasty and wrapping suturing technique in the oesophagectomy setting has yet to be described. In addition, the effect of this new technique on postoperative gastroesophageal reflux disease (GERD) after primary resection and anastomoses of the distal oesophagus remains unknown. In the current study, we examined the effect of the oesophageal flap valvuloplasty and wrapping suturing technique on postoperative GERD after primary oesophageal anasto-

mosis in a dog model. Our results suggest that the new technique can control reflux after end-to-end anastomosis following oesophagectomy.

MATERIALS AND METHODS

Animals

We used 10 domestic dogs weighing 25.2 ± 2.5 kg for these experiments. The dogs had free access to standard laboratory pellets and water until 12 h before surgery. This study was carried out in strict accordance with the recommendations in the Guide for the Care and Use of Laboratory Animals of the National Institutes of Health. The animal use protocol has been reviewed and approved by the Institutional Animal Care and Use Committee (IA-CUC) of the Third Military Medical University.

Randomisation

A right thoraco-abdominal incision was performed in all experimental animals under general anaesthesia. The thoracic oesophagus was mobilised, and a 5 cm-long segment of the distal oesophagus was transected. In these animals, this segment represents approximately one-third of the total length of the oesophagus. The animals were then assigned randomly to groups A and B. In group B, a primary anastomosis was created between the end of the residual oesophageal and gastric walls using a common stapling technique.

Surgery procedure

In group A, the oesophageal flap valvuloplasty and wrapping suturing technique was performed. We made a longitudinal cut on the distal oesophagus with a length of approximately 2-3 cm, forming two oesophageal flaps. A stoma was simultaneously made in the anterior wall of the stomach, which we named the “sleeve joint” (Figure 1). The site of the “sleeve joint” should be kept approximately 4 cm away from the top of the stomach wall, and the length of the “sleeve joint” should be 2 to 3 mm longer than the oesophageal diameter. Then, a 1 cm-long fold around the oesophageal flaps and remnant oesophagus was hand sutured using a neuromuscular layer of interrupted absorbable monofilament suture in the AA₁ site (Figure 2). In the last step, seromuscular layer suturing was executed between the oesophageal and gastric walls in the BB₁ and CC₁ sites. The BB₁ site was located just above the end of the oesophageal flaps, and the distance between BB₁ and CC₁ should be 2 cm (Figure 3).

Postoperative procedure

Feeding gastrostomy concluded the surgical intervention in all experimental animals. Feeding was resumed *via* the gastrostomy tube for the first postoperative week, and a swallow study with gastrografin (Schering, Germany) was performed at the end of the week to rule out anastomotic leakage. The experimental animals were then granted free access to either blended or solid food, depending on the animals' preference. Six weeks later, fluoroscopy using food impregnated with contrast material (barium

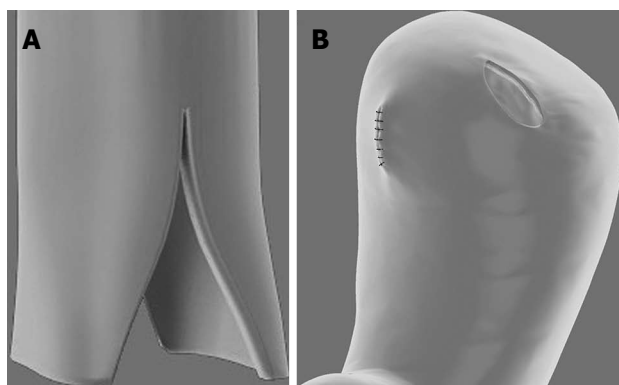


Figure 1 Oesophageal flaps and "sleeve joint". A: A longitudinal cut on the distal oesophageal about 2-3 cm in length; B: A stoma in the anterior wall of the stomach forming a "sleeve joint", which was 2 to 3 mm longer than the oesophageal diameter.



Figure 2 Oesophageal flap valvuloplasty. The seromuscular layer of the interrupted absorbable monofilament suture was used to suture the 1 cm-long fold around the remnant oesophageal flaps in the AA1 site forming modified oesophageal flaps.

sulphate) was performed to evaluate oesophageal motility patterns, and endoscopy was conducted to evaluate the level of mucosal damage^[14]. pH monitoring was performed to demonstrate gastrooesophageal reflux^[15]. The diameters of oesophageal lumen 1.5 cm below and above the anastomosis were evaluated by radiographic studies under standardised conditions for anastomotic circumference assessment. In addition, anastomotic leakage in dogs can also be easily observed by X-ray imaging.

Statistical analysis

The mean and standard error and deviation were calculated. Differences between groups were evaluated by the Student's *t*-test, followed by Tukey's test. Statistical significance was considered at $P < 0.05$.

RESULTS

Postoperative leakage

All animals survived the surgery in good condition. None

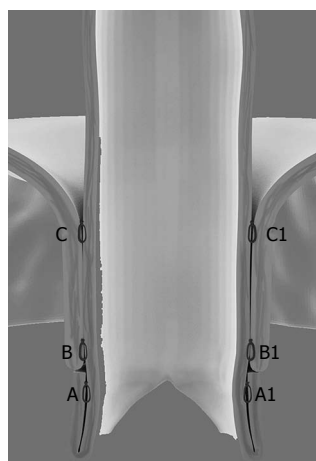


Figure 3 Wrapping suturing of the stomach wall around the oesophagus. The seromuscular layer of the oesophagus and the gastric wall was sutured in the BB1 site and CC1 site. The BB1 site was located just above the end of the oesophageal flaps and the distance between BB1 and CC1 should be 2 cm.

of the two groups exhibited clinical signs of anastomotic leakage. No difference in food tolerance was recorded in the first week when feeding was exclusively performed through gastrostomy. At the end of the first postoperative week, a contrast-swallow meal was accomplished, and radiographic signs of anastomotic leaks were not evident in either group.

Postoperative stricture

After the last examination, the experimental animals were allowed to resume free oral intake. Four dogs (80%) in group A resumed their regular feeding habits, whereas two dogs (40%) in the control group tolerated the ingestion of solid food. Anastomotic stricture was reported in two dogs in group A and four dogs in group B ($P < 0.05$, Table 1).

Postoperative GERD

Endoscope studies performed 6 wk after the operation revealed no mucosal damage in group A. Conversely, mucosal damage was observed in four of the control animals (Table 1). The results of pH monitoring showed that one dog in group A and all dogs in the control group exhibited reflux.

DISCUSSION

Reflux after oesophagectomy is a common problem that may adversely affect the quality of life of patients^[16]. GERD complications, such as oesophagitis, which occurs in 27%-35% of patients, and columnar metaplasia, which includes intestinal (Barrett's) metaplasia, have been observed in the remnant oesophagus after oesophagectomy^[17,18].

Most of these complications cannot be fully treated successfully, which decreases the life quality of patients. Therefore, gastrooesophageal reflux should be seriously monitored as one of the postoperative complications

Table 1 General information of patients in two study groups and incidence of postoperative complications

	Group A	Group B	P value
Weight (kg, mean \pm SD)	24.9 \pm 2.7	25.5 \pm 2.2	-
Sex			-
Female	3	3	
Male	2	2	
Anastomotic leakage	0	0	-
Anastomotic strictures	2	4	-
Reflux	1	5	0.024
Mucosal damage	0	4	0.024

Group A: patients receiving wrapping suturing around the oesophageal flap; Group B: patients receiving only a stapled technique. NS: Not significant.

after oesophagogastrectomy. Simple measures such as excluding as much of the stomach as possible from the abdominal compartment and enhancing gastric emptying by pyloric drainage procedures may help to control reflux. However, most anti-reflux reconstructions are complex or have been used only in a limited resection setting^[7,19,20].

In the 1970s, Butterfield reported the use of fundoplication after palliative resection of the lower oesophagus, and Boyd *et al*^[11] and Butterfield^[13] described 55 patients, of whom 30 had a 5 cm fundoplication fashioned after oesophagogastric anastomosis during resection for oesophageal and proximal gastric cancers.

Fundoplication or wrapping the gastric fundus around the distal oesophagus to act as a valve is a successful method for treating *de novo* gastrooesophageal reflux. However, the extent of resection, particularly of the stomach, is limited by the current standards and the availability of the fundus to form the wrap. Thus, a modified fundoplication could be created. In this study, we reported the efficacy of the oesophageal flap valvuloplasty and wrapping suturing technique in preventing postoperative gastrooesophageal reflux after oesophagogastrectomy. In the present study, anastomoses in patients of groups A and B were performed by hand suture and common stapling, respectively. In group A, no mucosal damage was observed by endoscopy, and only one case of reflux was reported by 24-h pH oesophageal monitoring. In the control group, four dogs had mucosal damage and all dogs exhibited gastrooesophageal reflux.

We propose that wrapping suturing with the oesophageal flap technology is a good alternative for preventing gastrooesophageal reflux after oesophagogastrectomy under the experimental conditions. In this study, this procedure was proven capable of preventing postoperative reflux after primary oesophageal anastomosis. However, the effects of reflux reduction strategies on the quality of life and pathological sequelae of patients must be evaluated in future studies.

COMMENTS

Background

Gastric acid reflux is a common complaint after primary oesophageal anas-

tomosis in oesophageal cancer patients. Traditional hand-sewn and stapled techniques help to prevent gastric acid reflux. Recent studies have proven that fundoplication is effective in curing gastrooesophageal reflux disease (GERD). This study aims to examine the efficiency of the oesophageal flap valvuloplasty and wrapping suturing technique, which is physiologically similar to a partial fundoplication, in decreasing the rate of postoperative GERD in a dog model.

Research frontiers

Many surgical manoeuvres have been previously described to prevent reflux after oesophagectomy. Intercostal muscle grafts with segmental vessels have been fashioned to act as anti-reflux valves. However, this method is seldom used at present because of its complex construction and better suitability to low intra-thoracic anastomoses.

Innovations and breakthroughs

An anastomosis procedure in which a 'globe' is fashioned by invagination of the gastric wall behind the oesophagus has been proven to control reflux. The mechanism of this procedure is similar to that of a posterior fundoplication, in which the gastric fundus is wrapped around the distal oesophagus to act as a valve. The use of the oesophageal flap valvuloplasty and wrapping suturing technique in the oesophagectomy setting has yet to be described. In addition, the effect of this new technique on postoperative GERD after primary resection and anastomoses of the distal oesophagus remains unknown.

Applications

The study results suggest that the oesophageal flap valvuloplasty and wrapping suturing technique is a feasible procedure following oesophagectomy for oesophageal cancer.

Peer review

This is a well-written and scientific description of oesophageal anastomotic techniques in a dog model over a relatively short time frame. The methodology and results are clear and helpful. This paper describes an interesting method of anastomosis after oesophagectomy for squamous cell carcinoma of the thoracic oesophagus. The authors are to be congratulated on their excellent results.

REFERENCES

- 1 Müller JM, Erasmi H, Stelzner M, Zieren U, Pichlmaier H. Surgical therapy of oesophageal carcinoma. *Br J Surg* 1990; 77: 845-857 [PMID: 2203505 DOI: 10.1002/bjs.1800770804]
- 2 Atkins BZ, Shah AS, Hutcheson KA, Mangum JH, Pappas TN, Harpole DH, D'Amico TA. Reducing hospital morbidity and mortality following esophagectomy. *Ann Thorac Surg* 2004; 78: 1170-1176; discussion 1170-1176 [PMID: 15464465]
- 3 Tolone S, Docimo G, Del Genio G, Bruscianno L, Verde I, Gili S, Vitiello C, D'Alessandro A, Casalino G, Lucido F, Leone N, Pirozzi R, Ruggiero R, Docimo L. Long term quality of life after laparoscopic antireflux surgery for the elderly. *BMC Surg* 2013; 13 Suppl 2: S10 [PMID: 24267446 DOI: 10.1186/1471-2482-13-S2-S10]
- 4 Dai JG, Zhang ZY, Min JX, Huang XB, Wang JS. Wrapping of the omental pedicle flap around esophagogastric anastomosis after esophagectomy for esophageal cancer. *Surgery* 2011; 149: 404-410 [PMID: 20850852 DOI: 10.1016/j.surg.2010.08.005]
- 5 Dresner SM, Griffin SM, Wayman J, Bennett MK, Hayes N, Raimes SA. Human model of duodenogastro-oesophageal reflux in the development of Barrett's metaplasia. *Br J Surg* 2003; 90: 1120-1128 [PMID: 12945080 DOI: 10.1002/bjs.4169]
- 6 Yamada E, Shirakawa Y, Yamatsuji T, Sakuma L, Takaoka M, Yamada T, Noma K, Sakurama K, Fujiwara Y, Tanabe S, Nagasaka T, Fujiwara T, Naomoto Y. Jejunal interposition reconstruction with a stomach preserving esophagectomy improves postoperative weight loss and reflux symptoms for esophageal cancer patients. *J Surg Res* 2012; 178: 700-707 [PMID: 22939551 DOI: 10.1016/j.jss.2012.07.057]
- 7 Demos NJ, Kulkarni VA, Port A, Micale J. Control of postresection gastroesophageal reflux: the intercostal pedicle esophagogastric experience of 26 years. *Am Surg* 1993; 59: 137-148 [PMID: 7682794]
- 8 Wooler G. Reconstruction of the cardia and fundus of the stomach. *Thorax* 1956; 11: 275-280 [PMID: 13391833 DOI: 10.1136/thorax.1956.0110275275]

- 10.1136/thx.11.4.275]
- 9 **Watkins DH**, Prevedel A, Harper FR. A method of preventing peptic esophagitis following esophagogastronomy: experimental and clinical study. *J Thorac Surg* 1954; **28**: 367-379, discussion 379-382 [PMID: 13202184]
- 10 **Lortat-Jacob JL**, Maillard JN, Fekete F. A procedure to prevent reflux after esophagogastric resection: experience with 17 patients. *Surgery* 1961; **50**: 600-611 [PMID: 14466730]
- 11 **Boyd AD**, Cukingnan R, Engelman RM, Localio SA, Slatery L, Tice DA, Bardin JA, Spencer FC. Esophagogastronomy. Analysis of 55 cases. *J Thorac Cardiovasc Surg* 1975; **70**: 817-825 [PMID: 1186273]
- 12 **Okada N**, Kuriyama T, Umemoto H, Komatsu T, Tagami Y. Esophageal surgery: a procedure for posterior invagination esophagogastronomy in one-stage without positional change. *Ann Surg* 1974; **179**: 27-34 [PMID: 4206381 DOI: 10.1097/00000658-197401000-00006]
- 13 **Butterfield WC**. Anti-reflux palliative resections for inoperable carcinoma of the esophagogastric junction. *J Thorac Cardiovasc Surg* 1971; **62**: 460-464 [PMID: 4108326]
- 14 **Nishimura K**, Fujita H, Tanaka T, Tanaka Y, Matono S, Murata K, Umeno H, Shirouzu K. Endoscopic classification for reflux pharyngolaryngitis. *Dis Esophagus* 2010; **23**: 20-26 [PMID: 19549209 DOI: 10.1111/j.1442-2050.2009.00994.x]
- 15 **Kleiman DA**, Beninato T, Bosworth BP, Brunaud L, Cieciera-ga T, Crawford CV, Turner BG, Fahey TJ, Zarnegar R. Early referral for esophageal pH monitoring is more cost-effective than prolonged empiric trials of proton-pump inhibitors for suspected gastroesophageal reflux disease. *J Gastrointest Surg* 2014; **18**: 26-33; discussion 33-34 [PMID: 24214090 DOI: 10.1007/s11605-013-2327-x]
- 16 **Rickenbacher N**, Kötter T, Kochen MM, Scherer M, Blozik E. Fundoplication versus medical management of gastroesophageal reflux disease: systematic review and meta-analysis. *Surg Endosc* 2014; **28**: 143-155 [PMID: 24018760 DOI: 10.1007/s00464-013-3140-z]
- 17 **Lindahl H**, Rintala R, Sariola H, Louhimo I. Cervical Barrett's esophagus: a common complication of gastric tube reconstruction. *J Pediatr Surg* 1990; **25**: 446-448 [PMID: 2329463 DOI: 10.1016/0022-3468(90)90391-L]
- 18 **Hamilton SR**, Yardley JH. Regenerative of cardiac type mucosa and acquisition of Barrett mucosa after esophagogastronomy. *Gastroenterology* 1977; **72**: 669-675 [PMID: 838221]
- 19 **Hoppo T**, Badylak SF, Jobe BA. A novel esophageal-preserving approach to treat high-grade dysplasia and superficial adenocarcinoma in the presence of chronic gastroesophageal reflux disease. *World J Surg* 2012; **36**: 2390-2393 [PMID: 22736346 DOI: 10.1007/s00268-012-1698-6]
- 20 **Procter DS**. The 'ink-well' anastomosis in oesophageal reconstruction. *S Afr Med J* 1967; **41**: 187-190 [PMID: 5337489]

P- Reviewer: Chaturvedi P, Vollmers HP **S- Editor:** Yu J
L- Editor: Wang TQ **E- Editor:** Zhang DN





Published by **Baishideng Publishing Group Inc**

8226 Regency Drive, Pleasanton, CA 94588, USA

Telephone: +1-925-223-8242

Fax: +1-925-223-8243

E-mail: bpgoffice@wjgnet.com

Help Desk: <http://www.wjgnet.com/esps/helpdesk.aspx>

<http://www.wjgnet.com>



ISSN 1007-9327

