

Effect of growth hormone, hyperbaric oxygen and combined therapy on the gastric serosa

Gokhan Adas, Mine Adas, Soykan Arikan, Ahu Kemik Sarvan, Akin Savas Toklu, Selva Mert, Gul Barut, Sedat Kamali, Bora Koc, Firat Tural

Gokhan Adas, Bora Koc, Department of Surgery, Bakirkoy Dr. Sadi Konuk Training and Research Hospital, 34147 Istanbul, Turkey

Mine Adas, Department of Endocrinology, Okmeydani Training and Research Hospital, 34384 Istanbul, Turkey

Soykan Arikan, Department of Surgery, Istanbul Training and Research Hospital, 34098 Istanbul, Turkey

Ahu Kemik Sarvan, Department of Biochemistry, Istanbul Faculty of Medicine, 34091 Istanbul, Turkey

Akin Savas Toklu, Selva Mert, Department of Underwater and Hyperbaric Medicine, Istanbul Faculty of Medicine, 34091 Istanbul, Turkey

Gul Barut, Department of Pathology, Haseki Training and Research Hospital, 34096 Istanbul, Turkey

Sedat Kamali, Firat Tural, Department of Surgery, Okmeydani training and Research Hospital, 34384 Istanbul, Turkey

Author contributions: Adas G, Adas M and Arikan S performed the majority of experiments; Koc B, Sarvan AK, Toklu AS and Barut G provided vital reagents and analytical tools and were also involved in editing the manuscript; Kamali S and Tural F designed the study and wrote the manuscript.

Correspondence to: Bora Koc, MD, Department of Surgery, Bakirkoy Dr. Sadi Konuk Training and Research Hospital, 11 Tevfik Saglam Ave, Zuhuratbaba, Bakirkoy, 34147 Istanbul, Turkey. drborakoc@hotmail.com

Telephone: +90-533-4948090 Fax: +90-212-2217777

Received: November 5, 2012 Revised: December 13, 2012

Accepted: January 11, 2013

Published online: May 21, 2013

Abstract

AIM: To investigate the role of growth hormone (GH), hyperbaric oxygen therapy (HBOT) and combined therapy on the intestinal neomucosa formation of the gastric serosa.

METHODS: Forty-eight male Wistar-albino rats, weighing 250-280 g, were used in this study. The rats were divided into four groups ($n = 12$): Group 1, control, gastric serosal patch; Group 2, gastric serosal patch +

GH; Group 3, gastric serosal patch + HBOT; and Group 4, gastric serosal patch + GH + HBOT. Abdominal access was achieved through a midline incision, and after the 1-cm-long defect was created in the jejunum, a 1 cm × 1 cm patch of the gastric corpus was anastomosed to the jejunal defect. Venous blood samples were taken to determine the insulin-like growth factor 1 (IGF-1) and insulin-like growth factor binding protein 3 (IGFBP-3) basal levels. HBOT was performed in Groups 3 and 4. In Groups 2 and 4, human GH was given subcutaneously at a dose of 2 mg per kg/d for 28 d, beginning on the operation day. All animals were sacrificed 60 d after surgery. The jejunal segment and the gastric anastomotic area were excised for histological examination. The inflammatory process, granulation, collagen deposition and fibroblast activity at the neomucosa formation were studied and scored. Additionally, the villus density, villus height, and crypt depth were counted and recorded. The measurements of villus height and crypt depth were calculated with an ocular micrometer. New vessel growth was determined by calculating each new vessel in a 1 mm² area.

RESULTS: In the histological comparison of groups, no significant differences were observed between the control group and Groups 2 and 3 with respect to epithelialization, granulation, fibroblastic activity and the inflammatory process, but significant differences were present between the control group and all others groups (Groups 2-4) with respect to angiogenesis ($P < 0.01$) and collagen deposition ($P < 0.05$, $P < 0.01$). Significant differences between the control group and Group 4 were also observed with respect to epithelialization and fibroblastic activity ($P < 0.01$ and $P < 0.05$, respectively). There were significant differences in villus density in all of groups compared with the control group ($P < 0.05$). Crypt depth was significantly greater in Group 4 than in the control group ($P < 0.05$), but no other groups had deeper crypts. However, villus height was significantly longer in Groups 2 and 4 than in

the control group ($P < 0.05$). The comparison of groups revealed, significant difference between control group and Groups 2 and 4) with respect to the levels of IGF-1 and IGFBP-3 ($P < 0.01$) 3 wk after the operation.

CONCLUSION: HBOT or GH and combined therapy augmented on neomucosal formation. The use of combined therapy produced a synergistic effect on the histological, morphological and functional parameters.

© 2013 Baishideng. All rights reserved.

Key words: Growth hormone; Hyperbaric oxygen; Neomucosa; Short bowel syndrome; Hypoxia

Adas G, Adas M, Arıkan S, Sarvan AK, Toklu AS, Mert S, Barut G, Kamali S, Koc B, Tütal F. Effect of growth hormone, hyperbaric oxygen and combined therapy on the gastric serosa. *World J Gastroenterol* 2013; 19(19): 2904-2912 Available from: URL: <http://www.wjgnet.com/1007-9327/full/v19/i19/2904.htm> DOI: <http://dx.doi.org/10.3748/wjg.v19.i19.2904>

INTRODUCTION

Short bowel syndrome (SBS) is a significant problem in clinical medicine that emerged at the beginning of the last century, when the first resections of the gastrointestinal tract were performed^[1]. SBS a malabsorptive disorder characterized by the loss of intestinal length, occurs when patients have < 200 cm of the post-duodenal small intestine, resulting in inadequate digestion and/or nutrient absorption^[2-5]. Depending on the extent, degree, and location of the intestinal resection, patients may experience severe malabsorption of fluids, electrolytes, and other nutrients. Many become dependent on long-term parenteral nutrition, which has been a life maintenance therapy^[6]. Even in the best hands, this treatment can be associated with nutritional deficiencies, septic complications and life-threatening organ failure^[7-9]. Another important factor is the time allowed for post-enterectomy or in utero bowel loss adaptation, which is the compensatory process in the remnant small intestine that includes mucosal regeneration, villous hypertrophy, bowel dilatation and lengthening, and delayed motility^[10]. Growth hormone (GH), glutamine, and dietary modification have been proposed as a regimen to enhance bowel adaptation^[3,6,7]. GH administration produced a positive nitrogen balance at all levels of energy intake^[4,5,11,12]. Evidence supporting the use of GH in the SBS includes the observation that exogenous GH stimulates structural and functional intestinal adaptation^[13,14].

The treatment consists of surgery to slow intestinal transit or increase the area of absorption. Reconstructive procedures on the remnant bowel and intestinal transplantation are areas of special interest to surgeons working in this field^[4,10,15]. Another potential technique for increasing the intestinal surface area is the growth of new intestinal mucosa, which takes advantage of the regenera-

tive capability of the intestine^[10]. Some researchers made gastric anastomosis and, colonic and abdominal wall flaps between intestinal defects in experimental SBS to expand the mucosal surface. The regenerated intestine develops by lateral ingrowth from the surrounding mucosa and becomes functionally normal intestinal mucosa^[16-19].

In gastrointestinal surgery, if the degree of hypoxia is sufficient to interfere with tissue viability, the tissues become necrosed, resulting in delayed wound healing^[20]. Ischemic wounds heal poorly and become infected. Tissue hypoxia can be reversed using hyperbaric oxygen therapy (HBOT). The effects of HBOT result from increased pressure and hyperoxia. Several studies have shown that increased oxygen tension with HBOT not only prevents the adverse effects of ischemia but also accelerates healing in different types of wounds^[21].

The serosal patch technique is one of the most popular methods. However, in many cases, only short segments of the small intestine can be patched because of the limited serosal surface and anatomical factors. In this experimental study, we used a gastric serosal patch to form neomucosa in ileum defects. Our aim in the present work was to investigate the role of GH, HBOT and combined therapy on the intestinal neomucosa formation of the gastric serosa.

MATERIALS AND METHODS

Animals

Forty-eight male Wistar-albino rats (Istanbul University, Institute of Experimental Medicine and Research, Turkey), weighing 250-280 g, were used in the study. The study was approved by the ethics committee of Istanbul University, Istanbul Medical School. All animals were housed in cages in a room at a constant temperature of 22 ± 2 °C. The rats were fed a standard chow diet and tap water.

Study design

The rats were divided into four groups ($n = 12$): Group 1, control, gastric serosal patch; Group 2, gastric serosal patch + GH; Group 3, gastric serosal patch + HBOT; Group 4, gastric serosal patch + GH + HBOT.

Surgical procedure

After one night of fasting, the animals were anaesthetized with an intramuscular injection of ketamine hydrochloride (50-100 mg per kg of body weight). Abdominal access was achieved through a midline incision, and the jejunum was incised at 1 cm longitudinally. After the 1-cm-long defect was created in the jejunum, a 1 cm \times 1 cm patch of the gastric corpus was anastomosed to the jejunal defect with interrupted 6/0 polypropylene sutures (Figure 1A and B). During the operation, venous blood samples (portal vein) were taken to determine the insulin-like growth factor 1 (IGF-1) and insulin like growth factor binding protein 3 (IGFBP-3) basal levels. After the bleeding control had been performed, 2 cc of 0.9% NaCl was injected into the intraperitoneal area, and the abdo-

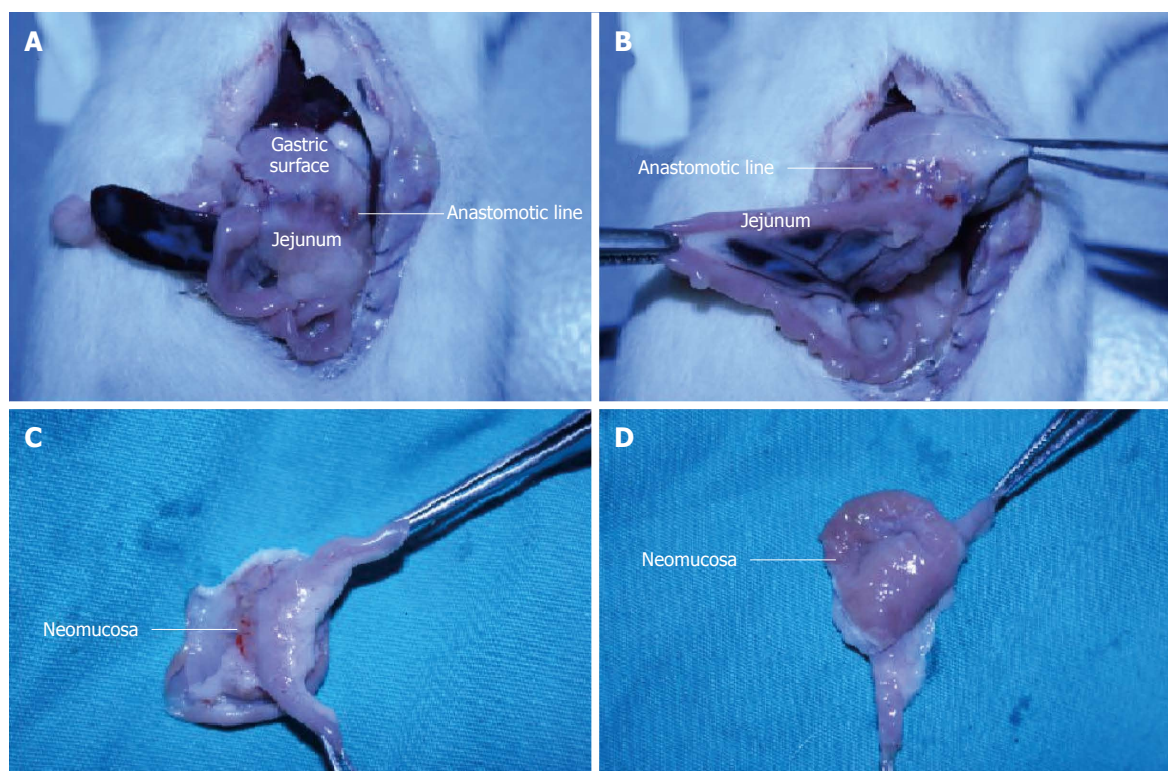


Figure 1 Surgical procedure and histopathological assessment. A, B: Anastomotic line is shown between the gastric surface and jejunum, C: Outer surface of the neomucosa formation is shown with the jejunal segment; D: Inner surface of the neomucosa is shown, and the neomucosa has a typical small intestinal phenotype.

men was closed with 3/0 continuous silk sutures. Twelve hours after the surgery, water was given; twenty-four hours after the surgery, food was given.

Treatment

HBOT was started 12 h after the surgery and completed after 12 d. The HBOT was performed 3 times per day for the first 4 d, 2 times per day for the following 4 d and then once per day for the remaining 4 d. This therapy was applied in the Istanbul Faculty of Medicine, Department of Underwater and Hyperbaric Medicine. The total number of HBOT sessions was 24. The treatments were conducted in a small research chamber (0.4 m³). The chamber was flushed with oxygen for 10 min to vent the air inside before compression, and thus the animals could be pressurized with 100% oxygen. The HBOT sessions consisted of 10 min of compression to 2.5 atmosphere absolute (ATA), 60 min at 2.5 ATA and 10 min of decompression to the surface pressure.

In Groups 2 and 4, human GH was given [Norditropin 4 IU (1.3 mg), Novo Nordisk-Denmark] subcutaneously at a dose of 2 mg per kg/d^[22-25] for 28 d, beginning on the operation day.

Histopathological assessment

All of the rats were sacrificed 60 d after the operation. The anastomosis, including the jejunal segment and the gastric anastomotic area, was excised (Figure 1C and D). To clean the fat tissues, the anastomotic area was washed with distilled water. The edges of the anastomotic area

were determined by following the subject line of the non-absorbable suture. Then, the area was fixed in 10% formalin for approximately 24 h and embedded in a paraffin block. Transverse sections of the embedded tissue, 4 μ m in thickness, were stained with hematoxylin and eosin, and the histological assessment was performed in a blinded manner. The intestinal neomucosa, inflammatory process, granulation and fibroblast activity at the neomucosa formation were studied and scored (from 0 to 3; 0, none; 1, slight; 2, moderate; 3, dense). Masson's trichrome staining was performed to distinguish the cells from the surrounding connective tissue. Three dyes were employed, and solution C was used to stain for collagen. Collagen deposition in the neomucosa was scored according to the density in the tissue (from 0 to 3; 0, none; 1, slight; 2, moderate; 3, dense). Small intestinal epithelial cell lineages (goblet cells and enteroendocrine cells) were identified within the regenerated intestinal mucosa. The goblet cells were stained by the periodic acid-Schiff stain, and mucin was identified with alcian blue staining, pH 2.5. The alcian blue staining at pH 2.5 was used because the acid mucins of the small intestine are primarily sialo mucins^[26]. The enteroendocrine cells were identified by immune histochemical staining.

Additionally, the villus density, villus height, and crypt depth were determined and recorded. The villus density was scored (from 0 to 3). The measurements of villus height and crypt depth were calculated with an ocular micrometer. New vessel growth was determined by calculating each new vessel in a 1 mm² area.

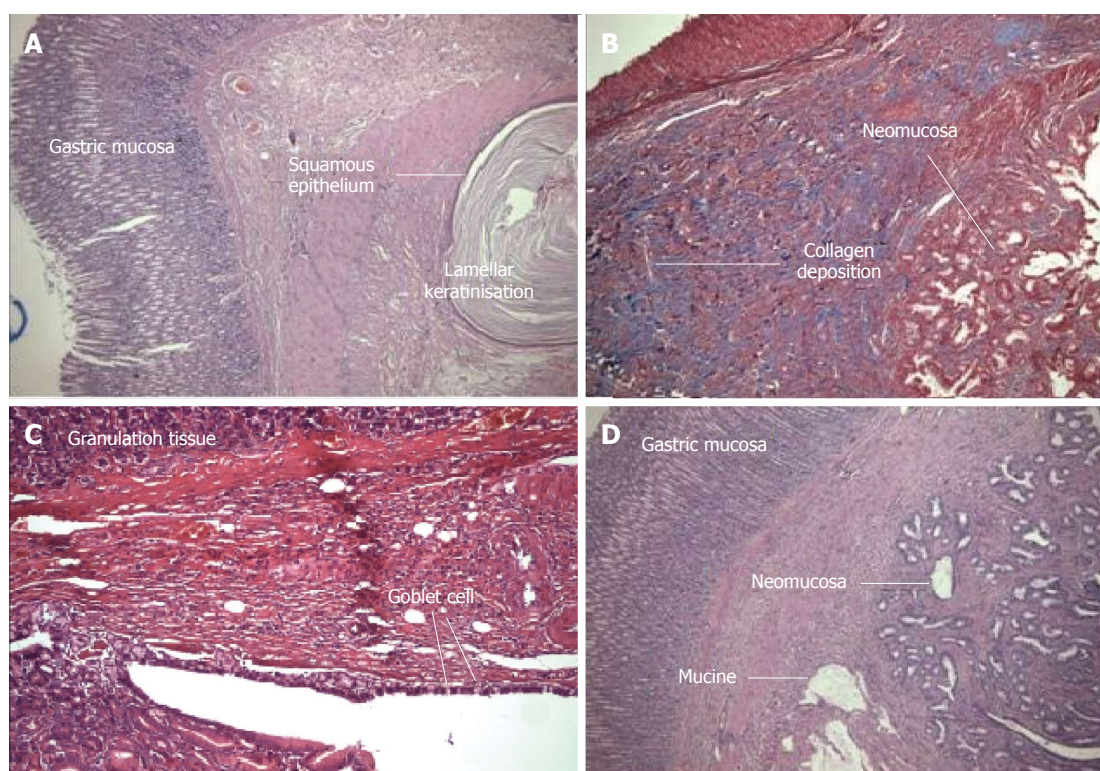


Figure 2 Histological and morphologic evaluation. A: Unexpected neomucosal formation. The gastric corpus mucosa can be seen. The squamous epithelium and lamellar keratinization formed from the anastomosis [Hematoxylin and eosin (HE) $\times 100$] (Group 3); B: Granulation tissue and newly formed neomucosa. The blue area is connective tissue (Masson Trichrome $\times 100$) (Group 4); C: In the gastric mucosa of the large granulation tissue, newly formed goblet cells can be seen (HE $\times 100$) (Group 4); D: The left side shows the gastric mucosa, and the right side shows newly formed neomucosa that contains mucin. The granulation tissue is reduced (HE $\times 100$) (Group 4).

GH assessment

To determine the GH efficacy, we assessed the venous IGF-1 and IGFBP-3 levels at the beginning of treatment and on postoperative day 21. Blood samples were taken from the tail vein of the rats. The analyses were performed in a biochemistry laboratory, at the Cerrahpasa Medical Faculty, University of Istanbul. The levels of IGF-1 and IGFBP-3 were measured by double-antibody, immune-radiometric assays. The IGF-1 antibody was from Immunotech France, and the IGFBP-3 antibody was from Diagnostic Systems Laboratories. The mean intra batch coefficients of variation calculated from the quality-control samples in this study were 5.6% and 2.7% for IGF-1 and IGFBP-3, respectively.

Statistical analysis

The statistical analysis was performed using SPSS 16.0 for Windows. Spearman's test was used for the intergroup correlations. Differences in the histological parameters between the treatment and control groups were analyzed non-parametrically with the Student-*t* test. All data were expressed as the mean \pm SD, and $P < 0.05$ was accepted as significant.

RESULTS

Mortality analysis

Seven rats died in the early phase (in the first week) of

the study. Upon post-mortem examination, we discovered that two had anastomotic leakage and sepsis, two had ileus, and three had pneumothorax.

Histological evaluation

In the histological comparison of the groups, no significant differences were observed between the control group and Groups 2 and 3 with respect to epithelialization, granulation, fibroblastic activity and the inflammatory process ($P > 0.05$), but significant differences were observed between the control group and all other groups (Groups 2-4) with respect to angiogenesis ($P < 0.01$) and collagen deposition ($P < 0.05$, $P < 0.01$) (Figure 2). We also found significant differences between the control group and Group 4 with respect to epithelialization and fibroblastic activity ($P < 0.01$ and $P < 0.05$, respectively). Two histological parameters were significantly different in Groups 2 and 3, and four histological parameters were significantly different in Group 4. These parameters in Group 4 were epithelialization, fibroblastic activity, angiogenesis and collagen deposition. The histological features and results are given in Table 1.

Morphologic evaluation

For the morphological evaluation, we measured the villus density (mm^2), villus height and crypt depth in the neomucosa. By 60 d, the luminal surface of the neomucosa tissue was nearly covered by mucosal epithelium. The

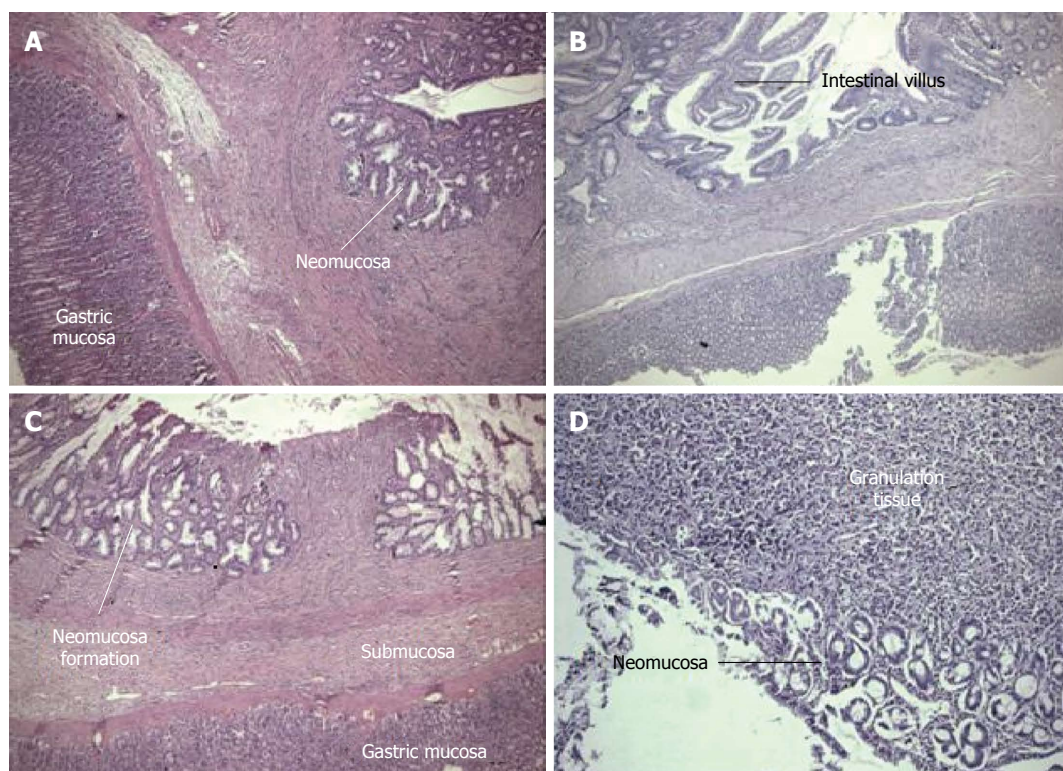


Figure 3 There were significant differences in the villus density in all of the groups compared with the control group. A: Gastric corpus mucosa on the left, newly formed thin neomucosa on the right. The muscularis propria has not yet formed. The granulation tissue regressed [Hematoxylin and eosin (HE) \times 100] (Group 3); B: Neomucosa formation is observed at the bottom of the gastric mucosa (HE \times 125) (Group 4); C: The granulation tissue is in the middle, with newly formed neomucosa on either side. At the bottom, the stomach tissue is visible (HE \times 100) (Group 2); D: The early development of the mucosal layer and granulation tissue (HE \times 125) (Group 1).

Table 1 Histological features of healing, morphological and functional findings and neomucosa formation

	Group 1 (control)	Group 2 (GH)	Group 3 (HBOT)	Group 4 (GH + HBOT)	P^1 (Groups 1-2)	P^2 (Groups 1-3)	P^3 (Groups 1-4)
Histological findings of wound healing							
Epithelialization	0.3	1.3	1.0	1.7	> 0.05	> 0.05	< 0.01
Granulation	2.4	1.4	1.9	1.1	> 0.05	> 0.05	> 0.05
Fibroblast	1.7	1.8	2.0	2.4	> 0.05	> 0.05	< 0.05
Inflammation	1.4	1.1	1.2	1.2	> 0.05	> 0.05	> 0.05
Angiogenesis	4.4	7.5	7.2	8.9	< 0.01	< 0.01	< 0.01
Collagen deposition	0.9	2.2	1.6	2.6	< 0.01	< 0.05	< 0.01
Morphological and functional findings							
Villus density	0.2	1.3	1.1	2.0	< 0.01	< 0.01	< 0.01
Villus height (μ m)	101 (70-109)	135 (98-153)	118 (81-129)	153 (119-181)	< 0.05	> 0.05	< 0.05
Crypt depth (μ m)	83 (74-88)	102 (82-114)	93 (76-101)	120 (101-133)	> 0.05	> 0.05	< 0.05
Goblet cells	0.2	1.4	1.1	2.2	< 0.01	< 0.01	< 0.01
Mucin	0.2	1.7	1.2	2.2	< 0.01	< 0.01	< 0.01

All parameters scored from 0 to 3, angiogenesis counted within 1 mm², villus density, goblet cells, mucin secretion and collagen deposition, scored from 0 to 3. The P^1 value compares Groups 1 and 2, P^2 value compares Groups 1 and 3, and P^3 value compares Groups 1 and 4. All values are expressed as the mean \pm SD. GH: Growth hormone; HBOT: Hyperbaric oxygen therapy.

neomucosa had a typical small intestinal phenotype (Figure 1C and D). There were significant differences in the villus density in all of the groups compared with the control group ($P < 0.05$). The crypt depth was significantly greater in group 4 than in the control group ($P < 0.05$), but no other groups had deeper crypts. However, the villus height was significantly longer in Groups 2 and 4 than in the control group ($P < 0.05$) (Figure 3). The comparison of the morphological characteristics and activation of the

neomucosa between the groups revealed significant differences between the control group and Groups 2-4, with respect to the number of goblet cells and mucin secretion, respectively (both $P < 0.01$) (Figure 2C and D). When we analyzed all of the groups, we obtained the highest significant differences in Group 4. The morphological and functional features in all groups are given in Table 1. We could not make any comparisons between in groups, because the immunohistochemical staining was too weak.

Table 2 The per-operative and 3-wk post-operative venous levels of like growth factor and insulin like growth factor binding protein 3 (nmol/L)

	Group 1 (control)	Group 2 (GH therapy)	Group 4 (GH + HBO therapy)	P^1 (Groups 1-2)	P^2 (Groups 1-4)
Before the surgery					
IGF-1 (nmol/L)	445 (402-482)	421 (405-460)	431 (395-470)	NS	NS
IGFBP-3 (nmol/L)	2250 (2100-2350)	2170 (2000-2300)	2147 (2025-2350)	NS	NS
After the surgery (3 wk)					
IGF-1 (nmol/L)	445 (415-500)	799 (755-875)	813 (775-900)	< 0.05	< 0.05
IGFBP-3 (nmol/L)	2290 (2050-2500)	3300 (3000-3600)	3328 (3000-3650)	< 0.05	< 0.05
P	NS	< 0.05	< 0.05		

The P value compares the per- and post-operative levels within the same group, P^1 value compares the levels between Groups 1 and 2, and P^2 value compares the levels between Groups 1 and 4. All values are expressed as the mean \pm SD. NS: Non-significant; GH: Growth hormone; HBOT: Hyperbaric oxygen therapy; IGF-1: Like growth factor; IGFBP-3: Insulin like growth factor binding protein 3.

GH determination

To determine the effect of the GH, we measured the IGF-1 and IGFBP-3 blood levels in the rats. The comparisons revealed no significant differences between the control group and Groups 2 and 4 in the blood levels of IGF-1 and IGFBP-3 ($P > 0.05$) per-operatively but significant differences between the control group and the other groups (Groups 2 and 4) in the levels of IGF-1 and IGFBP-3 ($P < 0.01$) 3 wk after the operation (Table 2). We also compared the per- and post-operative results within each group. There were significant differences in Groups 2 and 4 ($P < 0.05$, Table 2).

DISCUSSION

The use of serosal patching to grow new intestinal mucosa is a technique for enlarging the intestinal surface. In the literature, different animal models have been utilized to study the growth of intestinal neomucosa in full thickness defects patched with a variety of surfaces, including colonic serosa, abdominal wall, pedicle flaps, and prosthetic material. The serosal patch technique is one of the most popular methods. However, in many cases, only short segments of small intestine can be patched because of the limited serosal surface and anatomical factors^[10,27]. The peritoneal surface has also been utilized to develop epithelial cells. In a rat model, researchers folded the colon to form a seromuscular tunnel and sutured the two ends to the transacted ileum. After 6-12 wk, a pouch in which a single layer of cylindrical epithelium had developed showed evidence of disaccharidase activity^[10]. Erez *et al*^[28] showed that using pigs and rats, one could successfully enlarge the small bowel surface by growing new mucosa on the parietal peritoneum following entero-peritoneal anastomosis. Some important advantages of this technique include the absorption of fluids and electrolytes through the peritoneum, and slowing of the bowel transit time. Bragg *et al*^[29] used colonic serosa for patching, and by 8 wk, the defects were completely covered by neomucosa. In this study, we used the gastric serosal surface as a patch. An extensive literature search did not reveal a previous report of the use of the gastric serosal surface for this technique. We selected the gastric serosal-

surface because the gastric serosa constitutes a large area and because it is anatomically close to the small intestine. Furthermore, the stomach tissue is thick and has a wide network of collateral blood vessels. The fitness for surgery is also influenced by the interaction of the main vein with the easily protected neomucosa structure, the ability of the serosal flap of the small bowel to easily move to the surface, and the quick self-renewal and large surface area of the gastric surface, enabling the surgical operation to be repeated multiple times. In our study, we demonstrated that neomucosal formation occurred two months after the operation. To prevent SBS, it is important that the surface area of the bowel increases rapidly after the surgery to allow the absorption of nutrients to occur. To increase the rate of neomucosal formation, we used GH and HBOT together. To our knowledge, this study is the first to report the use of both these techniques together to encourage neomucosal formation.

There are a number of peptide growth factors, such as IGF-1, or general growth factors, such as GH, that are used as promoting factors for intestinal hyperplasia and adaptation^[1,2,6,14,30,31]. GH is expressed throughout the intestinal epithelium and in the lamina propria, muscularis mucosa, submucosa, and muscularispropria, indicating the potential for direct GH action within the intestine. GH has been shown to directly promote wound healing and growth of the intestine by increasing cell proliferation and collagen deposition^[14]. In neomucosa formation, Thompson investigated the effect of epidermal growth factor (EGF), and octreotide-induced enterocyte apoptosis. Compared with the controls, the EGF group had decreased apoptosis in the crypt and villus^[32]. Circulating GH binds to the GH receptor in the target cells and stimulates the production of IGF-1 in the liver and other target tissues, including the intestine^[14]. Clinical trials of GH treatment have reported significantly increased levels of IGF-1 and IGF-binding protein-3^[14,33-35]. In the GH treatment group, to control the efficacy of the GH, we assessed the level of the IGF-1 and IGF-binding protein at the end of 3 wk. Groups 2 and 4 had significantly higher levels of these hormones at the end of week three compared with the control group ($P < 0.01$).

Oxygen is an essential material for cell metabolism,

and reparative processes, such as cell proliferation and collagen synthesis^[21,36,37], have an especially increased demand for oxygen. Evidence from animal and cell line studies has shown that HBOT, the administration of pure oxygen at pressures greater than 1 ATA, results in increased growth factor production, such as platelet-related growth factor, transforming growth factor- β 1 and vascular endothelial growth factor, and improved wound healing^[38,39]. Hyperoxygenation can also increase collagen production, enabling these rapidly migrating fibroblasts to lay down larger, stronger beds of collagen for the advancing capillary beds, leading to increased granulation tissue formation and enhanced overall healing^[40]. A search of the literature did not reveal any data on HBOT regarding neomucosa formation. In plastic surgery, hyperbaric oxygen has also been used for the management of wounds requiring skin grafting and for the treatment of ischemic flaps^[39]. Additionally, HBOT has been reported to improve the healing of foot ulcers and glucose metabolism in patients with diabetes mellitus^[36]. Angiogenesis is a process in which new blood vessels originate by budding or spouting from pre-existing vessels. HBOT increases angiogenesis, which is an important step in wound healing^[21]. Huddy *et al.*^[41] published the results of giving HBOT to a patient who had suffered from SBS with stomal complications. After the therapy, the patient rapidly made natural adaptations. Neovascularization has been suggested as the mechanism by which HBOT acts. In our study, angiogenesis was significantly different in Group 3, which was given HBOT, compared with the control group ($P < 0.01$). Moreover, collagen (Masson trichrome) was significantly different in Group 3 compared with the control group ($P < 0.05$). This situation is consistent with other data reported in the literature in which HBOT increased the formation of collagen and angiogenesis. The exact mechanism by which HBOT enhances neomucosal formation is not known. There is no direct evidence regarding the mechanism by which HBOT improved neomucosa formation in our study. We thought our use of HBOT directly increased angiogenesis and collagen formation. Furthermore, HBOT may have increased the levels of some growth factors. To further examine the role of HBOT in wound healing, a more in-depth analysis of growth factors is warranted. In our study, we found some adverse side effects of HBOT. Three animals died of pneumo-thorax with the use of HBOT at the beginning. We believe that during the HBOT therapy, the tension pneumo-thorax complication can occur rarely in experimental animals; this condition was a cause of animal deaths in our study. The pneumo-thorax, could be caused directly by the high pressure of the HBOT. Murphy *et al.*^[42] showed that tension pneumo-thorax occurred in 3 patients who underwent HBOT. The GH and HBOT combined treatment had positive effects in all 4 groups.

Studies on the management of SBS have continued worldwide. Early attempts at increasing the surface area by serosal patching with regeneration from the margins of the wound were limited by the marked contraction of

the defects created, and thus only a modest gain in the surface area was achieved. The use of stem cells isolated from the intestine should lead to further progression of intestinal regeneration^[43]. The current techniques for experimental intestinal tissue engineering employ artificial biodegradable scaffolds in a 3-dimensional structure in which organoid units are seeded^[43,44]. Although these results have been reported as experimental studies, they have not been tested in clinical studies yet. Our study is a pilot study and also an experimental study model. We suggest that using this method in appropriate cases is easy. These adaptations will be increased with the combined use of GH and HBOT.

In conclusion, this study demonstrated that intestinal neomucosa can be successfully produced on a gastric serosal surface. In addition, HBOT, GH and their combined therapy augmented neomucosal formation. The combination therapy appears to be more effective. The simultaneous use of both therapies produced a synergistic effect on the histological, morphologic and functional parameters.

COMMENTS

Background

Short bowel syndrome (SBS) is a malabsorptive disorder characterized by loss of intestinal length and occurs when patients have < 200 cm post-duodenal small intestine, resulting in inadequate digestion and/or nutrient. Treatment consists of surgery to slow intestinal transit or to increase the area of absorption. Reconstructive procedures on the remnant bowel and intestinal transplantation are areas of special interest to surgeons working in this field. Another potential technique for increasing the intestinal surface area is the growth of new intestinal mucosa, which takes advantage of the regenerative capability of the intestine. The regenerated intestine develops by lateral in growth from the surrounding mucosa and is functionally to normal intestinal mucosa.

Research frontiers

The serosal patch technique is one of the most popular technique to treat SBS. In this experimental study, authors used gastric serosal patch to form neomucosa in ileum defects. In literature search did not reveal a previous report of the use of the gastric serosal surface for this technique. Moreover in the present work is to investigate the role of growth hormone, hyperbaric oxygen therapy (HBOT) and combined therapy on intestinal neomucosa formation of the gastric serosa. Evidence supporting the use of growth hormone (GH) in the SBS includes the fact that exogenous GH stimulates structural and functional intestinal adaptation. Several studies have shown that increased oxygen tension with HBOT not only prevents adverse effects of ischemia but also accelerates healing in different types of wounds.

Innovations and breakthroughs

In this experimental study, 1 cm-long defect was created in the jejunum, after that a 1 cm \times 1 cm patch of the gastric corpus was anastomosed to the jejunal defect with interrupted 6/0 polypropylene sutures. HBOT was started 12 h after the surgery and completed to 12 d. GH were given subcutaneously at a dose of 2 mg per kg/d for 28 d beginning on the operation day. In order to increase the rate of neomucosal formation, we used the GH and HBOT together. This is the first study to report using these two techniques together to encourage neomucosal formation.

Applications

Their study is a surface expander research and also is an experimental study model. Authors suggest that it is easy to use of this method in the appropriate cases. These adaptation will be increased with the togetherness use of GH and HBOT.

Terminology

SBS, also short gut syndrome or simply short gut, is a malabsorption disorder caused by the surgical removal of the small intestine, or rarely due to the complete dysfunction of a large segment of bowel.

Peer review

This study demonstrated that intestinal neomucosa can be successfully raised on a gastric serosal surface. In addition, HBOT or GH and combined therapy augmented on neomucosal formation. Combination therapies seem to be more effective. Simultaneous use of combined therapy produced synergistic effect on histological, morphologic and functional parameters.

REFERENCES

- Misiakos EP, Macheras A, Kapetanakis T, Liakakos T. Short bowel syndrome: current medical and surgical trends. *J Clin Gastroenterol* 2007; **41**: 5-18 [PMID: 17198059 DOI: 10.1097/01.mcg.0000212617.74337.e9]
- Messing B, Blethen S, Dibaise JK, Matarese LE, Steiger E. Treatment of adult short bowel syndrome with recombinant human growth hormone: a review of clinical studies. *J Clin Gastroenterol* 2006; **40** Suppl 2: S75-S84 [PMID: 16770166 DOI: 10.1097/01.mcg.0000212677.06549.80]
- Byrne TA, Wilmore DW, Iyer K, Dibaise J, Clancy K, Robinson MK, Chang P, Gertner JM, Lautz D. Growth hormone, glutamine, and an optimal diet reduces parenteral nutrition in patients with short bowel syndrome: a prospective, randomized, placebo-controlled, double-blind clinical trial. *Ann Surg* 2005; **242**: 655-661 [PMID: 16244538 DOI: 10.1097/01.sla.0000186479.53295.14]
- Whang EE, Ashley WS, Zinner JM. Small intestine. In: Burin-cardi CF, editor. Schwartz's principles of surgery. New York: McGraw-Hill, 2003: 1017-1054
- Evers MB. Small intestine. In: Townsend MC, editor. Textbook of surgery. Philadelphia: Elsevier Saunders, 2004: 1323-1380
- Matarese LE, Seidner DL, Steiger E. Growth hormone, glutamine, and modified diet for intestinal adaptation. *J Am Diet Assoc* 2004; **104**: 1265-1272 [PMID: 15281045 DOI: 10.1016/j.jada.2004.05.202]
- Li-Ling M. The effectiveness of growth hormone, glutamine and a low-fat diet containing high-carbohydrate on the enhancement of the function of remnant intestine among patients with short bowel syndrome: a review of published trials. *Clin Nutr* 2001; **20**: 199-204 [PMID: 11407865 DOI: 10.1054/clnu.2001.0423]
- Alexander JW, Gianotti L, Pyles T, Carey MA, Babcock GF. Distribution and survival of Escherichia coli translocating from the intestine after thermal injury. *Ann Surg* 1991; **213**: 558-66; discussion 566-7 [PMID: 2039286 DOI: 10.1097/00000658-199106000-00005]
- Buchman AL, Moukarzel A, Ament ME, Gornbein J, Goodson B, Carlson C, Hawkins RA. Serious renal impairment is associated with long-term parenteral nutrition. *JPN J Parenter Enteral Nutr* 1993; **17**: 438-444 [PMID: 8289410 DOI: 10.1177/0148607193017005438]
- Freud E, Eshet R. Insights from animal models for growing intestinal neomucosa with serosal patching--a still untapped technique for the treatment of short bowel syndrome. *Lab Anim* 2001; **35**: 180-187 [PMID: 11315169 DOI: 10.1258/0023677011911453]
- Bengtsson BA, Monson JP. Future directions of growth hormone research. In: John MP, editor. GH Replacement in Adults. London: Oxford PharmaGenesis Ltd, 2000: 202-208
- Weekers F, Van den Berghe G. The catabolic syndrome of prolonged critical illness. In: Abs R, Rasmussen FU, editors. Growth Hormone Deficiency in Adults. Oxford: Oxford PharmaGenesis Ltd, 2004: 299-313
- Shulman DI, Hu CS, Duckett G, Lavalley-Grey M. Effects of short-term growth hormone therapy in rats undergoing 75% small intestinal resection. *J Pediatr Gastroenterol Nutr* 1992; **14**: 3-11 [PMID: 1573509 DOI: 10.1097/00005176-199201000-00002]
- Pereira PM, Bines JE. New growth factor therapies aimed at improving intestinal adaptation in short bowel syndrome. *J Gastroenterol Hepatol* 2006; **21**: 932-940 [PMID: 16724975 DOI: 10.1111/j.1440-1746.2006.04351.x]
- Byrne TA, Persinger RL, Young LS, Ziegler TR, Wilmore DW. A new treatment for patients with short-bowel syndrome. Growth hormone, glutamine, and a modified diet. *Ann Surg* 1995; **222**: 243-254; discussion 254-255 [PMID: 7677455 DOI: 10.1097/00000658-199509000-00003]
- Tait IS, Flint N, Campbell FC, Evans GS. Generation of neomucosa in vivo by transplantation of dissociated rat postnatal small intestinal epithelium. *Differentiation* 1994; **56**: 91-100 [PMID: 8026650 DOI: 10.1007/s002580050025]
- Tait IS, Penny JL, Campbell FC. Does neomucosa induced by small bowel stem cell transplantation have adequate function? *Am J Surg* 1995; **169**: 120-125 [PMID: 7817980 DOI: 10.1016/S0002-9610(99)80119-6]
- Kamei Y, Torii S. A new composite gastric seromuscular and omental pedicle flap. *Ann Surg* 1994; **220**: 97-101 [PMID: 8024365]
- Tait IS, Evans GS, Flint N, Campbell FC. Colonic mucosal replacement by syngeneic small intestinal stem cell transplantation. *Am J Surg* 1994; **167**: 67-72 [PMID: 8311142 DOI: 10.1016/0002-9610(94)90055-8]
- Garcia JG, Criado FJ, Persona MA, Alonso AG. Healing of colonic ischemic anastomoses in the rat: role of superoxide radicals. *Dis Colon Rectum* 1998; **41**: 892-895 [PMID: 9678376]
- Hamzaoglu I, Karahasanoglu T, Aydin S, Sahin DA, Carkman S, Sariyar M, Alemdaroglu K. The effects of hyperbaric oxygen on normal and ischemic colon anastomoses. *Am J Surg* 1998; **176**: 458-461 [PMID: 9874433 DOI: 10.1016/S0002-9610(98)00234-7]
- Christensen H, Oxlund H. Growth hormone increases the collagen deposition rate and breaking strength of left colonic anastomoses in rats. *Surgery* 1994; **116**: 550-556 [PMID: 8079185]
- Christensen H, Chemnitz J, Christensen BC, Oxlund H. Collagen structural organization of healing colonic anastomoses and the effect of growth hormone treatment. *Dis Colon Rectum* 1995; **38**: 1200-1205 [PMID: 7587764 DOI: 10.1007/BF02048337]
- Tei TM, Kissmeyer-Nielsen P, Christensen H, Flyvbjerg A. Growth hormone treatment increases transmural colonic growth in GH-deficient dwarf rats. *Growth Horm IGF Res* 2000; **10**: 85-92 [PMID: 10931746 DOI: 10.1054/ghir.2000.0144]
- Li Y, Bao Y, Jiang T, Tan L, Liu F, Li J. Combination of fibrin glue with growth hormone augments healing of incomplete intestinal anastomoses in a rat model of intra-abdominal sepsis: a dynamic study. *J Invest Surg* 2007; **20**: 301-306 [PMID: 17972218 DOI: 10.1080/08941930701598826]
- Segel HG, Petras ER. Small intestine. In: Sternberg SS, editor. Histology for pathologists. New York: Lippincott-Raven, 1997: 547-569
- Saday C, Mir E. A surgical model to increase the intestinal absorptive surface: intestinal lengthening and growing neomucosa in the same approach. *J Surg Res* 1996; **62**: 184-191 [PMID: 8632637 DOI: 10.1006/jsre.1996.0193]
- Erez I, Rode H, Cywes S. [Enteroperitoneal anastomosis for short bowel syndrome]. *Harefuah* 1992; **123**: 5-8, 72 [PMID: 1505847]
- Bragg LE, Thompson JS. The influence of serosal patch size on the growth of small intestinal neomucosa. *J Surg Res* 1986; **40**: 426-431 [PMID: 3090369 DOI: 10.1016/0022-4804(86)90210-6]
- Zhou X, Li YX, Li N, Li JS. Effect of bowel rehabilitative therapy on structural adaptation of remnant small intestine: animal experiment. *World J Gastroenterol* 2001; **7**: 66-73 [PMID: 11819735]
- Botsios DS, Vasiliadis KD. Factors enhancing intestinal adaptation after bowel compensation. *Dig Dis* 2003; **21**: 228-236 [PMID: 14571096 DOI: 10.1159/000073340]
- Thompson JS. Epidermal growth factor inhibits somatosta-

- tin-induced apoptosis. *J Surg Res* 1999; **81**: 95-100 [PMID: 9889066 DOI: 10.1006/jsre.1998.5468]
- 33 **Seguy D**, Vahedi K, Kapel N, Souberbielle JC, Messing B. Low-dose growth hormone in adult home parenteral nutrition-dependent short bowel syndrome patients: a positive study. *Gastroenterology* 2003; **124**: 293-302 [PMID: 12557135 DOI: 10.1053/gast.2003.50057]
 - 34 **Raschke M**, Rasmussen MH, Govender S, Segal D, Suntum M, Christiansen JS. Effects of growth hormone in patients with tibial fracture: a randomised, double-blind, placebo-controlled clinical trial. *Eur J Endocrinol* 2007; **156**: 341-351 [PMID: 17322494 DOI: 10.1530/EJE-06-0598]
 - 35 **Sevette A**, Smith RC, Aslani A, Kee AJ, Hansen R, Barratt SM, Baxter RC. Does growth hormone allow more efficient nitrogen sparing in postoperative patients requiring parenteral nutrition? A double-blind, placebo-controlled randomised trial. *Clin Nutr* 2005; **24**: 943-955 [PMID: 16083996 DOI: 10.1016/j.clnu.2005.06.006]
 - 36 **Chen SJ**, Yu CT, Cheng YL, Yu SY, Lo HC. Effects of hyperbaric oxygen therapy on circulating interleukin-8, nitric oxide, and insulin-like growth factors in patients with type 2 diabetes mellitus. *Clin Biochem* 2007; **40**: 30-36 [PMID: 16996047 DOI: 10.1016/j.clinbiochem.2006.07.007]
 - 37 **Rachmilewitz D**, Karmeli F, Okon E, Rubenstein I, Better OS. Hyperbaric oxygen: a novel modality to ameliorate experimental colitis. *Gut* 1998; **43**: 512-518 [PMID: 9824579 DOI: 10.1136/gut.43.4.512]
 - 38 **Kang TS**, Gorti GK, Quan SY, Ho M, Koch RJ. Effect of hyperbaric oxygen on the growth factor profile of fibroblasts. *Arch Facial Plast Surg* 2004; **6**: 31-35 [PMID: 14732642 DOI: 10.1001/archfaci.6.1.31]
 - 39 **Friedman HI**, Fitzmaurice M, Lefavre JF, Vecchiolla T, Clarke D. An evidence-based appraisal of the use of hyperbaric oxygen on flaps and grafts. *Plast Reconstr Surg* 2006; **117**: 175S-190S; discussion 191S-192S [PMID: 16799386 DOI: 10.1097/01.prs.0000222555.84962.86]
 - 40 **Aktaş S**, Toklu AS, Olgaç V. Hyperbaric oxygen therapy in adriamycin extravasation: an experimental animal study. *Ann Plast Surg* 2000; **45**: 167-171 [PMID: 10949345 DOI: 10.1097/0000637-200045020-00012]
 - 41 **Huddy JE**, Patel P, Johnson MW, Hamilton-Farrell MR, Ede RJ, Sanderson JD. Hyperbaric oxygen as a treatment for malabsorption in a radiation-damaged short bowel. *Eur J Gastroenterol Hepatol* 2006; **18**: 685-688 [PMID: 16702860 DOI: 10.1097/00042737-200606000-00017]
 - 42 **Murphy DG**, Sloan EP, Hart RG, Narasimhan K, Barreca RS. Tension pneumothorax associated with hyperbaric oxygen therapy. *Am J Emerg Med* 1991; **9**: 176-179 [PMID: 1994949 DOI: 10.1016/0735-6757(91)90186-N]
 - 43 **Thompson JS**, Rochling FA, Weseman RA, Mercer DF. Current management of short bowel syndrome. *Curr Probl Surg* 2012; **49**: 52-115 [PMID: 22244264 DOI: 10.1067/j.cpsurg.2011.10.002]
 - 44 **Sala FG**, Kunisaki SM, Ochoa ER, Vacanti J, Grikscheit TC. Tissue-engineered small intestine and stomach form from autologous tissue in a preclinical large animal model. *J Surg Res* 2009; **156**: 205-212 [PMID: 19665143 DOI: 10.1016/j.jss.2009.03.062]

P- Reviewer Yang Z S- Editor Gou SX
L- Editor A E- Editor Xiong L

