

Acute pancreatitis associated with herpes zoster: Case report and literature review

Zhen Wang, Jun Ye, Yue-Hua Han

Zhen Wang, Cancer Institute, the Second Affiliated Hospital, Zhejiang University School of Medicine, Hangzhou 310009, Zhejiang Province, China

Jun Ye, Yue-Hua Han, Department of Gastroenterology, The Second Affiliated Hospital, Zhejiang University School of Medicine, Hangzhou 310009, Zhejiang Province, China

Author contributions: Wang Z and Ye J contributed equally to this work; Han YH was responsible for the patient's care and follow-up; Ye J reviewed the literature; Wang Z wrote the paper.

Supported by Zhejiang Provincial Natural Science Foundation of China No. LY14H160027, No. LQ12H16009; and the Science and Technology Bureau of Zhejiang Province, No. 2013C33137, No. 2013KYYA093

Correspondence to: Dr. Yue-Hua Han, Department of Gastroenterology, The Second Affiliated Hospital, Zhejiang University School of Medicine, No. 88 Jiefang Road, Hangzhou 310009, Zhejiang Province, China. hanyh_2012@aliyun.com
Telephone: 86-571-87784642 Fax: 86-571-87022776

Received: April 23, 2014 Revised: July 2, 2014

Accepted: July 29, 2014

Published online: December 21, 2014

Abstract

Varicella-zoster virus (VZV) is a type of herpes virus known to cause varicella, mainly in young children, and herpes zoster in adults. Although generally non-lethal, VZV infection can be associated with serious complications, particularly in adults. Acute pancreatitis caused by VZV infection is a rare event, with reports primarily concerning immunocompromised individuals. Here we report a 44-year-old immunocompetent female who developed acute pancreatitis associated with VZV infection. The patient presented with vomiting and persistent pain in the upper quadrant less than one week after diagnosis and treatment for a herpes zoster-related rash with stabbing pain on the abdomen and dorsal right trunk side. A diagnosis of acute pancreatitis was confirmed based on abdominal pain, elevated levels of urine and serum amylase, and findings of peri-pancreatic exudation and effusions by computed tomography and magnetic resonance cholangiopancreatography.

This case highlights that, though rare, acute pancreatitis should be considered in VZV patients who complain of abdominal pain, especially in the epigastric area. Early detection and proper treatment are needed to prevent the condition from deteriorating further and to minimize mortality.

© 2014 Baishideng Publishing Group Inc. All rights reserved.

Key words: Varicella-zoster virus; Herpes zoster; Acute pancreatitis; Immunocompetent adult

Core tip: Acute pancreatitis associated with varicella-zoster viral infection is extremely rare. This report presents the case of a 44-year-old woman who developed acute pancreatitis after the onset of herpes zoster. This is the first case report of acute pancreatitis associated with herpes zoster in an immunocompetent adult.

Wang Z, Ye J, Han YH. Acute pancreatitis associated with herpes zoster: Case report and literature review. *World J Gastroenterol* 2014; 20(47): 18053-18056 Available from: URL: <http://www.wjgnet.com/1007-9327/full/v20/i47/18053.htm> DOI: <http://dx.doi.org/10.3748/wjg.v20.i47.18053>

INTRODUCTION

Decades after a primary infection, latent varicella-zoster virus (VZV) in the dorsal root ganglia of the sensory nerves^[1] can reactivate and spread unilaterally along a dermatome to cause herpes zoster. Diagnosis is usually based on the characteristic varicella rash, which is vesicular, covers a single dermatome, and lasts for three to five days^[2]. The most frequent site of reactivation is the ophthalmic division of the trigeminal nerve, which can involve the eyes and the thoracic nerves^[2,3]. Without a typical rash, herpes zoster can also be confirmed by a virology laboratory or by testing for serum immunoglobulin.

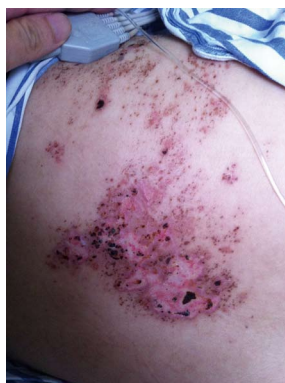

Figure 1 Presentation of characteristic rash. Image showing the rash, which had begun to scab, on the patient's right thoracodorsal area.

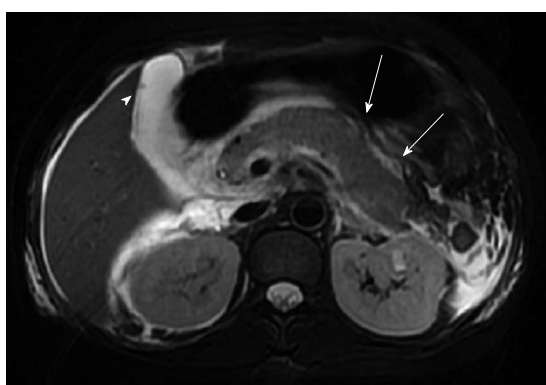


Figure 2 Magnetic resonance cholangiopancreatography. Image showing a punctiform low signal intensity in the gallbladder (arrowhead) and peri-pancreatic exudation (arrows).

lins M and A against VZV and the fluorescent antibody to membrane antigen test^[2,4]. The most common complication is secondary bacterial infection, followed by other serious complications including pneumonia, encephalitis, myelitis, retinitis, hemiparesis, hepatitis and disseminated intravascular coagulopathy^[4], which are more common in immunocompromised patients, such as transplant recipients and patients with acquired immune deficiency syndrome (AIDS). The occurrence of acute pancreatitis in association with VZV infection is very rare and has only been reported in immunocompromised individuals or children. Here, we present the first reported case of acute pancreatitis associated with VZV infection in an immunocompetent adult.

CASE REPORT

A 44-year-old woman experienced a pectoral and dorsal rash with persistent moderate stabbing pain on her right trunk. She was diagnosed with herpes zoster at a local hospital and treated with topical anti-viral drugs, which alleviated the pain. Five days later, the pain became worse after eating a regular meal, appearing in the epigastric area as well as the original location, and accompanied by vomiting. The pain was dull and severe, waking

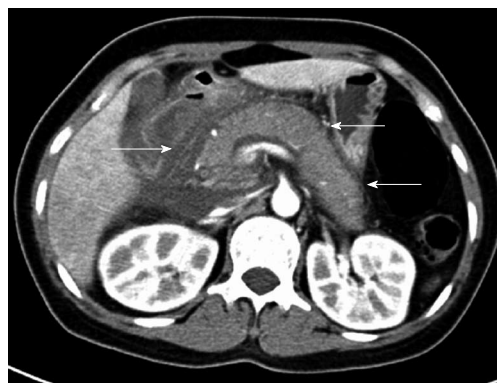


Figure 3 Contrast-enhanced computed tomography. Image showing the swelling of the pancreas with peri-pancreatic exudation and liquid collection (arrows). Grade E acute pancreatitis was diagnosed based on the computed tomography severity index.

her in the night. Over the ensuing 48 h, she vomited approximately 400 mL of gastric content, with no fever or diarrhea present. At this time, the patient was admitted to the emergency department of our hospital. She had no significant past medical history, and denied any alcohol, drug or smoke consumption.

On admission, physical examination showed a pulse rate of 107 beat/min, blood pressure of 113/71 mmHg, body temperature of 36.9 °C, and a respiration rate of 19 breaths/min. Pulse oximetry showed a normal (97%) O₂ saturation. Moderate tenderness in the upper abdomen was observed with no rebound tenderness, a rectal examination was normal, and heart and chest auscultation did not reveal any findings. No jaundice was seen in the skin and sclera. A sheet-like rash was noted in the right thoracodorsal area (Figure 1). Laboratory analysis of blood tests showed elevations of many proteins (Table 1). Magnetic resonance cholangiopancreatography revealed peri-pancreatic exudation and a punctiform low signal intensity in the gallbladder (Figure 2), which was identified as a small cholecystic polyp after additional ultrasound examination. Abdominal contrast-enhanced computed tomography (CT) showed acute pancreatitis (American Roentgen Ray Society severity index of 6^[5], Balthazar stage E^[6]) with swelling of the pancreas, peri-pancreatic exudation and liquid collection (Figure 3). The combined results indicated moderately severe acute pancreatitis according to the revised Atlanta classification^[7] and a Ranson score of 4^[8]. The decreased serum calcium concentration and elevated blood glucose also indicated significant impairment of the pancreas with a poor prognosis.

The patient was fasted upon admission and received passive gastric decompression along with mask oxygen inhalation, fluid resuscitation, and total parenteral nutrition. She was administered octreotide (0.05 mg/h, iv), lansoprazole (30 mg b.i.d.), antibiotics (imipenem and cilastatin sodium, 0.5 g q8h, iv), an analgesic (dezocine) as occasion required, and a subcutaneous insulin injection for hyperglycemia. Vomiting ceased on the first day

Table 1 Laboratory findings of the patient

Testing items	Results	Reference range
WBC, count/mL	12800	4000-10000
HCT, %	43.20	33.5-45.0
serum amylase, IU/L	456	20-80
urine amylase, IU/L	10999	42-321
CRP, mg/L	214.7	< 10
c(Ca ²⁺), mmol/L	1.63	2.08-2.60
Alb, g/L	34.9	35.0-52.0
LDH, U/L	539	140-271
FBG, mmol/L	14.73	3.89-6.11
HbA1C, %	6.20	4.3-6.3
ESR, mm/h	46	< 20
HIV	(-)	(-)
HBsAg	(-)	(-)
HCVAb	(-)	(-)

Alb: Serum albumin; c(Ca²⁺): Serum calcium concentration; CRP: C-reactive protein; ESR: Erythrocyte sedimentation rate; FBG: Fasting blood glucose; HbA1C: Glycosylated hemoglobin; HCT: Hematocrit; HBsAg: Hepatitis B surface antigen; HCVAb: Hepatitis C virus antibody; HIV: Human immunodeficiency virus; LDH: Lactic dehydrogenase; WBC: White blood cell.

of admission, abdominal pain gradually improved, and the rash progressively regressed. The herpes zoster rash was determined by a dermatologist to be in the recovering phase and locally treated with acyclovir ointment. The patient began enteral nutrition on the tenth day after amylase levels decreased to normal and C-reactive protein levels had decreased noticeably. She was permitted a fluid diet after 20 d, and discharged 27 d after admission with normal serum chemistry work-up results. The patient remained well during the one-month follow-up.

DISCUSSION

Acute pancreatitis is an inflammatory disease of the pancreas that may also involve peri-pancreatic tissues. The most common causes of acute pancreatitis in adults are common bile duct stones and alcohol abuse, accounting for 38% and 36% respectively, though other etiologies include toxins, drugs, surgery, and metabolic or autoimmune conditions, as well as infections (from bacteria, mycoplasma, virus and parasites)^[9]. The most common symptom of acute pancreatitis is acute abdominal pain, especially in the epigastrium, as well as gastrointestinal symptoms such as nausea and vomiting. Imaging results and increased concentrations of serum and urine amylase (exceeding three times the normal upper limit) and lipase can be used to directly diagnose 81%-95% of patients^[10].

Of the few cases of herpes zoster-associated acute pancreatitis that have been reported, most involve immunocompromised individuals, such as those in intensive care^[11], AIDS patients^[12], or receiving long-term immunosuppression, such as recipients of stem cell^[13-15], renal^[16,17] or liver^[18] transplants. Three studies reported acute pancreatitis associated with VZV in children with chickenpox^[19-21] and one study reported an elderly patient with herpes zoster suffering from systemic complications including pancreatitis and encephalitis^[22]. The case presented here is the

first report of acute pancreatitis in an immunocompetent adult without comorbidity. Although the mechanism of pancreatitis with herpes zoster is still unknown, VZV may remain latent in posterior sensory nerve roots that contain fibers from both skin and abdominal viscera, including the pancreas^[23]. VZV might injure the pancreatic acinar cell membrane, leading to the leakage of intracellular enzymes, or the cytopathic effect may be mediated through the patient's immune response.

In the present case, the patient's pain initially began as a constant, stabbing pain at the site of the rash on the abdomen. Although the location and the quality of the pain changed several days later, it could have easily been attributed to neuralgia caused by herpes zoster and ignored by mistake. The severity of the nausea and vomiting prompted the patient to seek additional treatment. At this time, the diagnosis of acute pancreatitis was not difficult to confirm, based on serum amylase elevation and CT imaging. Although the etiology is not evident, the influence of VZV on the pancreas gained attention, as common contributors, such as cholelithiasis, alcoholism, common infection and immune deficiency, were excluded. However, the management of viral acute pancreatitis is comparable to acute pancreatitis caused by other etiologies, involving supportive treatment with electrocardiograph monitoring, fluid resuscitation, pain control, and fasting with temporary enteral or total parenteral nutrition.

In conclusion, although rare, this case highlights the need to consider acute pancreatitis as a differential diagnosis for immunocompetent patients with herpes zoster, particularly when the location and quality of the pain changes during the course of the disease. Early detection and proper treatment is needed when acute pancreatitis is suspected.

COMMENTS

Case characteristics

A 44-year-old woman presented with persistent pain in the upper quadrant and vomiting less than one week after the onset of a rash with stabbing pain, characteristic of varicella, on the abdomen and dorsal right trunk.

Clinical diagnosis

Abdominal pain, elevated level of urine and serum amylase concentration, computed tomography findings of peri-pancreatic exudation and effusions.

Differential diagnosis

Common etiologies for acute pancreatitis were excluded based on the absence of alcohol, drug or smoke consumption. Computed tomography and magnetic resonance cholangiopancreatography (MRCP) showed no evidence of gallstones or pancreatic tumor. Laboratory findings did not indicate hypercalcemia or hyperlipidemia.

Laboratory diagnosis

Serum amylase, 456 IU/L; urine amylase, 10999 IU/L; C-reactive protein, 214.7 mg/L; calcium concentration, 1.63 mmol/L; lactic dehydrogenase, 539 U/L.

Imaging diagnosis

MRCP and contrast-enhanced CT showed acute pancreatitis with swelling of the pancreas, peri-pancreatic exudation and liquid collection.

Treatment

The viral acute pancreatitis was managed with supportive treatment, including electrocardiograph monitoring, fluid resuscitation, pain control, and fasting with temporary enteral nutrition. The patient also received octreotide, lansoprazole,

antibiotics, and an analgesic for the herpes zoster, and a subcutaneous insulin injection for hyperglycemia.

Related reports

Reports of acute pancreatitis associated with varicella-zoster virus (VZV) are rare, with only three previous studies involving children with chickenpox, and one study reported involving an elderly patient suffering from systemic herpes zoster-related complications including pancreatitis and encephalitis.

Term explanation

Herpes zoster refers to the reactivation of a latent VZV.

Experiences and lessons

This literature review highlights the need to consider acute pancreatitis in the differential diagnosis when the location and quality of a patient's pain changes during the course of varicella disease.

Peer review

This interesting case is the first report of acute pancreatitis associated with VZV infection in an immunocompetent adult. The authors describe the clinical features, physical examination, laboratory findings, and MRCP and CT imaging in this case. Although the etiology of viral acute pancreatitis is unknown, suspected cases should be confirmed and treated as early as possible.

REFERENCES

- 1 **Lungu O**, Annunziato PW, Gershon A, Staugaitis SM, Josefson D, LaRussa P, Silverstein SJ. Reactivated and latent varicella-zoster virus in human dorsal root ganglia. *Proc Natl Acad Sci USA* 1995; **92**: 10980-10984 [PMID: 7479921 DOI: 10.1073/pnas.92.24.10980]
- 2 **Wareham DW**, Breuer J. Herpes zoster. *BMJ* 2007; **334**: 1211-1215 [PMID: 17556477 DOI: 10.1136/bmj.39206.571042.AE]
- 3 **Mahalingam R**, Wellish M, Wolf W, Dueland AN, Cohrs R, Vafai A, Gilden D. Latent varicella-zoster viral DNA in human trigeminal and thoracic ganglia. *N Engl J Med* 1990; **323**: 627-631 [PMID: 2166914 DOI: 10.1056/NEJM199009063231002]
- 4 **Heininger U**, Seward JF. Varicella. *Lancet* 2006; **368**: 1365-1376 [PMID: 17046469 DOI: 10.1016/S0140-6736(06)69561-5]
- 5 **Mortele KJ**, Wiesner W, Intriore L, Shankar S, Zou KH, Kalantari BN, Perez A, vanSonnenberg E, Ros PR, Banks PA, Silverman SG. A modified CT severity index for evaluating acute pancreatitis: improved correlation with patient outcome. *AJR Am J Roentgenol* 2004; **183**: 1261-1265 [PMID: 15505289 DOI: 10.2214/ajr.183.5.1831261]
- 6 **Balthazar EJ**, Robinson DL, Megibow AJ, Ranson JH. Acute pancreatitis: value of CT in establishing prognosis. *Radiology* 1990; **174**: 331-336 [PMID: 2296641 DOI: 10.1148/radiology.174.2.2296641]
- 7 **Thoeni RF**. The revised Atlanta classification of acute pancreatitis: its importance for the radiologist and its effect on treatment. *Radiology* 2012; **262**: 751-764 [PMID: 22357880 DOI: 10.1148/radiol.11110947]
- 8 **Ranson JH**, Rifkind KM, Roses DF, Fink SD, Eng K, Spencer FC. Prognostic signs and the role of operative management in acute pancreatitis. *Surg Gynecol Obstet* 1974; **139**: 69-81 [PMID: 4834279]
- 9 **Frossard JL**, Steer ML, Pastor CM. Acute pancreatitis. *Lancet* 2008; **371**: 143-152 [PMID: 18191686]
- 10 **Mitchell RM**, Byrne MF, Baillie J. Pancreatitis. *Lancet* 2003; **361**: 1447-1455 [PMID: 12727412]
- 11 **Hagiya H**, Kimura M, Miyamoto T, Otsuka F. Systemic varicella-zoster virus infection in two critically ill patients in an intensive care unit. *Virology* 2013; **10**: 225 [PMID: 23829348 DOI: 10.1186/1743-422X-10-225]
- 12 **Fernández de la Puebla Giménez RA**, Lechuga Varona T, Kindelan Jaquotot JM, Jurado Jiménez R, Delgado Blanco M, de Non-Louis y Persson E. [Acute pancreatitis associated with varicella-zoster virus infection in a patient with acquired immunodeficiency syndrome]. *Med Clin (Barc)* 1992; **98**: 339-341 [PMID: 1583963]
- 13 **Kawakami T**, Mitsui T, Sendo D, Kanazawa C, Maeda S, Katsuura M, Shimizu Y, Yokoyama S. [Acute pancreatitis following hematopoietic stem cell transplantation: prevalence and cause of pancreatic amylasemia]. *Rinsho Ketsueki* 2002; **43**: 176-182 [PMID: 11979749]
- 14 **Ladrière M**, Bibes B, Rabaud C, Delaby P, May T, Canton P. [Varicella zoster virus infection after bone marrow transplant. Unusual presentation and importance of prevention]. *Presse Med* 2001; **30**: 1151-1154 [PMID: 11505833]
- 15 **Remmerswaal RG**, de Vries AC, Ramsoekh D, van Buuren HR. Varicella zoster-associated gastric ulcers, hepatitis and pancreatitis in an immunocompromised patient. *Endoscopy* 2012; **44** Suppl 2 UCTN: E140 [PMID: 22619038 DOI: 10.1055/s-0030-1256934]
- 16 **Cho MH**, Hong EH, Lee HS, Ko CW. Recurrent pancreatitis after renal transplantation in a child. *Pediatr Transplant* 2008; **12**: 593-596 [PMID: 18397214 DOI: 10.1111/j.1399-3046.2008.00922.x]
- 17 **Manrique J**, Rossich E, Hernández Sierra A. [Multiple complications after renal transplantation]. *Nefrologia* 2004; **24** Suppl 3: 26-29 [PMID: 15219064]
- 18 **Coelho JC**, Wiederkkehr JC, Campos AC, Zeni Neto C, Oliva V. [Acute pancreatitis caused by varicella-zoster virus after liver transplantation]. *J Chir (Paris)* 1994; **131**: 96-98 [PMID: 8207103]
- 19 **Torre JA**, Martin JJ, Garcia CB, Polo ER. Varicella infection as a cause of acute pancreatitis in an immunocompetent child. *Pediatr Infect Dis J* 2000; **19**: 1218-1219 [PMID: 11144392 DOI: 10.1097/00006454-200012000-00025]
- 20 **Franco J**, Fernandes R, Oliveira M, Alves AD, Braga M, Soares I, Calhau P. Acute pancreatitis associated with varicella infection in an immunocompetent child. *J Paediatr Child Health* 2009; **45**: 547-548 [PMID: 19702601 DOI: 10.1111/j.1440-1754.2009.01557.x]
- 21 **Kumar S**, Jain AP, Pandit AK. Acute pancreatitis: rare complication of chicken pox in an immunocompetent host. *Saudi J Gastroenterol* 2007; **13**: 138-140 [PMID: 19858632]
- 22 **Nakane S**, Honda H, Hamasaki S, Shirabe S, Nakamura T. [A case of herpes zoster encephalitis with Ramsay-Hunt syndrome, herpes zoster generalisatus and acute pancreatitis]. *No To Shinkei* 2000; **52**: 43-47 [PMID: 10689690]
- 23 **Stratman E**. Visceral zoster as the presenting feature of disseminated herpes zoster. *J Am Acad Dermatol* 2002; **46**: 771-774 [PMID: 12004322 DOI: 10.1067/mjd.2002.119091]

P- Reviewer: Bai DS, Karatapanis S, RanieriG, Zhou GX, Zhu ZH

S- Editor: Qi Y **L- Editor:** A **E- Editor:** Liu XM





Published by **Baishideng Publishing Group Inc**

8226 Regency Drive, Pleasanton, CA 94588, USA

Telephone: +1-925-223-8242

Fax: +1-925-223-8243

E-mail: bpgoffice@wjgnet.com

Help Desk: <http://www.wjgnet.com/esps/helpdesk.aspx>

<http://www.wjgnet.com>



ISSN 1007-9327

