

Role of preoperative tracheobronchoscopy in newborns with esophageal atresia: A review

Filippo Parolini, Giovanni Boroni, Stefania Stefini, Cristina Agapiti, Tullia Bazzana, Daniele Alberti

Filippo Parolini, Giovanni Boroni, Daniele Alberti, Department of Pediatric Surgery, Azienda Ospedaliera Spedali Civili, 25123 Brescia, Italy

Stefania Stefini, Tullia Bazzana, Department of Pediatric Otorhinolaryngology, Azienda Ospedaliera Spedali Civili, 25123 Brescia, Italy

Cristina Agapiti, Department of Pediatric Anesthesiology and Intensive Care Unit, Azienda Ospedaliera Spedali Civili, 25123 Brescia, Italy

Daniele Alberti, University of Brescia, 25123 Brescia, Italy

Author contributions: Parolini F conceptualized and designed the study, designed the data collection instruments, drafted the initial manuscript, reviewed and revised the manuscript and approved the final manuscript as submitted; Boroni G designed the data collection instruments, drafted, reviewed and revised the manuscript and approved the final manuscript as submitted; Stefani S designed the data collection instruments, drafted, reviewed and revised the manuscript and approved the final manuscript as submitted; Agapiti C designed the data collection instruments, drafted, reviewed and revised the manuscript and approved the final manuscript as submitted; Bazzana T coordinated and supervised data collection, critically reviewed the manuscript and approved the final manuscript as submitted; Alberti D conceptualized and designed the study, critically reviewed the manuscript and approved the final manuscript as submitted.

Correspondence to: Filippo Parolini, MD, Department of Paediatric Surgery, Azienda Ospedaliera Spedali Civili, Piazzale Spedali Civili 1, 25123 Brescia, Italy. parfil@hotmail.it

Telephone: +39-03-03996201 Fax: +39-03-03996154

Received: April 30, 2014 Revised: August 19, 2014

Accepted: September 6, 2014

Published online: October 16, 2014

Abstract

Preoperative tracheobronchoscopy (TBS) in the diagnostic assessment of newborns affected by esophageal atresia (EA) was described in 1981. Nevertheless, the value of the procedure is actually much debated; only a few studies have clearly explored the advantages of TBS and this procedure is not yet routinely included in

the diagnostic and therapeutic assessment in many international pediatric surgery settings. Routine preoperative TBS is a safe procedure that enables the accurate examination of the tracheobronchial tree, the visualization of tracheoesophageal fistula and the diagnosis of tracheomalacia or associated respiratory anomalies. When a distal fistula is found, its occlusion with a Fogarty balloon catheter improves mechanical ventilation and facilitates surgical repair. This review provides a detailed overview on the use of TBS in newborns with EA, focusing on technical aspects, anesthesiological management, indications and limits. The benefits and risks of the procedure are also compared with alternative diagnostic tools, such as an esophageal contrast study, computed tomography scan and ultrasound.

© 2014 Baishideng Publishing Group Inc. All rights reserved.

Key words: Computed tomography scan; Esophageal atresia; Newborns; Tracheobronchoscopy; Tracheoesophageal fistula; Tracheomalacia

Core tip: Despite preliminary tracheobronchoscopy (TBS) in the management of newborns affected by esophageal atresia (EA) being described in 1981, only a few studies have clearly explored the advantages of TBS in the subsequent years and this procedure is still not routinely part of the diagnostic and surgical assessment in many international pediatric surgery centers. This review provides a detailed overview on the use of TBS in newborns with EA, focusing on technical and anesthesiological aspects, benefits and risks of this procedure. TBS is also compared with alternative diagnostic tools, such as an esophageal contrast study, computed tomography scan and ultrasound.

Parolini F, Boroni G, Stefani S, Agapiti C, Bazzana T, Alberti D. Role of preoperative tracheobronchoscopy in newborns with esophageal atresia: A review. *World J Gastrointest Endosc* 2014; 6(10): 482-487 Available from: URL: <http://www.wjgnet.com>

INTRODUCTION

More than thirty years ago in 1981, Benjamin first highlighted the importance of preliminary tracheobronchoscopy (TBS) in the management of 152 newborns affected by esophageal atresia (EA), enabling an accurate examination of the tracheobronchial tree and the diagnosis of tracheomalacia or associated upper respiratory anomalies^[1]. Nevertheless, in subsequent years, only a few studies clearly explored the advantages of TBS in these patients and this procedure is not yet routinely included in the diagnostic and surgical assessment in many pediatric surgery centers all over the world^[2,3]. This review provides a detailed overview on the use of TBS in newborns with EA, focusing on technical and anesthesiological aspects and comparing benefits and risks of the procedure with alternative diagnostic tools.

BACKGROUND

Multicenter studies on diagnostic assessment and operative management of newborns with EA are lacking and only scant data on the use of TBS are available (Table 1). Lal *et al*^[4] reported an online-based survey sent to all members of the International Pediatric Endosurgery Group (IPEG) in 2012. The survey was completed by 170 surgeons from 31 countries and only 60% of them routinely performed tracheoscopy before surgical repair of EA^[4]. A lower rate of use (43%) was found by Zani *et al*^[5] with a survey completed by 178 delegates from 45 countries who attended the European Pediatric Surgeons Association (EUPSA) and British Association of Pediatric Surgeons (BAPS) Joint Congress in Rome in 2012^[5]. The Italian retrospective and prospective national register of EA compared the data of the 53 participating centers and the use of TBS stood at 40.5% (Pini Prato, personal communication 2013), while only 21.5% of the 38 centers of the French National Register performed TBS^[3]. None of these studies mentioned which type of tracheoscope, rigid or flexible, was used, nor technical details of the procedure. In a British and Irish prospective cohort study on 151 children affected by EA, no data were reported in regards to the use of tracheoscopy^[6]. Evidence suggests that TBS is still far from being a common practice in many international pediatric surgery centers. Possible explanations are the lack in many settings of adequate expertise in neonatal airways endoscopy and the availability of alternative diagnostic tools.

THE IMPORTANCE OF TBS

Overview on EA

Preoperative TBS has proven to be an useful diagnostic tool in newborns with EA^[7,8]. This procedure helps to

define the anatomy of the respiratory tree, confirms the presence of a proximal and/or distal tracheoesophageal fistula (TEF), the site of entry and location. The value of routine TBS is much debated because the incidence of the combination of a proximal and distal fistula has been historically reported in less than 1% of cases. Nevertheless, there is increasing evidence of a higher prevalence of double TEF^[8]. Two studies also reported that the routine use of TBS led to detection of a much higher relative incidence of proximal fistula, up to 5.69%. This finding suggests that the lower rate of EA with proximal TEF reported in the literature when TBS is not performed is probably due to a lack of accuracy in the diagnosis^[8,9]. The distance from the entrance of the distal fistula to the carina provides a clue as to the gap between the esophageal pouches as the location of the upper one could be suspected by observing an external compression of the pars membranacea. Water-soluble contrast inflated in a Fogarty catheter balloon positioned into the fistula at its entrance into the trachea provides a better assessment of the distance between the fistula and upper esophageal pouch and allows easier identification during surgery of a distal esophageal pouch. TBS also allows preoperative detection of unusual variants of AE, such as double or triple TEF fistula^[10], and if gross changes or deviation of the vascularization of the subepithelium are found, the suspicion of an hidden TEF should be raised.

Diagnosis of associated anomalies

Associated tracheobronchial anomalies are present in nearly half of newborns with EA^[9,11], including ectopic right upper bronchus, laryngotracheoesophageal cleft, tracheal stenosis, tracheobronchial vascular compression and laryngomalacia. The presence of an otorhinolaryngologist with expertise in neonatal settings is strongly recommended during the procedure in order to ensure early detection of associated anomalies of the respiratory tree as they can result in a significant perioperative and postoperative morbidity, such as difficulty in ventilation, failed extubation and atelectasis if their presence is unexpected^[12]. Congenital vocal fold paresis/paralysis in particular, although uncommon, should be ruled out prior to surgical repair as it could lead to multiple failures in extubation^[13]. Kosloke *et al*^[14] reported that preoperative endoscopic findings influenced the operative technique or management in 24 of 42 newborns (57%), as in the case of an unexpected cervical TEF fistula which was repaired through a cervical approach without thoracotomy^[14]. Bronchotracheomalacia can be clinically significant in 10% to 20% of children with EA, although it has been reported to be present in postmortem pathological specimens in nearly 75% of patients with EA^[15]. A definitive diagnosis of tracheomalacia can be made by TBS with the child spontaneously breathing by detecting the typical triad of anteroposterior narrowing of the tracheal lumen, weakening of the semicircular-shaped cartilages and forward ballooning of the widened posterior membranous tracheal wall^[11]. Limited to dynamic evaluation of the

Table 1 Review of the use of tracheobronchoscopy

Ref.	Type of study	Use of TBS (prevalence)	Setting
Lal <i>et al</i> ^[4]	Survey	60%	International Pediatric Endosurgery Group, Online-based Survey, 170 Pediatric Surgeons, 2012
Zani <i>et al</i> ^[5]	Survey	43%	European Pediatric Surgeons Association and British Association of Pediatric Surgeons Survey, 178 Pediatric Surgeons, 2012
Sfeir <i>et al</i> ^[3]	Prospective register	21.50%	French Reference Center for EA, 38 centers, 307 patients, 2008-2009
Burge <i>et al</i> ^[6]	Prospective cohort	-	Prospective Multicentric Cohort study, 151 patients, 2008-2009
Pini Prato (personal communication)	Prospective and Retrospective register	40.50%	Italian Group of Study on EA, 53 centers, 150 patients, 2011-2012

TBS: Tracheobronchoscopy; EA: Esophageal atresia.

airways, the flexible scope provides the best assessment for conditions such as epiglottic collapse, laryngomalacia, vocal cord paralysis, tracheobronchomalacia^[16,17]. Nevertheless, Dodge-Khatami *et al*^[18] reported that in 17 of the 20 newborns with an AE who developed a clinically-evident tracheomalacia, the pre-operative bronchoscopy was negative. Furthermore, according to Kosloske *et al*^[14], TBS can accurately predict the position of the aortic arch by observing the side of dominant pulsation and it could change the side of the thoracotomy.

Complications

The duration of the procedure is short and the oxygen desaturation could be corrected by a facemask. Complications of both flexible and rigid bronchoscopy are related to anesthesia, ventilation and equipment use, generally occurring in less than 5% of cases. Minor complications include epistaxis, airway bleeding, cough and transient laryngospasm. Major complications include apnea, bradycardia and important oxygen desaturation with bronchospasm^[16]. Spread of infections and mortality are extremely rare^[16]. Flexible bronchoscopes are associated with problems of mechanical ventilation, which often poses a time limit of 30-45 s on this procedure^[19,20]. Should ventilation become difficult, the tracheoscope may be removed and the ventilation can continue through the endoscope sheath. Ianolli *et al*^[21] reported a case of pneumothorax during flexible TBS in a neonate with EA. Deanovic *et al*^[22] reported two cases of accidental extubations during intermittent positive pressure ventilation (IPPV) and fiber optic tracheoscopy assisted repair of TEF (TARTEF) in 47 newborns, in whom the tracheoscope passed through the lumen of the tracheal tube and facilitated the identification of the TEF during surgery.

Contraindications and limits

No absolute contraindications to TBS are reported in newborns. Relative contraindications include pulmonary hypertension and uncorrected bleeding diathesis^[16] but these conditions are quite uncommon in newborns with EA. Special attention should be paid to extremely low birth weight (ELBW) premature neonates as the narrow larynx and trachea do not allow the introduction of the even ultra slim 1.9 or 2.2 mm diameter flexible fiberscope

without working channel. It is assumed that there must be at least a 2 mm difference between the size of the endoscope and the diameter of the larynx^[16].

ALTERNATIVE DIAGNOSTIC TOOLS

Prone esophagogram

The need for contrast prone esophagogram is actually debated^[9,19]. Under carefully controlled fluorography, water-soluble contrast can visualize the position of the dilated upper esophageal pouch and may detect a proximal TEF. However, this procedure requires a high degree of pediatric radiology expertise, involves radiation hazards and may be associated with complications, including aspiration pneumonia^[8,19]. Mortality during a contrast study in newborns is extremely rare but reported^[23]. Moreover, the esophagogram could give false negative results when the fistula is occluded by mucus or false positive results when the contrast identifies the tracheobronchial tree which is more likely to be aspiration through the larynx rather than through a proximal TEF^[8,23]. We previously reported a statistically significant better accuracy in the diagnosis of proximal TEF using TBS rather than an esophagogram^[8].

Ultrasound scan

Mediastinal sonography has been proposed to delineate the tracheoesophageal anatomy with promising results. Su *et al*^[24] demonstrated no statistically significant difference in the distance between the two esophageal pouches as assessed by ultrasound scan (US) and surgery in 36 newborns. In a study performed by Gassner *et al*^[25], a small volume of saline solution was instilled into the blind upper esophageal pouch and an ultrasound scan was performed. The examination detected two proximal fistulas in 16 patients and the fistula was located sonographically by detecting moving air bubbles in two newborns with isolated TEF^[25]. Ultrasound scan with Doppler evaluation also identified the position of the aortic arch as well as associated malformations^[25]. Increasing evidence suggests that an ultrasound scan is a useful noninvasive tool for the diagnostic assessment of newborns with EA and plays a crucial role in planning the surgical strategy. Nevertheless, this procedure is operator dependent and needs to be validated on a larger series of patients^[9].

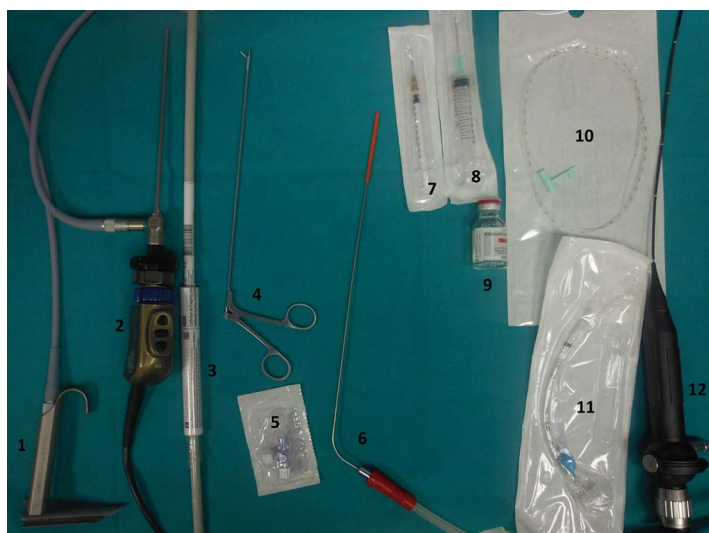


Figure 1 Tracheobronchoscopy instrumentation. 1: Open-sided laryngoscope with proximal prismatic lighting; 2: 2.7 mm neonatal rigid bronchoscope; 3: Fogarty catheter (size 3-4); 4: Bronchoscopy forceps; 5: Three-way stopcock; 6: Tracheoscope suction tube; 7: Insulin syringe (to inflate Fogarty catheter); 8: 10 mL syringe (to aspirate the contrast medium); 9: Water-soluble mean of contrast; 10: Nose gastric-tube 4-6 Fr; 11: Endotracheal tube; 12: Neonatal flexible fiberoptic bronchoscope.

Computed tomography

Computed tomography (CT) and three-dimensional imaging of the tracheobronchial system are well established in adults but experience with pediatric patients is limited. Su *et al*^[26] found no differences in the distance between the two esophageal pouches as measured by CT scan and at surgery and the same results were achieved by Wen *et al*^[27] by utilizing multidetector-row computed tomography (MDCT) in reconstruction of 3D volume rendering. Mahalik *et al*^[28] found that in 20% of newborns with EA, the TEF fistula could not be recognized on a preoperative 3D CT scan, while Fitoz *et al*^[29] reported that shaded surface display (SSD) and virtual bronchoscopy reconstruction techniques can satisfactorily show distal fistulae. A recent review of the 8 available studies on the topic suggests that the safety of CT scan techniques is questionable due to limited facilities, problems regarding neonatal transportation to the radiology department and the need for sedation. Moreover, although a modern CT gives low grade exposure, this examination is still associated with radiation hazards^[30]. Mahalik showed a risk of 1.79 radiation induced cancer per 10000 newborns^[28]. The routine use of preoperative CT scans in newborns with EA is controversial as the limited information acquired that may help to change the surgical plan can be easily obtained by TBS or intraoperatively.

Magnetic resonance imaging

The experience with MRI in newborns affected by EA is extremely limited^[9]. Cantinotti *et al*^[31] consider this method to be an important diagnostic tool in identifying anomalies of the aortic arch and associated cardiac anomalies. Nevertheless, the advantages of the visualization of tracheobronchial and esophageal system have not been studied yet and the need for general anesthesia makes magnetic resonance imaging (MRI) a procedure only for selected cases.

CONCLUSION

Routine preoperative TBS with a rigid tracheoscope has

proven to be most useful in the diagnostic and therapeutic assessment of newborns affected by esophageal atresia as this procedure enables an anatomical definition of the anomaly better than other diagnostic tools. The presence of an otorhinolaryngologist with expertise in neonatal settings is strongly recommended during the procedure to allow early detection of associated anomalies of the respiratory tree which can result in a significant perioperative and postoperative morbidity if not detected. When the distal TEF is cannulated by a Fogarty catheter, TBS may facilitate the surgical repair and improve the mechanical ventilation. Although TBS is not a routinely part of the management in many international centers, increasing evidence suggests that this procedure should be strongly recommended in the management of neonates affected by esophageal atresia.

TBS should performed in the operation room just before surgical repair^[7,8]. Instrumentation requested is illustrated in Figure 1. The presence of an otorhinolaryngologist with expertise in a neonatal setting is strongly recommended and close communication with the anesthesiological and surgical team is essential to perform a safe TBS^[2]. Electrocardiography and peripheral oxygen saturation must be obtained. Particular attention should be paid to any abnormality of the neck or spine that might make the insertion of the endoscope difficult^[11-32]. After inhalatory induction with halogenated ether (sevoflurane), the child is maintained in spontaneous ventilation and 100% oxygenation is achieved with a facemask. During laryngoscopy, a local anesthetic such as 0.5%-2% lidocaine should be applied to the vocal cords and larynx. Lidocaine may be instilled directly, sprayed or nebulized and the total dose should not exceed 5-7 mg/kg^[16]. Insufficient topical anesthesia could result in pain, cough, laryngospasm or bronchospasm, usually due to vagal stimulation. We concur with the recommendation^[11] of inserting a nasopharyngeal tube to provide oxygen and sevoflurane during the procedure. After visualization of the vocal cords, the neonate should be positioned with a small roll under the shoulders to slightly extend the neck and the tracheoscope should be pushed gently to enter

the trachea. The endoscope must be slowly brought down to the carina and then withdrawn more slowly to look for the presence of fistulas or other anomalies. A video recording system with magnification facilitates visualization of the tracheobronchial anatomy and allows an immediate collegial discussion of the findings. Higher quality images are provided by rigid scopes^[33]. If no proximal TEF is recognized, 10 mL of air should be injected through a gastric tube positioned in the upper esophageal pouch as very small or occluded fistulas could be missed. Mechanical ventilation can be facilitated by the placement of a 3-4 Ch Fogarty catheter relative to the child's weight to occlude the distal tracheoesophageal fistula, thus avoiding gastric overdistension and gastroesophageal reflux^[32]. Before the insertion of the Fogarty, we suggest placing a nasogastric tube through the mouth, parallel and external to the endoscope, which is advanced through the fistula into the stomach to aspirate gastric secretions. At this point, the balloon is inflated with 0.2-0.75 mL of water-soluble contrast under tracheoscopic control, retracted up to the entrance of the fistula in the trachea. This maneuver allows better assessment of the distance between the distal fistula and the tip of the endoscope or the radiopaque gastric tube subsequently positioned at the bottom of the upper esophageal pouch at chest X-ray. Furthermore, the inflated Fogarty balloon provides a gentle dilatation of the lower pouch, which makes easier the esophago-esophageal anastomosis. In patients with H-type TEF, Atzori *et al*^[2] advocates cannulation of the fistula by the insertion of a guide wire through the trachea and withdrawn through the mouth under fluoroscopy^[2,33]. With this procedure, the H-fistula can be localized and lifted upwards to enable a cervical approach and avoid thoracotomy^[2]. TBS also allows a correct positioning of the endotracheal tube which should be placed above the carina but below any fistula present^[11] at an appropriate depth which can be assessed by flexible tracheoscopy through an adaptor on the facemask.

REFERENCES

- 1 **Benjamin B.** Endoscopy in esophageal atresia and tracheoesophageal fistula. *Ann Otol Rhinol Laryngol* 1981; **90**: 376-382 [PMID: 7271151]
- 2 **Atzori P,** Iacobelli BD, Bottero S, Spiridakis J, Laviani R, Trucchi A, Braguglia A, Bagolan P. Preoperative tracheobronchoscopy in newborns with esophageal atresia: does it matter? *J Pediatr Surg* 2006; **41**: 1054-1057 [PMID: 16769333 DOI: 10.1016/j.jpedsurg.2006.01.074]
- 3 **Sfeir R,** Bonnard A, Khen-Dunlop N, Auber F, Gelas T, Michaud L, Podevin G, Breton A, Fouquet V, Piolat C, Lemelle JL, Petit T, Lavrand F, Becmeur F, Polimerol ML, Michel JL, Elbaz F, Habonimana E, Allal H, Lopez E, Lardy H, Morineau M, Pelatan C, Merrot T, Delagausie P, de Vries P, Levard G, Buisson P, Sapin E, Jaby O, Borderon C, Weil D, Gueiss S, Aubert D, Echaieb A, Fourcade L, Breaud J, Laplace C, Pouzac M, Duhamel A, Gottrand F. Esophageal atresia: data from a national cohort. *J Pediatr Surg* 2013; **48**: 1664-1669 [PMID: 23932604 DOI: 10.1016/j.jpedsurg.2013.03.075]
- 4 **Lal D,** Miyano G, Juang D, Sharp NE, St Peter SD. Current patterns of practice and technique in the repair of esophageal atresia and tracheoesophageal fistula: an IPEG survey. *J Laparosc Adv Surg Tech A* 2013; **23**: 635-638 [PMID: 23758564 DOI: 10.1089/lap.2013.0210]
- 5 **Zani A,** Eaton S, Hoellwarth ME, Puri P, Tovar J, Fasching G, Bagolan P, Lukac M, Wijnen R, Kuebler JF, Cecchetto G, Rintala R, Pierro A. International survey on the management of esophageal atresia. *Eur J Pediatr Surg* 2014; **24**: 3-8 [PMID: 23934626 DOI: 10.1055/s-0033-1350058]
- 6 **Burge DM,** Shah K, Spark P, Shenker N, Pierce M, Kurinczuk JJ, Draper ES, Johnson PR, Knight M. Contemporary management and outcomes for infants born with oesophageal atresia. *Br J Surg* 2013; **100**: 515-521 [PMID: 23334932 DOI: 10.1002/bjs.9019]
- 7 **Parolini F,** Leva E, Morandi A, Macchini F, Gentilino V, Di Cesare A, Torricelli M. Anastomotic strictures and endoscopic dilatations following esophageal atresia repair. *Pediatr Surg Int* 2013; **29**: 601-605 [PMID: 23519549 DOI: 10.1007/s00383-013-3298-4]
- 8 **Parolini F,** Morandi A, Macchini F, Canazza L, Torricelli M, Zanini A, Leva E. Esophageal atresia with proximal tracheoesophageal fistula: a missed diagnosis. *J Pediatr Surg* 2013; **48**: E13-E17 [PMID: 23845651 DOI: 10.1016/j.jpedsurg.2013.04.018]
- 9 **Bax KN,** Roskott AM, van der Zee DC. Esophageal atresia without distal tracheoesophageal fistula: high incidence of proximal fistula. *J Pediatr Surg* 2008; **43**: 522-525 [PMID: 18358293 DOI: 10.1016/j.jpedsurg.2007.10.034]
- 10 **Kane TD,** Atri P, Potoka DA. Triple fistula: management of a double tracheoesophageal fistula with a third H-type proximal fistula. *J Pediatr Surg* 2007; **42**: E1-E3 [PMID: 17560187 DOI: 10.1016/j.jpedsurg.2006.11.009]
- 11 **Veyckemans F,** Hamoir M, Rombaux P, Van Obbergh LJ, Reding R. Preoperative tracheoscopy in neonates with esophageal atresia. *Anesth Analg* 2002; **95**: 1827-1828 [PMID: 12456480 DOI: 10.1097/00005539-200212000-00088]
- 12 **Usui N,** Kamata S, Ishikawa S, Sawai T, Okuyama H, Imura K, Okada A. Anomalies of the tracheobronchial tree in patients with esophageal atresia. *J Pediatr Surg* 1996; **31**: 258-262 [PMID: 8938354 DOI: 10.1016/S0022-3468(96)90010-X]
- 13 **Mortellaro VE,** Pettiford JN, St Peter SD, Fraser JD, Ho B, Wei J. Incidence, diagnosis, and outcomes of vocal fold immobility after esophageal atresia (EA) and/or tracheoesophageal fistula (TEF) repair. *Eur J Pediatr Surg* 2011; **21**: 386-388 [PMID: 22169990 DOI: 10.1055/s-0031-1291269]
- 14 **Kosloske AM,** Jewell PF, Cartwright KC. Crucial bronchoscopic findings in esophageal atresia and tracheoesophageal fistula. *J Pediatr Surg* 1988; **23**: 466-470 [PMID: 3379553 DOI: 10.1016/S0022-3468(88)80450-0]
- 15 **Kovesi T,** Rubin S. Long-term complications of congenital esophageal atresia and/or tracheoesophageal fistula. *Chest* 2004; **126**: 915-925 [PMID: 15364774 DOI: 10.1378/chest.126.3.915]
- 16 **Midulla F,** de Blic J, Barbato A, Bush A, Eber E, Kotecha S, Haxby E, Moretti C, Pohunek P, Ratjen F. Flexible endoscopy of paediatric airways. *Eur Respir J* 2003; **22**: 698-708 [PMID: 14582925 DOI: 10.1183/09031936.02.00113202]
- 17 **Mair EA,** Parsons DS. Pediatric tracheobronchomalacia and major airway collapse. *Ann Otol Rhinol Laryngol* 1992; **101**: 300-309 [PMID: 1562133]
- 18 **Dodge-Khatami A,** Deanovic D, Sacher P, Weiss M, Gerber AC. Clinically relevant tracheomalacia after repair of esophageal atresia: the role of minimal intra-operative dissection and timing for aortopexy. *Thorac Cardiovasc Surg* 2006; **54**: 178-181 [PMID: 16639679 DOI: 10.1055/s-2005-872954]
- 19 **Spitz L,** Kiely E, Brereton RJ. Esophageal atresia: five year experience with 148 cases. *J Pediatr Surg* 1987; **22**: 103-108 [PMID: 3820001 DOI: 10.1016/S0022-3468(87)80420-7]
- 20 **De Gabriele LC,** Cooper MG, Singh S, Pitkin J. Intraoperative fiberoptic bronchoscopy during neonatal tracheoesophageal fistula ligation and oesophageal atresia repair. *Anaesth Intensive Care* 2001; **29**: 284-287 [PMID: 11439802]

- 21 **Iannoli ED**, Litman RS. Tension pneumothorax during flexible fiberoptic bronchoscopy in a newborn. *Anesth Analg* 2002; **94**: 512-53; table of contents [PMID: 11867367 DOI: 10.1097/00005539-200203000-00007]
- 22 **Deanovic D**, Gerber AC, Dodge-Khatami A, Dillier CM, Meuli M, Weiss M. Tracheoscopy assisted repair of tracheo-esophageal fistula (TARTEF): a 10-year experience. *Paediatr Anaesth* 2007; **17**: 557-562 [PMID: 17498018 DOI: 10.1111/j.1460-9592.2006.02147.x]
- 23 **McAlister WH**, Siegel MJ. Fatal aspirations in infancy during gastrointestinal series. *Pediatr Radiol* 1984; **14**: 81-83 [PMID: 6728539 DOI: 10.1007/BF01625811]
- 24 **Su P**, Yuan Y, Zhang Z, Huang Y, Wang W. Application of high-frequency ultrasound in esophageal atresia with distal fistula. *Dis Esophagus* 2014; **27**: 325-329 [PMID: 23980565 DOI: 10.1111/dote.12113]
- 25 **Gassner I**, Geley TE. Sonographic evaluation of oesophageal atresia and tracheo-oesophageal fistula. *Pediatr Radiol* 2005; **35**: 159-164 [PMID: 15480618 DOI: 10.1007/s00247-004-1329-y]
- 26 **Su P**, Huang Y, Wang W, Zhang Z. The value of preoperative CT scan in newborns with type C esophageal atresia. *Pediatr Surg Int* 2012; **28**: 677-680 [PMID: 22491897 DOI: 10.1007/s00383-012-3082-x]
- 27 **Wen Y**, Peng Y, Zhai RY, Li YZ. Application of MPVR and TL-VR with 64-row MDCT in neonates with congenital EA and distal TEF. *World J Gastroenterol* 2011; **17**: 1649-1654 [PMID: 21472133 DOI: 10.3748/wjg.v17.i12.1649]
- 28 **Mahalik SK**, Sodhi KS, Narasimhan KL, Rao KL. Role of preoperative 3D CT reconstruction for evaluation of patients with esophageal atresia and tracheoesophageal fistula. *Pediatr Surg Int* 2012; **28**: 961-966 [PMID: 22722826 DOI: 10.1007/s00383-012-3111-9]
- 29 **Fitos S**, Atasoy C, Yagmurcu A, Akyar S, Erden A, Dindar H. Three-dimensional CT of congenital esophageal atresia and distal tracheoesophageal fistula in neonates: preliminary results. *AJR Am J Roentgenol* 2000; **175**: 1403-1407 [PMID: 11044052 DOI: 10.2214/ajr.175.5.1751403]
- 30 **Garge S**, Rao KL, Bawa M. The role of preoperative CT scan in patients with tracheoesophageal fistula: a review. *J Pediatr Surg* 2013; **48**: 1966-1971 [PMID: 24074676 DOI: 10.1016/j.jpedsurg.2013.06.010]
- 31 **Cantinotti M**, Hegde S, Bell A, Razavi R. Diagnostic role of magnetic resonance imaging in identifying aortic arch anomalies. *Congenit Heart Dis* 2008; **3**: 117-123 [PMID: 18380760 DOI: 10.1111/j.1747-0803.2008.00174.x]
- 32 **Filston HC**, Chitwood WR, Schkolne B, Blackmon LR. The Fogarty balloon catheter as an aid to management of the infant with esophageal atresia and tracheoesophageal fistula complicated by severe RDS or pneumonia. *J Pediatr Surg* 1982; **17**: 149-151 [PMID: 7077495 DOI: 10.1016/S0022-3468(82)80199-1]
- 33 **Parolini F**, Morandi A, Macchini F, Gentilino V, Zanini A, Leva E. Cervical/thoracotomic/thoracoscopic approaches for H-type congenital tracheo-esophageal fistula: a systematic review. *Int J Pediatr Otorhinolaryngol* 2014; **78**: 985-989 [PMID: 24856837]

P- Reviewer: Contini S, Nagahara H **S- Editor:** Ji FF

L- Editor: Roemmele A **E- Editor:** Zhang DN





Published by **Baishideng Publishing Group Inc**

8226 Regency Drive, Pleasanton, CA 94588, USA

Telephone: +1-925-223-8242

Fax: +1-925-223-8243

E-mail: bpgoffice@wjgnet.com

Help Desk: <http://www.wjgnet.com/esps/helpdesk.aspx>

<http://www.wjgnet.com>

