

Endoscopic retrieval of an 18-cm long chopstick embedded for ten months post-automutilation in the esophagus of a patient with psychosis

Sheng-Xi Li, Hui Li, Tao Chen, Mei-Dong Xu

Sheng-Xi Li, Department of Endoscopic Diagnosis and Therapy, People's Hospital of Liaoning Province, Shenyang 110016, Liaoning Province, China

Hui Li, Department of Anesthesia, People's Hospital of Liaoning Province, Shenyang 110016, Liaoning Province, China

Tao Chen, Mei-Dong Xu, Endoscopy Center, Zhongshan Hospital of Fudan University, Shanghai 200032, China

Author contributions: Li SX and Xu MD contributed to the conception and design; Li SX and Li H drafted the article; Chen T critically revised the article for important intellectual content; Xu MD approved the final copy of the article.

Correspondence to: Mei-Dong Xu, MD, PhD, Endoscopy Center, Zhongshan Hospital of Fudan University, 180 Fenglin Rd, Shanghai 200032, China. xu.meidong@zs-hospital.sh.cn

Telephone: +86-21-64041900 Fax: +86-21-64041900

Received: May 8, 2014 Revised: June 3, 2014

Accepted: June 27, 2014

Published online: September 16, 2014

Abstract

Foreign body ingestion is an emergency or acute situation that commonly occurs in children or adults and involves the ingestion of one or more objects. Moreover, once the discovery of swallowed foreign bodies has been made, families are typically very anxious to have the patient see a doctor. If the foreign object becomes embedded in the digestive tract, it must be removed; in emergencies, this is done by endoscopy or surgery. This case report presents the successful endoscopic retrieval of a chopstick with both sides embedded 4 cm into the esophageal wall for > 10 mo in a male patient following automutilation in an attempt to be released from a psychiatric hospital. Hot hemostatic forceps were used to open the distal esophageal mucosa in which the chopstick was embedded. The procedure was performed under intravenous general anesthesia and took approximately 7 h.

Key words: Foreign body; Esophagus; Endoscopy; Chopstick; Gastroscope; Hot hemostatic forceps

Core tip: Foreign body ingestion is an emergency that often occurs in children or adults with psychiatric disorders or mental retardation. Here, we report the unique case of a chopstick lodged in the esophagus for 10 mo in a 50-year-old man. The chopstick was embedded 4 cm into the esophageal wall at both ends. Therefore, the procedure was performed under intravenous anesthesia. We made a 4-cm long incision, approximately 1 cm in depth in the esophageal mucosa using hot hemostatic forceps. This procedure took approximately 7 h to perform and an 18-cm long chopstick was removed.

Li SX, Li H, Chen T, Xu MD. Endoscopic retrieval of an 18-cm long chopstick embedded for ten months post-automutilation in the esophagus of a patient with psychosis. *World J Gastrointest Endosc* 2014; 6(9): 453-456 Available from: URL: <http://www.wjgnet.com/1948-5190/full/v6/i9/453.htm> DOI: <http://dx.doi.org/10.4253/wjge.v6.i9.453>

INTRODUCTION

Ingestion of foreign bodies that lodge in the upper gastrointestinal (GI) tract is a common clinical situation. Most of these objects pass through the GI tract spontaneously, but some require emergency endoscopic or surgical removal. Here, we report the first case of a patient with psychosis who had a chopstick lodged in the esophagus with both ends embedded in the esophageal wall for > 10 mo. The patient had a 2-mo history of repeated fever prior to foreign body removal. Ten months previously, the patient experienced a sudden loss of appetite and displayed repetitive behavior of touching his sternum with his hand. The patient's family brought him food daily. He experienced repeated episodes of emesis and fever for 2

mo before the family brought him to the hospital.

CASE REPORT

Foreign body ingestion is a commonly encountered clinical problem and emergency endoscopy case. The patient had swallowed a chopstick following self-mutilation in an attempt to be released from a psychiatric hospital. He refused to say why he would not take fluids daily until his repeated vomiting and fever gradually exacerbated. The family took him to see a doctor in the GI/Internal Medicine Department of our hospital. Chest computed tomography (CT) revealed the tip of an esophageal foreign body as well as a bilateral lung infection (Figure 1A and B). Gastroscopy revealed a chopstick with both ends lodged 4 cm in the esophagus wall (Figure 1C).

The patient's family chose to have the foreign body removed by gastroscopy rather than by a surgical procedure. Initially, a snare was used to tentatively remove the chopstick, however, this attempt failed (Figure 2A). After that, the bagging around the proximal esophageal mucosa was cut 22 cm from the incisors. However, the esophageal mucosa was fixed, and the field of vision was insufficient. Eventually, the esophageal wall was cut and wrapped on the far side of the chopstick using a hook knife. However, because the esophageal wall mucosa was > 1 cm thick, the hook knife was unable to cut properly. We cut the tissue using hot hemostatic forceps (Figure 2B), the distal end of the chopstick was freed (Figure 2C) and then removed by a snare and foreign body clamp. The full length of the removed chopstick was 18 cm (Figure 2D). The procedure was performed under intravenous anesthesia and took approximately 7 h to perform. On postoperative day 1, the patient experienced sustainable chest pain and had a maximum body temperature of 38.5 °C. The patient's condition gradually improved, and he was discharged on postoperative day 7.

DISCUSSION

Ingestion of foreign bodies is common in clinical practice^[1-3]. However, most foreign body ingestion occurs in children between 6 mo and 6 years of age; the rate of foreign body ingestion in adults is lower^[4]. In adults, it occurs more commonly in patients with psychiatric disorders, mental retardation, or impairment caused by alcohol. The vast majority of swallowed foreign bodies are found and removed in a timely manner by endoscopy or surgery. This is the first report of ingestion of a foreign body in a patient with psychosis that remained lodged in the esophagus for > 10 mo. Because patients do not like the psychiatric hospital environment, they attempt self-mutilation in order to go home, according to family members. An 18-cm long chopstick is difficult to swallow and would require an external force to enter the esophagus. The distal end of the chopstick may pierce the esophageal mucosa slightly, but cannot pass through the cardia easily. The esophageal peristaltic wave that occurs

while eating may move the chopstick tip in close contact with the esophageal mucosa. Reactive hyperplasia that would subsequently occur could embed the chopstick as a foreign body. In this case, hyperplasia of approximately 4 cm × 2 cm in the esophageal mucosa at both ends of the chopstick was noted after 10 mo.

The type of foreign body may determine the complications. Our patient was first examined to determine whether the chopstick had perforated the esophageal wall; this was suspected as the patient had recurrent fever. The CT results were important, and helped us determine that the chopstick perforated only the hyperplastic tissue and not the esophageal wall.

The type of foreign object differs as well. The commonest types of foreign bodies are endoscopically removed in a reliable and safe manner by skilled endoscopists, with a high success rate^[5]. Chopstick removal is associated with a high degree of risk; a skilled endoscopist is needed to perform a preoperative assessment and develop a good treatment plan. Esophageal perforation may require surgical management. We believe that endoscopic removal of foreign bodies is best done in the operating room.

In this case, because both ends of the chopstick were tightly embedded in the esophageal wall membrane, we suggested that the foreign body should be removed surgically, but the family insisted on gastroscopy. We found that this would be possible only if one end of the chopstick could be freed. Initially, we needed to determine if this would be the proximal or distal end. The chopstick was exposed at the distal end, approximately 22 cm from the incisors. Only a slight uplift of the esophageal mucosa was visible, and the mucous membrane was not fixed. Initially, we attempted to cut the esophageal wall which was wrapped around the distal end of the chopstick using a hook knife, but because the esophageal wall membrane was approximately 1 cm thick, the hook knife was not sufficient. We then used hot biopsy forceps to make a vertical incision in the mucosa to free the distal end of the chopstick. Considering the difficult nature of this procedure, it took a long time to perform, and there were concerns that the patient may not tolerate the anesthesia well. We decided to perform the procedure under intravenous anesthesia. Another key factor in this decision was cutting the esophageal wall next to the chopstick^[6-8].

The ingestion of foreign bodies is one of the most common endoscopic emergencies in China. However, compared to the cases reported in other studies, this is a special case in that the foreign body was a long chopstick and took us approximately 7 h to complete the procedure. In 2013 (Epub in 2012), we reported the endoscopic management of impacted esophageal foreign bodies and the longest one in this cohort was a 5.5 cm fish bone^[1]. In the recent report by Zhang *et al*^[9], the mean size of esophageal foreign bodies was less than 2 cm and the endoscopic procedure time was approximately 4 min. To date, the case in the present report is the first clinical report of the longest impacted esophageal foreign body

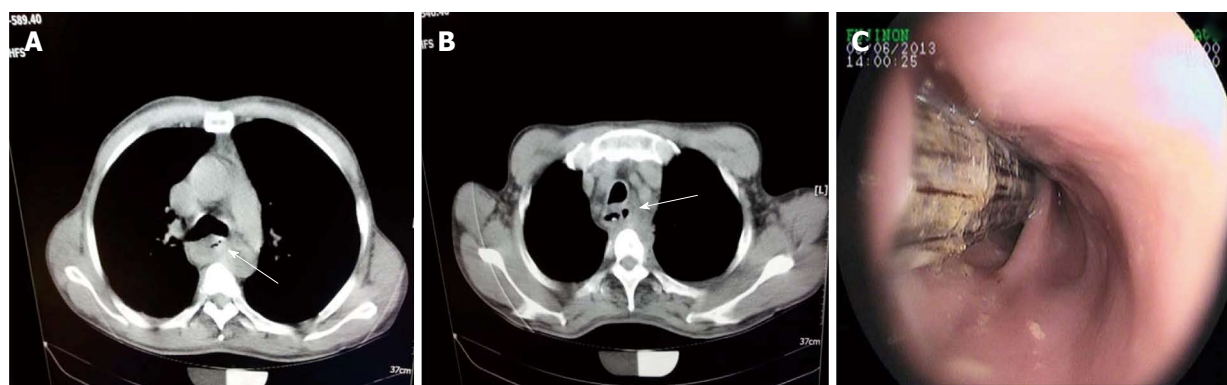


Figure 1 A long chopstick embedded in the esophageal wall. A and B: The roentgenograms showing the foreign body in the esophagus (arrow); C: Endoscopy showing the foreign body in the esophagus.

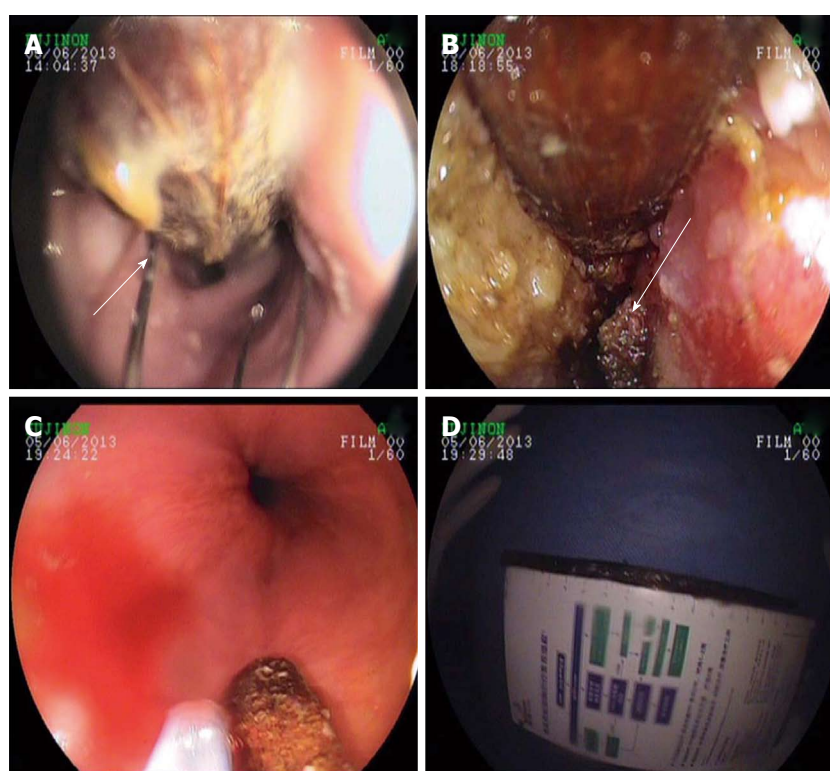


Figure 2 Endoscopic retrieval of the chopstick. A: A snare was tentatively used to remove the chopstick (arrow); B: Hot hemostatic forceps cutting the distal end of the chopstick in the lower esophagus (arrow); C: The freed distal end of the chopstick; D: The 18 cm chopstick measured by a ruler after removal from the esophagus.

removed by endoscopy. Li *et al*^[6] stated that when foreign bodies were deeply fixed in the esophageal wall, it was better to avoid any endoscopic attempts and to resort to surgery. However, according to our experience, impacted esophageal foreign bodies can be extracted even when they are fixed in the esophageal wall^[1]. Compared to surgery, endoscopic retrieval is minimally invasive and economical, especially in patients older than 60 years, although the procedure time can sometimes be long.

In conclusion, we report our experience of retrieving an 18-cm long chopstick which was lodged 4 cm in the esophageal wall for > 10 mo. To our knowledge, this is the first clinical report of this type of retrieval in a single case.

COMMENTS

Case characteristics

Exacerbated vomiting and fever was described.

Clinical diagnosis

A chest computed tomography (CT) scan revealed the tip of an esophageal foreign body as well as a bilateral lung infection and gastroscopy revealed a chopstick with both ends lodged 4 cm in the esophagus wall.

Differential diagnosis

The gastroscopy confirmed a foreign body in the esophagus.

Laboratory diagnosis

Blood tests were performed routinely and no major clues were found.

Imaging diagnosis

A chest CT scan revealed the tip of an esophageal foreign body.

Treatment

Endoscopic retrieval of the chopstick.

Experiences and lessons

Endoscopy is an effective and minimally invasive treatment for similar cases.

Peer review

This is a very interesting, original case report presenting utility of gastrointestinal endoscopy in diagnosis of psychiatric patient and demonstrating advantage of collaboration between psychiatrists and other clinicians, in management of patients with mental disorders. It is important in face of the fact that this collaboration is very often neglected. This paper is well written and endoscopic procedure is described in detail. The results are clearly presented.

REFERENCES

- 1 **Chen T**, Wu HF, Shi Q, Zhou PH, Chen SY, Xu MD, Zhong YS, Yao LQ. Endoscopic management of impacted esophageal foreign bodies. *Dis Esophagus* 2013; **26**: 799-806 [PMID: 22973974 DOI: 10.1111/j.1442-2050.2012.01401.x]
- 2 **Paul SP**, Hawes D, Taylor TM. Foreign body ingestion in children: case series, review of the literature and guidelines on minimising accidental ingestions. *J Fam Health Care* 2010; **20**: 200-204 [PMID: 21319673]
- 3 **Webb WA**. Management of foreign bodies of the upper gastrointestinal tract: update. *Gastrointest Endosc* 1995; **41**: 39-51 [PMID: 7698623 DOI: 10.1016/S0016-5107(95)70274-1]
- 4 **Mosca S**, Manes G, Martino R, Amitrano L, Bottino V, Bove A, Camera A, De Nucci C, Di Costanzo G, Guardascione M, Lampasi F, Picascia S, Picciotto FP, Riccio E, Rocco VP, Uomo G, Balzano A. Endoscopic management of foreign bodies in the upper gastrointestinal tract: report on a series of 414 adult patients. *Endoscopy* 2001; **33**: 692-696 [PMID: 11490386 DOI: 10.1055/s-2001-16212]
- 5 **Wu WT**, Chiu CT, Kuo CJ, Lin CJ, Chu YY, Tsou YK, Su MY. Endoscopic management of suspected esophageal foreign body in adults. *Dis Esophagus* 2011; **24**: 131-137 [PMID: 20946132 DOI: 10.1111/j.1442-2050.2010.01116.x]
- 6 **Li ZS**, Sun ZX, Zou DW, Xu GM, Wu RP, Liao Z. Endoscopic management of foreign bodies in the upper-GI tract: experience with 1088 cases in China. *Gastrointest Endosc* 2006; **64**: 485-492 [PMID: 16996336 DOI: 10.1016/j.gie.2006.01.059]
- 7 **Katsinelos P**, Kountouras J, Paroutoglou G, Zavos C, Mimiadis K, Chatzimavroudis G. Endoscopic techniques and management of foreign body ingestion and food bolus impaction in the upper gastrointestinal tract: a retrospective analysis of 139 cases. *J Clin Gastroenterol* 2006; **40**: 784-789 [PMID: 17016132 DOI: 10.1097/01.mcg.0000225602.25858.2c]
- 8 **Li QP**, Ge XX, Ji GZ, Fan ZN, Zhang FM, Wang Y, Miao L. Endoscopic retrieval of 28 foreign bodies in a 100-year-old female after attempted suicide. *World J Gastroenterol* 2013; **19**: 4091-4093 [PMID: 23840158 DOI: 10.3748/wjg.v19.i25.4091]
- 9 **Zhang S**, Wang J, Wang J, Zhong B, Chen M, Cui Y. Transparent cap-assisted endoscopic management of foreign bodies in the upper esophagus: a randomized, controlled trial. *J Gastroenterol Hepatol* 2013; **28**: 1339-1342 [PMID: 23573993 DOI: 10.1111/jgh.12215]

P- Reviewer: Bugaj AM, Ciaccio E **S- Editor:** Ji FF
L- Editor: Webster JR **E- Editor:** Zhang DN





Published by **Baishideng Publishing Group Inc**

8226 Regency Drive, Pleasanton, CA 94588, USA

Telephone: +1-925-223-8242

Fax: +1-925-223-8243

E-mail: bpgoffice@wjgnet.com

Help Desk: <http://www.wjgnet.com/esps/helpdesk.aspx>

<http://www.wjgnet.com>

