

## Acute idiopathic pancreatitis in pregnancy: A case study

Ji Yeon Kim, Sung Hoon Jung, Hyung Wook Choi, Dong Jin Song, Cheol Yoon Jeong, Dong Hyun Lee, Il Soon Whang

Ji Yeon Kim, Sung Hoon Jung, Hyung Wook Choi, Dong Jin Song, Cheol Yoon Jeong, Dong Hyun Lee, Il Soon Whang, Department of Internal Medicine, Cheil General Hospital and Women's Healthcare Center, Kwandong University College of Medicine, Seoul KS013, South Korea

**Author contributions:** Kim JY and Jung SH designed the research, analyzed the data and wrote the manuscript; Lee DH, Jeong CY, Song DJ and Choi HW contributed equally to this work; Jung SH critically revised the paper; Whang IS was responsible for approval of the final version of the manuscript.

**Correspondence to:** Sung Hoon Jung, MD, Department of Internal Medicine, Cheil General Hospital and Women's Healthcare Center, Kwandong University College of Medicine, 17, Seoae-ro 1-gil, Jung-gu, Seoul, KS013, South Korea. [gidrjsh@naver.com](mailto:gidrjsh@naver.com)

Telephone: +82-2-0004714 Fax: +82-2-0007477

Received: May 28, 2014 Revised: July 31, 2014

Accepted: September 5, 2014

Published online: November 21, 2014

### Abstract

Acute pancreatitis during pregnancy is a rare event, and can be associated with high maternal mortality and fetal loss. Gallstone disease is thought to be the most common causative factor of acute pancreatitis, but, in many cases, the cause remains unclear. We report a case of a 36-year-old woman at 35 wk of gestation, who presented with severe pain confined to the upper abdomen and radiating to the back. The patient was diagnosed with acute idiopathic pancreatitis, which was managed conservatively; she recovered within several days and then delivered a healthy baby. Therefore it is important to consider acute pancreatitis when a pregnant woman presents with upper abdominal pain, nausea and vomiting in order to improve fetal and maternal outcomes for patients with acute pancreatitis.

© 2014 Baishideng Publishing Group Inc. All rights reserved.

**Key words:** Acute pancreatitis; Pregnancy; Pancreatitis in pregnancy; Idiopathic; Idiopathic acute pancreatitis

**Core tip:** Acute pancreatitis in pregnancy is infrequent and, if poorly managed, it can increase maternal and fetal mortality. There have been a few case reports published about acute idiopathic pancreatitis in pregnancy thus far. Here, we report a case of a patient that presented with epigastric pain at her 35<sup>th</sup> wk of gestation and was consequently diagnosed with acute idiopathic pancreatitis. The patient successfully recovered after conservative treatment and did not experience any complications. This case emphasizes the importance of early diagnostic studies and proper therapeutic management to help reduce maternal mortality and fetal loss associated with acute pancreatitis during pregnancy.

Kim JY, Jung SH, Choi HW, Song DJ, Jeong CY, Lee DH, Whang IS. Acute idiopathic pancreatitis in pregnancy: A case study. *World J Gastroenterol* 2014; 20(43): 16364-16367 Available from: URL: <http://www.wjgnet.com/1007-9327/full/v20/i43/16364.htm> DOI: <http://dx.doi.org/10.3748/wjg.v20.i43.16364>

### INTRODUCTION

Acute pancreatitis in pregnancy occurs infrequently and has a reported incidence of approximately 1 in 1000 to 3 in 10000 births<sup>[1,2]</sup>. Recently, Zhang *et al*<sup>[3]</sup> reported the incidence of pregnancy-associated acute pancreatitis to be 22.7%. The most frequent etiology of acute pancreatitis in pregnancy is biliary (caused by gallstones or sludge), and other causes are hyperlipidemia or alcohol abuse. Characterized by acute symptom onset, many complications and high mortality, it is difficult to diagnose and treat. Therefore, this condition is often misdiagnosed and treatment can be delayed, which threatens the health of both mothers and babies. In past decades, a high perinatal mortality rate of up to 50% secondary to acute pancreatitis resulted from neonatal deaths after preterm

delivery. However, recent advances of diagnostic testing technology, including imaging (*e.g.*, abdominal ultrasound, endoscopic ultrasound) and neonatal intensive care, have enabled early diagnosis and management and play an important role in improving the prognosis of mother and premature infant survival. Herein we describe a case of acute idiopathic pancreatitis in late pregnancy and discuss its etiology and diagnosis.

## CASE REPORT

A previously healthy 36-year-old multiparous woman (gravida 4, para 2) was admitted at 35 wk of gestation with severe pain localized to the upper abdomen and radiating to the back. The pain was steady, lasted for 2 h and was relieved by lying down. She had no relevant past medical history or family history of autoimmune disease. On regular examination, she and her fetus had been in good health until the onset of symptoms. Vital monitoring at admission showed a pulse rate of 75/min, blood pressure of 100/60 mmHg, body temperature of 37.0 °C and a respiratory rate of 20/min. Physical examination revealed slightly decreased bowel sounds, epigastric tenderness and a gravid uterus. Fetal heart tones were 140/min.

Initial laboratory testing showed a white blood cell count of 8620/ $\mu$ L, a hemoglobin level of 11.9 g/dL, a hematocrit count of 34.2%, a red blood cell count of 3.52 million cells/ $\mu$ L and C-reactive protein of 0.3 mg/dL. There was no hemoconcentration on admission and the hematocrit count decreased to 28.1% after intravenous fluids were administered. Initial serum amylase level was 502 IU/L and lipase level was 539 IU/L. On hospital day 4, the level of amylase decreased to 96 IU/L and the lipase level decreased to 178 IU/L (Table 1). Abdominal ultrasound revealed that the anterior-posterior (AP) diameter of the visible body portion of the pancreas was in the upper normal range (about 18.2 mm) and slit-like fluid collection, which can develop with pancreatitis, was seen in the perisplenic area. No definite evidence of intra- or extra-hepatic duct dilatation was present and the gallbladder was unremarkable (Figure 1). The patient was finally diagnosed with acute idiopathic pancreatitis according to laboratory and abdominal ultrasound results and there was no evidence of other causes of acute pancreatitis. This case was determined to be mild acute pancreatitis based on the Ranson criteria and a bedside index of severity in acute pancreatitis (BISAP) score of 0.

The patient was managed with intravenous fluids, analgesics and by nil per oral. We monitored the fetus using the non-stress test based on amniotic fluid volume. The test results for the fetus were satisfactory for gestational age. The mother improved with this supportive treatment within two days and started a soft diet without any symptoms. Serum amylase and lipase levels dropped to 96 IU/L and 178 IU/L, respectively, on the 4<sup>th</sup> hospital day. The patient was discharged on the 4<sup>th</sup> hospital day in good health.

**Table 1** Laboratory data

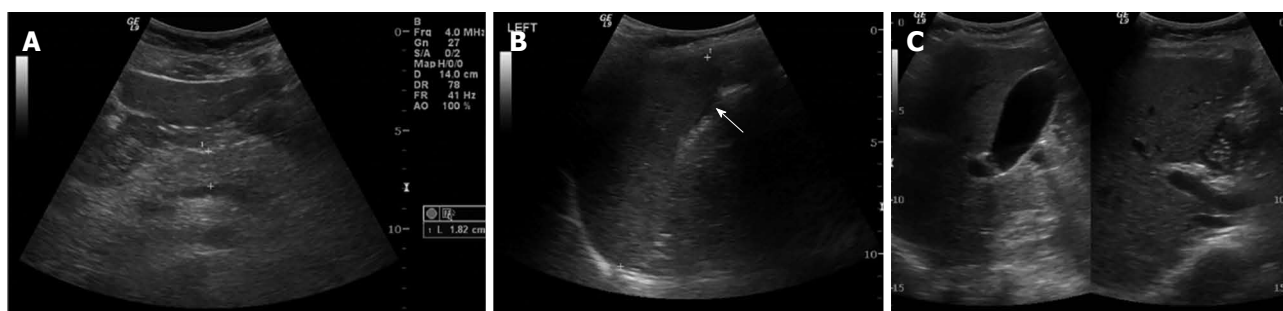
	HD#1	HD#4
WBC ( $4 \times 10^3/\mu\text{L}$ - $10 \times 10^3/\mu\text{L}$ )	8620	7450
Neutrophils (40%-74%)	81.8	80.9
Lymphocytes (19%-48%)	11.6	11.6
Eosinophils (0%-7%)	0.3	0.7
RBC ( $4.2 \times 10^6/\mu\text{L}$ - $5.4 \times 10^6/\mu\text{L}$ )	3.52	2.87
Hb (12-16 g/dL)	12	10.0
Hct (37%-47%)	34.2	28.1
Plt ( $130 \times 10^3/\mu\text{L}$ - $400 \times 10^3/\mu\text{L}$ )	119	103
CRP (0-0.5 mg/dL)	0.3	
Amylase (30-110 U/L)	502	96
Lipase (13-60 U/L)	539	178
FBS (74-100 mg/dL)	87	74
T.P./Alb (6-8/3.3-5.3 g/dL)	6.3/3.6	5.0/3.0
AST/ALT (0-40/0-40 IU/L)	21/11	15/7
ALP/ $\gamma$ -GTP (39-117 IU/L, 0-58 IU/L)	91/8	81/8
T.B./D.B (0.2-1.2/0-0.6 mg/dL)	0.3/0.1	0.3/0.1
BUN/Cr (5-25/0.5-1.4 mg/dL)	8.5/0.5	4.8/0.43
Cholesterol (150-250 mg/dL)	268	214
Triglyceride (44-166 mg/dL)	108	
HDL cholesterol (40-68 mg/dL)	73	
LDL cholesterol (0-130 mg/dL)	117	
LDH (250-520 IU/L)	342	
Total Calcium (8.2-10.8 mg/dL)	7.7	

HD: Hospital day; WBC: White blood cells; RBC: Red blood cells; Hb: Hemoglobin; Hct: Hematocrit; Plt: Platelet; CRP: C-reactive protein; FBS: Fasting blood sugar; T.P.: Total protein; Alb: Albumin; AST: Aspartate transaminase; ALT: Alanine aminotransferase; ALP: Alkaline phosphatase;  $\gamma$ -GTP: Gamma-glutamyl transpeptidase; T.B.: Total bilirubin; D.B.: Direct bilirubin; BUN: Blood urea nitrogen; Cr: Creatinine; HDL: High density lipoprotein; LDL: Low density lipoprotein; LDH: Lactate dehydrogenase.

The patient was followed for 10 d after discharge and was determined to be in good health. She delivered a viable female infant by normal spontaneous vaginal delivery at 39 wk + 5 d of pregnancy. The newborn had good Apgar scores of 8 in the first minute and 9 in the 5th minute and the baby's birth weight was 3.135 kg (range 50<sup>th</sup> to 75<sup>th</sup> percentile). The newborn's physical examination and clinical findings were normal. The patient has maintained her health and had not experienced a recurrence of acute pancreatitis when assessed at 10 d after discharge and 15 d postpartum.

## DISCUSSION

In South Korea, five cases of acute pancreatitis during pregnancy have been reported since 2005. The precipitating factors included 4 cases of hypertriglyceridemia and 1 case of alcohol-induced pancreatitis; however, there have been no case reports of acute idiopathic pancreatitis during pregnancy in South Korea. The etiological associations of acute pancreatitis during pregnancy are similar to those in the general population. Acute pancreatitis in pregnancy is most often associated with gallstone disease or hypertriglyceridemia<sup>[1]</sup>. Several cases of acute idiopathic pancreatitis in pregnancy have been reported worldwide<sup>[4-6]</sup>. Geng *et al*<sup>[7]</sup> reported that 38.9% of cases of acute pancreatitis in pregnancy were caused by biliary tract diseases, 27.8% were due to hypertriglyceridemia,



**Figure 1** Abdominal ultrasound of the patient. A: Anterior-posterior diameter of the visible body portion of the pancreas is in the upper normal range (about 18.2 mm); B: Slit-like fluid collection (arrow) in the perisplenic area was consistent with acute pancreatitis; C: A normal gallbladder and no evidence of intra- or extrahepatic duct dilatation were noted.

and 11.1% were idiopathic.

The relationship between acute pancreatitis and pregnancy remains unclear. Pregnancy does not primarily predispose pregnant woman to pancreatitis, but it does increase the risk of cholelithiasis and biliary sludge formation. Gallstones are the most common etiological factor and thought to be responsible for about 70% of cases of acute pancreatitis in pregnancy. Theoretical explanations for the association between pregnancy and biliary tract diseases include an increased bile acid pool size, percentage of cholic acid, cholesterol secretion and decreased enterohepatic circulation. Moreover, progesterone in pregnancy provokes gallbladder volume increase and slow emptying, induces bile stasis in the duodenum and then increases reflux<sup>[1]</sup>. Estrogens increase cholesterol secretion and minimally alter gallbladder function. Also, in the third trimester, an enlarged uterus and increased intra-abdominal pressure on the biliary duct bring about acute pancreatitis more frequent<sup>[8]</sup>.

Hyperlipidemia is the second most common causative factor of acute pancreatitis, and pregnancy increases the level of serum cholesterol, causes biliary stasis and induces gallstone formation. Hypertriglyceridemia may also directly cause acute pancreatitis. Plasma triglycerides increase to 2-4 times in pregnancy, principally in the third trimester, due to increased triglyceride-rich lipoprotein production and decreased lipoprotein lipase activity<sup>[9,10]</sup>. In women with abnormal lipoprotein metabolism, this can lead to severe hypertriglyceridemia precipitating pancreatitis. More than 1000 mg/dL of serum triglyceride level is an identifiable risk factor and reduction of triglyceride levels to well below 1000 mg/dL effectively prevents further episodes of pancreatitis<sup>[11,12]</sup>. In this case, the initial serum triglyceride level was 108 mg/dL; therefore, the patient was not considered to have hypertriglyceridemia-induced acute pancreatitis.

Other etiological factors for acute pancreatitis include alcohol abuse, diabetes mellitus, and, rarely, hyperparathyroidism, connective tissue diseases, abdominal surgery, infections or iatrogenic sources such as diuretics, antibiotics and antihypertensive drugs.

Laboratory tests are essential for diagnosing acute pancreatitis and the tests can include serum amylase, lipase, complete blood count, serum triglycerides, calcium

and liver function tests. An elevated serum amylase level has a diagnostic sensitivity of 81% and adding serum lipase increases this sensitivity to 94%<sup>[11]</sup>.

Abdominal ultrasound is an ideal imaging technique for diagnosing acute pancreatitis in pregnancy because it has no associated radiation risk and is useful for detecting dilated pancreatic ducts and pseudocysts<sup>[13]</sup>. However, it is difficult to diagnose acute pancreatitis in pregnancy by ultrasound because an enlarged uterus and combined ileus make a pancreas shadow invisible. Recently, additional useful imaging tools have been developed to detect acute pancreatitis in pregnancy. Abdominal ultrasound, computed tomography (CT), endoscopic ultrasound and magnetic resonance cholangiopancreatography (MRCP) are available for diagnosing a biliary etiology for acute pancreatitis. The usefulness of CT is substantially restricted in pregnancy because of the potential radiation exposure to the fetus.

Conservative therapy for acute pancreatitis, which includes gastric decompression, antispasmodic drugs, and antibiotics, is the first choice therapy, and the efficacy of surgical treatment remains controversial. However, surgical treatment could be considered under circumstances such as pancreatic enlargement, necrosis and gastrointestinal perforation. In case of moderate to severe acute pancreatitis that does not improve after 2-3 d of conservative management, endoscopic retrograde cholangiopancreatography (ERCP) or MRCP should be used to search for a causative factor. MRCP is associated with lower radiation exposure risks for the mother and fetus compared with other methods. However, MRCP can be used only for diagnosis and not for treatment. The role of therapeutic ERCP with sphincterotomy in the management of pregnant patients with acute pancreatitis without common bile duct stones continues to be controversial<sup>[14]</sup>. In a few cases, non-radiation ERCP was used during pregnancy and had good therapeutic effects<sup>[15]</sup>. Overall, a multi-disciplinary approach that includes obstetricians, surgeons and gastroenterologists is a key aspect of severe acute pancreatitis management<sup>[16]</sup>.

When a pregnant woman presents with upper abdominal pain, acute pancreatitis as well as acute gastritis, peptic ulcer disease and acute cholecystitis should be considered and the serum amylase and lipase levels should

be assessed in addition to using diagnostic imaging tools. In the past, pancreatitis during pregnancy was associated with a 20%-50% maternal death rate and fetal loss. However, recent studies have shown that there is a less than 5% mortality rate due to earlier diagnosis and better treatment options and advances in neonatal intensive care<sup>[13]</sup>. Although the diagnostic criteria and clinical scales for acute pancreatitis are not specific for pregnant patients, the Ranson criteria and BISAP score can be used to evaluate the severity of and to treat acute pancreatitis during pregnancy.

In conclusion, acute pancreatitis in pregnancy is an infrequent condition that can result from unknown origins, as identified in this case. Because delayed diagnosis and treatment can allow for a greater prevalence of shock and sepsis in both the pregnant woman and the fetus, early diagnosis and classification of severity of acute pancreatitis at presentation are an essential step for successful management in patients suffering from acute abdominal pain during pregnancy.

## COMMENTS

### Case characteristics

A 36-year-old woman at 35 wk of gestation with severe pain localized to the upper abdomen.

### Clinical diagnosis

The patient had direct tenderness on the upper abdomen with decreased bowel sounds along with pain that radiated to the back and was relieved by lying down.

### Differential diagnosis

Gallstones, acute cholecystitis, acute gastritis, peptic ulcer disease.

### Laboratory diagnosis

At admission, serum amylase level was 502 IU/L and the lipase level was 539 IU/L. On hospital day 4, amylase and lipase levels decreased.

### Imaging diagnosis

Abdominal ultrasound showed slit-like fluid collection, which can develop with pancreatitis; the fluid was seen in the perisplenic area.

### Treatment

The patient was treated conservatively by nil per oral and with intravenous fluids and analgesics.

### Experiences and lessons

Idiopathic acute pancreatitis is rare during pregnancy, but it can lead to life-threatening complications that require urgent treatment.

### Peer review

In this study, Kim *et al* report the case of a 36-year-old woman at 35 wk of gestation who was hospitalized due to acute pancreatitis. The authors discuss the steps undertaken that led to the diagnosis of idiopathic acute pancreatitis. Laboratory and ultrasound results are presented for the first and fourth hospitalization days together with the treatment received by the patient which consisted in conservative management. The patient was discharged on the fourth day and followed for ten days later. A viable female infant was born by normal spontaneous vaginal delivery at 39 wk + 5<sup>th</sup> day of pregnancy. The mother was in good health without recurrence of acute pancreatitis until the final follow-up at 15 d

postpartum. This is an interesting study and would provide useful information once the following points have been completely addressed.

## REFERENCES

- 1 Pitchumoni CS, Yegneswaran B. Acute pancreatitis in pregnancy. *World J Gastroenterol* 2009; **15**: 5641-5646 [PMID: 19960559 DOI: 10.3748/wjg.15.5641]
- 2 Qihui C, Xiping Z, Xianfeng D. Clinical study on acute pancreatitis in pregnancy in 26 cases. *Gastroenterol Res Pract* 2012; **2012**: 271925 [PMID: 23213326 DOI: 10.1155/2012/271925]
- 3 Zhang DL, Huang Y, Yan L, Phu A, Ran X, Li SS. Thirty-eight cases of acute pancreatitis in pregnancy: a 6-year single center retrospective analysis. *J Huazhong Univ Sci Technolog Med Sci* 2013; **33**: 361-367 [PMID: 23771661 DOI: 10.1007/s11596-013-1125-8]
- 4 Nanda S, Gupta A, Dora A, Gupta A. Acute pancreatitis: a rare cause of acute abdomen in pregnancy. *Arch Gynecol Obstet* 2009; **279**: 577-578 [PMID: 18726109 DOI: 10.1007/s00404-008-0755-8]
- 5 Weng MT, Wei SC, Wong JM, Chang TC. Hyperemesis gravidarum presenting as jaundice and transient hyperthyroidism complicated with acute pancreatitis. *J Formos Med Assoc* 2005; **104**: 194-197 [PMID: 15818435]
- 6 Croucher C, Wilson J. Idiopathic acute pancreatitis in pregnancy. *J Obstet Gynaecol* 1997; **17**: 588-589 [PMID: 15511970]
- 7 Geng Y, Li W, Sun L, Tong Z, Li N, Li J. Severe acute pancreatitis during pregnancy: eleven years experience from a surgical intensive care unit. *Dig Dis Sci* 2011; **56**: 3672-3677 [PMID: 21735079 DOI: 10.1007/s10620-011-1809-5]
- 8 Tang SJ, Rodriguez-Frias E, Singh S, Mayo MJ, Jazrawi SF, Sreenarasimhaiah J, Lara LF, Rockey DC. Acute pancreatitis during pregnancy. *Clin Gastroenterol Hepatol* 2010; **8**: 85-90 [PMID: 19747985 DOI: 10.1016/j.cgh.2009.08.035]
- 9 Neill AM, Hackett GA, Overton C, Byrne CD. Active management of acute hyperlipidaemic pancreatitis in pregnancy. *J Obstet Gynaecol* 1998; **18**: 174-175 [PMID: 15512042]
- 10 Eddy JJ, Gideonsen MD, Song JY, Grobman WA, O'Halloran P. Pancreatitis in pregnancy. *Obstet Gynecol* 2008; **112**: 1075-1081 [PMID: 18978108 DOI: 10.1097/AOG.0b013e318185a032]
- 11 Sahu S, Raghuvanshi S, Bahl DV, Sachan P. Acute Pancreatitis In Pregnancy. *Int J Surg* 2006; **11**: Number 2 [DOI: 10.5580/1630]
- 12 Gürsoy A, Kulaksizoglu M, Sahin M, Ertugrul DT, Ozer F, Tutuncu NB, Demirag NG. Severe hypertriglyceridemia-induced pancreatitis during pregnancy. *J Natl Med Assoc* 2006; **98**: 655-657 [PMID: 16623082]
- 13 Stimac D, Stimac T. Acute pancreatitis during pregnancy. *Eur J Gastroenterol Hepatol* 2011; **23**: 839-844 [PMID: 21795982 DOI: 10.1097/MEG.0b013e328349b199]
- 14 May GR, Shaffer EH. Should elective endoscopic sphincterotomy replace cholecystectomy for the treatment of high-risk patients with gallstone pancreatitis? *J Clin Gastroenterol* 1991; **13**: 125-128 [PMID: 2033219]
- 15 Akcakaya A, Ozkan OV, Okan I, Kocaman O, Sahin M. Endoscopic retrograde cholangiopancreatography during pregnancy without radiation. *World J Gastroenterol* 2009; **15**: 3649-3652 [PMID: 19653343 DOI: 10.3748/wjg.15.3649]
- 16 Sun Y, Fan C, Wang S. Clinical analysis of 16 patients with acute pancreatitis in the third trimester of pregnancy. *Int J Clin Exp Pathol* 2013; **6**: 1696-1701 [PMID: 23923092]

P- Reviewer: Cosen-Binker LI, Esrefoglu M, Shehata MMM  
S- Editor: Ma YJ L- Editor: Wang TQ E- Editor: Zhang DN







Published by **Baishideng Publishing Group Inc**

8226 Regency Drive, Pleasanton, CA 94588, USA

Telephone: +1-925-223-8242

Fax: +1-925-223-8243

E-mail: [bpgoffice@wjgnet.com](mailto:bpgoffice@wjgnet.com)

Help Desk: <http://www.wjgnet.com/esps/helpdesk.aspx>

<http://www.wjgnet.com>



ISSN 1007-9327

