

Appropriate kidney stone size for ureteroscopic lithotripsy: When to switch to a percutaneous approach

Ryoji Takazawa, Sachi Kitayama, Toshihiko Tsujii

Ryoji Takazawa, Sachi Kitayama, Toshihiko Tsujii, Department of Urology, Tokyo Metropolitan Ohtsuka Hospital, Tokyo 170-8476, Japan

Author contributions: Takazawa R designed research, wrote the paper and generated the figures and tables; Takazawa R, Kitayama S and Tsujii T performed the research and data analysis. Tsujii T contributed to this work as a supervisor.

Conflict-of-interest: The authors declare that they have no competing interests.

Open-Access: This article is an open-access article which was selected by an in-house editor and fully peer-reviewed by external reviewers. It is distributed in accordance with the Creative Commons Attribution Non Commercial (CC BY-NC 4.0) license, which permits others to distribute, remix, adapt, build upon this work non-commercially, and license their derivative works on different terms, provided the original work is properly cited and the use is non-commercial. See: <http://creativecommons.org/licenses/by-nc/4.0/>

Correspondence to: Ryoji Takazawa, MD, PhD, Chief, Department of Urology, Tokyo Metropolitan Ohtsuka Hospital, 2-8-1 Minami-Ohtsuka, Toshima-ku, Tokyo 170-8476, Japan. ryoji_takazawa@tmhp.jp
Telephone: +81-3-39413211

Fax: +81-3-39416347

Received: June 25, 2014

Peer-review started: June 26, 2014

First decision: September 3, 2014

Revised: September 29, 2014

Accepted: November 27, 2014

Article in press: December 1, 2014

Published online: February 6, 2015

Abstract

Flexible ureteroscopy (fURS) has become a more effective and safer treatment for whole upper urinary tract stones. Percutaneous nephrolithotomy (PNL) is currently the first-line recommended treatment for large kidney stones ≥ 20 mm and it has an excellent stone-free rate for large kidney stones. However, its invasiveness is not negligible considering its major complication rates. Staged fURS is a practical treatment

for such large kidney stones because fURS has a minimal blood transfusion risk, short hospitalization and few restrictions on daily routines. However, as the stone size becomes larger, the stone-free rate decreases, and the number of operations required increases. Therefore, in our opinion, staged fURS is a practical option for kidney stones 20 to 40 mm. Miniaturized PNL combined with fURS should be considered to be a preferred option for stones larger than 40 mm. Moreover, URS is an effective treatment for multiple upper urinary tract stones. Especially for patients with a stone burden < 20 mm, URS is a favorable option that promises a high stone-free rate after a single session either unilaterally or bilaterally. However, for patients with a stone burden ≥ 20 mm, a staged operation should be considered to achieve stone-free status.

Key words: Ureteroscopy; Lithotripsy; Laser; Kidney calculi; Nephrostomy; Percutaneous

© The Author(s) 2015. Published by Baishideng Publishing Group Inc. All rights reserved.

Core tip: Flexible ureteroscopy (fURS) has become a more effective treatment for large and multiple kidney stones. However, as the stone size becomes larger, the stone-free rate decreases, and the number of operations required increases. We herein review the appropriate kidney stone size for ureteroscopic lithotripsy and for situations when it should be combined with percutaneous surgery. In our opinion, staged fURS is a practical option for stones 20 to 40 mm. Miniaturized percutaneous nephrolithotomy combined with fURS should be considered to be a preferred option for stones larger than 40 mm.

Takazawa R, Kitayama S, Tsujii T. Appropriate kidney stone size for ureteroscopic lithotripsy: When to switch to a percutaneous approach. *World J Nephrol* 2015; 4(1): 111-117 Available from: URL: <http://www.wjgnet.com/2220-6124/full/v4/i1/111.htm>

INTRODUCTION

The technical developments and patient requests for rapid stone removal have led to changes in clinical stone management. In the past 30 years, kidney stone treatment has shifted from open surgery to percutaneous surgery, and this has almost been replaced by shock wave lithotripsy (SWL). However, during the last decade, the limitations of SWL for some situations have become evident, and flexible ureteroscopy (fURS) has become more available. The demand for imperative complete stone removal has led to a shift toward endourology. The fURS and related instruments are still evolving. This evolution has made it possible to treat urinary stones in all locations, while decreasing the morbidity associated with the active intervention. However, as the stone size become larger, the stone-free rate of fURS monotherapy decreases, and the number of operations required increases. A percutaneous approach should be considered preferentially for larger stones. In this review, we discuss the possibilities and limitations of ureteroscopic lithotripsy in terms of the kidney stone size and stone number.

INDICATION FOR ACTIVE TREATMENT OF KIDNEY STONES

In general, there is a consensus that small stones may be treated with conservative management. In contrast to ureteral stone, most kidney stones are asymptomatic. It is questionable for small stones, especially in the lower pole, if treatment is required. The natural history and the risk of progression of such kidney stones have not been well evaluated. However, stone growth, potential obstruction, associated infection and pain are clear indications for the treatment of such kidney stones. Several authors have reported a significant rate of incidents during the follow-up of kidney stones (Table 1). For example, Glowacki *et al*^[1] have reported that symptomatic events developed in 31.8% of patients, and spontaneous passage occurred in 15.0%, while surgical interventions were required in 16.8%. Burgher *et al*^[2] reported that 77% of asymptomatic kidney stones became larger, and 26% required surgical intervention. Hübner *et al*^[3] reported that an infection developed in 68% of asymptomatic kidney stones, and 45% had become larger after 7.4 years of follow-up. They also suggested that 83% of kidney stones require surgical intervention within the first five years after the diagnosis. Inci *et al*^[4] observed that 33.3% of lower pole kidney stones had become larger within 52.3 mo of follow-up, while only 11% required surgical intervention. In a prospective randomized controlled trial with a 2.2-year of follow-

up, Keeley *et al*^[5] reported that there is no significant difference between SWL and observation, when they compared with asymptomatic kidney stones < 15 mm regarding the stone-free rate, symptoms, requirement of intervention, and renal function. Although some authors recommended prophylactic treatment for these asymptomatic kidney stones, conflicting data have been reported about the issue^[6]. Other indications for active removal of kidney stones are shown in Table 2.

URETEROSCOPIC LITHOTRIPSY FOR LARGE KIDNEY STONES

Percutaneous nephrolithotomy (PNL) is currently the first-line recommended treatment for large kidney stones ≥ 20 mm^[7,8]. PNL yields an excellent stone-free rate for large kidney stones. However, its invasiveness is not negligible due to its considerable major complication rates. The puncture and dilation of a nephrostomy tract, although it is an essential process in PNL, may induce renal parenchymal damage, blood loss, or visceral injury. A recent global study of PNL reported the major complication rates, which included significant bleeding in 7.8%, renal pelvis perforation in 3.4%, and hydrothorax in 1.8%^[9]. Blood transfusions were necessary in 5.7% of the patients. Postoperative high-grade fever occurred in 10.5%. The conventional prone position during the surgery may induce the respiratory problems.

Recently, fURS has become an effective treatment for kidney stones throughout all renal calyces. URS is an endoscopic surgery performed through the natural orifice. Thus, renal parenchymal damage is unlikely after URS^[10]. The flexible ureteroscopes and their peripheral equipment have rapidly improved over the past few years. URS with holmium laser lithotripsy yields a same or better outcome than SWL for ureteral stones, as well as small kidney stones^[7,8]. Some authors have reported the treatment outcomes of fURS for large kidney stones. For example, Grasso *et al*^[11] reported their treatment outcomes of 45 patients with kidney stones larger than 20 mm, with a 76% stone-free rate after the first session of fURS. Second sessions were needed in 15 patients, and the stone-free rate increased to 91% without major complications. This primary remarkable result was supported by additional studies with similar findings^[10,12-15]. We summarized the results of the updated studies in Table 3. For larger stones (> 20 mm), fURS monotherapy has achieved an excellent stone-free rate, although its outcome depends on the operator's skills and it may require staged procedures.

We previously reported the treatment outcome of large kidney stones (mean cumulative stone diameter: 31 mm) with an overall 90% stone-free rate after a mean 1.4 session of fURS^[10]. In particular, we satisfactorily achieved a 100% stone-free rate in a cohort of

Table 1 Natural history of asymptomatic kidney stones

Ref.	Study type	No. of patients	Follow-up	Disease progression (stone growth)	Symptomatic episode	Need for intervention
Glowacki <i>et al</i> ^[11]	Retrospective	107	31.6 mo	NA	31.8%	16.8%
Hübner <i>et al</i> ^[13]	Retrospective	80	7.4 yr	45%	68%	83%
Keeley <i>et al</i> ^[5]	Randomized prospective	200	2.2 yr	NA	21%	10%
Burgher <i>et al</i> ^[2]	Retrospective	300	3.26 yr	77%	NA	26%
Inci <i>et al</i> ^[4]	Retrospective	24	52.3 mo	33.3%	41.7%	11%

NA: Not available.

Table 2 Indications for active stone removal of kidney stones

Kidney stones
Stone growth
Patients at high risk for stone formation
Obstruction caused by stones
Infection
Symptomatic stones (<i>e.g.</i> , pain, macrohematuria)
Stones ≥ 15 mm
Stones < 15 mm, if observation is not the option of choice
Patient preference
Comorbidity
Social situation of the patient (<i>e.g.</i> , profession or travelling)

14 patients with kidney stones 20–40 mm, that included 64% (9/14) of cases with complete stone-free status. Our overall stone-free rate is favorable and equal to that of PNL. In our study, three patients (15%) developed a high-grade fever after the surgery. One patient with a struvite stone developed sepsis after the first session. It is impossible to completely avoid postoperative infections because the bacteria spread into the irrigation fluid during the surgery. Thus, surgeon should make an effort not to push up the intrarenal pressure and to keep the proper drainage flow, as well as the administration of antibiotics^[10]. In our opinion, too long operation also apparently increases complication rates. When the operation time goes over 120 min, we usually terminate the surgery and retry the next session. This strategy was supported by a recent report which analyzed large patient cohort from a Japanese nationwide database. The authors suggested that longer operation time (> 90 min) increased the risk of complication^[16].

Consequently, staged fURS is a practical option for the treatment of large kidney stones. Staged fURS has little blood transfusion risk, and is associated with a short hospitalization and few restrictions on daily routines. Moreover, the latest digital ureteroscopes, whose image quality is excellent, can promise better treatment outcome^[17]. However, as the stone size becomes larger, the stone-free rate of fURS monotherapy decreases, and the number of operations increases. In our study, the stone-free rate for kidney stones > 40 mm dropped down to 67% after a mean 1.8 session, compared with a 100% stone-free rate for stones 20–40 mm after a mean 1.3 session^[10]. Therefore, in our opinion, the percutaneous approach should be considered to be a preferred option for stones larger than 40 mm.

MINI-PERCUTANEOUS NEPHROLITHOTOMY COMBINED WITH FLEXIBLE URETEROSCOPY

Kidney stones larger than 40 mm should be treated primarily by PNL. In recent years, the new surgical technique named as “miniperc-PNL (mini-PNL)” or “tubeless PNL,” which utilizes a smaller nephrostomy tract (≤ 18 Fr), was developed. It is expected to prevent the major complications which frequently occurred in conventional standard-PNL (24–30 Fr). Jackman *et al*^[18] reported the efficacy of a 13 Fr “miniperc” technique using a ureteroscopy sheath for nine adult patients. They concluded that the “miniperc” can offer advantages associated with hemorrhage, postoperative pain and the hospital stays. This report has been supported by several experts^[19–23]. Knoll *et al*^[23] evaluated the outcome of standard-(26 Fr) vs mini-PNL (18 Fr). They reported a prospective, nonrandomized series of consecutive 50 patients with a solitary kidney stone (lower pole or renal pelvis). After mini-PNL, if uncomplicated, the patients was not left a nephrostomy. Alternatively, a double-J catheter was placed antegradely and the nephrostomy tract was closed with thrombin-matrix. After standard-PNL, all patients were left 22 Fr nephrostomies. While the stone-free rates were comparable (mini-PNL, 96% vs standard-PNL, 92%), mini-PNL showed the advantages of a shorter hospital stay and less postoperative pain. Although the benefits of mini-PNL are still controversial^[24], this new less-invasive type of PNL can replace standard PNL for the treatment of large kidney stones, as well as complete staghorn stones. In addition, ultra-mini PNL (11–13 Fr) and micro-PNL (4.85 Fr) were developed and reported their effectiveness of the treatment for 10–20 mm sized kidney stone by some experts^[25,26]. These new developed miniaturized PNL are expected to be new standard treatment options.

Furthermore, the simultaneous approach with fURS and PNL in the Galdakao-modified supine Valdivia (GMSV) position has been reported. The double approach (retrograde and antegrade) is expected to be superior to a single antegrade approach with PNL^[27,28]. The advantages of the GMSV position enables the good versatility of stone manipulation along the whole upper urinary tract. The GMSV position can make use of combined or subsequent transurethral and percutaneous access to the urinary tract. The GMSV

Table 3 Treatment outcomes of ureteroscopy for large kidney stones

Ref	Study type	No. of patients	Mean stone diameter	Mean number of operation	SFR after the 1 st operation	SFR after the 2 nd operation
Ricchiuti <i>et al</i> ^[12]	Single center, retrospective	23	3.1 cm	1.43	56.5%	73.9%
Breda <i>et al</i> ^[13]	Single center, retrospective	15	2.2 cm	2.3	60%	86.6%
Riley <i>et al</i> ^[14]	Single center, retrospective	22	3.0 cm	1.82	23%	86.4%
Hyams <i>et al</i> ^[15]	Multi center, retrospective	120	2.4 cm	1.18	83%	97.5%
Takazawa <i>et al</i> ^[10]	Single center, retrospective	20	3.1 cm	1.4	65%	95%

SFR: Stone free rate.

position does not need to change the patient position. Also, it provides better descending drainage, retrieval of the stone fragments from percutaneous tract, and decompression of the intrarenal pressure. Scoffone *et al*^[27] reported their experiences with 127 patients who were treated by a simultaneous approach with fURS and standard-PNL (ECIRS: Endoscopic Combined Intra-Renal Surgery) in the GMSV position. The tract was conventionally dilated to 24 Fr or 30 Fr. The mean length of the operation was 70 (range 25-225) min. The stone-free rate was 81.9% after the first session and 87.4% after the second session. Although the overall complication rate was relatively high (38.6%), there was no visceral injury and no anesthetic problems. The anatomical changes related to the supine position do not increase the risk of PNL complications. Although there were some difficulties in the surgeon's manipulations, which are associated with the longer access tract and more limited access field, supine PNL may have some benefits over prone PNL.

A synchronous approach with fURS and mini-PNL (ECIRS) has been suggested to be useful. Hamamoto *et al*^[29] reported their treatment outcomes of mini-ECIRS (in the prone split-leg position), mini-PNL (18 Fr tract) and conventional standard-PNL (30 Fr tract). Although their study was nonrandomized and the patient position was prone, the stone-free rate of mini-ECIRS (81.7%) was superior to mini-PNL (38.9%) and standard-PNL (45.1%). Blood loss during the surgery was significantly lower in mini-ECIRS and mini-PNL than standard-PNL. Mini-ECIRS has a good versatility and will be an effective treatment for large kidney stones.

URETEROSCOPIC LITHOTRIPSY FOR MULTIPLE KIDNEY STONES

From some reports describing the outcome of SWL, about 20%-25% patients have multiple stones^[30-32]. The stone-free rates after SWL for multiple stones are significantly lower than for a single stone, which dropped down from 70% to only 40%^[30]. Many authors reported that the stone number was a significant predictor for the stone-free rates after SWL in their multivariate analyses^[8,30-34]. In recent years, URS has been demonstrated its effectiveness and safety for upper urinary tract stones, and the indication has been expanding^[35-37]. URS can

directly access to the target stones throughout the whole upper urinary tract, regardless of laterality, and actively clear away the stone fragments^[38]. This is a great advantage of URS superior to SWL. Therefore, URS may be an ideal treatment for multiple stones that promises a higher stone-free rate than SWL after a single surgery.

As well as fURS, SWL has been considered to be a recommended treatment for small to intermediate kidney stones^[8]. The SWL has some advantages: good patient's acceptance, short convalescence, and little need of anesthesia during the treatment. However, the outcome of SWL is susceptible to many factors: stone size, stone position, stone composition, and the distance from skin to stone^[30-34]. Particularly, the "multiple stones" is a strong unfavorable factor that impacts on the stone-free rates as well as recurrence-free rates after the treatment. Abe *et al*^[30] described in their large cohort study that the stone-free rates after SWL for multiple stones dropped down to 41% compared with 71% for solitary stone. The "multiple stones" was the strongest adverse factor for stone recurrence in their analyses.

PNL is another treatment option for multiple kidney stones. Multiple kidney stones sometimes grow larger in different calices. In such cases, multiple percutaneous tracts are needed for access to the target stones. However, multiple percutaneous tracts may induce blood transfusion risk and the patient's discomfort^[39,40].

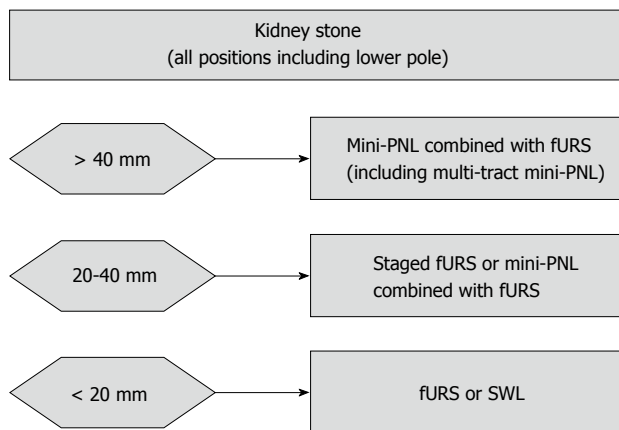
Flexible ureteroscopes and their peripheral equipments have rapidly improved over the past few years. Nowadays, fURS yields a same or better outcome than SWL for kidney stones^[8,36]. In comparison with SWL or PNL, fURS has some advantages for the treatment of multiple kidney stones. The various shaped nitinol baskets enable the removal of stone fragments safely. After the removal of one stone, we can continue the fragmentation of the next stones. Moreover, the latest flexible ureteroscopes and the smallest laser fiber can access to the lower calyx, where the spontaneous passage of residual fragments are hardly expected after SWL. Also, fURS can approach to bilateral upper urinary tract in a single operation^[41,42].

There have been some studies of the management of multiple kidney stones by ureteroscopy^[43-45]. We summarized the outcomes of the previous reports in Table 4. Breda *et al*^[43] studied the results of 51 patients who had multiple unilateral kidney stones. The mean stone number was 3.1 and the mean stone length was

Table 4 Treatment outcomes of ureteroscopy for multiple kidney stones

Ref	Study type	No. of patients	Mean number of stones	Mean number of operation	SFR after the 1 st operation	SFR after the 2 nd operation
Breda <i>et al</i> ^[43]	Single center, retrospective, unilateral kidney	51	3.1	1.4	64.7%	92.2%
Herrera-Gonzalez <i>et al</i> ^[44]	Single center, retrospective, unilateral kidney	125	3.59	1	74.4%	NA
Huang <i>et al</i> ^[45]	Single center, retrospective, bilateral kidney	25	5.1	1.5	50%	92%

SFR: Stone free rate.

**Figure 1 Our proposed treatment algorithm for kidney stones.** fURS: Flexible ureteroscopy; PNL: Percutaneous nephrolithotomy; SWL: Shock wave lithotripsy.

6.6 mm. The mean stone burden (cumulative stone length) was 21 mm. The overall stone-free rate was 92.2%, with a mean number of sessions of 1.4. The stone-free rate after one and two sessions in patients with a stone burden ≤ 20 mm was 79% and 100%, respectively, compared with 52% and 85% in patients with a stone burden > 20 mm. Complications occurred in seven patients (13.6%) including intraoperative bleeding in one, postoperative pyelonephritis in one and a urinary tract infection in three patients.

Herrera-Gonzalez *et al*^[44] studied the results of 125 patients with multiple unilateral kidney stones. The mean stone number was 3.59. The mean cumulative stone length was 11.93 mm, and the mean cumulative stone surface was 83.7 mm². The overall stone-free rates after a single session was 74.4%. The stone-free rates in patients with a cumulative stone surface ≥ 100 mm² was 65.4%, compared with 79.5% in patients < 100 mm². Complications occurred in seven patients (5.6%), including urinary tract infections in four, hematuria in two patients, and ureteral perforation in one. The authors concluded that ureteroscopic lithotripsy for multiple kidney stones was an effective treatment.

We also reported the results of 51 patients with multiple stones, although we included both kidney and ureteral stones, either unilaterally or bilaterally, into the study cohort^[38]. Our results were equivalent to those in Breda's reports^[43]. In our study, the "stone burden" and the presence of "impacted stones" can significantly predict the stone-free rate after the first session of

URS, whereas the "stone location" did not significantly influence the outcome. Due to the "impacted stones", if the ureteral mucosa was severely damaged during the procedure, we terminate the surgery in order to prevent a postoperative ureteral stricture. We always place a double-J stent to arrange for the next operation. At the next operation, the access to the residual stones usually becomes easier due to the spontaneous dilation of the ureter by stenting. In our study, we performed same session bilateral URS. We achieved 86% stone-free status after same session bilateral URS with no complication. Some experts have reported the effectiveness of same session bilateral URS^[41,42]. Our results supported the adequacy of a same session bilateral URS as a considerable option for bilateral stones when it is performed at the experienced institutions.

We also analyzed our surgical data regarding stone burden^[38]. Overall, the mean number of sessions was 1.3, the mean total operative time was 112 min, and stone-free rate after one and two sessions was 80.4% and 92.2%, respectively. The 25 patients with a stone burden < 20 mm had smaller number of sessions, shorter operative time, and higher stone-free rate after the first session than the 26 patients with a stone burden ≥ 20 mm.

Consequently, fURS is an effective option for multiple stones. Especially for patients with a stone burden < 20 mm, fURS is a favorable option that promises a high stone-free rate after a single session, either unilaterally or bilaterally. However, for patients with a stone burden ≥ 20 mm, a staged operation should be considered to achieve stone-free status.

CURRENT PROPOSAL FOR ACTIVE REMOVAL OF KIDNEY STONES

Figure 1 shows our proposed treatment algorithm for kidney stones. We select the treatment option with no distinction regarding the stone position (upper/middle pole or lower pole), because the current fURS instruments can easily reach to the all calyces, including the lower calyx, and can clear away the stone fragments by using a basket. Basically, we recommend endoscopic treatment for kidney stones, because residual fragments after SWL frequently do not pass spontaneously and often lead the stone recurrence. Besides, stones composed of calcium oxalate monohydrate, brushite, or cystine are usually resistant to SWL^[8]. Depending on the operator's skills

and the stone shape/position/component, stones up to 40 mm can be treated sufficiently by fURS monotherapy, although staged operations may be required. We also recommend using a combination of PNL and fURS for larger stones, especially for staghorn stones, because the fURS can access each calyx, where the percutaneous antegrade approach is difficult. This is associated with a major advantage in terms of clearing the stone burden. Multi-tract PNL has also been evaluated by experts, who reported successful outcomes. However, multi-tract procedures may cause more complications, but if necessary, should be considered for appropriate cases^[39,40]. Most upper urinary tract stones should be treated primarily by PNL, URS, SWL or a combination of these techniques. Thus, open or laparoscopic surgery may be a valid primary option in selected cases (*e.g.*, complex stone burden, treatment failed case, anatomical abnormal case.). Recently, the effectiveness of laparoscopic pyelolithotomy for large renal pelvic stone was reported, although further evaluation should be needed^[46,47].

CONCLUSION

For large kidney stones, staged fURS is a practical treatment. Staged fURS has little blood transfusion risk, and is associated with a minimal risk of needing a blood transfusion, a short hospitalization and few restrictions on daily routines. However, as the stone size becomes larger, the stone-free rate of fURS monotherapy decreases, and the number of operations increases. Therefore, in our opinion, PNL should be considered to be a preferred option for stones larger than 40 mm. In addition, URS is an effective option for multiple stones. Especially for patients with a stone burden < 20 mm, URS is a favorable option that promises a high stone-free rate after a single session, either unilaterally or bilaterally.

REFERENCES

- 1 **Glowacki LS**, Beecroft ML, Cook RJ, Pahl D, Churchill DN. The natural history of asymptomatic urolithiasis. *J Urol* 1992; **147**: 319-321 [PMID: 1732583]
- 2 **Burgher A**, Beman M, Holtzman JL, Monga M. Progression of nephrolithiasis: long-term outcomes with observation of asymptomatic calculi. *J Endourol* 2004; **18**: 534-539 [PMID: 15333216 DOI: 10.1089/end.2004.18.534]
- 3 **Hübner W**, Porpacz P. Treatment of caliceal calculi. *Br J Urol* 1990; **66**: 9-11 [PMID: 2393803 DOI: 10.1111/j.1464-410X.1990.tb14854.x]
- 4 **Inci K**, Sahin A, Islamoglu E, Eren MT, Bakkaloglu M, Ozen H. Prospective long-term followup of patients with asymptomatic lower pole caliceal stones. *J Urol* 2007; **177**: 2189-2192 [PMID: 17509315]
- 5 **Keeley FX**, Tilling K, Elves A, Menezes P, Wills M, Rao N, Feneley R. Preliminary results of a randomized controlled trial of prophylactic shock wave lithotripsy for small asymptomatic renal calyceal stones. *BJU Int* 2001; **87**: 1-8 [PMID: 11121982 DOI: 10.1046/j.1464-410x.2001.00781.x]
- 6 **Collins JW**, Keeley FX. Is there a role for prophylactic shock wave lithotripsy for asymptomatic calyceal stones? *Curr Opin Urol* 2002; **12**: 281-286 [PMID: 12072647 DOI: 10.1097/00042307-200207000-00004]
- 7 **Lingeman J**, Matlaga B, Evan A. Surgical management of upper urinary tract calculi. In: Wein AJ, Kavoussi LR, Novick AC, Partin AW, Peters CA, editors. *Cambell-Walsh Urology*. 9th ed. Philadelphia: Saunders Elsevier, 2007: 1437-1438
- 8 **Türk C**, Knoll T, Petrik A, Sarica K, Straub M, Skolarikos A, Seitz C. Guidelines on urolithiasis. Arnheim, The Netherlands: European Association of Urology (EAU), 2014
- 9 **de la Rosette J**, Assimos D, Desai M, Gutierrez J, Lingeman J, Scarpa R, Tefekli A. The Clinical Research Office of the Endourological Society Percutaneous Nephrolithotomy Global Study: indications, complications, and outcomes in 5803 patients. *J Endourol* 2011; **25**: 11-17 [PMID: 21247286 DOI: 10.1089/end.2010.0424]
- 10 **Takazawa R**, Kitayama S, Tsujii T. Successful outcome of flexible ureteroscopy with holmium laser lithotripsy for renal stones 2 cm or greater. *Int J Urol* 2012; **19**: 264-267 [PMID: 22145599 DOI: 10.1111/j.1442-2042.2011.02931.x]
- 11 **Grasso M**, Conlin M, Bagley D. Retrograde ureteropyeloscopic treatment of 2 cm. or greater upper urinary tract and minor Staghorn calculi. *J Urol* 1998; **160**: 346-351 [PMID: 9679874]
- 12 **Ricchiuti DJ**, Smaldone MC, Jacobs BL, Smaldone AM, Jackman SV, Averch TD. Staged retrograde endoscopic lithotripsy as alternative to PCNL in select patients with large renal calculi. *J Endourol* 2007; **21**: 1421-1424 [PMID: 18186677 DOI: 10.1089/end.2007.9871]
- 13 **Breda A**, Ogunyemi O, Leppert JT, Lam JS, Schulam PG. Flexible ureteroscopy and laser lithotripsy for single intrarenal stones 2 cm or greater--is this the new frontier? *J Urol* 2008; **179**: 981-984 [PMID: 18207179 DOI: 10.1016/j.juro.2007.10.083]
- 14 **Riley JM**, Stearman L, Troxel S. Retrograde ureteroscopy for renal stones larger than 2.5 cm. *J Endourol* 2009; **23**: 1395-1398 [PMID: 19694527 DOI: 10.1089/end.2009.0391]
- 15 **Hyams ES**, Munver R, Bird VG, Uberoi J, Shah O. Flexible ureterorenoscopy and holmium laser lithotripsy for the management of renal stone burdens that measure 2 to 3 cm: a multi-institutional experience. *J Endourol* 2010; **24**: 1583-1588 [PMID: 20629566 DOI: 10.1089/end.2009.0629]
- 16 **Sugihara T**, Yasunaga H, Horiguchi H, Nishimatsu H, Kume H, Ohe K, Matsuda S, Fushimi K, Homma Y. A nomogram predicting severe adverse events after ureteroscopic lithotripsy: 12372 patients in a Japanese national series. *BJU Int* 2013; **111**: 459-466 [PMID: 23253797 DOI: 10.1111/j.1464-410X.2012.11594.x]
- 17 **Humphreys MR**, Miller NL, Williams JC, Evan AP, Munch LC, Lingeman JE. A new world revealed: early experience with digital ureteroscopy. *J Urol* 2008; **179**: 970-975 [PMID: 18207196 DOI: 10.1016/j.juro.2007.10.073]
- 18 **Jackman SV**, Docimo SG, Cadeddu JA, Bishoff JT, Kavoussi LR, Jarrett TW. The "mini-perc" technique: a less invasive alternative to percutaneous nephrolithotomy. *World J Urol* 1998; **16**: 371-374 [PMID: 9870281 DOI: 10.1007/s003450050083]
- 19 **Chan DY**, Jarrett TW. Mini-percutaneous nephrolithotomy. *J Endourol* 2000; **14**: 269-272; discussion 272-273 [PMID: 10795617 DOI: 10.1089/end.2000.14.269]
- 20 **Monga M**, Oglevie S. Minipercutaneous nephrolithotomy. *J Endourol* 2000; **14**: 419-421 [PMID: 10958563]
- 21 **Traxer O**, Smith TG, Pearle MS, Corwin TS, Saboorian H, Cadeddu JA. Renal parenchymal injury after standard and mini percutaneous nephrostolithotomy. *J Urol* 2001; **165**: 1693-1695 [PMID: 11342957]
- 22 **Desai MR**, Kukreja RA, Desai MM, Mhaskar SS, Wani KA, Patel SH, Bapat SD. A prospective randomized comparison of type of nephrostomy drainage following percutaneous nephrostolithotomy: large bore versus small bore versus tubeless. *J Urol* 2004; **172**: 565-567 [PMID: 15247731 DOI: 10.1097/01.ju.0000130752.97414.c8]
- 23 **Knoll T**, Wezel F, Michel MS, Honeck P, Wendt-Nordahl G. Do patients benefit from miniaturized tubeless percutaneous nephrolithotomy? A comparative prospective study. *J Endourol* 2010; **24**: 1075-1079 [PMID: 20575685 DOI: 10.1089/end.2010.0111]
- 24 **Giusti G**, Piccinelli A, Taverna G, Benetti A, Pasini L, Corinti M,

- Teppa A, Zandegiacomo de Zorzi S, Graziotti P. Miniperc? No, thank you! *Eur Urol* 2007; **51**: 810-814; discussion 815 [PMID: 16938385 DOI: 10.1016/j.eururo.2006.07.047]
- 25 **Desai MR**, Sharma R, Mishra S, Sabnis RB, Stief C, Bader M. Single-step percutaneous nephrolithotomy (microperc): the initial clinical report. *J Urol* 2011; **186**: 140-145 [PMID: 21575966 DOI: 10.1016/j.juro.2011.03.029]
- 26 **Desai J**, Solanki R. Ultra-mini percutaneous nephrolithotomy (UMP): one more armamentarium. *BJU Int* 2013; **112**: 1046-1049 [PMID: 23841665 DOI: 10.1111/bju.12193]
- 27 **Scoffone CM**, Cracco CM, Cossu M, Grande S, Poggio M, Scarpa RM. Endoscopic combined intrarenal surgery in Galdakao-modified supine Valdivia position: a new standard for percutaneous nephrolithotomy? *Eur Urol* 2008; **54**: 1393-1403 [PMID: 18715696 DOI: 10.1016/j.eururo.2008.07.073]
- 28 **Daels F**, González MS, Freire FG, Jurado A, Damia O. Percutaneous lithotripsy in Valdivia-Galdakao decubitus position: our experience. *J Endourol* 2009; **23**: 1615-1620 [PMID: 19747031 DOI: 10.1089/end.2009.1526]
- 29 **Hamamoto S**, Yasui T, Okada A, Taguchi K, Kawai N, Ando R, Mizuno K, Kubota Y, Kamiya H, Tozawa K, Kohri K. Endoscopic combined intrarenal surgery for large calculi: simultaneous use of flexible ureteroscopy and mini-percutaneous nephrolithotomy overcomes the disadvantageous of percutaneous nephrolithotomy monotherapy. *J Endourol* 2014; **28**: 28-33 [PMID: 23987470 DOI: 10.1089/end.2013.0361]
- 30 **Abe T**, Akakura K, Kawaguchi M, Ueda T, Ichikawa T, Ito H, Nozumi K, Suzuki K. Outcomes of shockwave lithotripsy for upper urinary-tract stones: a large-scale study at a single institution. *J Endourol* 2005; **19**: 768-773 [PMID: 16190825 DOI: 10.1089/end.2005.19.768]
- 31 **Kanao K**, Nakashima J, Nakagawa K, Asakura H, Miyajima A, Oya M, Ohigashi T, Murai M. Preoperative nomograms for predicting stone-free rate after extracorporeal shock wave lithotripsy. *J Urol* 2006; **176**: 1453-1456; discussion 1456-1457 [PMID: 16952658 DOI: 10.1016/j.juro.2006.06.089]
- 32 **Abdel-Khalek M**, Sheir KZ, Mokhtar AA, Eraky I, Kenawy M, Bazeed M. Prediction of success rate after extracorporeal shock-wave lithotripsy of renal stones--a multivariate analysis model. *Scand J Urol Nephrol* 2004; **38**: 161-167 [PMID: 15204407 DOI: 10.1080/00365590310022626]
- 33 **Cass AS**. Comparison of first generation (Dornier HM3) and second generation (Medstone STS) lithotriptors: treatment results with 13,864 renal and ureteral calculi. *J Urol* 1995; **153**: 588-592 [PMID: 7861488]
- 34 **El-Assmy A**, El-Nahas AR, Abo-Elghar ME, Eraky I, El-Kenawy MR, Sheir KZ. Predictors of success after extracorporeal shock wave lithotripsy (ESWL) for renal calculi between 20-30 mm: a multivariate analysis model. *ScientificWorldJournal* 2006; **6**: 2388-2395 [PMID: 17619706 DOI: 10.1100/tsw.2006.370]
- 35 **Galvin DJ**, Pearle MS. The contemporary management of renal and ureteric calculi. *BJU Int* 2006; **98**: 1283-1288 [PMID: 17125486 DOI: 10.1111/j.1464-410X.2006.06514.x]
- 36 **Anagnostou T**, Tolley D. Management of ureteric stones. *Eur Urol* 2004; **45**: 714-721 [PMID: 15149742 DOI: 10.1016/j.eururo.2003.10.018]
- 37 **Takazawa R**, Kitayama S, Kobayashi S, Araki S, Waseda Y, Hyochi N, Tsujii T. [Transurethral lithotripsy with rigid and flexible ureteroscopy for renal and ureteral stones: results of the first 100 procedures]. *Hinyokika Kiyo* 2011; **57**: 411-416 [PMID: 21894076]
- 38 **Takazawa R**, Kitayama S, Tsujii T. Single-session ureteroscopy with holmium laser lithotripsy for multiple stones. *Int J Urol* 2012; **19**: 1118-1121 [PMID: 22853010 DOI: 10.1111/j.1442-2042.2012.03113.x]
- 39 **Desai M**, Ganpule A, Manohar T. "Multiperc" for complete staghorn calculus. *J Endourol* 2008; **22**: 1831-1833; discussion 1841 [PMID: 18811458 DOI: 10.1089/end.2008.9796]
- 40 **Akman T**, Sari E, Binbay M, Yuruk E, Tepeler A, Kaba M, Muslumanoglu AY, Tefekli A. Comparison of outcomes after percutaneous nephrolithotomy of staghorn calculi in those with single and multiple accesses. *J Endourol* 2010; **24**: 955-960 [PMID: 20443700 DOI: 10.1089/end.2009.0456]
- 41 **Hollenbeck BK**, Schuster TG, Faerber GJ, Wolf JS. Safety and efficacy of same-session bilateral ureteroscopy. *J Endourol* 2003; **17**: 881-885 [PMID: 14744354 DOI: 10.1089/089277903772036190]
- 42 **Watson JM**, Chang C, Pattaras JG, Ogan K. Same session bilateral ureteroscopy is safe and efficacious. *J Urol* 2011; **185**: 170-174 [PMID: 21074793 DOI: 10.1016/j.juro.2010.09.034]
- 43 **Breda A**, Ogunyemi O, Leppert JT, Schulam PG. Flexible ureteroscopy and laser lithotripsy for multiple unilateral intrarenal stones. *Eur Urol* 2009; **55**: 1190-1196 [PMID: 18571315 DOI: 10.1016/j.eururo.2008.06.019]
- 44 **Herrera-Gonzalez G**, Netsch C, Oberhagemann K, Bach T, Gross AJ. Effectiveness of single flexible ureteroscopy for multiple renal calculi. *J Endourol* 2011; **25**: 431-435 [PMID: 21401396 DOI: 10.1089/end.2010.0233]
- 45 **Huang Z**, Fu F, Zhong Z, Zhang L, Xu R, Zhao X. Flexible ureteroscopy and laser lithotripsy for bilateral multiple intrarenal stones: is this a valuable choice? *Urology* 2012; **80**: 800-804 [PMID: 22743260 DOI: 10.1016/j.urology.2012.05.013]
- 46 **Wang X**, Li S, Liu T, Guo Y, Yang Z. Laparoscopic pyelolithotomy compared to percutaneous nephrolithotomy as surgical management for large renal pelvic calculi: a meta-analysis. *J Urol* 2013; **190**: 888-893 [PMID: 23454154 DOI: 10.1016/j.juro.2013.02.092]
- 47 **Li S**, Liu TZ, Wang XH, Zeng XT, Zeng G, Yang ZH, Weng H, Meng Z, Huang JY. Randomized controlled trial comparing retroperitoneal laparoscopic pyelolithotomy versus percutaneous nephrolithotomy for the treatment of large renal pelvic calculi: a pilot study. *J Endourol* 2014; **28**: 946-950 [PMID: 24708300 DOI: 10.1089/end.2014.0064]

P-Reviewer: Soria F, Naselli A **S-Editor:** Tian YL
L-Editor: A **E-Editor:** Liu SQ





Published by **Baishideng Publishing Group Inc**

8226 Regency Drive, Pleasanton, CA 94588, USA

Telephone: +1-925-223-8242

Fax: +1-925-223-8243

E-mail: bpgoffice@wjgnet.com

Help Desk: <http://www.wjgnet.com/esps/helpdesk.aspx>

<http://www.wjgnet.com>

