

Perforation of small bowel caused by *Schistosoma japonicum*: A case report

Jin-Jian Xiang, Ben-Jing Cheng, Fu Tian, Mi Li, Xue-Feng Jiang, Hui-Chuan Zhao, Xiao-Miao Hu, Bao-Lai Xiao, Jian-Ping Xie, Arpana Shrestha

Jin-Jian Xiang, Ben-Jing Cheng, Fu Tian, Mi Li, Xue-Feng Jiang, Xiao-Miao Hu, Bao-Lai Xiao, Jian-Ping Xie, Arpana Shrestha, Department of General Surgery, the First Hospital affiliated to Yangtze University, Jingzhou 434000, Hubei Province, China

Hui-Chuan Zhao, Department of Pathology, the First Hospital Affiliated to Yangtze University, Jingzhou 434000, Hubei Province, China

Author contributions: Xiang JJ and Cheng BJ designed the report; Xiang JJ, Tian F, Li M and Jiang XF performed surgical operation; Hu XM, Xiao BL and Xie JP were attending doctors for the patient; Cheng BJ wrote paper; Zhao HC performed pathological examinations and imaging diagnosis; and Shrestha A polished the article.

Ethics approval: The study was reviewed and approved by the First Hospital affiliated to Yangtze University Institutional Review Board.

Informed consent: All study participants, or their legal guardian, provided informed written consent prior to study enrollment.

Conflict-of-interest: No potential conflicts of interest relevant to this article were reported.

Open-Access: This article is an open-access article which was selected by an in-house editor and fully peer-reviewed by external reviewers. It is distributed in accordance with the Creative Commons Attribution Non Commercial (CC BY-NC 4.0) license, which permits others to distribute, remix, adapt, build upon this work non-commercially, and license their derivative works on different terms, provided the original work is properly cited and the use is non-commercial. See: <http://creativecommons.org/licenses/by-nc/4.0/>

Correspondence to: Ben-Jing Cheng, Nurse-in-Charge, Department of General Surgery, the First Hospital affiliated to Yangtze University, No. 8, Hangkong Road, Shashi District, Jingzhou 434000, Hubei Province, China. 309802903@qq.com
Telephone: +86-716-8115071

Fax: +86-716-8118888

Received: September 22, 2014

Peer-review started: September 23, 2014

First decision: October 29, 2014

Revised: November 26, 2014

Accepted: December 13, 2014

Article in press: December 16, 2014

Published online: March 7, 2015

Abstract

A 67-year-old man from Jingzhou was admitted to the First Hospital Affiliated to Yangtze University in July 2013 with sudden onset of abdominal pain with dizziness for 12 h. The patient had sign of peritoneal irritation. Ultrasonography of the abdomen and pelvis showed hepatic fibrosis due to schistosomiasis. Computed tomography showed free gas in the peritoneal cavity. Plain abdominal radiography showed bilateral subdiaphragmatic accumulation of gas, perforation of the viscus, and radio-opacity in the left renal area. The patient underwent emergency exploratory laparotomy. At laparotomy, a moderate amount of muddy yellow pus was found in the intra-abdominal cavity. At the junction of the jejunum and ileum, about 250 cm from Treitz's ligament, there was an about 10-cm length of inflamed small bowel with perforation (3 mm in diameter) along the mesenteric border at the middle of the lesion. The patient underwent resection of the affected intestinal segment, along with end-to-end intestinal anastomosis. Histopathological examination revealed mucosal necrosis and hemorrhage with a large number of infiltrating eosinophils and neutrophils, and acute submucosal inflammation with a large number of infiltrating eosinophils and neutrophils associated with *Schistosoma japonicum* (*S. japonicum*) eggs. No intravascular adult parasite was found. Postoperatively, the patient was treated with praziquantel (30 mg/kg daily) for 4 d. The patient progressed well. To the best of our knowledge, this is the first case of small bowel perforation associated with eggs of *S. japonicum*.

Key words: *Schistosoma japonicum*; Intestinal perforation; Small bowel

© The Author(s) 2015. Published by Baishideng Publishing Group Inc. All rights reserved.

Core tip: There are rare cases of intestinal perforation

caused by schistosomiasis. When patients living in an endemic area for schistosomiasis develop intestinal perforation, the condition may be caused by *Schistosoma*. We present a case report of a patient from Jingzhou, China with small bowel perforation with peritonitis secondary to infection with *S. japonicum*.

Xiang JJ, Cheng BJ, Tian F, Li M, Jiang XF, Zhao HC, Hu XM, Xiao BL, Xie JP, Shrestha A. Perforation of small bowel caused by *Schistosoma japonicum*: A case report. *World J Gastroenterol* 2015; 21(9): 2862-2864 Available from: URL: <http://www.wjgnet.com/1007-9327/full/v21/i9/2862.htm> DOI: <http://dx.doi.org/10.3748/wjg.v21.i9.2862>

INTRODUCTION

There are 76 countries and regions with schistosomiasis^[1]. Among them, the distribution of *Schistosoma japonicum* (*S. japonicum*) is mainly in Asia, including Japan, the Philippines, Indonesia and China. This schistosome was first discovered in Japan, hence its species name. *Schistosoma haematobium* infection is most prevalent in Africa and Western Asia. *Schistosoma mansoni* is most prevalent in certain tropical and subtropical areas of sub-Saharan Africa, the Middle East, South America, and the Caribbean. China is only endemic for *S. japonicum*. In 1981, *Biomphalaria straminea*, an intermediate host of *S. mansoni* was first discovered in Southern China as an invasive snail species, and its habitation has extended considerably^[2]. There are rare reports of intestinal perforation caused by schistosomiasis. We present a case report of a patient from Jingzhou, China with small bowel perforation with peritonitis secondary to infection with *S. japonicum*.

CASE REPORT

A 67-year-old man from Jingzhou was admitted to the First Hospital Affiliated to Yangtze University in July 2013 with sudden onset of abdominal pain and dizziness for 12 h. The patient had sign of peritoneal irritation. Ultrasonography of the abdomen and pelvis showed hepatic fibrosis due to schistosomiasis. Computed tomography showed free gas in the peritoneal cavity. Plain abdominal radiography showed bilateral subdiaphragmatic accumulation of gas, perforation of the viscus, and radio-opacity in the left renal area. The patient underwent emergency exploratory laparotomy. At laparotomy, a moderate amount of muddy yellow pus was found in the intra-abdominal cavity. At the junction of the jejunum and ileum, about 250 cm from Treitz's ligament, there was an about 10-cm length of inflamed small intestine with perforation (3 mm in diameter) along the mesenteric border at the middle of the lesion. The patient underwent resection of the affected intestinal segment, along with end-to-end intestinal anastomosis. Histopathological examination revealed mucosal necrosis and hemorrhage with a

large number of infiltrating eosinophils and neutrophils (Figure 1A), and submucosal acute inflammation with a large number of infiltrating eosinophils and neutrophils associated with *Schistosoma* eggs (Figure 1B). No intravascular adult parasite was found. IgG for schistosomiasis was positive. Postoperatively, the patient was treated with praziquantel (30 mg/kg daily) for 4 d. The patient progressed well.

DISCUSSION

A review of the literature found four cases of intestinal perforation (excluding the appendix) associated with schistosomiasis: (1) colon perforation associated with *S. japonicum*^[3]; (2) sigmoid perforation associated with *S. mansoni*^[4]; (3) rectal perforation associated with *S. haematobium*^[5]; and (4) jejunal perforation associated with adult worm of *Schistosoma*^[6]. To the best of our knowledge, this is the first case report of small bowel perforation associated with eggs of *S. japonicum*. No intravascular adult parasite was found in this case.

Among the 81 national surveillance sites in China, the average positive rate of residents with serum examinations and average infection rate of the residents were 7.78% and 0.54% respectively and the infection rate of snails was 0.14% in 2011^[7]. From the 64 monitoring sites, in Jingzhou, a city in Central China, the average schistosomal infection rate of residents was 1.48% and the infection rate of snails was 0.08% in 2011^[8]. The snail *Oncomelania hupensis* is the only intermediate host of the parasite *S. japonicum*, which causes human schistosomiasis in East and Southeast Asia. Humans acquire schistosomiasis via contact with freshwater containing infectious, free-living, cercarial larvae. The worms then migrate through the circulation (mainly in the mesenteric vein) affecting the portal system. The main pathological changes are egg granuloma caused by ova, and deposition of eggs in the intestine or liver tissue. Patients develop fever, abdominal pain, bloody diarrhea, hepatomegaly and eosinophilia in the acute phase; chronic diarrhea and hepatosplenomegaly as the main features in the chronic phase; and liver periportal fibrosis with splenomegaly and ascites in the advanced phase. Digestive lesions are most frequently caused by rectal or large bowel involvement.

Some studies have shown that *Schistosoma* is related to appendicitis, and even rupture of the appendix with peritonitis^[9-11]. We consider that the intestinal pathological changes of schistosomiasis are similar to those of appendicitis associated with schistosomiasis. Two pathogenetic pathways^[5] have been described to explain this occurrence with appendicitis. The first pathway considers the role of feces, with their passage through inflammatory and fibrotic mucosa infected with the parasite. The second pathway is a direct inflammatory lesion of the appendix induced by an immunological granulomatous reaction around the parasite eggs, leading to tissue destruction and appendicitis.

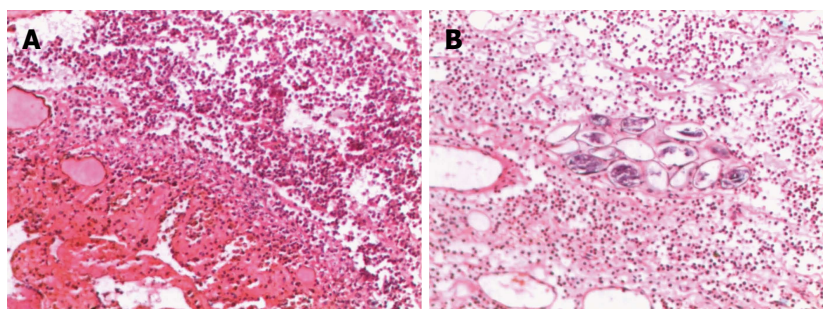


Figure 1 Microscopic images. A: Mucosal necrosis and hemorrhage with large numbers of infiltrating eosinophils and neutrophils (magnification × 400); B: Submucosal acute inflammation with a large number of infiltrating eosinophils and neutrophils associated with *Schistosoma* eggs (magnification × 400).

In our patient, several elements directed us to a diagnosis of small bowel perforation caused by acute infection with *Schistosoma*. The first was the presence of schistosomal eggs without granuloma formation, which indicated active infection. The second was the presence of acute inflammation of the mucosa and submucosa. The third was the presence of mucosal necrosis and hemorrhage. The patient should have a long history of infection with schistosomiasis. The reason was the presence of hepatic fibrosis caused by schistosomiasis shown by ultrasonography.

COMMENTS

Case characteristics

A 67-year-old man presented with abdominal pain and dizziness.

Clinical diagnosis

Upon physical examination, the patient had a sign of peritoneal irritation.

Differential diagnosis

Acute pancreatitis, tuberculous peritonitis, acute ileus, and acute appendicitis.

Laboratory diagnosis

IgG positive for schistosomiasis.

Imaging diagnosis

Computed tomography and plain abdominal radiography showed free gas in the peritoneal cavity.

Pathological diagnosis

Histopathological examination revealed mucosal necrosis and hemorrhage with large numbers of infiltrating eosinophils and neutrophils, and submucosa acute inflammation with a large number of infiltrating eosinophils and neutrophils associated with *Schistosoma* eggs.

Treatment

The patient underwent emergency exploratory laparotomy and resection of the affected intestinal segment along with end-to-end intestinal anastomosis.

Related reports

A review of the literature only found four cases of intestinal perforation (excluding the appendix) associated with schistosomiasis. To the best of our knowledge, this is the first case report of small bowel perforation associated with eggs of *Schistosoma japonicum*.

Term explanation

Schistosoma japonicum (*S. japonicum*) is currently only prevalent in Japan, the Philippines, Indonesia and China. This worm was first discovered in Japan, hence the species name.

Experiences and lessons

In our case, small bowel perforation was caused by *S. japonicum*. In

schistosomiasis endemic areas, this rare etiology needs to be considered in cases of intestinal perforation.

Peer-review

The authors have described a case of perforation of small intestine caused by *Schistosoma japonicum*. The article highlights this rare etiology which should be considered in cases of intestinal perforation in schistosomiasis endemic area.

REFERENCES

- Schistosomiasis: number of people treated in 2009. *Wkly Epidemiol Rec* 2011; **86**: 73-80 [PMID: 21395186]
- Attwood SW, Huo GN, Qiu JW. Update on the distribution and phylogenetics of Biomphalaria (Gastropoda: Planorbidae) populations in Guangdong Province, China. *Acta Trop* 2015; **141**: 258-270 [PMID: 24811366 DOI: 10.1016/j.actatropica.2014.04.032]
- Atik FA, Lopes Filho GJ, Linhares Mde M, Seda Neto J, Mansur NS. Large intestine obstruction complicated with perforation: a rare manifestation of *Schistosoma mansoni* infection. *Sao Paulo Med J* 1998; **116**: 1781-1783 [PMID: 9951750 DOI: 10.1590/S1516-31801998000400008]
- Wu TS, Chen TC, Chen RJ, Chiang PC, Leu HS. *Schistosoma japonicum* infection presenting with colon perforation: case report. *Changcheng Yi Xue Za Zhi* 1999; **22**: 676-681 [PMID: 10695221]
- Argemi X, Camuset G, Abou-Bakar A, Lucescu I, Forestier E, Christmann D, Hansmann Y. Case report: rectal perforation caused by *Schistosoma haematobium*. *Am J Trop Med Hyg* 2009; **80**: 179-181 [PMID: 19190208]
- Singh NG, Mannan AA, Kahvic M, Alanzi FM. Jejunal perforation caused by schistosomiasis. *Trop Doct* 2010; **40**: 191-192 [PMID: 20555055 DOI: 10.1258/td.2010.090352]
- Zhang LJ, Zhu R, Dang H, Xu J, Li SZ, Guo JG. [Analysis of surveillance of schistosomiasis in China in 2011]. *Zhongguo Xue Xi Chong Bing Fang Zhi Za Zhi* 2012; **24**: 627-631 [PMID: 23593827 DOI: 10.3969/j.issn.1005-6661.2012.06.002]
- Bie WT, Zheng ZW, Yuan MZ. [Surveillance of schistosomiasis endemic situation in Jingzhou City in 2011]. *Zhongguo Xue Xi Chong Bing Fang Zhi Za Zhi* 2013; **25**: 652-654 [PMID: 24490408]
- Terada T. Schistosomal appendicitis: incidence in Japan and a case report. *World J Gastroenterol* 2009; **15**: 1648-1649 [PMID: 19340911 DOI: 10.3748/wjg.15.1648]
- Mazigo HD, Giiti GC, Zinga M, Heukelbach J, Rambau P. Schistosomal peritonitis secondary to perforated appendicitis. *Braz J Infect Dis* 2010; **14**: 628-630 [PMID: 21340305 DOI: 10.1590/S1413-86702010000600013]
- Moore GR, Smith CV. Schistosomiasis associated with rupture of the appendix in pregnancy. *Obstet Gynecol* 1989; **74**: 446-448 [PMID: 2503794 DOI: 10.1016/0020-7292(90)91074-Z]

P- Reviewer: He SH, Kamocki ZK S- Editor: Qi Y L- Editor: A
E- Editor: Wang CH





Published by **Baishideng Publishing Group Inc**

8226 Regency Drive, Pleasanton, CA 94588, USA

Telephone: +1-925-223-8242

Fax: +1-925-223-8243

E-mail: bpgoffice@wjgnet.com

Help Desk: <http://www.wjgnet.com/esps/helpdesk.aspx>

<http://www.wjgnet.com>



ISSN 1007-9327



9 771007 932045