

## Endoscopic management of biliary complications after liver transplantation: An evidence-based review

Carlos Macías-Gómez, Jean-Marc Dumonceau

Carlos Macías-Gómez, Gastroenterology Service, Hospital Italiano de Buenos Aires, Juan D Peron 4190, Buenos Aires, Argentina

Jean-Marc Dumonceau, Division of Gastroenterology and Hepatology, Geneva University Hospitals, 1211 Geneva, Switzerland

**Author contributions:** Both authors contributed equally to the design of the review, literature research, interpretation of data, and writing of the manuscript.

**Conflict-of-interest:** No conflict of interest was reported by the authors.

**Open-Access:** This article is an open-access article which was selected by an in-house editor and fully peer-reviewed by external reviewers. It is distributed in accordance with the Creative Commons Attribution Non Commercial (CC BY-NC 4.0) license, which permits others to distribute, remix, adapt, build upon this work non-commercially, and license their derivative works on different terms, provided the original work is properly cited and the use is non-commercial. See: <http://creativecommons.org/licenses/by-nc/4.0/>

**Correspondence to:** Carlos Macías-Gómez, MD, Gastroenterology Service, Hospital Italiano de Buenos Aires, Juan D Peron 4190, Buenos Aires, Argentina. [carlos.macias@hospitalitaliano.org.ar](mailto:carlos.macias@hospitalitaliano.org.ar)  
Telephone: +54-1147-861218

Received: September 24, 2014  
Peer-review started: September 24, 2014  
First decision: December 17, 2014  
Revised: February 22, 2015  
Accepted: March 16, 2015  
Article in press: March 18, 2015  
Published online: June 10, 2015

### Abstract

Biliary tract diseases are the most common complications following liver transplantation (LT) and usually include biliary leaks, strictures, and stone disease. Compared

to deceased donor liver transplantation in adults, living donor liver transplantation is plagued by a higher rate of biliary complications. These may be promoted by multiple risk factors related to recipient, graft, operative factors and post-operative course. Magnetic resonance cholangiopancreatography is the first-choice examination when a biliary complication is suspected following LT, in order to diagnose and to plan the optimal therapy; its limitations include a low sensitivity for the detection of biliary sludge. For treating anastomotic strictures, balloon dilatation complemented with the temporary placement of multiple simultaneous plastic stents has become the standard of care and results in stricture resolution with no relapse in > 90% of cases. Temporary placement of fully covered self-expanding metal stents (FCSEMSs) has not been demonstrated to be superior (except in a pilot randomized controlled trial that used a special design of FCSEMSs), mostly because of the high migration rate of current FCSEMSs models. The endoscopic approach of non-anastomotic strictures is technically more difficult than that of anastomotic strictures due to the intrahepatic and/or hilar location of strictures, and the results are less satisfactory. For treating biliary leaks, biliary sphincterotomy and transpapillary stenting is the standard approach and results in leak resolution in more than 85% of patients. Deep enteroscopy is a rapidly evolving technique that has allowed successful treatment of patients who were not previously amenable to endoscopic therapy. As a result, the percutaneous and surgical approaches are currently required in a minority of patients.

**Key words:** Biliary stricture; Bile leakage; Liver transplantation; Endoscopic retrograde cholangio-pancreatography; Plastic stents; Fully-covered self-expandable metal stents

© The Author(s) 2015. Published by Baishideng Publishing Group Inc. All rights reserved.

**Core tip:** One third of liver transplant recipients are

affected by biliary tract complications which are the major source of morbidity in these patients. Biliary-biliary (as opposed to bilio-enteric) anastomoses are first treated by endoscopy, with resolution of > 85% and > 75% of cases in deceased and living-donor transplant recipients, respectively. New stenting protocols and new designs of fully covered self-expandable metal stents are at the frontline of efforts aiming to reduce patient burden during treatment. Here, we discuss the latest developments in the endoscopic approaches to these complications.

Macías-Gómez C, Dumonceau JM. Endoscopic management of biliary complications after liver transplantation: An evidence-based review. *World J Gastrointest Endosc* 2015; 7(6): 606-616 Available from: URL: <http://www.wjgnet.com/1948-5190/full/v7/i6/606.htm> DOI: <http://dx.doi.org/10.4253/wjge.v7.i6.606>

## INTRODUCTION

Liver transplantation (LT) has become a standard of care in patients with end-stage liver disease. After LT, approximately one third of patients are affected by biliary tract complications and these result in significant morbidity and decreased patient survival<sup>[1]</sup>. Due to the scarcity of organ donors and the increasing number of patients waiting for LT, living donor liver transplantation (LDLT) has emerged as an alternative to deceased donor liver transplantation (DDLT). Even though surgical techniques are constantly improving, biliary complications are more frequent following LDLT compared with DDLT<sup>[2]</sup>; LDLT also remains characterized by its technical complexity and ethical controversies.

Biliary complications following LT include biliary leaks, strictures, choledocholithiasis and other less common conditions<sup>[3,4]</sup>. Approaches commonly used for treating biliary complications involve endoscopic retrograde cholangiopancreatography (ERCP), percutaneous transhepatic cholangiography (PTC) and surgery. ERCP is commonly regarded as the first choice treatment modality in most circumstances; if it fails PTC is often used, reserving surgery for severe complications or refractory conditions not manageable by less invasive techniques<sup>[5-8]</sup>.

Here we review the literature focusing on the endoscopic management of biliary complications, the different strategies for treating strictures and biliary leaks and summarize their outcomes.

## ETIOLOGY, RISK FACTORS AND DIAGNOSIS

### **Biliary reconstruction in LT**

It is essential for endoscopists to have a clear comprehension of the different types of surgical reconstruction during LT. Biliary reconstruction is performed at the

end of LT, once all vascular anastomoses have been completed. An end-to-end choledoco-choledocal anastomosis is the first choice procedure in most institutions following whole organ LT in patients with healthy native bile ducts of suitable caliber<sup>[6,9]</sup>. This technique produces physiological bilioenteric continuity, preserves the function of the sphincter of Oddi and allows for potential future endoscopic treatment of biliary complications. Bilioenteric reconstruction (Roux-en-Y hepaticojejunostomy) is performed in cases of previous biliary tract disease (e.g., sclerosing cholangitis, biliary atresia), large disparity in size or small caliber of the bile ducts, and may be preferred in cases of retransplantation because of inadequate recipient duct length<sup>[10]</sup>. Due to the shortage of cadaveric livers, LDLT has gained popularity in adult patients. With LDLT, the living donor's right or left lobe or the left lateral segment is transplanted. Ductal anastomoses are more difficult to perform than in DDLT due to the small caliber of the intrahepatic ducts. In reduced size split-liver transplantation, a liver from a dead donor is splitted into two organs to permit two recipients to receive a graft; the anastomoses of both right and left lobe are alike to those of LDLT.

### **Risk factors for biliary complications**

Biliary complications may be promoted by multiple risk factors related to recipient, graft, operative factors and post-operative course: (1) among recipient-related factors, advanced recipient age and more advanced liver function impairment contribute to the development of biliary complications<sup>[11,12]</sup>; (2) among graft-related factors, prolonged cold and warm ischemia time, extended donor criteria grafts and donation after cardiac death, as opposed to brain death, are associated with a higher incidence of ischemic-type biliary lesions (ITBL)<sup>[13,14]</sup>. Nonetheless, a recent report by Vanatta *et al.*<sup>[15]</sup> showed that, by carefully selecting donors and recipients, overall patient and graft survival as well as the incidence of ITBL were similar following donation after cardiac vs brain death<sup>[15]</sup>; (3) operative risk factors are different for DDLT and LDLT for various reasons: LDLT by itself is an important risk factor for biliary complications due to the small duct size, the presence of multiple biliary duct outlets and the devascularization of the bile ducts during hilar dissection of the graft<sup>[16-18]</sup>. In DDLT, T-tube placement for duct to duct (DD) reconstruction allows minimizing the incidence of anastomotic strictures<sup>[19]</sup> and it is unequivocally recommended by some authors<sup>[20]</sup>; however, this results in biliary leakage following T-tube removal in 5%-33% of cases<sup>[19]</sup>; (4) during the postoperative course, early hepatic artery thrombosis may lead to the severest forms of non-anastomotic strictures, at multiple sites of the donor biliary system, because blood supply to the bile ducts is fragile. This may result in partial or total biliary necrosis with the formation of typical biliary casts and multiple intraluminal filling defects at

cholangiography<sup>[5,21]</sup>; and (5) other documented factors, including ABO incompatibility, cytomegalovirus infection and chronic/acute rejection episodes have been reported to be potential risk factors for biliary complications in historical publications; more recently these factors have been strongly associated with non-anastomotic, rather than anastomotic, complications<sup>[22-24]</sup>.

### Diagnostic approach

The clinical presentation of biliary complications varies considerably; patients could present no symptom at all, jaundice, abdominal pain, biliary leak or cholangitis. In asymptomatic LT recipients, a biliary complication usually is first suspected because of elevations of serum bilirubin, alkaline phosphatase, and/or gamma-glutamyl transferase levels. In the case of cholestasis, the initial diagnostic step is to discriminate obstructive vs nonobstructive causes, like LT rejection (acute or chronic), recurrence of primary disease and drug-induced cholestasis.

The initial evaluation should include a liver ultrasound (US) with a Doppler evaluation of the hepatic vessels, due to the frequent association of biliary complications with the presence of hepatic artery thrombosis or stenosis<sup>[6,25]</sup>. If hepatic artery stenosis or occlusion is suspected by Doppler US, multidetector computed tomography should be used as the second-line modality of choice for the rapid assessment of major vascular complications requiring pre-treatment confirmation. If hepatic artery thrombosis is confirmed, angiographic intervention should be performed urgently to re-establish hepatic artery flow<sup>[26,27]</sup>. Magnetic resonance cholangiopancreatography (MRCP) has substantially facilitated the accurate recognition of biliary tract complications (sensitivity and specificity of 93%-97% and 92%-98%, respectively, compared with ERCP as the reference standard)<sup>[28-31]</sup>. MRCP provides the endoscopist with a map of the whole biliary tract and, unlike ERCP, consistently demonstrates ducts even upstream from a tight stricture, therefore it is especially useful for hilar or intrahepatic anastomotic strictures. When findings at MRCP were compared to other approaches, including ERCP, PTC, and surgery to diagnose post-LT biliary complications, the sensitivity, specificity, positive predictive value, and negative predictive of MRCP were 98%, 94%, 94%, and 98%, respectively<sup>[31]</sup>. Its main disadvantages include a low sensitivity in the case of sludge or small stones (< 5 mm). MRCP is noninvasive and is the technique of choice for diagnosing post-LT biliary complications.

### Etiology and types of biliary strictures

Post-LT biliary strictures are usually classified as anastomotic strictures (ASs) or non-anastomotic strictures (NASs), also called ischemic type biliary strictures (ITBS)<sup>[32-34]</sup>. Biliary strictures complicate around 2%-14% of LT and can be categorized in to early or late (occurring within or after the first month

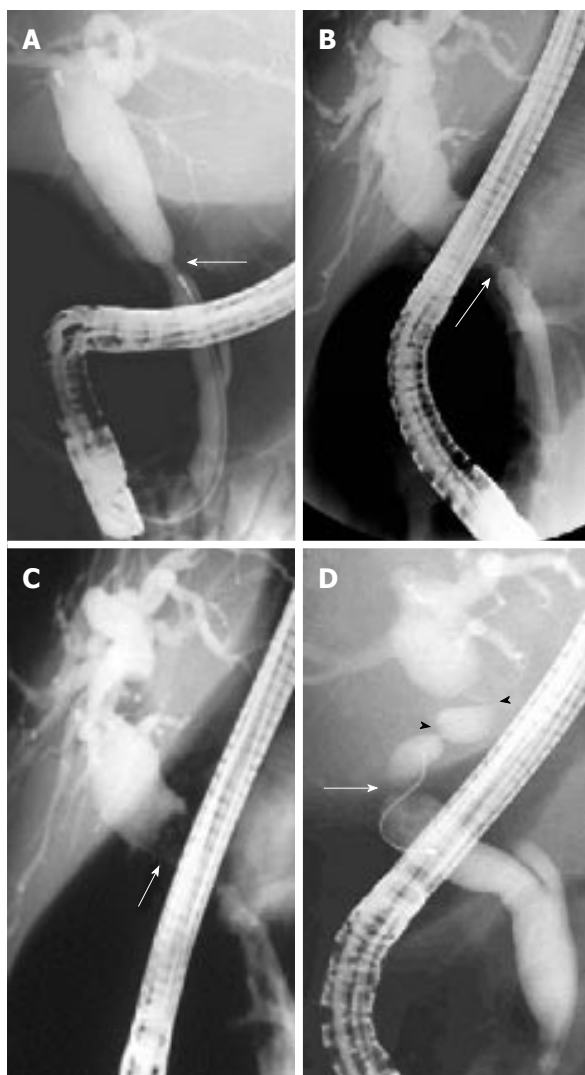following LT, respectively). Strictures which appear soon after LT are commonly referable to technical problems, whereas late strictures are generally attributable to vascular insufficiency and problems with healing and fibrosis. In a recent systematic review, 1844 (12.8%) of 14359 LT patients had biliary strictures. The appearance of a stricture varies widely, from 7 d to 11 years after LT<sup>[35]</sup>.

**Anastomotic strictures:** ASs can present at any time after transplantation but most of them are diagnosed within one year following LT with a mean interval between LT and diagnosis of 5-8 mo. ASs complicate around 6%-12% and 34% of deceased and living donor LT procedures, respectively<sup>[33,36,37]</sup>. ASs pathogenesis is believed to include inadequate mucosa-to-mucosa anastomosis, local tissue ischemia, and the fibrotic nature of the healing process<sup>[33,38]</sup>. ASs are solitary and short in length (Figure 1A and B). They may involve a choledocho-jejunostomy or a choledocho-choledochostomy; they are considered clinically relevant only if cholestasis or cholangitis are present. A slight and transient narrowing of the biliary lumen occurs frequently within the first one to two months following biliary anastomosis due to postoperative edema and inflammation, but it is uncertain how many of these cases progress to clinically significant ASs (Figure 1A)<sup>[33]</sup>. ASs can generally be effectively treated by endoscopic means and do not decrease graft or patient survival.

**Non-anastomotic strictures:** Post-LT strictures are classified as NASs if they are located more than 5 mm proximal to the anastomosis (Figure 1D). They account for 10% to 25% of all strictures complicating LT, with an incidence in the range of 0.5% to 10%<sup>[19,38-40]</sup>. NASs are considered to derive from ischemic damage to the duct as it may occur following hepatic artery thrombosis. Conditions associated with NASs include a prolonged ischemia time (cold and warm), transplantation after cardiac death donation, prolonged vasopressor support for the donor, ABO-type incompatibility, primary sclerosing cholangitis, autoimmune hepatitis or hepatitis C virus infection in the recipient<sup>[41-48]</sup>. Furthermore, nowadays a wider acceptance of older and extended criteria donors has been suggested to contribute to an increased incidence of NASs<sup>[19]</sup>. True NASs, usually referred to as ITBSs, characteristically are diffuse and include the hilum and sectorial or segmental intrahepatic branches. The treatment of NASs is technically more difficult than that of ASs and, in the case of hepatic artery thrombosis, the endoscopic treatment is mostly ineffective if the arterial blood flow cannot be restored.

### Etiology and types of biliary leaks

Biliary leakage is the second most common complication after LT, with an incidence of 2%-21%<sup>[19,49,50]</sup>. In a recent meta-analysis, the rate of biliary leakage after LT



**Figure 1** Biliary strictures at endoscopic retrograde cholangiopancreatography. A: Early and incipient anastomotic stricture (arrow) with upstream biliary dilation; B and C: Late and high-grade anastomotic stricture (arrow) > 1 year after deceased-donor liver transplantation, with a large stone located upstream from the stricture (arrow); D: Combination of anastomotic (arrow) and non-anastomotic (arrow heads) strictures.

was 8.2%, without significant difference between DDLT (7.8%) and LDLT (9.5%)<sup>[35]</sup>. Leakage may develop at the level of the anastomotic site, from the cystic duct remnant, from the cut surface of partial liver grafts in the case of LDLT, and following T-tube removal (Figure 2). Bile leaks can be classified into two categories: early bile leaks, which present within 4 wk following LT (these usually occur at the anastomotic site and are often related to technical issues, not to the type of biliary reconstruction), and late bile leaks, which present beyond this time (they are usually related to T-tube removal, resulting from delayed T-tube tract maturation possibly related to immunosuppression). A bile leak should be suspected in any patient who develops abdominal pain, fever or any sign of peritonitis following LT, especially after T-tube removal. Bile leaks can derive in collections of fluids and abscesses that might be related to strictured or disconnected ducts. Depending

on the size of the leakage and the clinical presentation, bile leaks can be managed conservatively, nonsurgically or surgically<sup>[4,51]</sup>.

### ***Etiology and type of intraluminal biliary filling defects***

Stones, sludge and casts occur in approximately 5% of patients after LT, with stones accounting for 70% of the cases. Biliary stone disease is associated with disorders that can reduce the flow of bile such as ASs or NASs. In addition, medications such as cyclosporine may play a role in bile lithogenicity by inhibiting bile secretion and promoting functional biliary stasis. Sludge is described as a thick collection of mucus, calcium bicarbonate and cholesterol crystals, which, when left untreated, can transform into biliary stones (Figure 3A).

Casts refer to the presence of multiple hard pigmented dark material that mold the bile ducts (Figure 4). These are thought to develop due to bile duct mucosal damage related to obstruction, ischemia, or bacterial infection. A history of hepatic artery thrombosis and a prolonged cold ischemia time are associated with debris formation<sup>[52-54]</sup>. This disorder occurs in 2.5% to 18.0% of LT recipients<sup>[32,54]</sup>. Casts are associated with increased morbidity, graft failure, retransplantation and mortality.

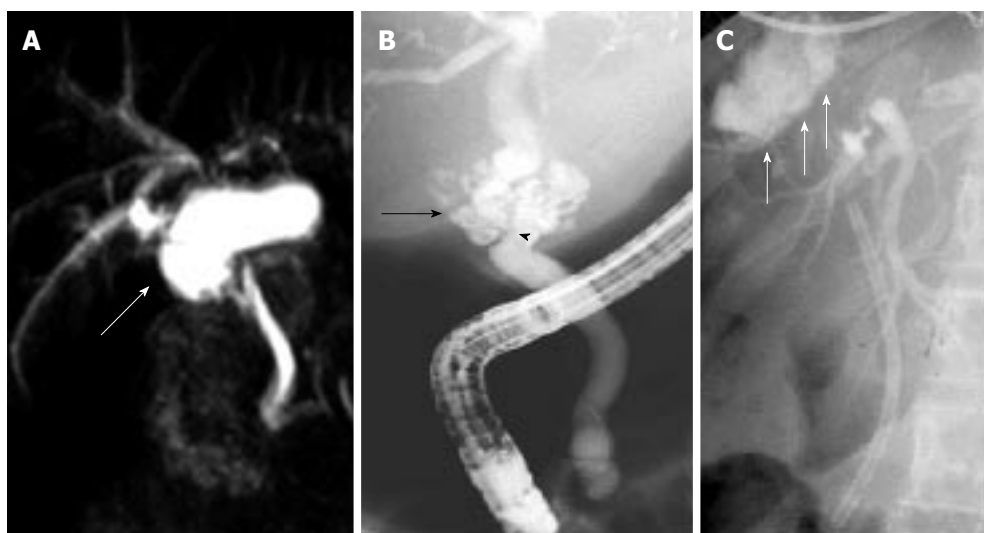
### ***Sphincter of oddi dysfunction***

Sphincter of oddi dysfunction (SOD) describes a clinical syndrome of biliary or pancreatic functional obstruction that may be responsible for cholestasis, pain, or pancreatitis.

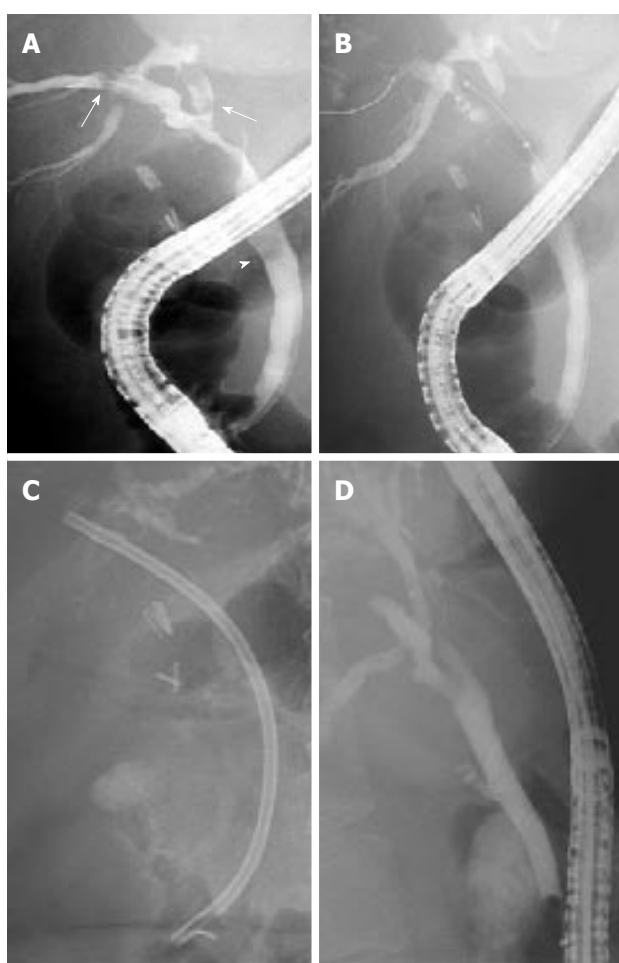
It is hypothesized that, in the post-LT setting, denervation of the ampulla (secondary to surgical intervention) might generate a hypertonic sphincter, resulting in increased intraductal biliary pressure. This complication has been reported in 2% to 7% of patients who have undergone LT<sup>[55,56]</sup>. Typically, patients present with cholestasis, dilation of the distal bile duct and no obstacle detected at cholangiography.

## **ENDOSCOPIC MANAGEMENT**

Managing post-LT biliary complications needs a multi-disciplinary team involving transplant surgeons, hepatologists, endoscopists, and interventional radiologists. Endoscopic therapy is the first line therapy in most cases with a duct-to-duct anastomosis. With recent developments in enteroscopy, many patients with Roux-en-Y hepaticojejunostomy can also be treated endoscopically<sup>[57]</sup>, with PTC being mostly reserved for the salvage of failures. The spectrum of endoscopic therapies includes biliary sphincterotomy, balloon dilation of strictures, basket and balloon extraction of stones, sludge, and casts, and the placement of one or multiple, side-by-side, biliary plastics stents. Additionally, cholangioscopy allows the characterization of strictures by observation and tissue sampling, and therapy of difficult casts or stones by intraductal lithotripsy<sup>[58-62]</sup>. Endoscopic therapy is usually highly successful and has a low incidence of procedure-related complications,



**Figure 2 Biliary leaks.** A: Biloma (arrow) resulting from anastomotic leakage early after liver transplantation as shown at magnetic resonance cholangiopancreatography; B: Anastomotic leakage (arrow) at the level of an anastomotic stricture (arrow head) early after liver transplantation as shown at endoscopic retrograde cholangiopancreatography (ERCP); C: Multiple leak sites from the cut surface in a split liver transplantation patient (arrows) as shown at ERCP with a plastic biliary stent in place.

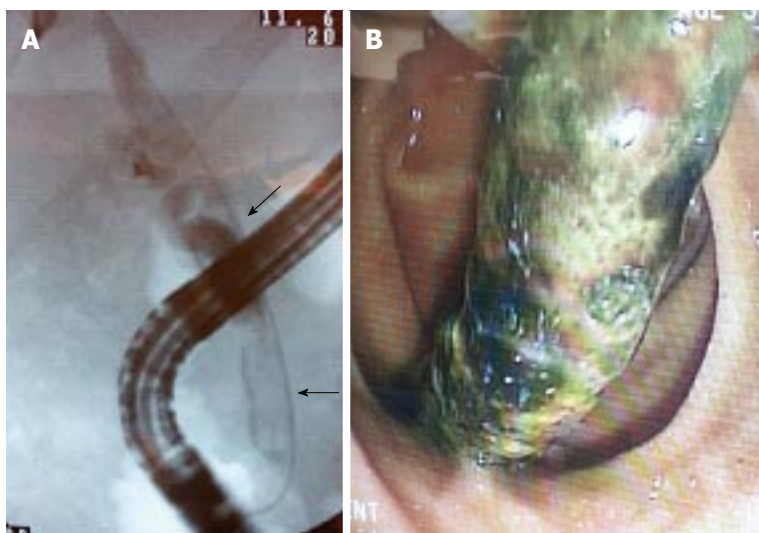


**Figure 3 Endoscopic treatment of an anastomotic biliary stricture with upstream sludge and downstream stone after living donor liver transplantation.** A: Anastomotic biliary stricture with upstream sludge (arrows) and downstream stone (arrowhead); B: Stricture dilation using a 10-mm in-diameter balloon; C: 10-F plastic biliary stent in place; D: Absence of residual stricture at late follow-up.

reserving surgery as a last option intervention if endoscopic and/or percutaneous treatment is not feasible or is ineffective.

### Biliary leaks

Traditionally, post-LT biliary leaks have been treated surgically with anastomotic revision or conversion to a Roux-en-Y hepaticojejunostomy if a duct-to-duct anastomosis is not technically feasible. With advances in endoscopic therapy, ERCP has now become the initial therapeutic option in the management of biliary leaks. Usually the leakage of bile is treated through biliary sphincterotomy followed by the placement of a transpapillary stent (Figure 2C) for 2 to 3 mo (in contrast to post-cholecystectomy leaks, where the stent can be removed in 4 to 6 wk) with the aim of ensuring the proper healing of the leaks. Prolonged stenting is advised because healing may be delayed by immunosuppressors. If the leak is associated with a biliary stricture, this can be prudently dilated before inserting one or more plastic stents upstream from both the stricture and the leak<sup>[63]</sup>. Biliary stenting provides faster leak resolution than sphincterotomy alone and it is equally effective whether sphincterotomy is performed or not. At the time of stent removal, a careful anatomical evaluation should be performed and duct cleansing should always be performed because biliary abnormalities (mostly sludge, stones, or persistent leak) can be found at this time in a significant proportion of patients<sup>[64]</sup>. Endoscopic therapy solves the leakage of bile in more than 85% of patients<sup>[38,63-66]</sup>. Recently, fully covered self-expandable metal stents (FCSEMS) have been used in a pilot study of 17 LT recipients with biliary leaks<sup>[67]</sup>. FCSEMS offered minimally invasive and low-morbidity short-term control of leaks but it resulted in a relatively high stricture rate. In this series of 17



**Figure 4** Elongated intraductal filling defects in the choledocus and common hepatic duct suggestive of biliary casts (arrows) (A) and endoscopic view of the successfully removed cast (B).

patients, 8 (47%) patients developed common bile duct strictures following FCSEMS removal; of these, 6 (35%) required repeat endoscopic treatment for a clinically significant stricture, therefore the use of current FCS-EMS models cannot be recommended in the post-LT population. In specific situations, endoscopic therapy can be impossible or fail, for example, in the case of large anastomotic leaks associated with hepatic artery compromise or surgically altered anatomy (Roux-en-Y anastomosis). These patients will most often require surgical management.

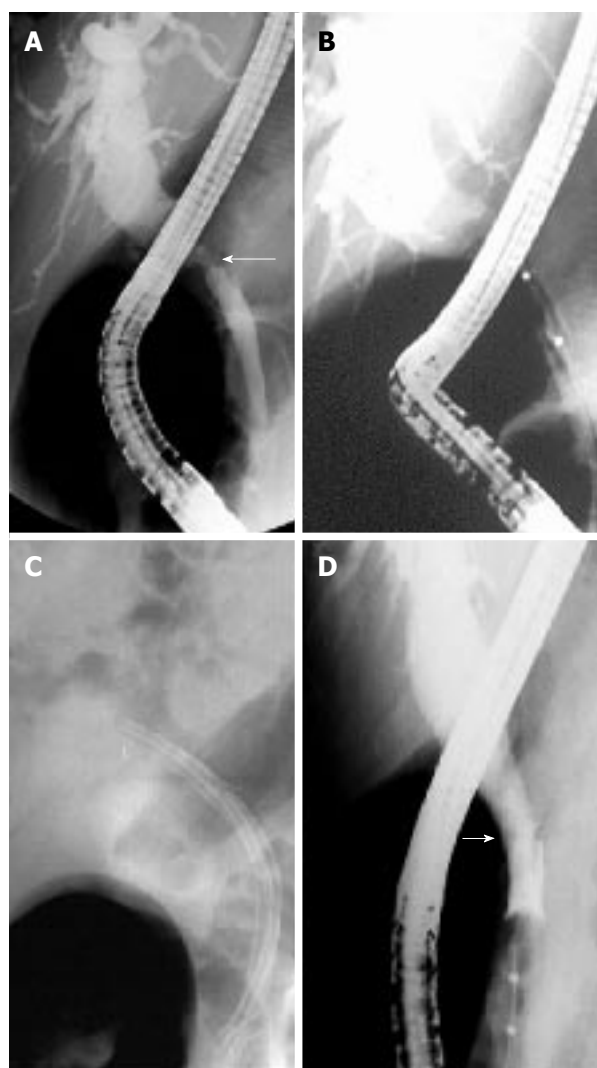
### **Biliary strictures**

**Anastomotic strictures:** No standard protocol has emerged for the endoscopic therapy of ASs. By analogy with the more frequent postcholecystectomy biliary stricture, endoscopic therapy of ASs usually requires biliary sphincterotomy plus balloon dilatation (BD) and stent placement (Figure 5). The use of BD alone in early onset anastomotic strictures (the first 2 mo following LT) may be effective. However, despite good initial success, BD alone led to a high rate of recurrent stricture formation<sup>[68]</sup>. Therefore, the combination of BD and stenting is a more adequate approach<sup>[33,65,68-71]</sup>.

Multiple 10-Fr plastic stents are usually maintained until stricture resolution or for a minimum of 12 mo, with stent exchange scheduled every 3-4 mo to reduce the chance of stent blockage and cholangitis. In a recent systematic review that included 440 LT-related ASs treated with multiple simultaneous plastic stents<sup>[72]</sup>, the mean AS resolution rate was approximately 85% for early as well as late ASs. Higher ASs resolution rates (97% vs 78%) and lower ASs recurrence rates (1.5% vs 14%) have been reported with stenting durations > 12 mo vs < 12 mo. This was observed despite the fact that shorter stenting durations were applied for early vs late ASs. Most cases of ASs recurrence were successfully managed with repeat plastic stenting.

Recently, different strategies of AS treatment have been described to decrease patient burden: (1) long-

term maximal stent therapy with stent exchange only when signs or symptoms of biliary obstruction are detected: this strategy has allowed minimizing the number of ERCPs needed to treat ASs without compromising success or patient safety. With this protocol, complete AS resolution was reached in 94% of patients and recurrence rate at a median follow-up of 11 mo was 3%<sup>[73]</sup>. The authors reported in a total of 83 patients 2 cases of post-ERCP pancreatitis, 2 cases of periprocedural bacteremia but no episodes of cholangitis caused by stent occlusion; (2) stent exchange every 2 wk: ERCP with rapid-sequence balloon dilation followed by stenting with multiple stents over a short time period<sup>[74]</sup>. With this approach, mean stenting duration was 107 d and long-term stricture resolution was achieved in 33 (87%) of 38 patients; ERCP-related complications occurred in 2 (5%) patients. During a mean follow-up of one year after stent removal, 5 (13%) patients had a stricture recurrence, successfully retreated by endoscopic means in 4 cases; and (3) temporary placement of covered self-expandable metal stent (SEMSs). Covered SEMSs offer the advantage of longer stent patency and larger nominal diameter compared with a single plastic stent. Covered SEMSs should be maintained in place for a minimum of 3 mo as shorter stenting durations result in lower ASs resolution (72% vs 90%)<sup>[75-79]</sup>. In the systematic review cited above<sup>[72]</sup>, covered SEMSs had a much higher stent migration rate (16%) compared with simultaneous multiple plastic stenting. Furthermore, covered SEMS carry a low but real risk of tissue ingrowth and stent impaction. Therefore, the authors concluded that current evidence does not suggest a clear advantage of SEMS use over multiple simultaneous plastic stenting in the management of ASs. In a large prospective study that was not included in the systematic review<sup>[80]</sup>, the AS resolution rate using FCSEMSs was 68% of 42 LT patients and the migration rate was 17% and 75% at 3 and 6 mo, respectively. In this study, cholangitis was reported in 24% of patients with LT-related ASs and it



**Figure 5** Endoscopic treatment of an anastomotic biliary stricture after deceased donor liver transplantation. A: Late, high-grade, anastomotic stricture (arrow) with a stone partially concealed by the endoscope; B: Stricture dilatation with a 4-mm in-diameter balloon; C: Three 10-Fr plastic stents in place, no residual stone; D: Balloon occlusion cholangiogram showing stricture disappearance at the end of treatment (arrow).

was strikingly associated with stent migration. Finally, a recent randomized trial compared a new design of FCSEMS vs multiple simultaneous plastic stenting in 20 patients with LT-related ASs<sup>[81]</sup>. ASs resolution rates were similar with both stent models but complication rate and hospital stay duration were non-significantly higher with the plastic stent vs FCSEMS, suggesting that some FCSEMS designs that effectively prevent stent migration might be a cost-effective alternative to plastic stenting.

Endoscopic management of ASs seemed to be more challenging in LDLT vs DDLT due to the complexity of duct-to-duct anastomosis. However, using an aggressive strategy of maximal endoscopic stent placement, two studies reported high (75%-100%) AS resolution rates in LDLT patients<sup>[82,83]</sup>. The long-term resolution rates of biliary leaks and/or strictures reported in selected retrospective studies are summarized in Table 1<sup>[37,82-87]</sup>.

**Table 1** Retrospectives series showing living donor liver transplantation endoscopic anastomotic strictures treatment results

Ref.	Patients (n)	Stenting (m)	Success (%)	F/U (m)	Relapse (%)
Yazumi <i>et al</i> <sup>[37]</sup> (2006) <sup>1</sup>	75	6	68	20 (1-50)	10
Gómez <i>et al</i> <sup>[84]</sup> (2009)	10	NR	20	30.5 (2-23)	NR
Seo <i>et al</i> <sup>[87]</sup> (2009)	29	3-6	64.5	31	30
Chang <i>et al</i> <sup>[86]</sup> (2010)	113	3-6	26.5	33 (3-96)	NR
Kim <i>et al</i> <sup>[85]</sup> (2011)	112	12.7	36	42.8 ± 15.2	11.5
Chan <sup>[82]</sup> (2013)	8	NR	75	18 ± 8.7	NR
Hsieh <sup>[83]</sup> (2013) <sup>2</sup>	38	5.3	100	74	21

<sup>1</sup>Combination of percutaneous transhepatic biliary drainage plus endoscopic retrograde cholangiopancreatography (ERCP) in 9 patients and inside stents technique; <sup>2</sup>Combination of percutaneous transhepatic biliary drainage plus ERCP in 6 patients. NR: Not reported.

Factors identified as independent predictors of failed endoscopic treatment of LDLT-related ASs include higher LT recipient age, longer operation duration, and a pouched morphology of the AS<sup>[84,88]</sup>. Recurrent ASs occur in approximately 21% of patients and may be retreated by endoscopy<sup>[83]</sup>. PTC plays an important role when a guide wire cannot be inserted through the anastomotic stricture at the time of ERCP (e.g., disconnected duct, some refractory angulated or twisted strictures). For these patients, the rendez-vous technique (PTC + ERCP) may be useful to insert a stent above the stricture. This approach has been demonstrated to be feasible and relatively safe for the management of biliary strictures complicating LDLT with duct-to-duct anastomosis<sup>[89]</sup>. The endoscopic treatment of some ASs can be unsuccessful and may need long-term stenting or surgical hepaticojejunal anastomosis<sup>[87,90]</sup>.

**Non-anastomotic strictures:** The endoscopic therapy of NASs or ITBSs often involves the hilum and intrahepatic ducts and is notably more demanding than the therapy of ASs. The stenosis at the level of the sectorial or segmental branch ducts can result in a cholangiographic appearance that simulates primary sclerosing cholangitis. It is challenging to make general recommendations for managing NASs and treatment should be individualized. Treatment success depends upon stricture grade, number, and location. Extra-hepatic strictures generally respond better to therapy and altogether, in the few published reports of endoscopic treatment, the success rates ranged between 50% and 70%<sup>[50,91]</sup>. Finally, a few patients (especially the ones with complex ischemic intrahepatic strictures) may need surgical revision or retransplantation.

In patients who have undergone Roux-en-Y hepaticojejunostomy, a potential alternative to PTC is the use of various techniques of enteroscopy. In 25 pediatric patients with hepaticojejunal anastomoses, the bilioen-

teric anastomosis could be reached in 17 patients, a stent could be placed in 9 patients and AS resolution was obtained in 5 (20%) patients, showing the difficulty of this procedure<sup>[92]</sup>. In a series of 44 adults with choledochojejunal AS following various hepato-biliary-pancreatic surgery, temporary stenting (including stent removal) was achieved in 32 (73%) patients and restenosis occurred in 7/32 patients<sup>[93]</sup>.

### Other complications

**Biliary stones, sludge and casts:** In LT recipients, the endoscopic management of stones is similar to that performed in the nontransplant setting although the approach may be complicated by the presence of a stricture downstream from the stone. In such circumstances, delayed stone extraction (following biliary stenting) or advanced endoscopic techniques like intraductal lithotripsy or direct choledocopy may be required to achieve stone removal. In patients with serious coagulation disorders or thrombocytopenia where sphincter ablation may be relatively contraindicated, balloon dilatation of the intact sphincter can be applied.

For biliary casts, the endoscopic approaches are alike to those utilized in stone disease. However, the success rate is significantly lower owing to the multiplicity of filling defects located in intrahepatic bile ducts<sup>[39]</sup>. Treatment usually requires multiple ERCPs, possibly complemented with PTC and it may require retransplantation in a significant proportion of cases<sup>[39,94]</sup>. Cholangioscopy might aid to discriminate biliary casts from strictures<sup>[59]</sup>.

### Sphincter of Oddi dysfunction and papillary stenosis

As for SOD in the non-LT setting, biliary sphincterotomy is the common treatment and provides a high success rate<sup>[39]</sup>. The question of whether these patients are at similar risk of post-ERCP pancreatitis as those who are affected in the non-LT setting has not been formally studied; however it seems reasonable to consider prophylactic pancreatic stenting in addition to standard rectal administration of NSAIDs when performing sphincterotomy in these patients<sup>[95]</sup>.

## SUMMARY

Biliary complications remain a burden in LT patients and continue in some cases to be a challenging aspect of the multidisciplinary care of LT patients. As biliary complications are the most frequent complication following LT, the index of suspicion for requesting further investigations should be low. MRCP is the most useful examination to establish the diagnosis, especially because the low sensitivity of US may be more detrimental in LT as compared to the average patient. Successful endoscopic treatment is achieved in most cases, with the notable exceptions of ASs in LDLT patients, NASs and biliary casts. For ASs, temporary simultaneous multiple plastic stenting for a

minimum of 12 mo (except in some cases of early AS) remains the standard of care; FCSEMS have yielded disappointing results up to now. In patients with choledochojejunostomy, deep enteroscopy techniques may allow successful treatment but success rates are lower. Nowadays PTC and surgery are reserved for a small minority of patients.

## REFERENCES

- 1 Duffy JP, Kao K, Ko CY, Farmer DG, McDiarmid SV, Hong JC, Venick RS, Feist S, Goldstein L, Saab S, Hiatt JR, Busuttil RW. Long-term patient outcome and quality of life after liver transplantation: analysis of 20-year survivors. *Ann Surg* 2010; **252**: 652-661 [PMID: 20881772 DOI: 10.1097/SLA.0b013e3181f5f23a]
- 2 Wan P, Yu X, Xia Q. Operative outcomes of adult living donor liver transplantation and deceased donor liver transplantation: a systematic review and meta-analysis. *Liver Transpl* 2014; **20**: 425-436 [PMID: 24478109 DOI: 10.1002/lt.23836]
- 3 Ayoub WS, Esquivel CO, Martin P. Biliary complications following liver transplantation. *Dig Dis Sci* 2010; **55**: 1540-1546 [PMID: 20411422 DOI: 10.1007/s10620-010-1217-2]
- 4 Thuluvath PJ, Atassi T, Lee J. An endoscopic approach to biliary complications following orthotopic liver transplantation. *Liver Int* 2003; **23**: 156-162 [PMID: 12955878 DOI: 10.1034/j.1600-0676.2003.00823.x]
- 5 Arain MA, Attam R, Freeman ML. Advances in endoscopic management of biliary tract complications after liver transplantation. *Liver Transpl* 2013; **19**: 482-498 [PMID: 23417867 DOI: 10.1002/lt.23624]
- 6 Greif F, Bronsther OL, Van Thiel DH, Casavilla A, Iwatsuki S, Tzakis A, Todo S, Fung JJ, Starzl TE. The incidence, timing, and management of biliary tract complications after orthotopic liver transplantation. *Ann Surg* 1994; **219**: 40-45 [PMID: 8297175]
- 7 Kochhar G, Parungao JM, Hanounieh IA, Parsi MA. Biliary complications following liver transplantation. *World J Gastroenterol* 2013; **19**: 2841-2846 [PMID: 23704818 DOI: 10.3748/wjg.v19.i19.2841]
- 8 Lopez RR, Benner KG, Ivancev K, Keefe EB, Deveney CW, Pinson CW. Management of biliary complications after liver transplantation. *Am J Surg* 1992; **163**: 519-524 [PMID: 1575311 DOI: 10.1016/0002-9610(92)90401-C]
- 9 Verran DJ, Asfar SK, Ghent CN, Grant DR, Wall WJ. Biliary reconstruction without T tubes or stents in liver transplantation: report of 502 consecutive cases. *Liver Transpl Surg* 1997; **3**: 365-373 [PMID: 9346765 DOI: 10.1002/lt.500030403]
- 10 Vallera RA, Cotton PB, Clavien PA. Biliary reconstruction for liver transplantation and management of biliary complications: overview and survey of current practices in the United States. *Liver Transpl Surg* 1995; **1**: 143-152 [PMID: 9346556 DOI: 10.1002/lt.500010302]
- 11 Qian YB, Liu CL, Lo CM, Fan ST. Risk factors for biliary complications after liver transplantation. *Arch Surg* 2004; **139**: 1101-1105 [PMID: 15492152 DOI: 10.1001/archsurg.139.10.1101]
- 12 Welling TH, Heidt DG, Englesbe MJ, Magee JC, Sung RS, Campbell DA, Punch JD, Pelletier SJ. Biliary complications following liver transplantation in the model for end-stage liver disease era: effect of donor, recipient, and technical factors. *Liver Transpl* 2008; **14**: 73-80 [PMID: 18161843 DOI: 10.1002/lt.21354]
- 13 Jay CL, Skaro AI, Ladner DP, Wang E, Lyuksemburg V, Chang Y, Xu H, Talakkokla S, Parikh N, Holl JL, Hazen GB, Abecassis MM. Comparative effectiveness of donation after cardiac death versus donation after brain death liver transplantation: Recognizing who can benefit. *Liver Transpl* 2012; **18**: 630-640 [PMID: 22645057 DOI: 10.1002/lt.23418]
- 14 Merion RM, Pelletier SJ, Goodrich N, Englesbe MJ, Delmonico FL. Donation after cardiac death as a strategy to increase deceased donor liver availability. *Ann Surg* 2006; **244**: 555-562 [PMID: 16511422 DOI: 10.1097/SLA.0b013e3181f5f23a]

- 16998364 DOI: 10.1097/01.sla.0000239006.33633.39]
- 15 **Vanatta JM**, Dean AG, Hathaway DK, Nair S, Modanlou KA, Campos L, Nezakatgoo N, Satapathy SK, Eason JD. Liver transplant using donors after cardiac death: a single-center approach providing outcomes comparable to donation after brain death. *Exp Clin Transplant* 2013; **11**: 154-163 [PMID: 23480344 DOI: 10.6002/ect.2012.0173]
  - 16 **Ishiko T**, Egawa H, Kasahara M, Nakamura T, Oike F, Kaihara S, Kiuchi T, Uemoto S, Inomata Y, Tanaka K. Duct-to-duct biliary reconstruction in living donor liver transplantation utilizing right lobe graft. *Ann Surg* 2002; **236**: 235-240 [PMID: 12170029 DOI: 10.1097/01.SLA.0000022026.90761.FC]
  - 17 **Lee KW**, Joh JW, Kim SJ, Choi SH, Heo JS, Lee HH, Park JW, Lee SK. High hilar dissection: new technique to reduce biliary complication in living donor liver transplantation. *Liver Transpl* 2004; **10**: 1158-1162 [PMID: 15350008 DOI: 10.1002/lt.20230]
  - 18 **Ohkubo M**, Nagino M, Kamiya J, Yuasa N, Oda K, Arai T, Nishio H, Nimura Y. Surgical anatomy of the bile ducts at the hepatic hilum as applied to living donor liver transplantation. *Ann Surg* 2004; **239**: 82-86 [PMID: 14685104 DOI: 10.1097/01.sla.0000102934.93029.89]
  - 19 **Riediger C**, Müller MW, Michalski CW, Hüser N, Schuster T, Kleeff J, Friess H. T-Tube or no T-tube in the reconstruction of the biliary tract during orthotopic liver transplantation: systematic review and meta-analysis. *Liver Transpl* 2010; **16**: 705-717 [PMID: 20517904 DOI: 10.1002/lt.22070]
  - 20 **López-Andújar R**, Orón EM, Carregnato AF, Suárez FV, Herraiz AM, Rodríguez FS, Carbó JJ, Ibars EP, Sos JE, Suárez AR, Castillo MP, Pallardó JM, De Juan Burgueño M. T-tube or no T-tube in cadaveric orthotopic liver transplantation: the eternal dilemma: results of a prospective and randomized clinical trial. *Ann Surg* 2013; **258**: 21-29 [PMID: 23426348 DOI: 10.1097/SLA.0b013e318286e0a0]
  - 21 **Seehofer D**, Eurich D, Veltzke-Schlieker W, Neuhaus P. Biliary complications after liver transplantation: old problems and new challenges. *Am J Transplant* 2013; **13**: 253-265 [PMID: 23331505 DOI: 10.1111/ajt.12034]
  - 22 **Sanchez-Urdazpal L**, Gores GJ, Ward EM, Maus TP, Buckel EG, Steers JL, Wiesner RH, Krom RA. Diagnostic features and clinical outcome of ischemic-type biliary complications after liver transplantation. *Hepatology* 1993; **17**: 605-609 [PMID: 8477965 DOI: 10.1002/hep.1840170413]
  - 23 **Fisher A**, Miller CH. Ischemic-type biliary strictures in liver allografts: the Achilles heel revisited? *Hepatology* 1995; **21**: 589-591 [PMID: 7843733 DOI: 10.1002/hep.1840210245]
  - 24 **Buis CI**, Verdonk RC, Van der Jagt EJ, van der Hilst CS, Slooff MJ, Haagsma EB, Porte RJ. Nonanastomotic biliary strictures after liver transplantation, part 1: Radiological features and risk factors for early vs. late presentation. *Liver Transpl* 2007; **13**: 708-718 [PMID: 17457932 DOI: 10.1002/lt.21166]
  - 25 **Zajko AB**, Campbell WL, Logsdon GA, Bron KM, Tzakis A, Esquivel CO, Starzl TE. Cholangiographic findings in hepatic artery occlusion after liver transplantation. *AJR Am J Roentgenol* 1987; **149**: 485-489 [PMID: 3303874 DOI: 10.2214/ajr.149.3.485]
  - 26 **Meng XC**, Huang WS, Xie PY, Chen XZ, Cai MY, Shan H, Zhu KS. Role of multi-detector computed tomography for biliary complications after liver transplantation. *World J Gastroenterol* 2014; **20**: 11856-11864 [PMID: 25206292 DOI: 10.3748/wjg.v20.i33.11856]
  - 27 **Girometti R**, Como G, Bazzocchi M, Zuiani C. Post-operative imaging in liver transplantation: state-of-the-art and future perspectives. *World J Gastroenterol* 2014; **20**: 6180-6200 [PMID: 24876739 DOI: 10.3748/wjg.v20.i20.6180]
  - 28 **Beltrán MM**, Marugán RB, Oton E, Blesa C, Nuño J. Accuracy of magnetic resonance cholangiography in the evaluation of late biliary complications after orthotopic liver transplantation. *Transplant Proc* 2005; **37**: 3924-3925 [PMID: 16386586 DOI: 10.1016/j.transproceed.2005.10.044]
  - 29 **Boraschi P**, Donati F, Gigoni R, Volpi A, Salemi S, Filipponi F, Falaschi F. MR cholangiography in orthotopic liver transplantation: sensitivity and specificity in detecting biliary complications. *Clin Transplant* 2010; **24**: E82-E87 [PMID: 20041910 DOI: 10.1111/j.1399-0012.2009.01190.x]
  - 30 **Linhares MM**, Gonzalez AM, Goldman SM, Coelho RD, Sato NY, Moura RM, Silva MH, Lanzoni VP, Salzedas A, Serra CB, Succi T, D'Ippolito G, Szejnfeld J, Triviño T. Magnetic resonance cholangiography in the diagnosis of biliary complications after orthotopic liver transplantation. *Transplant Proc* 2004; **36**: 947-948 [PMID: 15194328 DOI: 10.1016/j.transproceed.2004.04.005]
  - 31 **Novellas S**, Caramella T, Fournol M, Gugenheim J, Chevallier P. MR cholangiopancreatography features of the biliary tree after liver transplantation. *AJR Am J Roentgenol* 2008; **191**: 221-227 [PMID: 18562749 DOI: 10.2214/AJR.07.2938]
  - 32 **Porrett PM**, Hsu J, Shaked A. Late surgical complications following liver transplantation. *Liver Transpl* 2009; **15** Suppl 2: S12-S18 [PMID: 19877292 DOI: 10.1002/lt.21893]
  - 33 **Sharma S**, Gurakar A, Jabbour N. Biliary strictures following liver transplantation: past, present and preventive strategies. *Liver Transpl* 2008; **14**: 759-769 [PMID: 18508368 DOI: 10.1002/lt.21509]
  - 34 **Verdonk RC**, Buis CI, Porte RJ, van der Jagt EJ, Limburg AJ, van den Berg AP, Slooff MJ, Peeters PM, de Jong KP, Kleibeuker JH, Haagsma EB. Anastomotic biliary strictures after liver transplantation: causes and consequences. *Liver Transpl* 2006; **12**: 726-735 [PMID: 16628689 DOI: 10.1002/lt.20714]
  - 35 **Akamatsu N**, Sugawara Y, Hashimoto D. Biliary reconstruction, its complications and management of biliary complications after adult liver transplantation: a systematic review of the incidence, risk factors and outcome. *Transpl Int* 2011; **24**: 379-392 [PMID: 21143651 DOI: 10.1111/j.1432-2277.2010.01202.x]
  - 36 **Gastaca M**. Biliary complications after orthotopic liver transplantation: a review of incidence and risk factors. *Transplant Proc* 2011; **44**: 1545-1549 [PMID: 22841209 DOI: 10.1016/j.transproceed.2012.05.008]
  - 37 **Yazumi S**, Yoshimoto T, Hisatsune H, Hasegawa K, Kida M, Tada S, Uenoyama Y, Yamauchi J, Shio S, Kasahara M, Ogawa K, Egawa H, Tanaka K, Chiba T. Endoscopic treatment of biliary complications after right-lobe living-donor liver transplantation with duct-to-duct biliary anastomosis. *J Hepatobiliary Pancreat Surg* 2006; **13**: 502-510 [PMID: 17139423 DOI: 10.1007/s00534-005-1084-y]
  - 38 **Rerknimitr R**, Sherman S, Fogel EL, Kalayci C, Lumeng L, Chalasani N, Kwo P, Lehman GA. Biliary tract complications after orthotopic liver transplantation with choledochcholedochostomy anastomosis: endoscopic findings and results of therapy. *Gastrointest Endosc* 2002; **55**: 224-231 [PMID: 11818927 DOI: 10.1067/mge.2002.120813]
  - 39 **Pfau PR**, Kochman ML, Lewis JD, Long WB, Lucey MR, Olthoff K, Shaked A, Ginsberg GG. Endoscopic management of postoperative biliary complications in orthotopic liver transplantation. *Gastrointest Endosc* 2000; **52**: 55-63 [PMID: 10882963 DOI: 10.1067/mge.2000.106687]
  - 40 **Thethy S**, Thomson BNj, Pleass H, Wigmore SJ, Madhavan K, Akyol M, Forsythe JL, James Garden O. Management of biliary tract complications after orthotopic liver transplantation. *Clin Transplant* 2004; **18**: 647-653 [PMID: 15516238 DOI: 10.1111/j.1399-0012.2004.00254.x]
  - 41 **Fujita S**, Fujikawa T, Mizuno S, Reed AI, Kim RD, Howard RJ, Firpi RJ, Nelson DR, Hemming AW. Is early recurrence of hepatitis C associated with biliary anastomotic stricture after liver transplantation? *Transplantation* 2007; **84**: 1631-1635 [PMID: 18165775 DOI: 10.1097/01.tp.0000295983.55088.96]
  - 42 **Suárez F**, Otero A, Solla M, Arnal F, Lorenzo MJ, Marini M, Vázquez-Iglesias JL, Gómez M. Biliary complications after liver transplantation from maastricht category-2 non-heart-beating donors. *Transplantation* 2008; **85**: 9-14 [PMID: 18192905 DOI: 10.1097/01.tp.0000297945.83430.ce]
  - 43 **Fujikawa T**, Fujita S, Mekeel KL, Reed AI, Foley DP, Kim RD, Howard RJ, Hemming AW. Effect of early recurrence of hepatitis C on late biliary anastomotic stricture after liver transplantation. *Transplant Proc* 2006; **38**: 3661-3662 [PMID: 17175360 DOI:

- 10.1016/j.transproceed.2006.10.131]
- 44 **Abt P**, Crawford M, Desai N, Markmann J, Olthoff K, Shaked A. Liver transplantation from controlled non-heart-beating donors: an increased incidence of biliary complications. *Transplantation* 2003; **75**: 1659-1663 [PMID: 12777852 DOI: 10.1097/01.TP.0000062574.18648.7C]
- 45 **Kowdley KV**, Fawaz KA, Kaplan MM. Extrahepatic biliary stricture associated with cytomegalovirus in a liver transplant recipient. *Transpl Int* 1996; **9**: 161-163 [PMID: 8639259 DOI: 10.1111/j.1432-2277.1996.tb00872.x]
- 46 **Halme L**, Hockerstedt K, Lautenschlager I. Cytomegalovirus infection and development of biliary complications after liver transplantation. *Transplantation* 2003; **75**: 1853-1858 [PMID: 12811245 DOI: 10.1097/01.TP.0000064620.08328.E5]
- 47 **Koneru B**, Sterling MJ, Bahramipour PF. Bile duct strictures after liver transplantation: a changing landscape of the Achilles' heel. *Liver Transpl* 2006; **12**: 702-704 [PMID: 16628684 DOI: 10.1002/lt.20753]
- 48 **Maheshwari A**, Maley W, Li Z, Thuluvath PJ. Biliary complications and outcomes of liver transplantation from donors after cardiac death. *Liver Transpl* 2007; **13**: 1645-1653 [PMID: 18044778 DOI: 10.1002/lt.21212]
- 49 **Wojcicki M**, Milkiewicz P, Silva M. Biliary tract complications after liver transplantation: a review. *Dig Surg* 2008; **25**: 245-257 [PMID: 18628624 DOI: 10.1159/000144653]
- 50 **Thuluvath PJ**, Pfau PR, Kimmey MB, Ginsberg GG. Biliary complications after liver transplantation: the role of endoscopy. *Endoscopy* 2005; **37**: 857-863 [PMID: 16116539 DOI: 10.1055/s-2005-870192]
- 51 **Righi D**, Franchello A, Ricchiuti A, Breatta AD, Versace K, Calvo A, Romagnoli R, Fonio P, Gandini G, Salizzoni M. Safety and efficacy of the percutaneous treatment of bile leaks in hepaticojejunostomy or split-liver transplantation without dilatation of the biliary tree. *Liver Transpl* 2008; **14**: 611-615 [PMID: 18433033 DOI: 10.1002/lt.21416]
- 52 **Sheng R**, Sammon JK, Zajko AB, Campbell WL. Bile leak after hepatic transplantation: cholangiographic features, prevalence, and clinical outcome. *Radiology* 1994; **192**: 413-416 [PMID: 8029406 DOI: 10.1148/radiology.192.2.8029406]
- 53 **Londoño MC**, Balderramo D, Cárdenas A. Management of biliary complications after orthotopic liver transplantation: the role of endoscopy. *World J Gastroenterol* 2008; **14**: 493-497 [PMID: 18203278 DOI: 10.3748/wjg.14.493]
- 54 **Gor NV**, Levy RM, Ahn J, Kogan D, Dodson SF, Cohen SM. Biliary cast syndrome following liver transplantation: Predictive factors and clinical outcomes. *Liver Transpl* 2008; **14**: 1466-1472 [PMID: 18825683 DOI: 10.1002/lt.21492]
- 55 **Douzdjian V**, Abecassis MM, Johlin FC. Sphincter of Oddi dysfunction following liver transplantation. Screening by bedside manometry and definitive manometric evaluation. *Dig Dis Sci* 1994; **39**: 253-256 [PMID: 8313805]
- 56 **Clavien PA**, Camargo CA, Baillie J, Fitz JG. Sphincter of Oddi dysfunction after liver transplantation. *Dig Dis Sci* 1995; **40**: 73-74 [PMID: 7821122]
- 57 **Saleem A**, Baron TH. Successful endoscopic treatment of biliary cast syndrome in an orthotopic liver transplant patient with a Roux-en-Y anastomosis via balloon enteroscopy. *Liver Transpl* 2010; **16**: 527-529 [PMID: 20213831 DOI: 10.1002/lt.22007]
- 58 **Parsi MA**, Guardino J, Vargo JJ. Peroral cholangioscopy-guided stricture therapy in living donor liver transplantation. *Liver Transpl* 2009; **15**: 263-265 [PMID: 19177445 DOI: 10.1002/lt.21584]
- 59 **Navaneethan U**, Venkatesh PG, Al Mohajer M, Gelrud A. Successful diagnosis and management of biliary cast syndrome in a liver transplant patient using single operator cholangioscopy. *JOP* 2011; **12**: 461-463 [PMID: 21904071]
- 60 **Tsukui D**, Yano T, Nakazawa K, Osawa H, Kawano Y, Mizuta K, Kawarasaki H, Yamamoto H. Rendezvous technique combining double-balloon endoscopy with percutaneous cholangioscopy is useful for the treatment of biliary anastomotic obstruction after liver transplantation (with video). *Gastrointest Endosc* 2008; **68**: 1013-1015 [PMID: 18534587 DOI: 10.1016/j.gie.2008.02.034]
- 61 **Petersen BT**. Cholangioscopy for special applications: primary sclerosing cholangitis, liver transplant, and selective duct access. *Gastrointest Endosc Clin N Am* 2009; **19**: 579-586 [PMID: 19917463 DOI: 10.1016/j.giec.2009.06.003]
- 62 **Gürakar A**, Wright H, Camci C, Jaboor N. The application of SpyScope® technology in evaluation of pre and post liver transplant biliary problems. *Turk J Gastroenterol* 2010; **21**: 428-432 [PMID: 21331998]
- 63 **Johnston TD**, Gates R, Reddy KS, Nickl NJ, Ranjan D. Nonoperative management of bile leaks following liver transplantation. *Clin Transplant* 2000; **14**: 365-369 [PMID: 10946772 DOI: 10.1034/j.1399-0012.2000.14040102.x]
- 64 **Dumonceau JM**, Tringali A, Blero D, Devière J, Laugiers R, Heresbach D, Costamagna G. Biliary stenting: indications, choice of stents and results: European Society of Gastrointestinal Endoscopy (ESGE) clinical guideline. *Endoscopy* 2012; **44**: 277-298 [PMID: 22297801 DOI: 10.1055/s-0031-1291633]
- 65 **Morelli J**, Mulcahy HE, Willner IR, Cunningham JT, Draganov P. Long-term outcomes for patients with post-liver transplant anastomotic biliary strictures treated by endoscopic stent placement. *Gastrointest Endosc* 2003; **58**: 374-379 [PMID: 14528211]
- 66 **Solmi L**, Cariani G, Leo P, Miracolo A, Nigro G, Roda E. Results of endoscopic retrograde cholangiopancreatography in the treatment of biliary tract complications after orthotopic liver transplantation: our experience. *Hepatogastroenterology* 2007; **54**: 1004-1008 [PMID: 17629026]
- 67 **Phillips MS**, Bonatti H, Sauer BG, Smith L, Javaid M, Kahaleh M, Schmitt T. Elevated stricture rate following the use of fully covered self-expandable metal biliary stents for biliary leaks following liver transplantation. *Endoscopy* 2011; **43**: 512-517 [PMID: 21618151]
- 68 **Zoeft T**, Maldonado-Lopez EJ, Hilgard P, Malago M, Broelsch CE, Treichel U, Gerken G. Balloon dilatation vs. balloon dilatation plus bile duct endoprosthesis for treatment of anastomotic biliary strictures after liver transplantation. *Liver Transpl* 2006; **12**: 88-94 [PMID: 16382450 DOI: 10.1002/lt.20548]
- 69 **Zoeft T**, Maldonado de Dechêne EJ, Dechêne A, Malágo M, Beckebaum S, Paul A, Gerken G, Hilgard P. Optimized endoscopic treatment of ischemic-type biliary lesions after liver transplantation. *Gastrointest Endosc* 2012; **76**: 556-563 [PMID: 22898414 DOI: 10.1016/j.gie.2012.04.474]
- 70 **Kulaksiz H**, Weiss KH, Gotthardt D, Adler G, Stremmel W, Schaible A, Dogan A, Stiehl A, Sauer P. Is stenting necessary after balloon dilation of post-transplantation biliary strictures? Results of a prospective comparative study. *Endoscopy* 2008; **40**: 746-751 [PMID: 18702031 DOI: 10.1055/s-2008-1077489]
- 71 **Costamagna G**, Tringali A, Mutignani M, Perri V, Spada C, Pandolfi M, Galasso D. Endotherapy of postoperative biliary strictures with multiple stents: results after more than 10 years of follow-up. *Gastrointest Endosc* 2010; **72**: 551-557 [PMID: 20630514 DOI: 10.1016/j.gie.2010.04.052]
- 72 **Kao D**, Zepeda-Gomez S, Tandon P, Bain VG. Managing the post-liver transplantation anastomotic biliary stricture: multiple plastic versus metal stents: a systematic review. *Gastrointest Endosc* 2013; **77**: 679-691 [PMID: 23473000 DOI: 10.1016/j.gie.2013.01.015]
- 73 **Tabibian JH**, Asham EH, Han S, Saab S, Tong MJ, Goldstein L, Busuttill RW, Durazo FA. Endoscopic treatment of postorthotopic liver transplantation anastomotic biliary strictures with maximal stent therapy (with video). *Gastrointest Endosc* 2010; **71**: 505-512 [PMID: 20189508 DOI: 10.1016/j.gie.2009.10.023]
- 74 **Morelli G**, Fazel A, Judah J, Pan JJ, Forsmark C, Draganov P. Rapid-sequence endoscopic management of posttransplant anastomotic biliary strictures. *Gastrointest Endosc* 2008; **67**: 879-885 [PMID: 18178206 DOI: 10.1016/j.gie.2007.08.046]
- 75 **Hu B**, Gao DJ, Yu FH, Wang TT, Pan YM, Yang XM. Endoscopic stenting for post-transplant biliary stricture: usefulness of a novel removable covered metal stent. *J Hepatobiliary Pancreat Sci* 2011; **18**: 640-645 [PMID: 21643818 DOI: 10.1007/s00534-011-0408-3]
- 76 **Kahaleh M**, Brijbassie A, Sethi A, Degaetani M, Poneros JM, Loren DE, Kowalski TE, Sejjal DV, Patel S, Rosenkranz L,

- McNamara KN, Raijman I, Talreja JP, Gaidhane M, Sauer BG, Stevens PD. Multicenter trial evaluating the use of covered self-expanding metal stents in benign biliary strictures: time to revisit our therapeutic options? *J Clin Gastroenterol* 2013; **47**: 695-699 [PMID: 23442836 DOI: 10.1097/MCG.0b013e31827fd311]
- 77 **Traina M**, Tarantino I, Barresi L, Volpes R, Gruttadauria S, Petridis I, Gridelli B. Efficacy and safety of fully covered self-expandable metallic stents in biliary complications after liver transplantation: a preliminary study. *Liver Transpl* 2009; **15**: 1493-1498 [PMID: 19877248 DOI: 10.1002/lt.21886]
- 78 **García-Pajares F**, Sánchez-Antolín G, Pelayo SL, Gómez de la Cuesta S, Herranz Bachiller MT, Pérez-Miranda M, de La Serna C, Vallecillo Sande MA, Alcaide N, Llamas RV, Pacheco D, Caro-Patón A. Covered metal stents for the treatment of biliary complications after orthotopic liver transplantation. *Transplant Proc* 2010; **42**: 2966-2969 [PMID: 20970584 DOI: 10.1016/j.transproceed.2010.07.084]
- 79 **Sauer P**, Chahoud F, Gotthardt D, Stremmel W, Weiss KH, Büchler M, Schemmer P, Weitz J, Schaible A. Temporary placement of fully covered self-expandable metal stents in biliary complications after liver transplantation. *Endoscopy* 2012; **44**: 536-538 [PMID: 22370701 DOI: 10.1055/s-0031-1291714]
- 80 **Devière J**, Nageshwar Reddy D, Püspök A, Ponchon T, Bruno MJ, Bourke MJ, Neuhaus H, Roy A, González-Huix Lladó F, Barkun AN, Kortan PP, Navarrete C, Peetermans J, Blero D, Lakhtakia S, Dolak W, Lepilliez V, Poley JW, Tringali A, Costamagna G. Successful management of benign biliary strictures with fully covered self-expanding metal stents. *Gastroenterology* 2014; **147**: 385-395; quiz e15 [PMID: 24801350 DOI: 10.1053/j.gastro.2014.04.043]
- 81 **Kaffes A**, Griffin S, Vaughan R, James M, Chua T, Tee H, Dinesen L, Corte C, Gill R. A randomized trial of a fully covered self-expandable metallic stent versus plastic stents in anastomotic biliary strictures after liver transplantation. *Therap Adv Gastroenterol* 2014; **7**: 64-71 [PMID: 24587819 DOI: 10.1177/1756283X13503614]
- 82 **Chan CH**, Donnellan F, Byrne MF, Coss A, Haque M, Wiesenger H, Scudamore CH, Steinbrecher UP, Weiss AA, Yoshida EM. Response to endoscopic therapy for biliary anastomotic strictures in deceased versus living donor liver transplantation. *Hepatobiliary Pancreat Dis Int* 2013; **12**: 488-493 [PMID: 24103278 DOI: 10.1016/S1499-3872(13)60077-6]
- 83 **Hsieh TH**, Mekeel KL, Crowell MD, Nguyen CC, Das A, Aqel BA, Carey EJ, Byrne TJ, Vargas HE, Douglas DD, Mulligan DC, Harrison ME. Endoscopic treatment of anastomotic biliary strictures after living donor liver transplantation: outcomes after maximal stent therapy. *Gastrointest Endosc* 2013; **77**: 47-54 [PMID: 23062758 DOI: 10.1016/j.gie.2012.08.034]
- 84 **Gómez CM**, Dumonceau JM, Marcolongo M, de Santibañes E, Ciardullo M, Pekolj J, Palavecino M, Gadano A, Dávalos J. Endoscopic management of biliary complications after adult living-donor versus deceased-donor liver transplantation. *Transplantation* 2009; **88**: 1280-1285 [PMID: 19996927 DOI: 10.1097/TP.0b013e3181bb48c2]
- 85 **Kim TH**, Lee SK, Han JH, Park do H, Lee SS, Seo DW, Kim MH, Song GW, Ha TY, Kim KH, Hwang S, Lee SG. The role of endoscopic retrograde cholangiography for biliary stricture after adult living donor liver transplantation: technical aspect and outcome. *Scand J Gastroenterol* 2011; **46**: 188-196 [PMID: 20955089 DOI: 10.3109/00365521.2010.522722]
- 86 **Chang JH**, Lee IS, Choi JY, Yoon SK, Kim DG, You YK, Chun HJ, Lee DK, Choi MG, Chung IS. Biliary Stricture after Adult Right-Lobe Living-Donor Liver Transplantation with Duct-to-Duct Anastomosis: Long-Term Outcome and Its Related Factors after Endoscopic Treatment. *Gut Liver* 2010; **4**: 226-233 [PMID: 20559526 DOI: 10.5009/gnl.2010.4.2.226]
- 87 **Seo JK**, Ryu JK, Lee SH, Park JK, Yang KY, Kim YT, Yoon YB, Lee HW, Yi NJ, Suh KS. Endoscopic treatment for biliary stricture after adult living donor liver transplantation. *Liver Transpl* 2009; **15**: 369-380 [PMID: 19326412 DOI: 10.1002/lt.21700]
- 88 **Chok KS**, Chan SC, Cheung TT, Sharr WW, Chan AC, Fan ST, Lo CM. A retrospective study on risk factors associated with failed endoscopic treatment of biliary anastomotic stricture after right-lobe living donor liver transplantation with duct-to-duct anastomosis. *Ann Surg* 2014; **259**: 767-772 [PMID: 23657086 DOI: 10.1097/SLA.0b013e318294d0ce]
- 89 **Chang JH**, Lee IS, Chun HJ, Choi JY, Yoon SK, Kim DG, You YK, Choi MG, Choi KY, Chung IS. Usefulness of the rendezvous technique for biliary stricture after adult right-lobe living-donor liver transplantation with duct-to-duct anastomosis. *Gut Liver* 2010; **4**: 68-75 [PMID: 20479915 DOI: 10.5009/gnl.2010.4.1.68]
- 90 **Kyoden Y**, Tamura S, Sugawara Y, Matsui Y, Togashi J, Kaneko J, Kokudo N, Makuuchi M. Incidence and management of biliary complications after adult-to-adult living donor liver transplantation. *Clin Transplant* 2010; **24**: 535-542 [PMID: 19849703 DOI: 10.1111/j.1399-0012.2009.01124.x]
- 91 **Tsujino T**, Isayama H, Sugawara Y, Sasaki T, Kogure H, Nakai Y, Yamamoto N, Sasahira N, Yamashiki N, Tada M, Yoshida H, Kokudo N, Kawabe T, Makuuchi M, Omata M. Endoscopic management of biliary complications after adult living donor liver transplantation. *Am J Gastroenterol* 2006; **101**: 2230-2236 [PMID: 16952286 DOI: 10.1111/j.1572-0241.2006.00797.x]
- 92 **Sanada Y**, Mizuta K, Yano T, Hatanaka W, Okada N, Wakiya T, Umehara M, Egami S, Urahashi T, Hishikawa S, Fujiwara T, Sakuma Y, Hyodo M, Yamamoto H, Yasuda Y, Kawarasaki H. Double-balloon enteroscopy for bilioenteric anastomotic stricture after pediatric living donor liver transplantation. *Transpl Int* 2011; **24**: 85-90 [PMID: 20738835 DOI: 10.1111/j.1432-2277.2010.01156.x]
- 93 **Sakakihara I**, Kato H, Muro S, Noma Y, Yamamoto N, Harada R, Horiguchi S, Tsutsumi K, Okada H, Yamamoto K, Sadamori H, Yagi T. Double-balloon enteroscopy for choledochojejunal anastomotic stenosis after hepato-biliary-pancreatic operation. *Dig Endosc* 2015; **27**: 146-154 [PMID: 25041448 DOI: 10.1111/den.12332]
- 94 **Srinivasaiah N**, Reddy MS, Balupuri S, Talbot D, Jaques B, Manas D. Biliary cast syndrome: literature review and a single centre experience in liver transplant recipients. *Hepatobiliary Pancreat Dis Int* 2008; **7**: 300-303 [PMID: 18522886]
- 95 **Dumonceau JM**, Andriulli A, Elmunzer BJ, Mariani A, Meister T, Deviere J, Marek T, Baron TH, Hassan C, Testoni PA, Kapral C. Prophylaxis of post-ERCP pancreatitis: European Society of Gastrointestinal Endoscopy (ESGE) Guideline - updated June 2014. *Endoscopy* 2014; **46**: 799-815 [PMID: 25148137 DOI: 10.1055/s-0034-1377875]

**P- Reviewer:** Boucek C, Uchiyama H **S- Editor:** Ji FF  
**L- Editor:** A **E- Editor:** Wu HL





Published by **Baishideng Publishing Group Inc**

8226 Regency Drive, Pleasanton, CA 94588, USA

Telephone: +1-925-223-8242

Fax: +1-925-223-8243

E-mail: [bpgoffice@wjgnet.com](mailto:bpgoffice@wjgnet.com)

Help Desk: <http://www.wjgnet.com/esps/helpdesk.aspx>

<http://www.wjgnet.com>

