

February 9, 2015

Dear Editor,

Please find enclosed the edited manuscript in Word format (file name: 15598-review.doc).

Title: Left ventricular twist in cardiomyopathy, dance of the helices.

Author: Floris Kauer, Marcel Leonard Geleijnse, Bastiaan Martijn van Dalen

Name of Journal: *World Journal of Cardiology*

ESPS Manuscript NO: 15598

The manuscript has been improved according to the suggestions of the editor and reviewers:

Editor

- (1) The conflicted interest statement is adjusted and also added as a separate file.
- (2) References have been updated with DOI's as far as available. References 1-3 are not listed on the Pubmed. Only the first page of reference 1 is available (first pages uploaded as separate files).

Reviewer no. 2446694

- (1) Comment: This review is well-written and very educative.
Reply: We thank the reviewer for the kind compliments.
- (2) Comment: To make the readers understand left ventricular twist more closely, the authors had better provide a table of summary or representative figures of speckle tracking imaging in 4 kinds of myocardial diseases.
Reply: We fully agree with the reviewer and added a figure (Figure 2).

Reviewer no. 225356

- (1) Comment: The paper by Kauer et al. is a very well-written editorial on the left ventricular twist in physiological conditions and in cardiomyopathies. The topic is also very new and interesting.
Reply: We thank the reviewer for the kind compliments.
- (2) Comment: In the first or third paragraph, a picture should be added to make it clear to a larger readership the mechanics of twisting and untwisting.
Reply: We fully agree with the reviewer and added a figure (Figure 2).
- (3) Comment: Similarly, in the second paragraph, a figure showing left ventricular twist by speckle tracking echography should be added.
Reply: We fully agree with the reviewer and added a figure (Figure 1).
- (4) Comment: There are some typographical errors throughout the manuscript. E.G.: page 6, line 19, the phrase "Even in dilated..." is not clear because probably a "and" is missing; page 9 line 3 "infraction" instead of "infarction".
Reply: Revision has been made according to the suggestions of the reviewer. The changes are highlighted in yellow in the text.

Reviewer no. 227355

- (1) Comment: This is an interesting paper for the clinical practice... Overall the paper appears to be

carefully examined and data adequately discussed. I suggest that this paper have the priority to be published in WJC.

Reply: We thank the reviewer for the kind compliments.

Reviewer no. 225356

- (1) Comment: This is an interesting review article of revision coming from authors with recognized expertise in the field.

Reply: We thank the reviewer for the kind compliments.

- (2) Comment: Given that the issue is imaging I think that some images showing representative cases are necessary, particularly a case of rigid basal and apical motion in a patient with non compacted cardiomyopathy, but also in other reviewed entities.

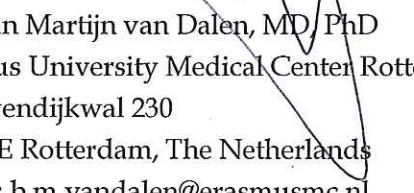
Reply: We fully agree with the reviewer and added figures (Figure 1 and 2).

- (3) Comment: Please revise this sentence in Physiology: "The left ventricular sphericity index (as measure of change in left ventricle fibre orientation) in patients with a dilated cardiomyopathy showed a linear relation with peak systolic twist"

Reply: Revision has been made according to the suggestions of the reviewer. The changes are highlighted in yellow in the text.

Thank you again for publishing our manuscript in the *World Journal of Cardiology*.

Sincerely yours,



Bastiaan Martijn van Dalen, MD, PhD
Erasmus University Medical Center Rotterdam, The Thoraxcenter, Room BA 302
's Gravendijkwal 230
3015 CE Rotterdam, The Netherlands
E-Mail: b.m.vandalen@erasmusmc.nl
Telephone: +31 10 4633533