

Resected tumor seeding in stomach wall due to endoscopic ultrasonography-guided fine needle aspiration of pancreatic adenocarcinoma

Akiko Tomonari, Akio Katanuma, Tomoaki Matsumori, Hajime Yamazaki, Itsuki Sano, Ryuki Minami, Manabu Sen-yo, Satoshi Ikarashi, Toshifumi Kin, Kei Yane, Kuniyuki Takahashi, Toshiya Shinohara, Hiroyuki Maguchi

Akiko Tomonari, Akio Katanuma, Hajime Yamazaki, Itsuki Sano, Ryuki Minami, Manabu Sen-yo, Satoshi Ikarashi, Toshifumi Kin, Kei Yane, Kuniyuki Takahashi, Hiroyuki Maguchi, Center for Gastroenterology, Teine-Keijinkai Hospital, Sapporo 006-8555, Japan

Tomoaki Matsumori, Department of Gastroenterology and Hepatology, Kyoto University Graduate School of Medicine, Kyoto 606-8501, Japan

Toshiya Shinohara, Department of Pathology, Teine-Keijinkai Hospital, Sapporo 006-8555, Japan

Author contributions: All authors helped to perform the research; Tomonari A wrote the paper; all authors have approved the final draft of the manuscript.

Institutional review board statement: Teine-keijinkei Hospital Institutional Review Board for Conduction and Submission of the study.

Informed consent statement: The patient provided informed consent prior to study enrollment.

Conflict-of-interest statement: To the best of our knowledge, no conflict of interest, financial or other, exists to any authors listed in this manuscript.

Open-Access: This article is an open-access article which was selected by an in-house editor and fully peer-reviewed by external reviewers. It is distributed in accordance with the Creative Commons Attribution Non Commercial (CC BY-NC 4.0) license, which permits others to distribute, remix, adapt, build upon this work non-commercially, and license their derivative works on different terms, provided the original work is properly cited and the use is non-commercial. See: <http://creativecommons.org/licenses/by-nc/4.0/>

Correspondence to: Akiko Tomonari, MD, Center for Gastroenterology, Teine-Keijinkai Hospital, 1-12-1-40 Maeda, Teine-ku, Sapporo 006-8555, Japan. narinarii@yahoo.co.jp
Telephone: +81-11-6818111

Fax: +81-11-6852967

Received: December 21, 2014

Peer-review started: December 22, 2014

First decision: January 8, 2015

Revised: February 10, 2015

Accepted: March 27, 2015

Article in press: March 27, 2015

Published online: July 21, 2015

Abstract

Endoscopic ultrasonography-guided fine needle aspiration (EUS-FNA) is a useful and relatively safe tool for the diagnosis and staging of pancreatic cancer. However, there have recently been several reports of tumor seeding after EUS-FNA of adenocarcinomas. A 78-year-old man was admitted to our hospital due to upper gastric pain. Examinations revealed a 20 mm mass in the pancreatic body, for which EUS-FNA was performed. The cytology of the lesion was adenocarcinoma, and the stage of the cancer was T3N0M0. The patient underwent surgery with curative intent, followed by adjuvant chemotherapy with S-1. An enlarging gastric submucosal tumor was found on gastroscopy at 28 mo after surgery accompanied by a rising level of CA19-9. Biopsy result was adenocarcinoma, consistent with a pancreatic primary tumor. Tumor seeding after EUS-FNA was strongly suspected. The patient underwent surgical resection of the gastric tumor with curative intent. The pathological result of the resected gastric specimen was adenocarcinoma with a perfectly matched mucin special stain result with the previously resected pancreatic cancer. This is the first case report of tumor seeding after EUS-FNA which was surgically resected and inspected pathologically.

Key words: Endoscopic ultrasonography-guided fine

needle aspiration; Tumor seeding; Pancreatic cancer

© The Author(s) 2015. Published by Baishideng Publishing Group Inc. All rights reserved.

Core tip: This manuscript is the first case report about tumor seeding after endoscopic ultrasonography-guided fine needle aspiration (EUS-FNA) which was surgically resected and inspected pathologically. EUS-FNA is a widely performed procedure; however, there are no clear guidelines indicating the selection of treatments in cases of tumor seeding after the procedure, as this adverse event is relatively rare. This manuscript may help in the selection of patients undergoing EUS-FNA, and clarifies the points we should be careful about after the procedure.

Tomonari A, Katanuma A, Matsumori T, Yamazaki H, Sano I, Minami R, Sen-yo M, Ikarashi S, Kin T, Yane K, Takahashi K, Shinohara T, Maguchi H. Resected tumor seeding in stomach wall due to endoscopic ultrasonography-guided fine needle aspiration of pancreatic adenocarcinoma. *World J Gastroenterol* 2015; 21(27): 8458-8461 Available from: URL: <http://www.wjgnet.com/1007-9327/full/v21/i27/8458.htm> DOI: <http://dx.doi.org/10.3748/wjg.v21.i27.8458>

INTRODUCTION

Endoscopic ultrasonography-guided fine needle aspiration (EUS-FNA) is a useful and relatively safe tool for the diagnosis and staging of pancreatic cancer. The reported complication rates of EUS-FNA are low (< 1% in large centers^[1]), and the risks of tumor seeding are lower compared to transcutaneous methods^[2,3]. However, there have recently been several reports of tumor seeding after EUS-FNA of non-cystic solid adenocarcinomas^[4,5]. The previously reported cases were all diagnosed at unresectable stages when the tumor seeding lesions were found. This is the first case report of tumor seeding after EUS-FNA which was surgically resected and inspected pathologically.

CASE REPORT

A 78-year-old man with persistent upper gastric pain was referred to our center for detailed examination. Computed tomography (CT) revealed a 20-mm-diameter hypodense mass lesion in the pancreatic body, with an upstream dilatation of the main pancreatic duct (Figure 1). CA19-9 was abnormal with a level of 162.4 kU/mL (normal range, 0-37.0 kU/mL). At EUS, the patient had a 21-mm-diameter hypoechoic mass in the pancreatic body. EUS-FNA of the mass was performed using a 22-G needle (Expect, Boston Scientific, Natick, MA) (Figure 2). Suction was applied at each pass, and a total of two passes were made. Cytology of the lesion revealed an adenocarcinoma.

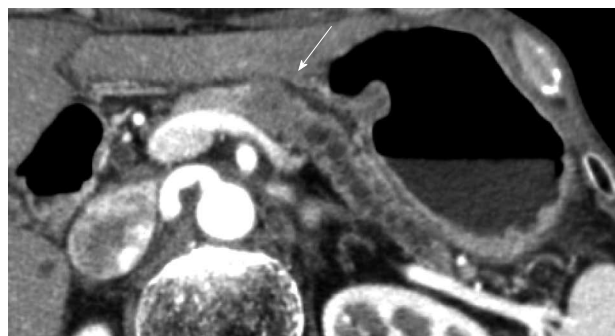


Figure 1 Computed tomography showing a 20-mm mass lesion in the pancreatic body (arrow).

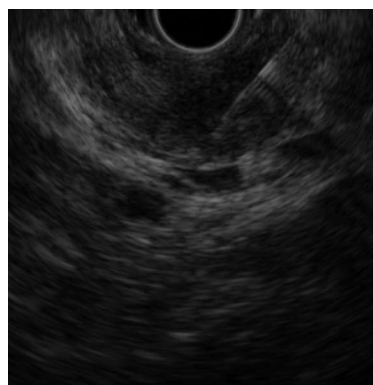


Figure 2 Endoscopic ultrasonography-guided fine needle aspiration of the 20-mm hypoechoic mass lesion was performed using a 22-G needle.

No metastatic disease was found and the patient underwent surgery with curative intent.

There were no liver metastases, ascites, or peritoneal implantation at surgery. An intra-operative frozen section diagnosis of a lymph node around the abdominal aorta was performed, which revealed to be negative for metastasis. A 20-mm palpable mass was identified, with evidence of inflammation in the distal pancreas. Distal pancreatectomy and splenectomy were performed. Histology of the specimen revealed a 25 mm × 25 mm mass with no lymphatic or vascular involvement, and the resection margins were negative for malignancy. There were no abnormalities in the spleen. The final diagnosis was T3N0M0 with an extension of moderately differentiated adenocarcinoma beyond the pancreas in the ventral direction.

The patient underwent adjuvant chemotherapy with S-1 starting at 2 mo after surgery. At 9 mo after surgery, a periodical follow-up gastroscopy performed at a private clinic revealed a 5-mm-diameter submucosal tumor at the posterior wall of the gastric body. The patient had no symptoms at that time. The private clinician who had performed the exam made the decision to follow the submucosal tumor, and gastroscopy was repeated after 2 mo, which showed no changes in the shape or the size of the submucosal tumor. At 8 mo after surgery, CA19-9 level gradually started to rise. Gastroscopy performed at 28 mo

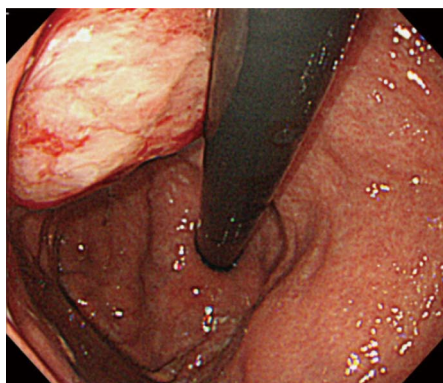


Figure 3 Submucosal tumor at the gastric body increased in size at 28 mo after surgery.

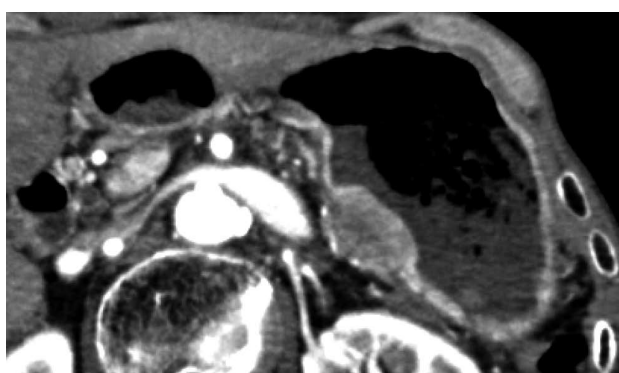


Figure 4 Computed tomography shows the submucosal tumor located adjacent to the pancreatic resection site.

after surgery revealed an increase in the size of the submucosal tumor, and at this point, the patient was referred to our center for further examinations (Figure 3). Histology of the lesion indicated adenocarcinoma, consistent with a pancreatic primary tumor. CT showed a 28-mm submucosal tumor adjacent to the pancreatic resection site (Figure 4). There were no apparent metastatic lesions, and the patient underwent surgery with curative intent.

Subtotal gastrectomy was performed. Histology of the specimen revealed a 32 mm × 30 mm submucosal tumor, consisting of moderately to well differentiated adenocarcinoma (Figure 5). The specimen was positive for vascular and lymphatic involvement. Mucin special stain results for the resected stomach specimen were MUC1 positive, MUC2 negative, MUC5AC positive, and MUC6 negative. Mucin special stains for the previously resected specimen of the pancreas were additionally performed. The results were MUC1 positive, MUC2 negative, MUC5AC positive, and MUC6 negative, which were perfectly compatible with the resected stomach lesion.

DISCUSSION

Although gastric recurrence of adenocarcinoma may

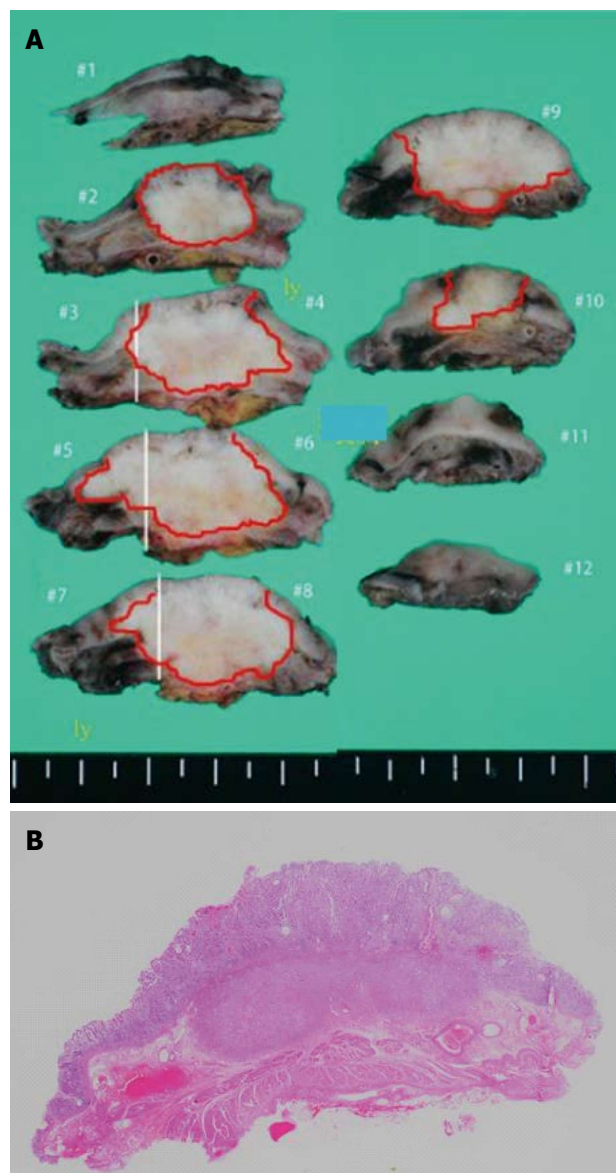


Figure 5 Resected specimen of the needle tract seeding in the stomach. The tumor is 25 mm × 25 mm, with a whitish appearance (A). The tumor is located in the submucosal layer (B). Hematoxylin and eosin staining.

occur by direct invasion, the resected specimen in this case strongly suggests tumor seeding after EUS-FNA due to the facts that its origin is submucosal, and the mucin special stains were perfectly matched to the original pancreatic cancer. There has been a retrospective study which reported that there is no association with an increased rate of gastric or peritoneal cancer recurrence following EUS-FNA^[6]. However, it is also true that there have been several reports of tumor seeding after the procedure. This may be due to the rate of tumor seeding after EUS-FNA being so low that it is statistically difficult to establish an association between the procedure and the recurrence. Also, unresected recurrences are difficult to distinguish between direct invasion and tract seeding, and this may contribute to the fact that the

reported incidence rate of seeding is so low.

EUS-FNA is an important procedure usually performed pre-operatively to determine the indication of surgical resection of the tumor. The reported incidences of tumor seeding are so low that the advantage of performing EUS-FNA before surgery may not outweigh the risk of needle tract seeding. However, as the number of EUS-FNA is expected to continue to increase, the possibility of post-procedural EUS-FNA needle tract seeding should always be minded. In cases when surgical resection will not include the needle tract (e.g., resection of the tail/body of the pancreas), EUS-FNA should be either avoided, or the number of needle passes limited. When EUS-FNA is indispensable for the diagnosis and treatment of the disease, excision of the needle tract path may be necessary for consideration. When this is not possible, close periodical examinations including gastroscopy should be scheduled for patients who undergo EUS-FNA without needle tract resection.

COMMENTS

Case characteristics

A case of tumor seeding of a pancreatic adenocarcinoma in the stomach wall at the endoscopic ultrasonography-guided fine needle aspiration (EUS-FNA) puncture site, was treated surgically and inspected pathologically.

Clinical diagnosis

A submucosal tumor of the stomach wall found at a periodical post-operative endoscopy was suspected as a seeding tumor recurrence of the resected pancreatic adenocarcinoma.

Differential diagnosis

Pancreatic adenocarcinoma metastasis or a new completely separate submucosal lesion such as a GIST.

Laboratory diagnosis

Periodical tumor marker follow-ups were performed, showing a gradual CA19-9 increase.

Imaging diagnosis

Periodical gastroscopy revealed a lesion in a submucosal tumor form at the puncture site of the EUS-FNA which was performed preoperatively.

Pathological diagnosis

Endoscopically performed biopsy revealed an adenocarcinoma, leading to the suspicion of a tumor recurrence as a seeding after EUS-FNA.

Treatment

Subtotal gastrectomy was performed, and mucin special stain results for the resected stomach specimen were perfectly compatible with the previously resected pancreatic adenocarcinoma.

Experiences and lessons

When EUS-FNA is indispensable for the diagnosis and treatment of the disease, excision of the needle tract path may be necessary for consideration. When this is not possible, close periodical examinations including gastroscopy should be scheduled for patients who undergo EUS-FNA without needle tract resection.

Peer-review

This is a rare case of tumor recurrence of a pancreatic adenocarcinoma as seeding after EUS-FNA, treated surgically and inspected pathologically.

REFERENCES

- 1 Carrara S, Arcidiacono PG, Mezzi G, Petrone MC, Boemo C, Testoni PA. Pancreatic endoscopic ultrasound-guided fine needle aspiration: complication rate and clinical course in a single centre. *Dig Liver Dis* 2010; **42**: 520-523 [PMID: 19955025 DOI: 10.1016/j.dld.2009.10.002]
- 2 Smith EH. Complications of percutaneous abdominal fine-needle biopsy. Review. *Radiology* 1991; **178**: 253-258 [PMID: 1984314 DOI: 10.1148/radiology.178.1.1984314]
- 3 Micames C, Jowell PS, White R, Paulson E, Nelson R, Morse M, Hurwitz H, Pappas T, Tyler D, McGrath K. Lower frequency of peritoneal carcinomatosis in patients with pancreatic cancer diagnosed by EUS-guided FNA vs. percutaneous FNA. *Gastrointest Endosc* 2003; **58**: 690-695 [PMID: 14595302 DOI: 10.1016/S0016-5107(03)02009-1]
- 4 Paquin SC, Gariépy G, Lepanto L, Bourdages R, Raymond G, Sahai AV. A first report of tumor seeding because of EUS-guided FNA of a pancreatic adenocarcinoma. *Gastrointest Endosc* 2005; **61**: 610-611 [PMID: 15812422 DOI: 10.1016/S0016-5107(05)00082-9]
- 5 Katanuma A, Maguchi H, Hashigo S, Kaneko M, Kin T, Yane K, Kato R, Kato S, Harada R, Osanai M, Takahashi K, Shinohara T, Itoi T. Tumor seeding after endoscopic ultrasound-guided fine-needle aspiration of cancer in the body of the pancreas. *Endoscopy* 2012; **44** Suppl 2 UCTN: E160-E161 [PMID: 22622721 DOI: 10.1055/s-0031-1291716]
- 6 Ngamruengphong S, Xu C, Woodward TA, Raimondo M, Stauffer JA, Asbun HJ, Wallace MB. Risk of gastric or peritoneal recurrence, and long-term outcomes, following pancreatic cancer resection with preoperative endosonographically guided fine needle aspiration. *Endoscopy* 2013; **45**: 619-626 [PMID: 23881804 DOI: 10.1055/s-0033-1344216]

P- Reviewer: Altonbary AY, Hirahara N S- Editor: Qi Y

L- Editor: Wang TQ E- Editor: Liu XM





Published by **Baishideng Publishing Group Inc**

8226 Regency Drive, Pleasanton, CA 94588, USA

Telephone: +1-925-223-8242

Fax: +1-925-223-8243

E-mail: bpgoffice@wjgnet.com

Help Desk: <http://www.wjgnet.com/esps/helpdesk.aspx>

<http://www.wjgnet.com>



ISSN 1007-9327



9 771007 932045