

Coumadin ridge: An incidental finding of a left atrial pseudotumor on transthoracic echocardiography

Aadil Mubeen Lodhi, Tin Nguyen, Christopher Bianco, Assad Movahed

Aadil Mubeen Lodhi, Tin Nguyen, Christopher Bianco, Assad Movahed, Department of Cardiovascular Sciences, East Carolina University, Brody School of Medicine, East Carolina Heart Institute, Greenville, NC 27834, United States

Author contributions: Lodhi AM, Nguyen T, Bianco C and Movahed A contributed to the manuscript writing and revision.

Supported by The “East Carolina Heart Institute”.

Institutional review board statement: This study was case report and so no approval was required from our institution.

Informed consent statement: Consent was obtained from the patient at the time of investigations, but not at the time of writing patient case report.

Conflict-of-interest statement: None.

Open-Access: This article is an open-access article which was selected by an in-house editor and fully peer-reviewed by external reviewers. It is distributed in accordance with the Creative Commons Attribution Non Commercial (CC BY-NC 4.0) license, which permits others to distribute, remix, adapt, build upon this work non-commercially, and license their derivative works on different terms, provided the original work is properly cited and the use is non-commercial. See: <http://creativecommons.org/licenses/by-nc/4.0/>

Correspondence to: Assad Movahed, MD, Department of Cardiovascular Sciences, East Carolina University, Brody School of Medicine, East Carolina Heart Institute, 115 Heart Drive, Mail Stop 651, Greenville, NC 27834, United States. movaheda@ecu.edu
Telephone: +1-252-7444400
Fax: +1-252-7447724

Received: January 5, 2015

Peer-review started: January 7, 2015

First decision: March 6, 2015

Revised: March 30, 2015

Accepted: June 15, 2015

Article in press: June 16, 2015

Published online: September 16, 2015

Abstract

Coumadin ridge is a normal anatomic variant that is occasionally found in the left atrium. It can present as a linear or nodular mass which can undulate with cardiac motion and if particularly prominent, can easily be mistaken for a tumor or thrombus. Careful evaluation and consideration of the common variants discussed in this review can help limit misdiagnosis, as well as unnecessary workup and treatment. We present a case of coumadin ridge that was found on a patient using two-dimensional transthoracic echocardiography.

Key words: Coumadin ridge; Pseudotumor; Warfarin ridge; Left atrial pseudotumor

© The Author(s) 2015. Published by Baishideng Publishing Group Inc. All rights reserved.

Core tip: As we improve imaging modalities, normal anatomic variants of the heart are coming to our attention more frequently. Coumadin ridge is an example of such a variant that is occasionally found on various imaging modalities of the heart, including transthoracic echocardiography, transesophageal echocardiography, cardiac magnetic imaging, among others. Coumadin ridge is a term that refers to a part of the left atrium that lies between the left atrial appendage and the left superior pulmonary vein. Since this is a not a common finding, and due to its shape and location, it has the potential of being misdiagnosed as a left atrial myoxoma or thrombus.

Lodhi AM, Nguyen T, Bianco C, Movahed A. Coumadin ridge: An incidental finding of a left atrial pseudotumor on transthoracic echocardiography. *World J Clin Cases* 2015; 3(9): 831-834 Available from: URL: <http://www.wjgnet.com/2307-8960/full/v3/i9/831.htm> DOI: <http://dx.doi.org/10.12998/wjcc.v3.i9.831>

INTRODUCTION

As imaging modalities continue to improve in resolution and clarity, several normal anatomic variants of the heart have come to our attention. One of these normal variants is the coumadin ridge, which is found in the left atrium between the left atrial appendage and the left superior pulmonary vein. Although the coumadin ridge is a normal anatomic finding, its shape and location can cause it to be mistaken for a tumor or thrombus, leading to unnecessary, risky, and costly treatments for patients. In this case report, we present a patient in whom a coumadin ridge was found using two-dimensional transthoracic echocardiography with color Doppler.

CASE REPORT

A 58-year-old African American woman with hypertension, morbid obesity, and no remarkable history of heart disease presented to general medicine clinic with complaints of worsening exertional dyspnea with abdominal and lower extremity swelling. She denied chest pain, palpitation, orthopnea, or paroxysmal nocturnal dyspnea. Her medications included aspirin 81 mg, amlodipine 10 mg, hydrochlorothiazide 25 mg, and losartan 50 mg. She weighed 114 kg with a body mass index of 41 kg/m². Physical examination revealed a blood pressure of 170/88 mmHg, pulse of 72 bpm, and respiration rate of 18 breaths per minute. Lungs were clear to auscultation. There was no jugular venous distention. Normal heart sounds, no S3 or S4, no murmurs, and no rubs. No hepatomegaly or ascites was present. There was 1+ pitting edema over the dorsum of each foot. An electrocardiography showed sinus rhythm with a heart rate of 63 and left atrial abnormality (Figure 1). Given long-standing history of hypertension, worsening exertional dyspnea and lower extremity edema, a transthoracic echocardiography was performed to evaluate her cardiac anatomy and function, which showed prominent coumadin ridge in the left atrium, mild concentric left ventricular hypertrophy, grade II left ventricular diastolic dysfunction with pseudonormalization pattern, normal valves and normal biventricular size and systolic function (Figures 2 and 3). All other workup was negative in assessing the etiology of the patient's edema and worsening exertional dyspnea, including a complete metabolic panel, thyroid stimulating hormone, pulmonary function tests, and urine analysis. The patient's serum albumin level was also within normal limits. The patient's elevated blood pressure was improved by up-titrating her losartan to 100 mg. The patient's edema improved with lifestyle changes such as keeping her feet elevated. Her worsening exertional dyspnea was attributed to her conditioning, and physical therapy was recommended.

DISCUSSION

Over the past few decades, echocardiography has

become an increasingly common tool to assess cardiac anatomy and function. As imaging modalities continue to improve in resolution and clarity, we are more likely to come across normal anatomic variants of the heart. Some of these normal variants include the eustachian valve, chiari network, and crista terminalis of the right atrium, lipomatous hypertrophy of the interatrial septum, interatrial aneurysms, pectinate muscles of the right and left atriums, transverse sinus of the pericardium, moderator band of the right ventricle, Lambd's excrescence of the aortic valve, and coumadin ridge of the left atrium^[1].

The coumadin ridge is a prominent, muscular ridge of tissue that lies in the left atrium in between the left superior pulmonary vein and the left atrial appendage^[2]. It may often appear to be attached to the roof of the left atrial appendage, with a rounded end extending into the left atrium^[2]. Due to this rounded end, the coumadin ridge is often referred to as a "Q-tip sign" on echocardiography^[2]. It is important to keep in mind that it may not always appear rounded. When viewing it in the parasternal long axis view, it may appear as a linear band within the left atrium (LA)^[2]. Also, when several cross sections of heart specimens were looked at along their narrowest point, 75% of the samples were shown to be round, 15% flat, and 10% pointed^[3].

In our case, we used two-dimensional transthoracic echocardiography to show the coumadin ridge in its rounded and flattened shape. Due to its rounded edge, the coumadin ridge has often been mistaken for a thrombus, thereby, resulting in unnecessary anticoagulation and hence the name, Coumadin ridge. It may also be mistaken for a myxoma, leading to inappropriate surgeries^[3,4]. Correct identification of these variants on cardiac imaging is crucial and will help prevent unnecessary workup and treatment. These inappropriate treatments can have a devastating impact on patients' outcomes, raise healthcare spending, and may often times result in legal repercussions for healthcare providers^[4]. Knowledge of its location and features on various imaging modalities is critical in making the correct diagnosis.

Figure 2 shows the patient's coumadin ridge on an apical transthoracic echocardiography view, while Figure 3 shows it on an apical four-chamber transthoracic echocardiography view. In both of these views, the echogenicity of the ridge is similar to the surrounding cardiac tissues, suggesting this is a normal structure of the heart and not a thrombus or myxoma. Its location in the left atrium and its shape are also consistent with other reported cases. In both of the apical transthoracic echocardiography views, the coumadin ridge can be seen as a rounded "Q-tip" shape.

Two-dimensional transthoracic echocardiography can provide adequate clarity of the coumadin ridge. Additionally, fast spin echocardiography techniques with contrast can further help to clarify the diagnosis^[5]. If coumadin ridge is seen using transthoracic echocardiography and question still remains about the

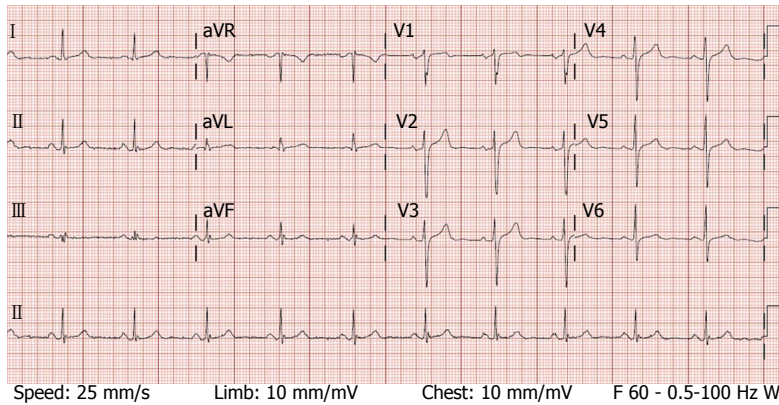


Figure 1 Electrocardiography showed sinus rhythm with a heart rate of 63 and left atrial abnormality.

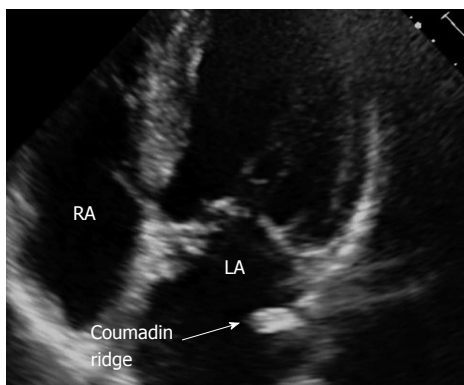


Figure 2 Apical transthoracic echocardiography view of coumadin ridge in the left atrium. RA: Right atrium; LA: Left atrium.

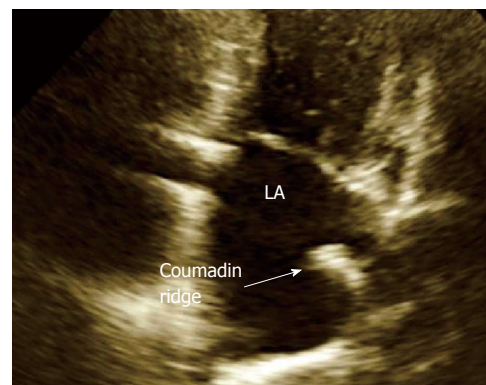


Figure 3 Apical four-chamber transthoracic echocardiography view of coumadin ridge in the left atrium. LA: Left atrium.

diagnosis, full volume three-dimensional transthoracic echocardiography with color Doppler can also provide additional clarity of the surrounding structures^[2]. In other cases, transesophageal echocardiography may be needed, as the coumadin ridge is best seen using midesophageal two-chamber view^[6]. In cases where it is difficult differentiating coumadin ridge from a thrombus or tumor, cardiac magnetic resonance or computed tomography may help to provide clarity to the diagnosis^[4,5]. On both T1 and T2-weighted imaging, the coumadin ridge should have the same signal strength as adjacent cardiac tissue^[5]. In addition, late gadolinium enhancement cardiac magnetic resonance may assist in clarifying the diagnosis; the coumadin ridge is unlikely to exhibit late enhancement^[5]. Thrombus, however, will typically have low signal-strength surrounded by structures with higher signal strength on late gadolinium enhancement^[5].

The usual location of the coumadin ridge is between the left superior pulmonary vein and the left atrial appendage. Along with its location, the lack of mobility and its unique linear structure with a rounded tip help differentiate this normal anatomic variant from other abnormal masses^[1,6]. However, if the mass is not imaged correctly, it may appear as a free-floating structure in the left atrium or may even appear to undulate with

cardiac motion (LA)^[1,5]. In addition, there are a few features that help distinguish intracardiac thrombi from a coumadin ridge. Thrombi will typically have different echogenicity from adjacent tissue. Also, thrombi will have mobility with underlying tissue^[1]. Thrombi are often seen in patients with atrial fibrillation, and are much less likely in patients with sinus rhythm^[1]. The gold standard in assessing these thrombi is with transesophageal echocardiography using color flow and pulse wave Doppler^[1]. Color flow Doppler will help in assessing if there is a low-flow risk for thrombus, which occurs when peak velocity is less than 40 cm/s^[1].

Coumadin ridge may also be misinterpreted for a myxoma of the left atrium. Myxoma is the most common benign tumor in adults, and is found in the left atrium 75% of the time^[1]. It is typically located on the interatrial septum and has a stalk attached to the fossa ovalis^[1]. It has a smooth surface with homogeneous consistency, and can grow very large in size^[1]. Midesophageal four-chamber view gives the best indication of the size and location of left atrial myxomas^[1].

While there is concern that the coumadin ridge may be misinterpreted as a tumor or thrombus, one should also be careful not to overlook lesions that may be near or attached to the coumadin ridge, as there have been cases of myxomas and fibroelastomas attached to the

tip of the coumadin ridge^[7]. These abnormalities can be differentiated on imaging from the coumadin ridge by their different sizes, shapes, echogenic features, and mobility^[7]. Although these cases are not common, careful attention needs to be given to rule out other pathology when the diagnosis is not immediately clear. Just like with any study, it is important to evaluate the findings from imaging in context with the patient's clinical evaluation.

As we continue to see more cases of coumadin ridge, we will likely arrive at a better understanding of the implications of this anatomic variant. One such example is its value in patients with atrial fibrillation, where coumadin ridge may serve as a site for catheterization^[8]. There are also implications of using the coumadin ridge as a site to stabilize the catheter while ablating adjacent areas in the left atrium^[9].

In conclusion, coumadin ridge is a normal variant of the left atrium. We presented a case in which a prominent ridge was found on two-dimensional transthoracic echocardiography. Awareness of its typical location and features on various image modalities are crucial to avoid unnecessary interventions which potentially put patients through unnecessary and risky treatments and surgeries.

COMMENTS

Case characteristics

A 58-year-old African American woman with hypertension, morbid obesity, and no remarkable history of heart disease, presented to general medicine clinic with complaints of worsening exertional dyspnea with abdominal and lower extremity swelling.

Clinical diagnosis

Lungs were clear to auscultation. Normal heart sounds, no S3 or S4, no murmurs, and no rubs. No hepatomegaly or extremity edema.

Imaging diagnosis

Transthoracic echocardiography showed prominent coumadin ridge in the left atrium.

Differential diagnosis

Coumadin ridge, left atrial pseudotumor.

Treatment

Coumadin ridge may present as a normal variant of the left atrium, which requires no additional intervention.

Related reports

Coumadin ridge may present as a linear or nodular mass, which can undulate with cardiac motion and can easily be mistaken for a tumor or a thrombus.

Experiences and lessons

Awareness of the location and imaging features of coumadin ridge will help prevent misdiagnosis and unnecessary workup.

Peer-review

It is a very interesting, well written paper.

REFERENCES

- 1 **Oxom DC**. Intraoperative echocardiography. 1st ed. Philadelphia: Saunders, 2012: 241-269
- 2 **McKay T**, Thomas L. 'Coumadin ridge' in the left atrium demonstrated on three dimensional transthoracic echocardiography. *Eur J Echocardiogr* 2008; **9**: 298-300 [PMID: 17127097 DOI: 10.1016/j.euje.2006.10.002]
- 3 **Ho SY**, McCarthy KP, Faletra FF. Anatomy of the left atrium for interventional echocardiography. *Eur J Echocardiogr* 2011; **12**: i11-i15 [PMID: 21998463 DOI: 10.1093/ejechocard/jeu093]
- 4 **George A**, Parameswaran A, Nekkanti R, Lurito K, Movahed A. Normal anatomic variants on transthoracic echocardiogram. *Echocardiography* 2009; **26**: 1109-1117 [PMID: 19840080 DOI: 10.1111/j.1540-8175.2009.01013.x]
- 5 **Gupta S**, Plein S, Greenwood JP. The Coumadin Ridge: An Important Example of a Left Atrial Pseudotumour demonstrated by Cardiovascular Magnetic Resonance Imaging. *J Radiol Case Rep* 2009; **3**: 1-5 [PMID: 22470681 DOI: 10.3941/jrcr.v3i9.210]
- 6 **Perrino AC**, Reeves ST. A practical approach to transesophageal echocardiography. 3rd ed. Philadelphia: Lippincott Williams and Wilkins, 2013: 458
- 7 **Agostini F**, Click RL. More than just the "Q-tip sign". *J Am Soc Echocardiogr* 2001; **14**: 832-833 [PMID: 11490333 DOI: 10.1067/mje.2001.110373]
- 8 **Kistler PM**, Earley MJ, Harris S, Abrams D, Ellis S, Sporton SC, Schilling RJ. Validation of three-dimensional cardiac image integration: use of integrated CT image into electroanatomic mapping system to perform catheter ablation of atrial fibrillation. *J Cardiovasc Electrophysiol* 2006; **17**: 341-348 [PMID: 16643352 DOI: 10.1111/j.1540-8167.2006.00371.x]
- 9 **Ho SY**, Sánchez-Quintana D. The importance of atrial structure and fibers. *Clin Anat* 2009; **22**: 52-63 [PMID: 18470938 DOI: 10.1002/ca.20634]

P- Reviewer: Pavlovic M, Rehman HU **S- Editor:** Ji FF
L- Editor: A **E- Editor:** Liu SQ





Published by **Baishideng Publishing Group Inc**

8226 Regency Drive, Pleasanton, CA 94588, USA

Telephone: +1-925-223-8242

Fax: +1-925-223-8243

E-mail: bpgoffice@wjgnet.com

Help Desk: <http://www.wjgnet.com/esps/helpdesk.aspx>

<http://www.wjgnet.com>

