

Extraordinary cause of acute gastric dilatation and hepatic portal venous gas: Chronic use of synthetic cannabinoid

Mert Mahsuni Sevinc, Erdem Kinaci, Savas Bayrak, Aytul Hande Yardimci, Ekrem Cakar, Hasan Bektaş

Mert Mahsuni Sevinc, Erdem Kinaci, Savas Bayrak, Ekrem Cakar, Hasan Bektaş, Department of General Surgery, Istanbul Training and Research Hospital, Istanbul 34098, Turkey

Erdem Kinaci, Org. Nafiz Gurman Cad. Istanbul Egitim ve Arastirma Hastanesi, Genel Cerrahi Klinigi, Istanbul 34098, Turkey

Aytul Hande Yardimci, Department of Radiology, Istanbul Training and Research Hospital, Istanbul 34098, Turkey

Author contributions: Sevinc MM, Kinaci E and Bektaş H designed the study; Sevinc MM, Kinaci E, Bayrak S, Yardimci AH and Cakar E analyzed the literature and wrote the study.

Informed consent statement: Written informed consent was obtained for all interventions and follow up.

Conflict-of-interest statement: The authors declare that there is no conflict of interests.

Open-Access: This article is an open-access article which was selected by an in-house editor and fully peer-reviewed by external reviewers. It is distributed in accordance with the Creative Commons Attribution Non Commercial (CC BY-NC 4.0) license, which permits others to distribute, remix, adapt, build upon this work non-commercially, and license their derivative works on different terms, provided the original work is properly cited and the use is non-commercial. See: <http://creativecommons.org/licenses/by-nc/4.0/>

Correspondence to: Erdem Kinaci, MD, Org. Nafiz Gurman Cad. Istanbul Egitim ve Arastirma Hastanesi, Genel Cerrahi Klinigi, Fatih, Istanbul 34098, Turkey. erdemkinaci@gmail.com
Telephone: +90-506-5087930

Received: February 2, 2015

Peer-review started: February 3, 2015

First decision: May 18, 2015

Revised: June 19, 2015

Accepted: August 25, 2015

Article in press: August 25, 2015

Published online: October 7, 2015

Abstract

Addiction to synthetic cannabinoids (SCs) is a growing social and health problem worldwide. Chronic use of SCs may cause adverse effects in the gastrointestinal system. We describe a very rare case of acute gastric dilatation (AGD) and hepatic portal venous gas (HPVG), with findings of acute abdomen resulting from chronic use of a SC, Bonzai. AGD and HPVG were detected by computerized tomography examination. Patchy mucosal ischemia was seen in endoscopic examination. Despite the findings of an acute abdomen, a non-surgical approach with nasogastric decompression, antibiotic therapy, and close radiologic and endoscopic follow-up was preferred in the presented case. Clinical and radiologic findings decreased dramatically on the first day, and endoscopic findings gradually disappeared over 7 d. In conclusion, this case shows that chronic use of a SC may cause AGD and accompanying HPVG, which can be managed non-surgically despite the findings of acute abdomen.

Key words: Acute abdomen; Acute gastric dilatation; Bonzai; Synthetic cannabinoid; Hepatic portal venous gas

© **The Author(s) 2015.** Published by Baishideng Publishing Group Inc. All rights reserved.

Core tip: This is the first case of acute gastric dilatation and accompanying hepatic portal venous gas presenting as acute abdomen as a result of chronic use of a synthetic cannabinoid, Bonzai. Despite the findings of acute abdomen, this type of patient can be managed non-surgically with wide spectrum antibiotic therapy and close radiologic and endoscopic follow-up.

Sevinc MM, Kinaci E, Bayrak S, Yardimci AH, Cakar E, Bektaş H. Extraordinary cause of acute gastric dilatation and hepatic

portal venous gas: Chronic use of synthetic cannabinoid. *World J Gastroenterol* 2015; 21(37): 10704-10708 Available from: URL: <http://www.wjgnet.com/1007-9327/full/v21/i37/10704.htm> DOI: <http://dx.doi.org/10.3748/wjg.v21.i37.10704>

INTRODUCTION

Despite the presence of some therapeutic effects of cannabinoids (also called cannabis), addiction to these substances has been known for many decades, and it is a common health problem worldwide^[1]. Chronic use of cannabinoids or synthetic derivatives have many negative effects on human health, such as pulmonary, endocrine, and cardiovascular pathologies, as well as cognitive and behavioral disorders^[1,2]. The gastrointestinal tract is another target of cannabinoids. Their effects on the gastrointestinal system are mediated by specific receptors in the brain and intestinal tract^[3]. Delayed gastric emptying and hyperemesis are defined gastric pathologies of chronic cannabinoid use^[2,4], but the extent of gastric effects of cannabinoids are not predictable. We describe an extraordinary case of a young man and his interesting clinical course after being admitted to the emergency room with the signs of acute abdomen.

CASE REPORT

A 29-year-old man was admitted to the emergency room with abdominal distension and gradually increasing pain over the previous 2 d. In his history, he had been using Bonzai regularly over the last 5 years and was undergoing treatment for addiction. Physical examination revealed abdominal distension, tenderness, defense, rebound, nausea and vomiting. At admission, the laboratory findings were as follows: white blood cell count 18200/mm³, hemoglobin 14.2 g/dL, platelet count 208000/mm³, glucose 240 mg/dL, amylase 382 U/L, aspartate transaminase 25 IU/L, alanine transaminase 17 IU/L, lactate dehydrogenase 224 U/L, and C-reactive protein 27.7 mg/L. An abdominal X-ray showed a very large amount of gas in the fundus. Nasogastric decompression was applied and approximately 6 L of brownish black fluid was discharged. Computerized tomography (CT) examination revealed a huge stomach, elongated towards the pelvis, and accompanying hepatic portal venous gas (HPVG) was detected (Figure 1). There was no evidence of perforation of the luminal organs. Emergency upper gastrointestinal endoscopy was performed immediately. Endoscopic examination showed severe mucosal edema and patchy ischemic areas all around the stomach (Figure 2). The patient was hospitalized and followed up with close radiologic and endoscopic surveillance under wide-spectrum antibiotic therapy, despite the presence of findings of acute abdomen.

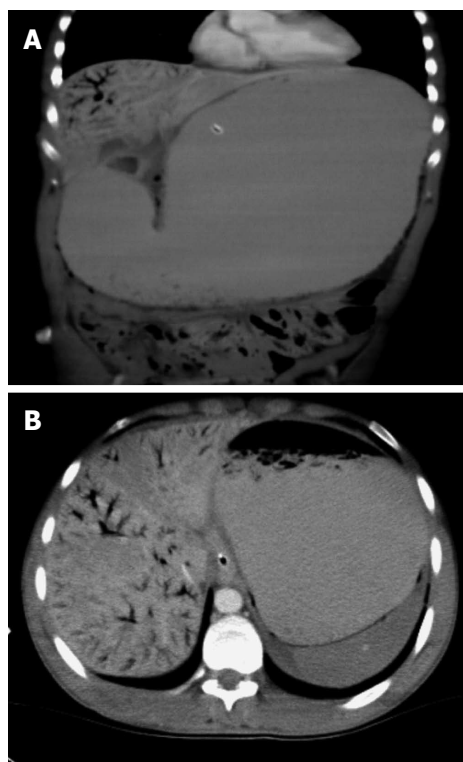


Figure 1 Abdominal computerized tomography shows massive gastric dilatation and hepatic portal venous gas at presentation. A: Coronal section; B: Transverse section.

After 24 h, endoscopic findings were almost the same, but clinical findings and HPVG in CT were dramatically decreased (Figure 3). There was a small amount of free peritoneal fluid. A sample was taken from this fluid, with guidance of ultrasonography, and there was no growth in culture.

Nasogastric decompression, antibiotic therapy and serial upper gastrointestinal endoscopy were continued, and all the clinical, radiological, and endoscopic findings regressed completely by the 7th d. The patient was discharged on the 8th d.

DISCUSSION

Although cannabinoids have some therapeutic features, chronic use can cause addiction and many deleterious effects^[1]. More than 10 different products are available containing SCs, such as Bonzai aromatic potpourri, Bonzai plant growth regulator, Bonzai Cuba, Bonzai black diamond, Spice, K2, Jamaican gold, and Yucatan fire^[5]. Addiction to this type of product has been growing in young adults. According to the World Drug Report from the United Nations Office on Drugs and Crime, SCs have been the leading new psychoactive substances worldwide^[6]. SCs were introduced into Turkey in 2010, and these products have become increasingly common in the country^[5].

SCs mimic the effects of natural cannabinoids by binding to the cannabinoid binding (CB) receptors. Although CB1 and CB2 receptors are found mainly

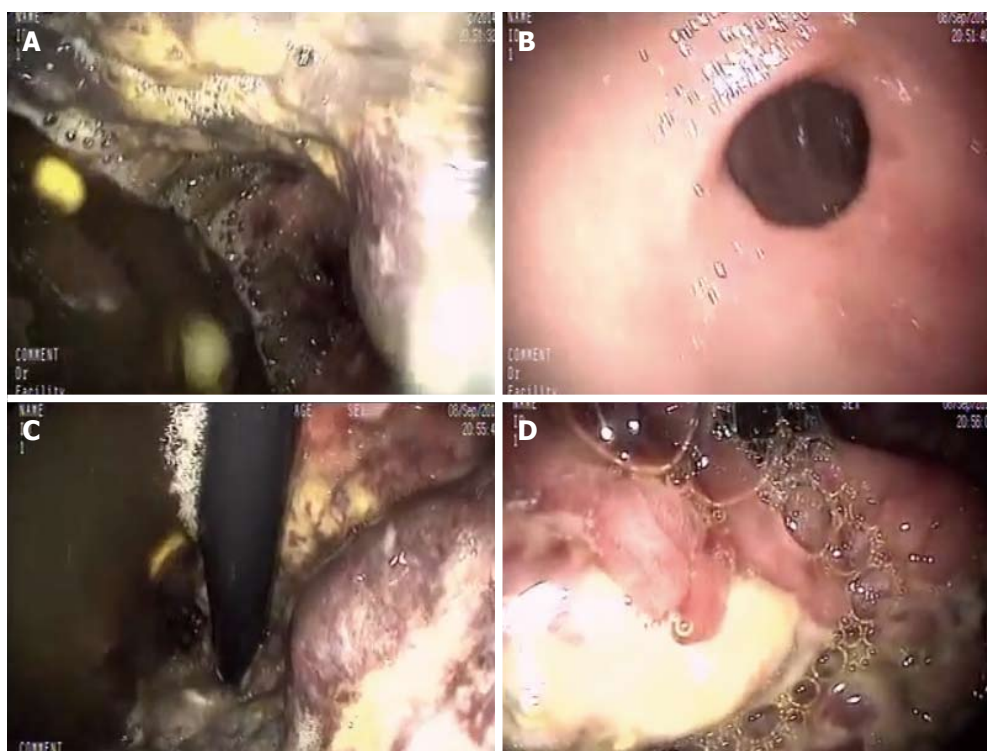


Figure 2 Patchy ischemia of gastric mucosa in emergency upper gastrointestinal endoscopy at presentation. A: Entry to stomach; B: Pylorus; C: Corpus, view of retroflexion; D: Cardia, view of retroflexion.

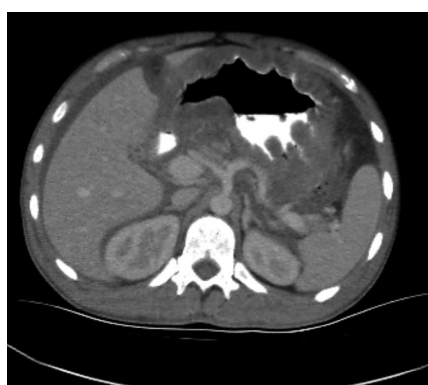

Figure 3 Transverse section of abdominal computerized tomography after 24 h. Hepatic portal venous gas and gastric dilatation regressed dramatically.

in neurons and immune cells, respectively, there is evidence for the presence of these receptors along the gastrointestinal tract^[3]. The inhibitory effect of cannabinoids and CB1 receptor agonists on gastric motility and contractility has been shown in animal studies^[7,8]. Clinically, cannabinoids have been used to treat hyperemesis in patients undergoing chemotherapy, and this effect is mediated by CB1 receptors^[9]. Paradoxically, Choung *et al.*^[10] and Allen *et al.*^[4] have reported an association between chronic cannabinoid use and cyclical hyperemesis. Additionally, cannabinoids can affect the lower esophageal sphincter by binding to CB1 receptors within the nucleus tractus solitarius^[11]. As shown, there are different aspects of the effects of cannabinoids on the stomach. In the

present case, we saw an extraordinary presentation of chronic SC use. According to our knowledge, this is the first case of acute gastric dilatation and hepatic portal venous gas resulting from SC use. Although, the pathogenesis of AGD is generally not clear, we thought that, in our case, this process should be mediated by binding to CB1 receptors.

HPVG is recognized, not as a specific disease entity, but rather as a diagnostic clue in patients with underlying acute abdominal pathology. The diagnostic features of HPVG on CT imaging include: branching lucencies extending to within 2 cm of the liver capsule, predominantly in the anterior-superior aspect of the left lobe^[12,13]. An association of AGD and HPVG is extremely rare; there are few cases reported in the literature. In 1985, Radin *et al.*^[13] reviewed very early reported cases. Of four AGD-HPVG cases, conservative treatment with nasogastric decompression was successful in three cases^[13]. In more recent reports, surgical exploration was associated with successful results^[14-16]. The pathogenesis of HPVG is also not clear. There are two hypotheses regarding its cause; microbe-derived gas production and absorbed intraluminal air^[17]. We could not determine the precise cause of HPVG in our case. In the literature, necrotizing enterocolitis, bowel necrosis, digestive tract dilatation, inflammatory bowel disease, gastric ulcer, cholangitis, pancreatitis, and endoscopic interventions have been reported as a cause of HPVG^[18,19]. Whatever the mechanism, it is now clearly known that the prognosis is related to the primary pathology and is not influenced by the

presence of HPVG^[19].

The stomach is resistant to ischemia and necrosis due to the rich collateral blood flow. However, if a sudden increase in gastric pressure occurs, gastric ischemia, necrosis, and perforation can occur^[20]. In our case, we endoscopically detected mucosal ischemia, which was an indicator of impaired perfusion of the stomach. However, there was no evidence of vascular pathology (thrombus or embolus) or obstruction of the tract. There are some challenges in deciding to perform surgery or follow-up due to the chronic use of SC, which has deleterious effects on other organs^[1,21]. We finally opted for close clinical, radiologic, and endoscopic follow-up.

In conclusion, this is an extraordinary case of AGD with gastric mucosal ischemia and HPVG resulting from chronic use of a SC. Although the patient's clinical diagnosis included acute abdomen, which is a specific indication for surgical exploration, a conservative approach of nasogastric decompression, wide spectrum antibiotic therapy, and daily endoscopic follow-up was successful. In patients with AGD without vascular or obstructive pathologies, the presence of HPVG and even gastric mucosal ischemia should not be considered as a particular indication for emergency surgery.

COMMENTS

Case characteristics

A 29-year-old male patient presented with severe abdominal pain; the most striking feature in his medical history was chronic use of a synthetic cannabinoid, Bonazi.

Clinical diagnosis

Upon physical examination, there were findings of acute abdomen.

Differential diagnosis

Perforation of hollow organs, acute pancreatitis.

Laboratory diagnosis

The patient had elevated hematological values, with white blood cell count 18200/mm³, glucose 240 mg/dL, amylase 382 U/L, and C-reactive protein 27.7 mg/L.

Imaging diagnosis

Abdominal X-rays showed a very large amount of gas in the gastric fundus. Computerized tomography (CT) examination revealed a huge stomach, elongated towards the pelvis and accompanying hepatic portal venous gas (HPVG) was detected. Endoscopic examination showed severe mucosal edema and patchy ischemic areas all around the stomach.

Treatment

Nasogastric decompression, antibiotic therapy, and serial upper gastrointestinal endoscopy were performed, and all the clinical, radiological, and endoscopic findings regressed completely by the 7th d.

Related reports

The effects of cannabinoids on the gastrointestinal system show great variation. The combination of acute gastric dilatation (AGD) and HPVG is a very rare entity. HPVG is not a sign of a poor prognosis.

Term explanation

Bonazi is a trademark of a synthetic cannabinoid which is commercially available in Turkey.

Experiences and lessons

This case report presents an extraordinary result of chronic use of synthetic cannabinoid. AGD and HPVG can be seen in such a situation. The authors recommend that abdominal CT and upper GI endoscopy should be first-line modalities for diagnosis, and conservative therapy with close endoscopic follow-up should be considered as first choice for treatment.

Peer-review

The case is very interesting for readers. In the manuscript they describe a rare case of AGD accompanied by HPVG, presenting as acute abdomen in a 29-year-old man resulting from chronic use of synthetic cannabinoids. The clinical history and diagnostic test are well described and it is easy to follow the flow of the case.

REFERENCES

- 1 Kogan NM, Mechoulam R. Cannabinoids in health and disease. *Dialogues Clin Neurosci* 2007; **9**: 413-430 [PMID: 18286801]
- 2 Sontineni SP, Chaudhary S, Sontineni V, Lanspa SJ. Cannabinoid hyperemesis syndrome: clinical diagnosis of an underrecognised manifestation of chronic cannabis abuse. *World J Gastroenterol* 2009; **15**: 1264-1266 [PMID: 19291829 DOI: 10.3748/wjg.15.1264]
- 3 Pertwee RG. Cannabinoids and the gastrointestinal tract. *Gut* 2001; **48**: 859-867 [PMID: 11358910]
- 4 Allen JH, de Moore GM, Heddle R, Twartz JC. Cannabinoid hyperemesis: cyclical hyperemesis in association with chronic cannabis abuse. *Gut* 2004; **53**: 1566-1570 [PMID: 15479672]
- 5 Gurdal F, Asirdizer M, Aker RG, Korkut S, Gocer Y, Kucukbrahimoglu EE, Ince CH. Review of detection frequency and type of synthetic cannabinoids in herbal compounds analyzed by Istanbul Narcotic Department of the Council of Forensic Medicine, Turkey. *J Forensic Leg Med* 2013; **20**: 667-672 [PMID: 23910858 DOI: 10.1016/j.jflm.2013.03.041]
- 6 United Nations Office on Drugs and Crime. World Drug Report, 2014. New York: United Nations Publication, 2014 [DOI: 10.1111/dar.12110/abstract]
- 7 Krowicki ZK, Moerschbaecher JM, Winsauer PJ, Digavalli SV, Hornby PJ. Delta9-tetrahydrocannabinol inhibits gastric motility in the rat through cannabinoid CB1 receptors. *Eur J Pharmacol* 1999; **371**: 187-196 [PMID: 10357256]
- 8 Izzo AA, Mascolo N, Capasso R, Germanò MP, De Pasquale R, Capasso F. Inhibitory effect of cannabinoid agonists on gastric emptying in the rat. *Naunyn Schmiedeberg's Arch Pharmacol* 1999; **360**: 221-223 [PMID: 10494894]
- 9 Tramèr MR, Carroll D, Campbell FA, Reynolds DJ, Moore RA, McQuay HJ. Cannabinoids for control of chemotherapy induced nausea and vomiting: quantitative systematic review. *BMJ* 2001; **323**: 16-21 [PMID: 11440936]
- 10 Choung RS, Locke GR, Lee RM, Schleck CD, Zinsmeister AR, Talley NJ. Cyclic vomiting syndrome and functional vomiting in adults: association with cannabinoid use in males. *Neurogastroenterol Motil* 2012; **24**: 20-26, e1 [PMID: 21951771 DOI: 10.1111/j.1365-2982.2011.01791.x]
- 11 Partosoedarso ER, Abrahams TP, Scullion RT, Moerschbaecher JM, Hornby PJ. Cannabinoid1 receptor in the dorsal vagal complex modulates lower oesophageal sphincter relaxation in ferrets. *J Physiol* 2003; **550**: 149-158 [PMID: 12879865 DOI: 10.1113/jphysiol.2003.042242]
- 12 Benson MD. Adult survival with intrahepatic portal venous gas secondary to acute gastric dilatation, with a review of portal venous gas. *Clin Radiol* 1985; **36**: 441-443 [PMID: 4064538]
- 13 Radin DR, Rosen RS, Halls JM. Acute gastric dilatation: a rare cause of portal venous gas. *AJR Am J Roentgenol* 1987; **148**:

- 279-280 [PMID: 3492104]
- 14 **Lim JE**, Duke GL, Eachempati SR. Superior mesenteric artery syndrome presenting with acute massive gastric dilatation, gastric wall pneumatosis, and portal venous gas. *Surgery* 2003; **134**: 840-843 [PMID: 14639366 DOI: 10.1016/S0039-6060(02)21677-3]
- 15 **Allaparthi SB**, Anand CP. Acute gastric dilatation: a transient cause of hepatic portal venous gas-case report and review of the literature. *Case Rep Gastrointest Med* 2013; **2013**: 723160 [PMID: 23819076 DOI: 10.1155/2013/723160]
- 16 **Oomatia A**, Carroll N, Safranek PM. Acute gastric necrosis and air in the hepatic-portal vein secondary to a strangulated paraumbilical hernia. *Lancet* 2013; **382**: 1733 [PMID: 23664059 DOI: 10.1016/S0140-6736(12)61778-4]
- 17 **Nelson AL**, Millington TM, Sahani D, Chung RT, Bauer C, Hertl M, Warshaw AL, Conrad C. Hepatic portal venous gas: the ABCs of management. *Arch Surg* 2009; **144**: 575-581; discussion 581 [PMID: 19528392 DOI: 10.1001/archsurg.2009.88]
- 18 **Kinoshita H**, Shinozaki M, Tanimura H, Umemoto Y, Sakaguchi S, Takifuji K, Kawasaki S, Hayashi H, Yamaue H. Clinical features and management of hepatic portal venous gas: four case reports and cumulative review of the literature. *Arch Surg* 2001; **136**: 1410-1414 [PMID: 11735870]
- 19 **Abboud B**, El Hachem J, Yazbeck T, Doumit C. Hepatic portal venous gas: physiopathology, etiology, prognosis and treatment. *World J Gastroenterol* 2009; **15**: 3585-3590 [PMID: 19653334 DOI: 10.3748/wjg.15.3585]
- 20 **Turan M**, Sen M, Canbay E, Karadayi K, Yildiz E. Gastric necrosis and perforation caused by acute gastric dilatation: report of a case. *Surg Today* 2003; **33**: 302-304 [PMID: 12707829]
- 21 **Köklü E**, Yüksel İÖ, Bayar N, Üreyen ÇM, Arslan Ş. A new cause of silent myocardial infarction: Bonsai. *Anadolu Kardiyol Derg* 2015; **15**: 69-70 [PMID: 25550251 DOI: 10.5152/akd.2014.5870]

P- Reviewer: Casadesus D, Vorobjova T **S- Editor:** Ma YJ
L- Editor: Cant MR **E- Editor:** Wang CH





Published by **Baishideng Publishing Group Inc**

8226 Regency Drive, Pleasanton, CA 94588, USA

Telephone: +1-925-223-8242

Fax: +1-925-223-8243

E-mail: bpgoffice@wjgnet.com

Help Desk: <http://www.wjgnet.com/esps/helpdesk.aspx>

<http://www.wjgnet.com>



ISSN 1007-9327

