

Current management of patients with hepatocellular carcinoma

Tatsuo Kanda, Sadahisa Ogasawara, Tetsuhiro Chiba, Yuki Haga, Masao Omata, Osamu Yokosuka

Tatsuo Kanda, Sadahisa Ogasawara, Tetsuhiro Chiba, Yuki Haga, Osamu Yokosuka, Department of Gastroenterology and Nephrology, Graduate School of Medicine, Chiba University, Chuo-ku, Chiba 260-8677, Japan

Masao Omata, Yamanashi Hospitals (Central and Kita) Organization, Kofu-shi, Yamanashi 400-8506, Japan

Masao Omata, University of Tokyo, Hongo, Bunkyo-ku, Tokyo 113-8655, Japan

Author contributions: Kanda T, Ogasawara S, Chiba T, Haga Y, Omata M and Yokosuka O contributed to this paper.

Conflict-of-interest statement: Dr. Sadahisa Ogasawara, Dr. Tetsuhiro Chiba, Dr. Yuki Haga and Professor Masao Omata have no conflict of interest to declare. Dr. Tatsuo Kanda reports receiving lecture fees from Chugai Pharmaceutical, MSD, Tanabe-Mitsubishi, Daiichi-Sankyo, and Bristol-Myers Squibb, and Professor Osamu Yokosuka reports receiving grant support from Chugai Pharmaceutical, Bayer, MSD, Daiichi-Sankyo, Tanabe-Mitsubishi, and Bristol-Myers Squibb.

Open-Access: This article is an open-access article which was selected by an in-house editor and fully peer-reviewed by external reviewers. It is distributed in accordance with the Creative Commons Attribution Non Commercial (CC BY-NC 4.0) license, which permits others to distribute, remix, adapt, build upon this work non-commercially, and license their derivative works on different terms, provided the original work is properly cited and the use is non-commercial. See: <http://creativecommons.org/licenses/by-nc/4.0/>

Correspondence to: Tatsuo Kanda, MD, PhD, Associate Professor, Department of Gastroenterology and Nephrology, Graduate School of Medicine, Chiba University, 1-8-1 Inohana, Chuo-ku, Chiba 260-8677, Japan. kandat-cib@umin.ac.jp
 Telephone: +81-43-2262086
 Fax: +81-43-2262088

Received: February 20, 2015
 Peer-review started: February 22, 2015
 First decision: April 27, 2015
 Revised: May 2, 2015
 Accepted: June 4, 2015

Article in press: June 8, 2015
 Published online: July 28, 2015

Abstract

The current management therapies for hepatocellular carcinoma (HCC) patients are discussed in this review. Despite the development of new therapies, HCC remains a "difficult to treat" cancer because HCC typically occurs in advanced liver disease or hepatic cirrhosis. The progression of multistep and multicentric HCC hampers the prevention of the recurrence of HCC. Many HCC patients are treated with surgical resection and radiofrequency ablation (RFA), although these modalities should be considered in only selected cases with a certain HCC number and size. Although there is a shortage of grafts, liver transplantation has the highest survival rates for HCC. Several modalities are salvage treatments; however, intensive care in combination with other modalities or in combination with surgical resection or RFA might offer a better prognosis. Sorafenib is useful for patients with advanced HCC. In the near future, HCC treatment will include stronger molecular targeted drugs, which will have greater potency and fewer adverse events. Further studies will be ongoing.

Key words: Hepatocellular carcinoma; Living donor liver transplantation; Radiofrequency ablation; Surgical resection

© The Author(s) 2015. Published by Baishideng Publishing Group Inc. All rights reserved.

Core tip: Liver transplantation is the first-line treatment of hepatocellular carcinoma (HCC). Surgical resection and radiofrequency ablation (RFA) are second-line HCC treatments. Surgical resection and RFA should only be considered for selected cases. Sorafenib administration, transarterial chemoembolization, stereotactic body radiation treatments, or proton or carbon ion treatments

are available as salvage treatments for HCC. Laparoscopic liver resection appears to offer at least a short-term benefit in selected HCC patients. These HCC treatments should be carefully selected or combined in clinical practice.

Kanda T, Ogasawara S, Chiba T, Haga Y, Omata M, Yokosuka O. Current management of patients with hepatocellular carcinoma. *World J Hepatol* 2015; 7(15): 1913-1920 Available from: URL: <http://www.wjgnet.com/1948-5182/full/v7/i15/1913.htm> DOI: <http://dx.doi.org/10.4254/wjh.v7.i15.1913>

HEPATOCELLULAR CARCINOMA

Globally, hepatocellular carcinoma (HCC) is a common malignancy with a poor prognosis worldwide, and the incidence of HCC is increasing in the United States^[1,2]. In Asian countries, HCC is caused by hepatitis B virus (HBV) or hepatitis C virus (HCV) infection^[3-6]. Despite the ongoing development of new therapies, HCC remains a "difficult to treat" cancer^[7] because the malignancy typically occurs in advanced liver disease or hepatic cirrhosis. In HCC treatments, such as surgical resection or percutaneous local ablation therapy, the liver function should always be considered^[8-12]. The recurrence of HCC within 5 years after primary resection is as high as 70% because multistep and multicentric HCC develops most frequently after a resection or ablation treatment in patients with chronic liver disease^[13,14].

CURRENT MANAGEMENT OF HCC

Surgical resection for HCC

The tumor status and liver function reserve of HCC patients determine whether a hepatectomy should be performed^[9] (Figure 1A). Careful attention should be focused on the selection of appropriate candidates. Makuuchi's criteria for the selection of the operative procedures in patients with HCC and liver cirrhosis are available in Japan^[8,15]. The criteria comprise the existence of ascites, the serum total bilirubin and indocyanine green (ICG) clearance rates. In patients without ascites and with total bilirubin levels < 2 mg/dL, a hepatectomy could be safely performed. Serum total bilirubin levels (< 1 mg/dL) and a normal range (10%-19%, 20%-29%, or \geq 30%) of ICG retention at 15 min suggest a trisegmentectomy or right hepatectomy, left hepatectomy or right segmentectomy, subsegmentectomy, or limited resection, respectively. Patients with serum total bilirubin levels of 1.1-1.9 mg/dL could receive a limited liver resection safely. Small HCC is a clinical entity with a high surgical cure rate^[9]. Yamazaki *et al*^[9] reported that the 5-year survival following a hepatectomy is 53%, with 26% morbidity and 0% mortality in patients within the Makuuchi's criteria; however, they reported that the 5-year survival in HCC patients in major institutions worldwide is 37%-53% following a hepatectomy, with

11%-45% morbidity and 0%-10% mortality. A hepatic venous pressure gradient \geq 10 mmHg as a direct measurement of relevant portal hypertension could be useful^[16,17] because the concept of portal hypertension as a prognostic factor in patients undergoing resection has been validated^[18]. An accepted application to measure and quantitate the liver reserve is debatable, and further studies are required.

The prognosis of patients with a portal vein tumor thrombus, which typically is poor, might be improved by surgical resection with or without pre-operative transarterial chemoembolization (TACE)^[19,20]. A combination of aggressive surgical treatment and effective preoperative TACE for HCC with major vascular tumor invasion including invasion of the main trunk, the first-order branch of the portal vein, or the inferior vena cava might be beneficial for certain patients^[19,21]. Because chemotherapy or antiviral treatment could be administered, a concomitant splenectomy and hepatectomy might extend the criteria for surgery in "selected" HCC patients with hypersplenism^[22].

Percutaneous local ablation therapy: Ebara *et al*^[23] reported that following percutaneous ethanol injection (PEI) therapy, the 1-, 2-, 3-, 4- and 5-year survival rates of 95 patients with an HCC smaller than 3 cm were 93%, 81%, 65%, 52% and 28%, respectively. This treatment could be performed for patients with Child's A as well as Child's B or C disease, although the survival rates of patients with Child's A or B status was higher than those in Child's C patients^[23]. In cases of HCC recurrence, PEI was easily repeated^[23], although a repeated hepatic resection was reported in selected patients^[9]. Additionally, Shiina *et al*^[10] reported that with a median follow-up of 51.6 mo, the 5-, 10- and 20-year survival rates of 2147 HCC-patients, were 49%, 18% and 7.2%, respectively. There were 45 complications (2.1%) and two deaths (0.1%)^[10].

Radiofrequency ablation (RFA), instead of PEI (Figure 1A), is widely performed for HCC. Shiina *et al*^[11] reported that the 5-, and 10-year survival rates of 1170 HCC-patients with a median follow-up of 38.2 mo were 60% and 27%, respectively. In that study, the survival rates of RFA were found to be superior to those of PEI^[10,11], although it was not a head-to-head comparison. One death (0.03%) and 67 complications (2.2%) occurred^[11], and the HCC was controlled by RFA. A randomized controlled trial of surgery vs RFA for small HCC has begun in Japan^[24]. Additionally, it was reported that adjuvant RFA might provide palliative care for patients with metastatic cancer^[25]. Further studies are required. The meta-analysis of the four randomized controlled trials demonstrated a significant improvement in the 3-year survival rate and that RFA was more effective than PEI^[26].

Liver transplantation for HCC

Liver transplantation offers additional benefits for HCC patients because additional cancers might be

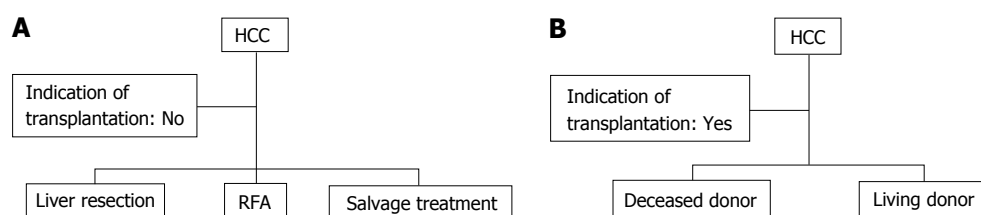


Figure 1 Treatment algorithm for hepatocellular carcinoma. A: In patients for which liver transplantation is unavailable. If possible, the patients should select surgical resection or radiofrequency ablation (RFA). Otherwise, other salvage treatments should be selected; B: In patients in which deceased-donor or living-donor liver transplantation is available. HCC: Hepatocellular carcinoma.

incidentally found during the examination of the explanted liver; additional cancers attribute to high HCC recurrence rates after primary surgical resection^[27]. The criteria for liver transplantation have improved over many years^[28-32]. According to the Milan criteria, patients are eligible for liver transplantation if they have a single HCC less than 5 cm in diameter or no more than three tumors less than 3 cm in diameter^[30]. Liver transplantation is the first-line treatment option for these patients^[16]. Mazzaferro *et al.*^[30] studied 48 patients within the Milan criteria; they reported an overall mortality rate of 17% after 4 years and that the actual survival rate and recurrence-free survival rate were 75% and 83%, respectively. Additionally, they reported that in 35 patients meeting the predetermined criteria for small HCCs in the pathology examination of the explanted liver, the overall and recurrence-free survival rates at four years were 85% and 92%, respectively^[30]. These results suggest that liver transplantation is an effective treatment for small, unresectable HCCs in patients with cirrhosis. An excellent 5-year survival rate has been reported in cases in which the restrictive Milan criteria are used to select transplant candidates. HCC is a good indication for orthotopic liver transplantation, and cadaveric liver transplantation/deceased-donor liver transplantation is an excellent treatment for early HCC (Figure 1B). Additionally, living-donor liver transplantation is an excellent treatment for early HCC because deceased-donor liver transplantation is limited by the shortage of grafts^[33,34]. In Japan and other Asian countries, living-donor liver transplantation will continue to be a mainstay treatment of HCC in cirrhotic patients^[35,36].

HCC frequently occurs in cirrhotic liver patients infected with HBV or HCV. Although the viral infections are eradicated or controlled^[37-45], the risk of developing HCC persists in patients with advanced liver disease. Elder patients tend to have more advanced fibrosis than younger patients^[46-52]. Regardless of the liver function, in cases in which the restrictive Milan criteria are used to select transplant candidates, liver transplantation in patients within the criteria has a better prognosis. However, many difficulties exist, including a shortage of donors and whether a patient is eligible for transplantation because of age. Elderly patients with an increased risk for postoperative complications should be excluded from living donor liver transplantation,

at least; previous published studies have shown that age is not a contraindication for deceased donor liver transplantation^[53,54].

Down-staging the policies for HCCs exceeding the conventional criteria could not be recommended^[16], and prospective studies should be conducted to explore the issue of expanded criteria for orthotopic liver transplantation, down staging and bridge therapies.

OTHER MODALITIES FOR HCC

Sorafenib

Treatment with sorafenib prolongs progression-free survival in patients with advanced clear-cell renal-cell carcinoma in whom previous therapy has failed; the treatment is associated with increased toxic effects^[55]. Similarly, in 602 patients with advanced HCC (299 in the sorafenib group; 303 in the placebo group), overall survival (OS) was significant longer in the sorafenib group compared with the placebo group (OS of 10.7 mo vs 7.9 mo, respectively; hazard ratio in the sorafenib group, 0.69; 95%CI: 0.55-0.87; $P < 0.001$)^[56]. Another study from the Asia-Pacific region^[57] showed that sorafenib is effective for advanced HCC treatment in Child's A patients. Common adverse events such as hand-foot skin reactions, diarrhea and fatigue were observed in the study^[57]. Molecular targeted therapy against HCCs is being developed and will augment the treatment of advanced HCC^[58,59].

TACE: A Japanese prospective cohort study in 8510 patients with unresectable HCC showed a 5-year survival rate of 26%^[60]. Superselective TACE for HCC showed overall median and 5-year survival rates of 3.3 years and 34%, respectively^[61]. TACE showed higher survival rates in patients with fewer tumor numbers, smaller tumor size, and better liver function (Child's A or B). In Asian countries, TACE is the main therapeutic modality in advanced HCC-patients, and the overall therapeutic outcomes depend on the tumor size^[62]. TACE has a long history in the treatment of unresectable HCC cases^[63,64]. TACE, in combination with surgery or local ablation therapy, is frequently used in clinical practice. The timing and number of treatment sessions of TACE are not uniform for each patient, although new devices and treatments, including drug-eluting bead TACE and trans-arterial radio-embolization, have been

Table 1 Comparison of treatment modalities for hepatocellular carcinoma^[84]

| Modalities | Indication of the features of HCC |
|-----------------------|---|
| Surgical resection | Performance status 0, Child-Pugh A, single < 3 cm Normal bilirubin/normal portal pressure Associated diseases, no |
| RFA | Performance status 0, Child-Pugh A-B, single or 3 nodule ≤ 3 cm Slightly increased bilirubin/increased portal pressure Associated diseases, yes or no |
| Liver transplantation | Performance status 0, single or 3 nodule ≤ 3 cm Increased bilirubin/increased portal pressure Associated diseases, no |
| Sorafenib | Performance status 1-2, Child-Pugh A-B, Advanced stage (portal invasion), node classification 1, metastasis classification 1 |
| TACE | Performance status 0, Child-Pugh A-B, Intermediate stage (multi nodular) |

RFA: Radiofrequency ablation; TACE: Transarterial chemoembolization; HCC: Hepatocellular carcinoma.

developed and continue to develop^[65,66].

Stereotactic body radiation therapy/stereotactic ablative radiotherapy: Stereotactic body radiation therapy (SBRT) for HCC has been documented in several recent studies^[67-70]. Use of a cyberknife is an SBRT system that allows for real-time tracking of a tumor. The system affords good local tumor control and higher overall survival rates than other historical controls such as best supportive care or sorafenib therapy^[70]. SBRT is a salvage treatment for unresectable HCC patients who failed or were unsuitable for TACE^[71] or for patients with an unresectable massive HCC for whom standard treatment care is unsuitable^[72]. Repeated stereotactic ablative radiotherapy in selected HCC patients might be feasible, if toxicity levels are acceptable^[73].

Other therapies: Proton and carbon ion therapies for 343 HCC-patients showed that the 5-year local control and overall survival rates were 91% and 38%, respectively^[74]. These therapies might be alternatives to conventional local therapies for HCC^[74-77]. Additionally, laparoscopic liver resection appears to offer at least short-term benefits in selected HCC patients^[78,79] whereas it is a widely employed alternative to open surgery in well-selected candidates. Standardization of surgical techniques might facilitate the performance of safe procedures^[79].

FOLLOW-UP

After a curative treatment such as surgical resection or RFA, antiviral therapies should be considered in patients infected with chronic HBV and/or HCV^[38,49,50,80,81]. In HCV-infected individuals, interferon-free regimens might be beneficial^[82]. Hepatic resection was recommended in non-B and non-C patients^[83] because unknown causes of HCC might be present in these patients, and particularly careful follow-up is needed.

CONCLUSION

Many reviews on this topic have been published in the

last few years, and most prestigious scientific societies worldwide provide practical treatment guidelines that are regularly updated, including HCC treatment algorithms (Table 1)^[16,84-87]. Liver transplantation and surgical resections are regarded as the only curative treatments; however, they have different indications. Although liver transplantation has not received priority over surgical resection, the most reliable therapy for HCC patients, presently, appears to be liver transplantation because its survival rate is superior to that of the other treatments. On this point, this review might differ from other practical guidelines or treatment algorithms. Deceased-donor liver-transplantation is limited by the shortage of grafts, and living-donor liver-transplantation should be discussed. If it is impossible for an HCC patient to undergo liver transplantation, then surgical resection or RFA, should be considered, in accordance with the liver function of the patient. We expect that stronger molecular targeted drugs will be used in the treatment of HCC patients and that these treatments will have more potency and fewer adverse events than are observed with sorafenib treatment. In the near future, methods of promoting hepatic regeneration might be improved. Further studies are ongoing.

ACKNOWLEDGMENTS

The authors thanks Dr. Ryosuke Tateishi, University of Tokyo for valuable discussions.

REFERENCES

- 1 Fong ZV, Tanabe KK. The clinical management of hepatocellular carcinoma in the United States, Europe, and Asia: a comprehensive and evidence-based comparison and review. *Cancer* 2014; **120**: 2824-2838 [PMID: 24897995 DOI: 10.1002/cncr.28730]
- 2 El-Serag HB. Epidemiology of viral hepatitis and hepatocellular carcinoma. *Gastroenterology* 2012; **142**: 1264-1273.e1 [PMID: 22537432 DOI: 10.1053/j.gastro.2011.12.061]
- 3 Liaw YF, Kao JH, Piratvisuth T, Chan HLY, Chien RN, Liu CJ, Gane E, Locarnini S, Lim SG, Han KH, Amarapurkar D, Cooksley G, Jafri W, Mohamed R, Hou JL, Chuang WL, Lesmana LA, Sollano JD, Suh DJ, Omata M. Asian-Pacific consensus statement on the management of chronic hepatitis B: a 2012 update. *Hepatol Int* 2012; **6**: 531-561 [DOI: 10.1007/s12072-012-9365-4]

- 4 **Omata M**, Kanda T, Yu ML, Yokosuka O, Lim SG, Jafri W, Tateishi R, S. Hamid S, Chuang WL, Chutaputti A, Wei L, Sollano J, Sarin SK, Kao JH, W. McCaughan G. APASL consensus statements and management algorithms for hepatitis C virus infection. *Hepatol Int* 2012; **6**: 409-435 [DOI: 10.1007/s12072-012-9342-y]
- 5 **Yoshizawa H**, Tanaka J, Miyakawa Y. National prevention of hepatocellular carcinoma in Japan based on epidemiology of hepatitis C virus infection in the general population. *Intervirol* 2006; **49**: 7-17 [PMID: 16166783 DOI: 10.1159/000087257]
- 6 **Kanda T**, Imazeki F, Yokosuka O. New antiviral therapies for chronic hepatitis C. *Hepatol Int* 2010; **4**: 548-561 [PMID: 21063477 DOI: 10.1007/s12072-010-9193-3]
- 7 **Kanda T**, Jiang X, Yokosuka O. Androgen receptor signaling in hepatocellular carcinoma and pancreatic cancers. *World J Gastroenterol* 2014; **20**: 9229-9236 [PMID: 25071315 DOI: 10.3748/wjg.v20.i28.9229]
- 8 **Makuuchi M**, Kosuge T, Takayama T, Yamazaki S, Kakazu T, Miyagawa S, Kawasaki S. Surgery for small liver cancers. *Semin Surg Oncol* 1993; **9**: 298-304 [PMID: 8210909 DOI: 10.1002/ssu.2980090404]
- 9 **Yamazaki S**, Takayama T. Surgical treatment of hepatocellular carcinoma: evidence-based outcomes. *World J Gastroenterol* 2008; **14**: 685-692 [PMID: 18205256 DOI: 10.3748/wjg.14.685]
- 10 **Shiina S**, Tateishi R, Imamura M, Teratani T, Koike Y, Sato S, Obi S, Kanai F, Kato N, Yoshida H, Omata M, Koike K. Percutaneous ethanol injection for hepatocellular carcinoma: 20-year outcome and prognostic factors. *Liver Int* 2012; **32**: 1434-1442 [PMID: 22712520 DOI: 10.1111/j.1478-3231.2012.02838.x]
- 11 **Shiina S**, Tateishi R, Arano T, Uchino K, Enooku K, Nakagawa H, Asaoka Y, Sato T, Masuzaki R, Kondo Y, Goto T, Yoshida H, Omata M, Koike K. Radiofrequency ablation for hepatocellular carcinoma: 10-year outcome and prognostic factors. *Am J Gastroenterol* 2012; **107**: 569-577; quiz 578 [PMID: 22158026 DOI: 10.1038/ajg.2011.425]
- 12 **Tanaka K**, Shimada M, Kudo M. Characteristics of long-term survivors following sorafenib treatment for advanced hepatocellular carcinoma: report of a workshop at the 50th Annual Meeting of the Liver Cancer Study Group of Japan. *Oncology* 2014; **87** Suppl 1: 104-109 [PMID: 25427741 DOI: 10.1159/000368153]
- 13 **Sakamoto M**, Hirohashi S, Tsuda H, Shimosato Y, Makuuchi M, Hosoda Y. Multicentric independent development of hepatocellular carcinoma revealed by analysis of hepatitis B virus integration pattern. *Am J Surg Pathol* 1989; **13**: 1064-1067 [PMID: 2556944 DOI: 10.1097/00000478-198912000-00009]
- 14 **Oikawa T**, Ojima H, Yamasaki S, Takayama T, Hirohashi S, Sakamoto M. Multistep and multicentric development of hepatocellular carcinoma: histological analysis of 980 resected nodules. *J Hepatol* 2005; **42**: 225-229 [PMID: 15664248 DOI: 10.1016/j.jhep.2004.10.024]
- 15 **Makuuchi M**, Sano K. The surgical approach to HCC: our progress and results in Japan. *Liver Transpl* 2004; **10**: S46-S52 [PMID: 14762839 DOI: 10.1002/lt.20044]
- 16 **European Association For The Study Of The Liver**; European Organisation For Research And Treatment Of Cancer. EASL-EORTC clinical practice guidelines: management of hepatocellular carcinoma. *J Hepatol* 2012; **56**: 908-943 [PMID: 22424438 DOI: 10.1016/j.jhep.2011.12.001]
- 17 **Bruix J**, Castells A, Bosch J, Feu F, Fuster J, Garcia-Pagan JC, Visa J, Bru C, Rodés J. Surgical resection of hepatocellular carcinoma in cirrhotic patients: prognostic value of preoperative portal pressure. *Gastroenterology* 1996; **111**: 1018-1022 [PMID: 8831597 DOI: 10.1016/S0016-5085(96)70070-7]
- 18 **Ishizawa T**, Hasegawa K, Aoki T, Takahashi M, Inoue Y, Sano K, Imamura H, Sugawara Y, Kokudo N, Makuuchi M. Neither multiple tumors nor portal hypertension are surgical contraindications for hepatocellular carcinoma. *Gastroenterology* 2008; **134**: 1908-1916 [PMID: 18549877 DOI: 10.1053/j.gastro.2008.02.091]
- 19 **Kashima Y**, Miyazaki M, Ito H, Kaiho T, Nakagawa K, Ambiru S, Shimizu H, Furuya S, Nakajima N. Effective hepatic artery chemoembolization for advanced hepatocellular carcinoma with extensive tumour thrombus through the hepatic vein. *J Gastroenterol Hepatol* 1999; **14**: 922-927 [PMID: 10535476 DOI: 10.1046/j.1440-1746.1999.01966.x]
- 20 **Minagawa M**, Makuuchi M, Takayama T, Ohtomo K. Selection criteria for hepatectomy in patients with hepatocellular carcinoma and portal vein tumor thrombus. *Ann Surg* 2001; **233**: 379-384 [PMID: 11224626 DOI: 10.1097/0000658-200103000-00012]
- 21 **Yoshidome H**, Takeuchi D, Kimura F, Shimizu H, Ohtsuka M, Kato A, Furukawa K, Yoshitomi H, Miyazaki M. Treatment strategy for hepatocellular carcinoma with major portal vein or inferior vena cava invasion: a single institution experience. *J Am Coll Surg* 2011; **212**: 796-803 [PMID: 21530845 DOI: 10.1016/j.jamcollsurg.2011.01.002]
- 22 **Miyazaki M**, Kimura F, Shimizu H, Yoshidome H, Ohtsuka M, Kato A, Yoshitomi H, Nozawa S, Furukawa K, Takeuchi D, Suda K, Yoshioka I, Mituhashi N. Surgical treatment for liver cancer. Current issues. *Dig Surg* 2007; **24**: 120-125 [PMID: 17446706 DOI: 10.1159/000101899]
- 23 **Ebara M**, Ohto M, Sugiura N, Kita K, Yoshikawa M, Okuda K, Kondo F, Kondo Y. Percutaneous ethanol injection for the treatment of small hepatocellular carcinoma. Study of 95 patients. *J Gastroenterol Hepatol* 1990; **5**: 616-626 [PMID: 1966597 DOI: 10.1111/j.1440-1746.1990.tb01115.x]
- 24 **Hasegawa K**, Kokudo N, Shiina S, Tateishi R, Makuuchi M. Surgery versus radiofrequency ablation for small hepatocellular carcinoma: Start of a randomized controlled trial (SURF trial). *Hepatol Res* 2010; **40**: 851-852 [PMID: 20649823 DOI: 10.1111/j.1872-034X.2010.00696.x]
- 25 **Ogura K**, Miyake R, Shiina S, Shinoda Y, Okuma T, Kobayashi H, Goto T, Nakamura K, Kawano H. Bone radiofrequency ablation combined with prophylactic internal fixation for metastatic bone tumor of the femur from hepatocellular carcinoma. *Int J Clin Oncol* 2012; **17**: 417-421 [PMID: 21915771 DOI: 10.1007/s10147-011-0319-y]
- 26 **Cho YK**, Kim JK, Kim MY, Rhim H, Han JK. Systematic review of randomized trials for hepatocellular carcinoma treated with percutaneous ablation therapies. *Hepatology* 2009; **49**: 453-459 [PMID: 19065676 DOI: 10.1002/hep.22648]
- 27 **Guest J**, Blumgart LH. Surgery of liver tumours. *Baillieres Clin Gastroenterol* 1987; **1**: 131-150 [PMID: 3034356 DOI: 10.1016/0950-3528(87)90037-6]
- 28 **O'Grady JG**, Polson RJ, Rolles K, Calne RY, Williams R. Liver transplantation for malignant disease. Results in 93 consecutive patients. *Ann Surg* 1988; **207**: 373-379 [PMID: 2451484 DOI: 10.1097/0000658-198804000-00002]
- 29 **Jaurrieta E**, Fabregat J, Figueras J, Bella R, Moreno-Llorente P, Rafecas A, Torras J, Casanovas T, Casais L. Liver transplantation in hepatocellular carcinoma. *Transpl Int* 1992; **5** Suppl 1: S196-S197 [PMID: 14621774 DOI: 10.1007/978-3-642-77423-2_61]
- 30 **Mazzaferro V**, Regalia E, Doci R, Andreola S, Pulvirenti A, Bozzetti F, Montalto F, Ammatuna M, Morabito A, Gennari L. Liver transplantation for the treatment of small hepatocellular carcinomas in patients with cirrhosis. *N Engl J Med* 1996; **334**: 693-699 [PMID: 8594428 DOI: 10.1056/NEJM199603143341104]
- 31 **Figueras J**, Ibañez L, Ramos E, Jaurrieta E, Ortiz-de-Urbina J, Pardo F, Mir J, Loinaz C, Herrera L, López-Cillero P, Santoyo J. Selection criteria for liver transplantation in early-stage hepatocellular carcinoma with cirrhosis: results of a multicenter study. *Liver Transpl* 2001; **7**: 877-883 [PMID: 11679986 DOI: 10.1053/jlts.2001.27856]
- 32 **Llovet JM**, Fuster J, Bruix J. The Barcelona approach: diagnosis, staging, and treatment of hepatocellular carcinoma. *Liver Transpl* 2004; **10**: S115-S120 [PMID: 14762851 DOI: 10.1002/lt.20034]
- 33 **Sarasin FP**, Majno PE, Llovet JM, Bruix J, Mentha G, Hadengue A. Living donor liver transplantation for early hepatocellular carcinoma: A life-expectancy and cost-effectiveness perspective. *Hepatology* 2001; **33**: 1073-1079 [PMID: 11343234 DOI: 10.1053/jhep.2001.23311]
- 34 **Kurtovic J**, Riordan SM, Williams R. Liver transplantation for hepatocellular carcinoma. *Best Pract Res Clin Gastroenterol* 2005; **19**: 147-160 [PMID: 15757810 DOI: 10.1016/j.bpg.2004.10.002]

- 35 **Akamatsu N**, Sugawara Y, Kokudo N. Living donor liver transplantation for patients with hepatocellular carcinoma. *Liver Cancer* 2014; **3**: 108-118 [PMID: 24945001 DOI: 10.1159/000343866]
- 36 **Akamatsu N**, Sugawara Y, Kokudo N. Living-donor vs deceased-donor liver transplantation for patients with hepatocellular carcinoma. *World J Hepatol* 2014; **6**: 626-631 [PMID: 25276278 DOI: 10.4254/wjh.v6.i9.626]
- 37 **Yoshida H**, Shiratori Y, Moriyama M, Arakawa Y, Ide T, Sata M, Inoue O, Yano M, Tanaka M, Fujiyama S, Nishiguchi S, Kuroki T, Imazeki F, Yokosuka O, Kinoyama S, Yamada G, Omata M. Interferon therapy reduces the risk for hepatocellular carcinoma: national surveillance program of cirrhotic and noncirrhotic patients with chronic hepatitis C in Japan. IHIT Study Group. Inhibition of Hepatocarcinogenesis by Interferon Therapy. *Ann Intern Med* 1999; **131**: 174-181 [PMID: 10428733 DOI: 10.7326/0003-4819-131-3-199908030-00003]
- 38 **Shiratori Y**, Shiina S, Teratani T, Imamura M, Obi S, Sato S, Koike Y, Yoshida H, Omata M. Interferon therapy after tumor ablation improves prognosis in patients with hepatocellular carcinoma associated with hepatitis C virus. *Ann Intern Med* 2003; **138**: 299-306 [PMID: 12585827 DOI: 10.7326/0003-4819-138-4-200302180-00008]
- 39 **Shiratori Y**, Ito Y, Yokosuka O, Imazeki F, Nakata R, Tanaka N, Arakawa Y, Hashimoto E, Hirota K, Yoshida H, Ohashi Y, Omata M. Antiviral therapy for cirrhotic hepatitis C: association with reduced hepatocellular carcinoma development and improved survival. *Ann Intern Med* 2005; **142**: 105-114 [PMID: 15657158 DOI: 10.7326/0003-4819-142-2-200501180-00009]
- 40 **Morgan RL**, Baack B, Smith BD, Yartel A, Pitasi M, Falck-Ytter Y. Eradication of hepatitis C virus infection and the development of hepatocellular carcinoma: a meta-analysis of observational studies. *Ann Intern Med* 2013; **158**: 329-337 [PMID: 23460056 DOI: 10.7326/0003-4819-158-5-201303050-00005]
- 41 **Liaw YF**, Sung JJ, Chow WC, Farrell G, Lee CZ, Yuen H, Tanwandee T, Tao QM, Shue K, Keene ON, Dixon JS, Gray DF, Sabbat J. Lamivudine for patients with chronic hepatitis B and advanced liver disease. *N Engl J Med* 2004; **351**: 1521-1531 [PMID: 15470215 DOI: 10.1056/NEJMoa033364]
- 42 **Hosaka T**, Suzuki F, Kobayashi M, Seko Y, Kawamura Y, Sezaki H, Akuta N, Suzuki Y, Saitoh S, Arase Y, Ikeda K, Kobayashi M, Kumada H. Long-term entecavir treatment reduces hepatocellular carcinoma incidence in patients with hepatitis B virus infection. *Hepatology* 2013; **58**: 98-107 [PMID: 23213040 DOI: 10.1002/hep.26180]
- 43 **Gordon SC**, Lamerato LE, Rupp LB, Li J, Holmberg SD, Moorman AC, Spradling PR, Teshale EH, Vijayadeva V, Boscarino JA, Henkle EM, Oja-Tebbe N, Lu M. Antiviral therapy for chronic hepatitis B virus infection and development of hepatocellular carcinoma in a US population. *Clin Gastroenterol Hepatol* 2014; **12**: 885-893 [PMID: 24107395 DOI: 10.1016/j.cgh.2013.09.062]
- 44 **Huang G**, Lau WY, Wang ZG, Pan ZY, Yuan SX, Shen F, Zhou WP, Wu MC. Antiviral therapy improves postoperative survival in patients with hepatocellular carcinoma: a randomized controlled trial. *Ann Surg* 2015; **261**: 56-66 [PMID: 25072444 DOI: 10.1097/SLA.0000000000000858]
- 45 **Chong CC**, Wong GL, Wong VW, Ip PC, Cheung YS, Wong J, Lee KF, Lai PB, Chan HL. Antiviral therapy improves post-hepatectomy survival in patients with hepatitis B virus-related hepatocellular carcinoma: a prospective-retrospective study. *Aliment Pharmacol Ther* 2015; **41**: 199-208 [PMID: 25413146 DOI: 10.1111/apt.13034]
- 46 **Di Bisceglie AM**, Shiffman ML, Everson GT, Lindsay KL, Everhart JE, Wright EC, Lee WM, Lok AS, Bonkovsky HL, Morgan TR, Ghany MG, Morishima C, Snow KK, Dienstag JL. Prolonged therapy of advanced chronic hepatitis C with low-dose peginterferon. *N Engl J Med* 2008; **359**: 2429-2441 [PMID: 19052125 DOI: 10.1056/NEJMoa0707615]
- 47 **Morgan TR**, Ghany MG, Kim HY, Snow KK, Shiffman ML, De Santo JL, Lee WM, Di Bisceglie AM, Bonkovsky HL, Dienstag JL, Morishima C, Lindsay KL, Lok AS. Outcome of sustained virological responders with histologically advanced chronic hepatitis C. *Hepatology* 2010; **52**: 833-844 [PMID: 20564351 DOI: 10.1002/hep.23744]
- 48 **Lok AS**, Everhart JE, Wright EC, Di Bisceglie AM, Kim HY, Sterling RK, Everson GT, Lindsay KL, Lee WM, Bonkovsky HL, Dienstag JL, Ghany MG, Morishima C, Morgan TR. Maintenance peginterferon therapy and other factors associated with hepatocellular carcinoma in patients with advanced hepatitis C. *Gastroenterology* 2011; **140**: 840-849; quiz e12 [PMID: 21129375 DOI: 10.1053/j.gastro.2010.11.050]
- 49 **Kanda T**, Imazeki F, Mikami S, Kato K, Shimada N, Yonemitsu Y, Miyauchi T, Arai M, Fujiwara K, Tsubota A, Takada N, Nishino T, Takashi M, Sugiura N, Kimura M, Fukai K, Yokosuka O. Occurrence of hepatocellular carcinoma was not a rare event during and immediately after antiviral treatment in Japanese HCV-positive patients. *Oncology* 2011; **80**: 366-372 [PMID: 21822027 DOI: 10.1159/000330549]
- 50 **Kanda T**, Nakamoto S, Yasui S, Nakamura M, Miyamura T, Wu S, Jiang X, Arai M, Imazeki F, Yokosuka O. Occurrence and Recurrence of Hepatocellular Carcinoma Were Not Rare Events during Phlebotomy in Older Hepatitis C Virus-Infected Patients. *Case Rep Oncol* 2014; **7**: 288-296 [PMID: 24926259 DOI: 10.1159/000362869]
- 51 **Singal AK**, Salameh H, Kuo YF, Fontana RJ. Meta-analysis: the impact of oral anti-viral agents on the incidence of hepatocellular carcinoma in chronic hepatitis B. *Aliment Pharmacol Ther* 2013; **38**: 98-106 [PMID: 23713520 DOI: 10.1111/apt.12344]
- 52 **Arends P**, Sonneveld MJ, Zoutendijk R, Carey I, Brown A, Fasano M, Mutimer D, Deterding K, Reijnders JG, Oo Y, Petersen J, van Bömmel F, de Knecht RJ, Santantonio T, Berg T, Welzel TM, Wedemeyer H, Buti M, Pradat P, Zoulim F, Hansen B, Janssen HL; VIRGIL Surveillance Study Group. Entecavir treatment does not eliminate the risk of hepatocellular carcinoma in chronic hepatitis B: limited role for risk scores in Caucasians. *Gut* 2015; **64**: 1289-1295 [PMID: 25011935 DOI: 10.1136/gutjnl-2014-307023]
- 53 **Alamo JM**, Olivares C, Jiménez G, Bernal C, Marín LM, Tinoco J, Suárez G, Serrano J, Padillo J, Gómez MÁ. Donor characteristics that are associated with survival in liver transplant recipients older than 70 years with grafts. *Transplant Proc* 2013; **45**: 3633-3636 [PMID: 24314980 DOI: 10.1016/j.transproceed.2013.10.031]
- 54 **Oezcelik A**, Dayangac M, Guler N, Yaprak O, Erdogan Y, Akyildiz M, Sevdik Z, Yuzer Y, Tokat Y. Living Donor Liver Transplantation in Patients 70 Years or Older. *Transplantation* 2015; **99**: 1436-1440 [PMID: 25606791 DOI: 10.1097/TP.0000000000000524]
- 55 **Escudier B**, Eisen T, Stadler WM, Szczylk C, Oudard S, Siebels M, Negrier S, Chevreau C, Solska E, Desai AA, Rolland F, Demkow T, Hutson TE, Gore M, Freeman S, Schwartz B, Shan M, Simantov R, Bukowski RM. Sorafenib in advanced clear-cell renal-cell carcinoma. *N Engl J Med* 2007; **356**: 125-134 [PMID: 17215530 DOI: 10.1056/NEJMoa060655]
- 56 **Llovet JM**, Ricci S, Mazzaferro V, Hilgard P, Gane E, Blanc JF, de Oliveira AC, Santoro A, Raoul JL, Forner A, Schwartz M, Porta C, Zeuzem S, Bolondi L, Greten TF, Galle PR, Seitz JF, Borbath I, Häussinger D, Giannaris T, Shan M, Moscovici M, Voliotis D, Bruix J. Sorafenib in advanced hepatocellular carcinoma. *N Engl J Med* 2008; **359**: 378-390 [PMID: 18650514 DOI: 10.1056/NEJMoa0708857]
- 57 **Cheng AL**, Kang YK, Chen Z, Tsao CJ, Qin S, Kim JS, Luo R, Feng J, Ye S, Yang TS, Xu J, Sun Y, Liang H, Liu J, Wang J, Tak WY, Pan H, Burock K, Zou J, Voliotis D, Guan Z. Efficacy and safety of sorafenib in patients in the Asia-Pacific region with advanced hepatocellular carcinoma: a phase III randomised, double-blind, placebo-controlled trial. *Lancet Oncol* 2009; **10**: 25-34 [PMID: 19095497 DOI: 10.1016/S1470-2045(08)70285-7]
- 58 **Kanda T**, Imazeki F, Kanai F, Tada M, Yokosuka O, Omata M. Signaling pathways involved in molecular carcinogenesis of hepatocellular carcinoma. Molecular Aspects of Hepatocellular Carcinoma. 1st ed. Qiao L, Li Y, Yan X, George J, editors. Saif Zone, UAE: Bentham Science Publishers, 2012: 39-55
- 59 **Jiang X**, Kanda T, Nakamoto S, Miyamura T, Wu S, Yokosuka O.

- Involvement of androgen receptor and glucose-regulated protein 78 kDa in human hepatocarcinogenesis. *Exp Cell Res* 2014; **323**: 326-336 [PMID: 24583399 DOI: 10.1016/j.yexcr.2014.02.017]
- 60 **Takayasu K**, Arii S, Ikai I, Omata M, Okita K, Ichida T, Matsuyama Y, Nakanuma Y, Kojiro M, Makuuchi M, Yamaoka Y. Prospective cohort study of transarterial chemoembolization for unresectable hepatocellular carcinoma in 8510 patients. *Gastroenterology* 2006; **131**: 461-469 [PMID: 16890600]
 - 61 **Takayasu K**, Arii S, Kudo M, Ichida T, Matsui O, Izumi N, Matsuyama Y, Sakamoto M, Nakashima O, Ku Y, Kokudo N, Makuuchi M. Superselective transarterial chemoembolization for hepatocellular carcinoma. Validation of treatment algorithm proposed by Japanese guidelines. *J Hepatol* 2012; **56**: 886-892 [PMID: 22173160 DOI: 10.1016/j.jhep.2011.10.021]
 - 62 **Han KH**, Kudo M, Ye SL, Choi JY, Poon RT, Seong J, Park JW, Ichida T, Chung JW, Chow P, Cheng AL. Asian consensus workshop report: expert consensus guideline for the management of intermediate and advanced hepatocellular carcinoma in Asia. *Oncology* 2011; **81** Suppl 1: 158-164 [PMID: 2212951 DOI: 10.1159/000333280]
 - 63 **Ohnishi K**, Tsuchiya S, Nakayama T, Hiyama Y, Iwama S, Goto N, Takashi M, Ohtsuki T, Kono K, Nakajima Y. Arterial chemoembolization of hepatocellular carcinoma with mitomycin C microcapsules. *Radiology* 1984; **152**: 51-55 [PMID: 6203138]
 - 64 **Soga K**, Nomoto M, Ichida T, Aoyagi Y, Ozaki T, Ichida F. Clinical evaluation of transcatheter arterial embolization and one-shot chemotherapy in hepatocellular carcinoma. *Hepatogastroenterology* 1988; **35**: 116-120 [PMID: 2841214]
 - 65 **Golfieri R**, Giampalma E, Renzulli M, Cioni R, Bargellini I, Bartolozzi C, Breata AD, Gandini G, Nani R, Gasparini D, Cucchetti A, Bolondi L, Trevisani F. Randomised controlled trial of doxorubicin-eluting beads vs conventional chemoembolisation for hepatocellular carcinoma. *Br J Cancer* 2014; **111**: 255-264 [PMID: 24937669 DOI: 10.1038/bjc.2014.199]
 - 66 **Andreana L**, Isgrò G, Marelli L, Davies N, Yu D, Navalkisoor S, Burroughs AK. Treatment of hepatocellular carcinoma (HCC) by intra-arterial infusion of radio-emitter compounds: trans-arterial radio-embolisation of HCC. *Cancer Treat Rev* 2012; **38**: 641-649 [PMID: 22169503 DOI: 10.1016/j.ctrv.2011.11.004]
 - 67 **Goyal K**, Einstein D, Yao M, Kunos C, Barton F, Singh D, Siegel C, Stulberg J, Sanabria J. Cyberknife stereotactic body radiation therapy for nonresectable tumors of the liver: preliminary results. *HPB Surg* 2010; **2010**: pii: 309780 [PMID: 20689733 DOI: 10.1155/2010/309780]
 - 68 **Huang WY**, Jen YM, Lee MS, Chang LP, Chen CM, Ko KH, Lin KT, Lin JC, Chao HL, Lin CS, Su YF, Fan CY, Chang YW. Stereotactic body radiation therapy in recurrent hepatocellular carcinoma. *Int J Radiat Oncol Biol Phys* 2012; **84**: 355-361 [PMID: 22342300 DOI: 10.1016/j.ijrobp.2011.11.058]
 - 69 **O'Connor JK**, Trotter J, Davis GL, Dempster J, Klintmalm GB, Goldstein RM. Long-term outcomes of stereotactic body radiation therapy in the treatment of hepatocellular cancer as a bridge to transplantation. *Liver Transpl* 2012; **18**: 949-954 [PMID: 22467602 DOI: 10.1002/lt.23439]
 - 70 **Bibault JE**, Dewas S, Vautravers-Dewas C, Hollebecque A, Jarraya H, Lacomberie T, Lartigau E, Mirabel X. Stereotactic body radiation therapy for hepatocellular carcinoma: prognostic factors of local control, overall survival, and toxicity. *PLoS One* 2013; **8**: e77472 [PMID: 24147002 DOI: 10.1371/journal.pone.0077472]
 - 71 **Lo CH**, Huang WY, Lee MS, Lin KT, Lin TP, Chang PY, Fan CY, Jen YM. Stereotactic ablative radiotherapy for unresectable hepatocellular carcinoma patients who failed or were unsuitable for transarterial chemoembolization. *Eur J Gastroenterol Hepatol* 2014; **26**: 345-352 [PMID: 24384685 DOI: 10.1097/MEG.0000000000000032]
 - 72 **Que JY**, Lin LC, Lin KL, Lin CH, Lin YW, Yang CC. The efficacy of stereotactic body radiation therapy on huge hepatocellular carcinoma unsuitable for other local modalities. *Radiat Oncol* 2014; **9**: 120 [PMID: 24885086 DOI: 10.1186/1748-717X-9-120]
 - 73 **Lo CH**, Huang WY, Lin KT, Lin MJ, Lin TP, Jen YM. Repeated stereotactic ablative radiotherapy using CyberKnife for patients with hepatocellular carcinoma. *J Gastroenterol Hepatol* 2014; **29**: 1919-1925 [PMID: 25041220 DOI: 10.1111/jgh.12659]
 - 74 **Komatsu S**, Fukumoto T, Demizu Y, Miyawaki D, Terashima K, Sasaki R, Hori Y, Hishikawa Y, Ku Y, Murakami M. Clinical results and risk factors of proton and carbon ion therapy for hepatocellular carcinoma. *Cancer* 2011; **117**: 4890-4904 [PMID: 21495022 DOI: 10.1002/cncr.26134]
 - 75 **Kato H**, Tsujii H, Miyamoto T, Mizoe JE, Kamada T, Tsuji H, Yamada S, Kandatsu S, Yoshikawa K, Obata T, Ezawa H, Morita S, Tomizawa M, Morimoto N, Fujita J, Ohto M. Results of the first prospective study of carbon ion radiotherapy for hepatocellular carcinoma with liver cirrhosis. *Int J Radiat Oncol Biol Phys* 2004; **59**: 1468-1476 [PMID: 15275734]
 - 76 **Imada H**, Kato H, Yasuda S, Yamada S, Yanagi T, Hara R, Kishimoto R, Kandatsu S, Minohara S, Mizoe JE, Kamada T, Yokosuka O, Tsujii H. Compensatory enlargement of the liver after treatment of hepatocellular carcinoma with carbon ion radiotherapy - relation to prognosis and liver function. *Radiother Oncol* 2010; **96**: 236-242 [PMID: 20416964 DOI: 10.1016/j.radonc.2010.03.025]
 - 77 **Imada H**, Kato H, Yasuda S, Yamada S, Yanagi T, Kishimoto R, Kandatsu S, Mizoe JE, Kamada T, Yokosuka O, Tsujii H. Comparison of efficacy and toxicity of short-course carbon ion radiotherapy for hepatocellular carcinoma depending on their proximity to the porta hepatis. *Radiother Oncol* 2010; **96**: 231-235 [PMID: 20579756 DOI: 10.1016/j.radonc.2010.05.019]
 - 78 **Sasaki A**, Nitta H, Otsuka K, Takahara T, Nishizuka S, Wakabayashi G. Ten-year experience of totally laparoscopic liver resection in a single institution. *Br J Surg* 2009; **96**: 274-279 [PMID: 19224518 DOI: 10.1002/bjs.6472]
 - 79 **Ho CM**, Wakabayashi G, Nitta H, Takahashi M, Takahara T, Ito N, Hasegawa Y. Total laparoscopic limited anatomical resection for centrally located hepatocellular carcinoma in cirrhotic liver. *Surg Endosc* 2013; **27**: 1820-1825 [PMID: 23233006 DOI: 10.1007/s00464-012-2624-6]
 - 80 **Miyauchi T**, Kanda T, Shinozaki M, Kamezaki H, Wu S, Nakamoto S, Kato K, Arai M, Mikami S, Sugiura N, Kimura M, Goto N, Imazeki F, Yokosuka O. Efficacy of lamivudine or entecavir against virological rebound after achieving HBV DNA negativity in chronic hepatitis B patients. *Int J Med Sci* 2013; **10**: 647-652 [PMID: 23569428 DOI: 10.7150/ijms.5904]
 - 81 **Saito T**, Chiba T, Suzuki E, Shinozaki M, Goto N, Kanogawa N, Motoyama T, Ogasawara S, Ooka Y, Tawada A, Kanda T, Miyazaki M, Yokosuka O. Effect of previous interferon-based therapy on recurrence after curative treatment of hepatitis C virus-related hepatocellular carcinoma. *Int J Med Sci* 2014; **11**: 707-712 [PMID: 24843320 DOI: 10.7150/ijms.8764]
 - 82 **Kanda T**, Yokosuka O, Omata M. Treatment of hepatitis C virus infection in the future. *Clin Transl Med* 2013; **2**: 9 [PMID: 23577631 DOI: 10.1186/2001-1326-2-9]
 - 83 **Utsunomiya T**, Shimada M, Kudo M, Ichida T, Matsui O, Izumi N, Matsuyama Y, Sakamoto M, Nakashima O, Ku Y, Kokudo N, Makuuchi M. Nationwide study of 4741 patients with non-B non-C hepatocellular carcinoma with special reference to the therapeutic impact. *Ann Surg* 2014; **259**: 336-345 [PMID: 23673768 DOI: 10.1097/SLA.0b013e31829291e9]
 - 84 **Bruix J**, Sherman M. Management of hepatocellular carcinoma: an update. *Hepatology* 2011; **53**: 1020-1022 [PMID: 21374666 DOI: 10.1002/hep.24199]
 - 85 **Omata M**, Lesmana LA, Tateishi R, Chen PJ, Lin SM, Yoshida H, Kudo M, Lee JM, Choi BI, Poon RT, Shiina S, Cheng AL, Jia JD, Obi S, Han KH, Jafri W, Chow P, Lim SG, Chawla YK, Budihusodo U, Gani RA, Lesmana CR, Putranto TA, Liaw YF, Sarin SK. Asian Pacific Association for the Study of the Liver consensus recommendations on hepatocellular carcinoma. *Hepatol Int* 2010; **4**: 439-474 [PMID: 20827404 DOI: 10.1007/s12072-010-9165-7]
 - 86 **Kudo M**, Matsui O, Izumi N, Kadoya M, Okusaka T, Miyayama S, Yamakado K, Tsuchiya K, Ueshima K, Hiraoka A, Ikeda M, Ogasawara S, Yamashita T, Minami T. Transarterial chemo-

embolization failure/refractoriness: JSH-LCSGJ criteria 2014 update. *Oncology* 2014; **87** Suppl 1: 22-31 [PMID: 25427730 DOI: 10.1159/000368142]

87 **Roayaie S**, Jibara G, Tabrizian P, Park JW, Yang J, Yan L,

Schwartz M, Han G, Izzo F, Chen M, Blanc JF, Johnson P, Kudo M, Roberts LR, Sherman M. The role of hepatic resection in the treatment of hepatocellular cancer. *Hepatology* 2015; Epub ahead of print [PMID: 25678263 DOI: 10.1002/hep.27745]

P- Reviewer: Chiang TA, Mihaila RG, Moralioglu S
S- Editor: Tian YL **L- Editor:** A **E- Editor:** Liu SQ





Published by **Baishideng Publishing Group Inc**

8226 Regency Drive, Pleasanton, CA 94588, USA

Telephone: +1-925-223-8242

Fax: +1-925-223-8243

E-mail: bpgoffice@wjgnet.com

Help Desk: <http://www.wjgnet.com/esps/helpdesk.aspx>

<http://www.wjgnet.com>

