

Versatility of therapeutic reduction mammoplasty in oncoplastic breast conserving surgery

Fernando Hernanz, Mónica González-Noriega, Rocío Vázquez Pérez, Manuel Gómez-Fleitas

Fernando Hernanz, Mónica González-Noriega, Rocío Vázquez Pérez, Manuel Gómez-Fleitas, Department of Surgery, Valdecilla Hospital, 39008 Santander, Cantabria, Spain

Author contributions: Hernanz F contributed to the conception and design of the study, who carried out surgical procedures; González-Noriega M made acquisition of and analysis and interpretation of them; Pérez RV made acquisition of data; Gómez-Fleitas M made critical revision.

Conflict-of-interest statement: All authors disclose that they do not have any commercial associations or financial support.

Open-Access: This article is an open-access article which was selected by an in-house editor and fully peer-reviewed by external reviewers. It is distributed in accordance with the Creative Commons Attribution Non Commercial (CC BY-NC 4.0) license, which permits others to distribute, remix, adapt, build upon this work non-commercially, and license their derivative works on different terms, provided the original work is properly cited and the use is non-commercial. See: <http://creativecommons.org/licenses/by-nc/4.0/>

Correspondence to: Fernando Hernanz, MD, PhD, Assistant Professor of Surgery, Department of Surgery, Valdecilla Hospital, Avenue Valdecilla sn., 39008 Santander, Cantabria, Spain. cgdhff@humv.es
Telephone: +34-942-203733
Fax: +34-942-202726

Received: February 28, 2015
Peer-review started: March 2, 2015
First decision: June 3, 2015
Revised: June 27, 2015
Accepted: July 21, 2015
Article in press: July 23, 2015
Published online: November 28, 2015

Abstract

Oncoplastic breast conserving surgery is the gold standard approach for the surgical treatment of early breast cancer. There is a well defined technique named

"therapeutic mammoplasty" which is characterized for using a reduction mammoplasty technique to treat breast cancer conservatively. In our current practice, "therapeutic mammoplasty" or therapeutic reduction mammoplasty is our favorite oncoplastic breast conserving approach which it used in almost half of our patients. This technique is very versatile allows us the resection of tumors located in all breast quadrants of patients with moderate-to large-sized breasts. We describe a series of 57 patients who were treated using a therapeutic reduction mammoplasty. All surgical procedures were carried out by one comprehensive breast surgeon who planned and designed the surgery performing both oncologic and reconstructive procedures. Surgical margins were insufficient in eight patients (14%). Nine patients (15.8%) had a complication in early postoperative period and in one of them adjuvant radiotherapy was delayed four months due to a wound dehiscence. The rate of synchronous contralateral symmetrization was 31.6%. Our conclusion is that reduction mammoplasty is a useful and safe skill to treat breast cancer conservatively playing a very important role therefore it must be situated in the priority of learning objectives.

Key words: Breast conserving surgery; Oncoplastic; Oncoplastic breast surgery; Reduction mammoplasty; Therapeutic mammoplasty

© The Author(s) 2015. Published by Baishideng Publishing Group Inc. All rights reserved.

Core tip: Reduction mammoplasty techniques are a really useful and safe skills to treat breast cancer conservatively allowing breast surgeons manage tumors located in all breast quadrants with low morbidity in moderate to large breasted patients, thanks their versatility they play a very important role in oncoplastic conservative surgery therefore they must be situated in the priority of learning objectives.

Hernanz F, González-Noriega M, Pérez RV, Gómez-Fleitas M. Versatility of therapeutic reduction mammoplasty in oncoplastic breast conserving surgery. *World J Surg Proced* 2015; 5(3): 217-222 Available from: URL: <http://www.wjgnet.com/2219-2832/full/v5/i3/217.htm> DOI: <http://dx.doi.org/10.5412/wjssp.v5.i3.217>

INTRODUCTION

Currently, oncoplastic breast conserving surgery (OBCS) should be the gold standard approach for the surgical treatment of early breast cancer^[1-3]. Oncoplastic techniques (OT) offer clear advantages on nearly forty percent of patients in who common breast conserving treatment (BCT) (surgery plus radiotherapy) are followed by cosmetic sequelae^[4] besides the rest of the patients who also could be benefited from many surgical tricks which can improve aesthetic outcomes^[5]. Since 1998, when Audretsch *et al*^[6] described the use of plastic surgery techniques to reshape the breast at the time of lumpectomy or quadrantectomy introducing the term "oncoplastic", it has passed enough time to be able to evaluate long-term oncologic outcomes, therefore a meta-analysis gathering 3165 patients treated by OBCS vs 5494 treated BCT have demonstrated that OBCS obtain similar results to standard breast conserving surgery improving cosmetic outcome and patients' satisfaction^[7].

There is a large amount of OT but these can be classified in two main groups: Volume replacement or displacement techniques. Nowadays, the last ones, which are more frequently used^[8], have a broad technical variety with different patterns incisions, pedicles used for nipple areola complex (NAC) movement, ways to fill tumor removal defect and their multiple combinations. Several authors^[9-13] have created different algorithms attempting to optimize OT and offering us a method to select the most appropriate OT in each patient. These algorithms for immediate conservative surgery reconstruction are based on some aspects such as type and size of the breast, extent of tumor removal defect, ptosis degree, breast tissue density and location of the tumor in the breast. Other aspects very important in the process of decision are patient preferences and surgeon expertise.

In OT displacement volume group there is well defined technique a "therapeutic mammoplasty" term coined by McCulley *et al*^[14,15] which is characterized for using a reduction mammoplasty technique and radiotherapy to treat breast cancer. These authors described two different scenarios depending if the tumor lies or not within the routine pattern incision and excision dividing the breast in nine areas with theirs corresponding approaches. Therapeutic mammoplasty is especially useful in large breasted patients in who a bilateral reduction mammoplasty offers clear advantages which are both oncological and functional which cause better radiation therapy and beside relieving the symp-

toms related to breast hypertrophy thus improves quality of life^[16], even more, this approach is a better option than skin-sparing total mastectomy and immediate reconstruction having lower morbidity and more favorable cosmesis^[17].

Munhoz *et al*^[18], wrote that the main advantages of the therapeutic reduction mammoplasty (TRM) should include reproducibility, low interference with oncological treatment and long-term results. We agree completely with him and it is more, based on our experience, we would like to add that this technique is versatile because it could be used to treat tumors located in all breast quadrants with the condition that the patient having a moderate to large-sized breast.

The aim of this work was to communicate our experience with TRM showing the distribution of tumors into the breast, rate of affected margins, early surgical complications, and synchronous contralateral breast symmetrization.

PATIENTS AND METHODS

Between 2005 and 2013, 57 patients suffering from breast cancer suitable for BCT underwent TRM at our Oncoplastic Breast Unit, Hospital Valdecilla (Santander, Spain). All surgical procedures were carried out by one comprehensive breast surgeon (FH) who planned and designed the surgery performing both oncologic and reconstructive procedures. Data from patient and tumor characteristics, surgical procedures, early complications and pathological study were prospectively collected and stored in IBM SPSS statistics program.

RESEARCH RESULT

Characteristic of patients and tumours are described in Tables 1 and 2. Seven patients were treated before surgery with neoadjuvant chemotherapy. Most of tumor excisions were guided by needle-wires (84.2%) according to our method previously published^[19]; wires were inserted 1 cm distant to radiologic tumors limits as markers of optimal limit resection, sufficiently of resection margins was per-operatively tested by X-ray analysis of surgical specimen. Biopsy of sentinel lymph node (49) and axillary lymphadenectomy (10) was performed in mostly patients by the T inverted pattern incision. Opposite breast surgery by reduction mammoplasty was carried out in eighteen patients (31.6%).

Surgical margins status

Margins were insufficient in eight patients (14%), five affected and three with focal involvement. Two of them having affected margins underwent total mastectomy. Pathologic study of mastectomy showed residual invasive carcinoma and carcinoma *in situ* in one patient and residual ductal carcinoma *in situ* in the other.

Early surgical complications

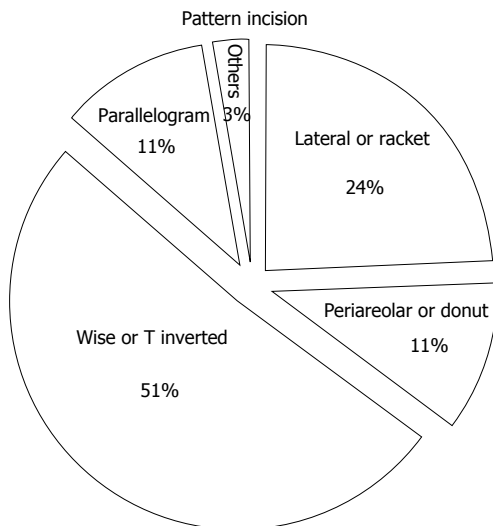
Nine patients (15.8%) had a complication in early

Table 1 Characteristics of the series of 57 patients *n* (%)

Age (yr)	57, 8.9 SD
Status menstrual	
Premenopausal	13 (22.8)
Postmenopausal	44 (77.2)
Affected breast	
Right	19 (33.3)
Left	38 (66.7)
Tumour location through the breast (quadrant)	
Upper outer	16 (28.1)
Upper inner	3 (5.3)
Lower Inner	3 (5.3)
Central	12 (21.1)
Intersection upper quadrants	7 (12.3)
Intersection lower quadrants	5 (8.8)
Intersection inner quadrants	3 (5.3)
Intersection outer quadrants	7 (12.3)
Inframmary fold	1 (1.8)
Multifocal	14 (24.6)
Radiological tumour size (mm)	21.7, 12.58 SD

Table 2 Characteristic of 57 breast carcinomas *n* (%)

<i>In situ</i>	7 (12.3)
Invasive	50 (87.7)
Type of histology	
Ductal	39
Lobular	6
Mixed	1
Papilar	1
Others	3
Positive estrogenic receptors	38
Positive progesterone receptors	37
Positive Herb2 receptors	7
Ki67 (<i>n</i> = 42)	
> 10%	15
10%-50%	19
51%-75%	3
> 75%	4
Pathologic tumour size (mm)	17.1, 9.77 SD
Patients with lymph nodes positives	12 (14)

**Figure 1** Distribution of the pattern incisions used in breast cancer patients treated using oncoplastic conservative approach at our unit.

postoperative period (five a hematoma, four a minor wound dehiscence) and three of them had to be re-operated for evacuating a hematoma. There were no major complications such necrosis of NAC or severe breast infections and only one adjuvant radiotherapy was delayed four months in one patient due to a wound dehiscence.

DISCUSSION

Although some OT are specifically useful to manage some determined tumor locations such as a lateral or tennis racket mammoplasty^[20] for tumors located at upper outer quadrant or LIQ-V mammoplasties^[21] for these located at lower inner quadrants, reduction mammoplasty with T inverted pattern incision appropriately adapted is be able to treat tumors situated at all breast quadrants. In a very large series of 540

consecutive cases published by Fitoussi *et al*^[22] in which a variety of OT were used, T inverted pattern incision was the most frequently utilized in 40% of patients. Our current BCT entails 77.2% of breast cancer surgery and in oncoplastic breast conserving experience using volume displacement technique this pattern incision is the most common (Figure 1) used in 52% of cases, and our favorite approach (unpublished data).

As inner quadrants were the less frequent tumor localizations with 10.6% and the outer ones were the most frequent our first choice to move NAC was a superomedial pedicle but in this series we also used inferior and bipediced ones. In those patients with central tumors in who NAC had to be removed we reconstructed NAC using different techniques, for example, contralateral areola (Figure 2) or skin graft plus arrow flap for nipple reconstruction. The variation of localizations shows the versatility of TRM in breast with moderate or large size.

Early complications rate was 15.8%, these were minor; our experience is similar to others authors such as Gulcelik *et al*^[23] who reported a rate of minor early complications of 16.3% and major ones of 1.9% without differences between reduction mammoplasty used for macromastia treatment and breast cancer. A wide range of complications rate of therapeutic reduction mammoplasty has been reported^[24] likely due to differences in criteria and collecting data but, one conclusion is uniform that they usually are minor not impacting seriously on delivery of adjuvant therapies unless they were severe, McIntosh *et al*^[25] in a systematic review found that delayed adjuvant treatment in only 6% of cases.

The rate of synchronous contralateral symmetrization was 31.6% but most of these patients were operated in the first half of the series before 2011; like as Fitoussi *et al*^[22] our current preference is delayed contralateral symmetrization. The reasons for that have been clearly exposed by Kaviani *et al*^[26] who categorized the patients in three groups: Patients unwilling any contralateral

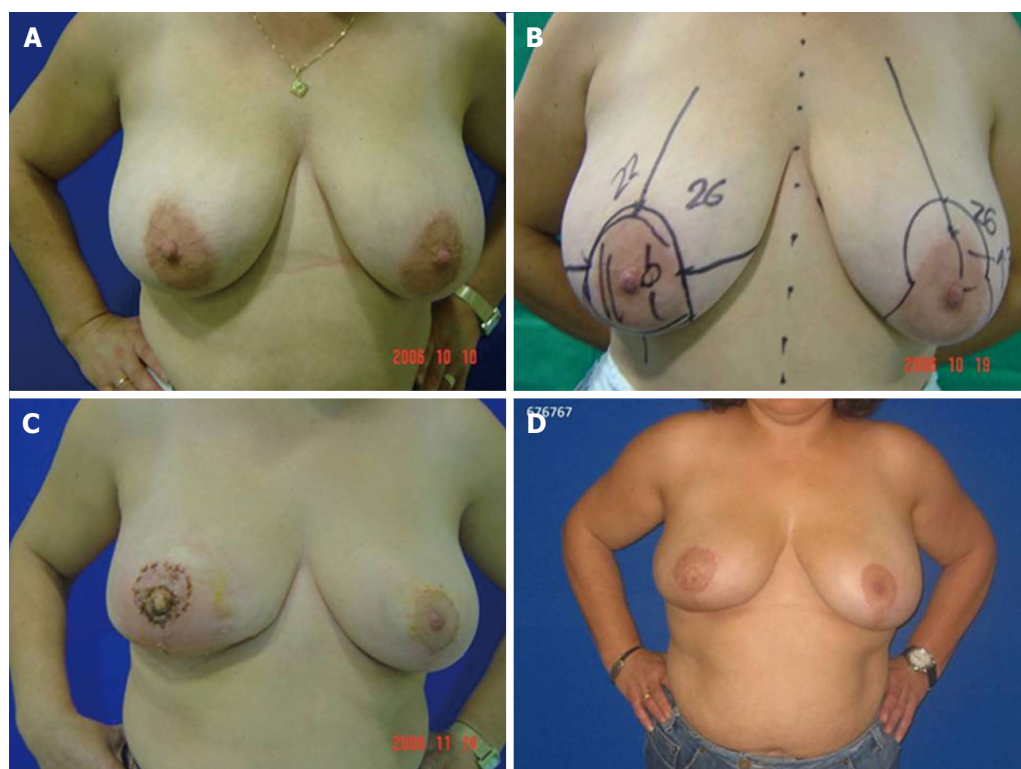

Figure 2 A 40-year-old postmenopausal woman with an invasive ductal carcinoma with positive estrogenic, progesterone and Herb2 receptors situated at central quadrant of right breast which sized 15 mm on mammograms. A and B: Appearance of patient. Design of pattern of therapeutic reduction mammoplasty; C and D: Nipple areola complex right reconstructed by contralateral areola graft. Long-term aesthetic outcome.

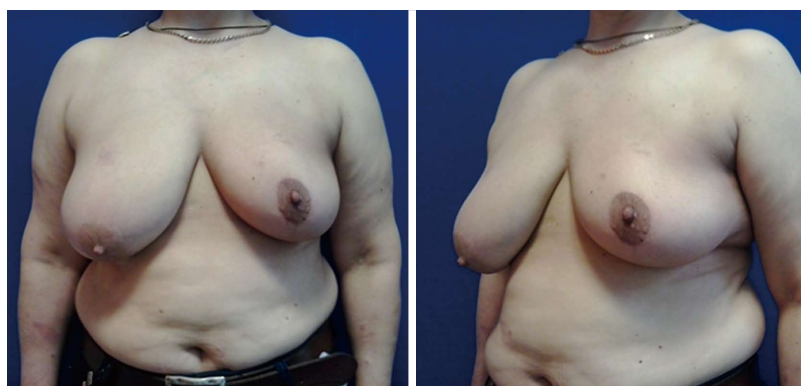

Figure 3 Appearance of a 49-year-old woman after underwent oncoplastic breast conserving surgery and posterior adjuvant chemotherapy and radiotherapy. She had a bifocal invasive lobulillar carcinoma situated at intersection of upper quadrants with positive estrogenic and progesterone receptors and T₂N₀M₀ pathological staging. She presents breast asymmetry which she wants it to be corrected.

procedures, patients preferring an all-in-one operation willing immediate symmetrization and patients desiring optimal aesthetic results; only patients belonging to the second group are candidates to immediate contralateral symmetrization. In our experience, our average patient is in the first group. Figure 3 shows the appearance of a patient belonging to third group with breast asymmetry which she wants it to be corrected; we will carry out symmetrization of the right breast when she stabilized her weight because she put on weight during chemotherapy treatment.

Patient satisfaction and aesthetic outcomes reported are very high with a low rate of failure as which sum-

marized by the fact that almost none patients regretted to chose this type of surgery^[18]. Changes of aesthetic outcomes over the time after completing radiotherapy have been commented not affecting negatively patient satisfaction. In our experience, TRM as reduction mammoplasty technique has the same limitations and aesthetic outcomes can be deteriorated over the time by pseudoptosis (Figure 4) or excessive weight gain.

Finally, all OT and more specifically those of level II are based on the knowledge of reduction mammoplasty techniques; independently, which model for oncoplastic approach can be chosen "comprehensive breast surgeon" or "oncologic and plastic team", skill sharing

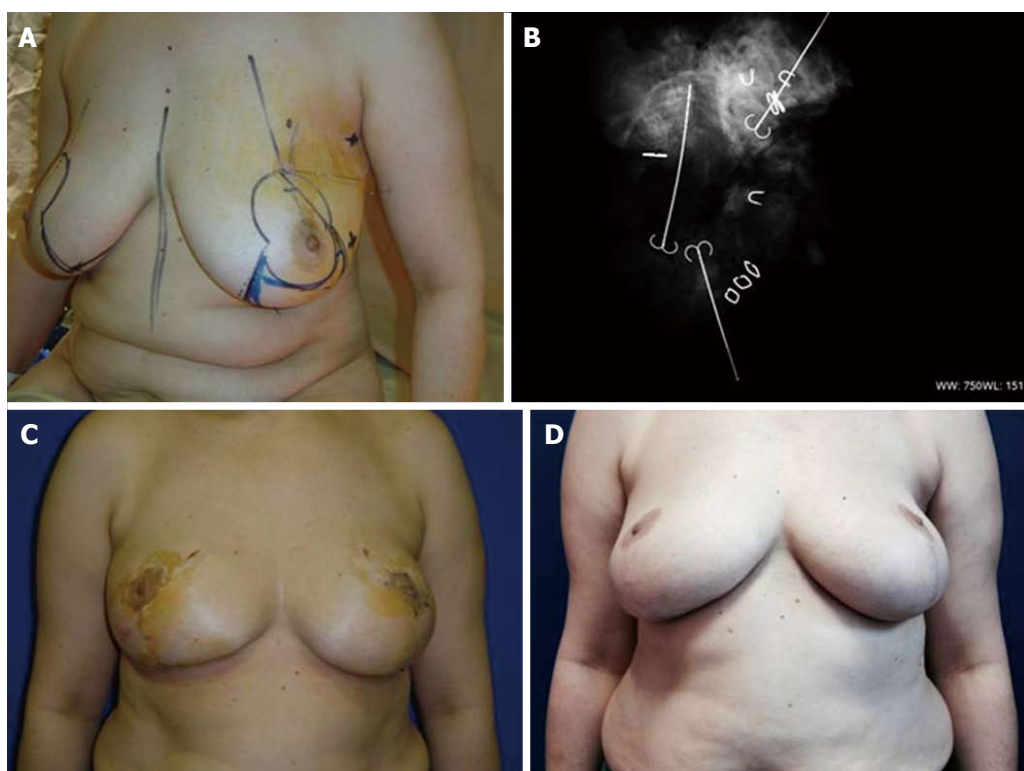


Figure 4 A 44-year-old premenopausal female with an invasive ductal carcinoma at upper outer quadrant of the left breast which sized 35 mm on mammograms who was treated with neoadjuvant chemotherapy before surgery. A therapeutic bilateral reduction mammoplasty with T inverted pattern incision and superomedial pedicle used for shifting nipple areola complex and an infero-lateral one to fill the breast defect caused by extirpation of a surgical specimen weighted 223 g was carried out. Pathological study showed a tumor size 12 mm, one negative sentinel lymph node and free surgical margins. A: Design of pattern incision with three wires inserted to guide tumor excision; B: X-ray of surgical specimen showed complete radiological removal of tumor; C: Appearance on early postoperative period; D: Long-term aesthetic outcome three years after breast conserving treatment shows both breasts with pseudotosis.

between breast unit members is eagerly desirable and, in our opinion, about reduction mammoplasty techniques the former statement is essential. Accepting the lack of oncoplastic training^[27] and the fact that expertise requires long time^[28], we proposed a management policy^[29] to mitigate this situation incorporating the surgical treatment of symptomatic macromastia into Breast Cancer Unit^[30]. One step in this direction is the inclusion of gynaecomastia and congenital asymmetry surgical treatment into several Oncoplastic Breast Surgery Units in United Kingdom.

CONCLUSION

Reduction mammoplasty technique is a useful and safe skill to treat breast cancer located in all breast quadrants with low morbidity playing a very important role in oncoplastic conservative surgery in moderate to large breasted patients therefore it must be situated in the priority of learning objectives.

REFERENCES

- 1 **Warren AG**, Morris DJ, Houlihan MJ, Slavin SA. Breast reconstruction in a changing breast cancer treatment paradigm. *Plast Reconstr Surg* 2008; **121**: 1116-1126 [PMID: 18349628 DOI: 10.1097/01.prs.0000305516.93441.fd]
- 2 **Spear SL**. Oncoplastic surgery. *Plast Reconstr Surg* 2009; **124**: 993-994 [PMID: 19730325 DOI: 10.1097/PRS.0b013e3181b17ab3]
- 3 **Silverstein MJ**, Mai T, Savalia N, Vaince F, Guerra L. Oncoplastic breast conservation surgery: the new paradigm. *J Surg Oncol* 2014; **110**: 82-89 [PMID: 24847860 DOI: 10.1002/jso.23641]
- 4 **Hernanz F**, Pérez-Cerdeira M, Sánchez S, Redondo-Figueroa C. Cosmetic sequelae after breast-conserving treatment using conventional surgical techniques. *Breast J* 2013; **19**: 342-343 [PMID: 23600624 DOI: 10.1111/tbj.12113]
- 5 **Petit JY**, De Lorenzi F, Rietjens M, Intra M, Martella S, Garusi C, Rey PC, Matthes AG. Technical tricks to improve the cosmetic results of breast-conserving treatment. *Breast* 2007; **16**: 13-16 [PMID: 17070051]
- 6 **Audretsch WP**, Rezai M, Kolotas C, Zamboglou N, Schnabel T, Bojar H. Tumor-specific immediate reconstruction in breast cancer patients. *Perspect Plast Surg* 1998; **11**: 71
- 7 **Losken A**, Dugal CS, Styblo TM, Carlson GW. A meta-analysis comparing breast conservation therapy alone to the oncoplastic technique. *Ann Plast Surg* 2014; **72**: 145-149 [PMID: 23503430 DOI: 10.1097/SAP.0b013e3182605598]
- 8 **Haloua MH**, Krekel NM, Winters HA, Rietveld DH, Meijer S, Bloemers FW, van den Tol MP. A systematic review of oncoplastic breast-conserving surgery: current weaknesses and future prospects. *Ann Surg* 2013; **257**: 609-620 [PMID: 23470508 DOI: 10.1097/SLA.0b013e3182888782]
- 9 **Churgin S**, Isakov R, Yetman R. Reconstruction options following breast conservation therapy. *Cleve Clin J Med* 2008; **75** Suppl 1: S24-S29 [PMID: 18457194]
- 10 **Munhoz AM**, Montag E, Arruda E, Pellarin L, Filassi JR, Piatto JR, de Barros AC, Prado LC, Fonseca A, Baracat E, Ferreira MC. Assessment of immediate conservative breast surgery reconstruction: a classification system of defects revisited and an algorithm for selecting the appropriate technique. *Plast Reconstr Surg* 2008; **121**: 716-727 [PMID: 18317121 DOI: 10.1097/01.

- prs.0000299295.74100.fa]
- 11 **Losken A**, Hamdi M. Partial breast reconstruction: current perspectives. *Plast Reconstr Surg* 2009; **124**: 722-736 [PMID: 19730292 DOI: 10.1097/PRS.0b013e3181b179d2]
- 12 **Clough KB**, Kaufman GJ, Nos C, Buccimazza I, Sarfati IM. Improving breast cancer surgery: a classification and quadrant per quadrant atlas for oncoplastic surgery. *Ann Surg Oncol* 2010; **17**: 1375-1391 [PMID: 20140531 DOI: 10.1245/s10434-009-0792-y]
- 13 **Urban C**, Lima R, Schunemann E, Spautz C, Rabinovich I, Anselmi K. Oncoplastic principles in breast conserving surgery. *Breast* 2011; **20** Suppl 3: S92-S95 [PMID: 22015301 DOI: 10.1016/S0960-9776(11)70302-2]
- 14 **McCulley SJ**, Macmillan RD. Planning and use of therapeutic mammoplasty--Nottingham approach. *Br J Plast Surg* 2005; **58**: 889-901 [PMID: 16043150 DOI: 10.1016/j.bjps.2005.03.008]
- 15 **McCulley SJ**, Macmillan RD. Therapeutic mammoplasty--analysis of 50 consecutive cases. *Br J Plast Surg* 2005; **58**: 902-907 [PMID: 16043153 DOI: 10.1016/j.bjps.2005.03.007]
- 16 **Hernanz F**, Regaño S, Vega A, Gómez Fleitas M. Reduction mammoplasty: an advantageous option for breast conserving surgery in large-breasted patients. *Surg Oncol* 2010; **19**: e95-e102 [PMID: 19716288 DOI: 10.1016/j.suronc.2009.08.001]
- 17 **Losken A**, Pinell XA, Eskenazi B. The benefits of partial versus total breast reconstruction for women with macromastia. *Plast Reconstr Surg* 2010; **125**: 1051-1056 [PMID: 20072088 DOI: 10.1097/PRS.0b013e318d0ab08]
- 18 **Munhoz AM**, Montag E, Gemperli R. Current aspects of therapeutic reduction mammoplasty for immediate early breast cancer management: An update. *World J Clin Oncol* 2014; **5**: 1-18 [PMID: 24527398 DOI: 10.5306/wjco.v5.i1.1]
- 19 **Hernanz F**, Regaño S, Vega A, Alvarez A. Needle-wire-guided breast tumor excision. *J Surg Oncol* 2006; **94**: 165-166 [PMID: 16847825]
- 20 **Ballester M**, Berry M, Couturaud B, Reyat F, Salmon RJ, Fitoussi AD. Lateral mammoplasty reconstruction after surgery for breast cancer. *Br J Surg* 2009; **96**: 1141-1146 [PMID: 19787762 DOI: 10.1002/bjs.6696]
- 21 **Clough KB**, Oden S, Ihrat T, Massey E, Nos C, Sarfati I. Level 2 oncoplastic surgery for lower inner quadrant breast cancers: the LIQ-V mammoplasty. *Ann Surg Oncol* 2013; **20**: 3847-3854 [PMID: 23838910 DOI: 10.1245/s10434-013-3085-4]
- 22 **Fitoussi AD**, Berry MG, Famà F, Falcou MC, Curnier A, Couturaud B, Reyat F, Salmon RJ. Oncoplastic breast surgery for cancer: analysis of 540 consecutive cases [outcomes article]. *Plast Reconstr Surg* 2010; **125**: 454-462 [PMID: 20124831 DOI: 10.1097/PRS.0b013e3181c82d3e]
- 23 **Gulcelik MA**, Dogan L, Camlibel M, Karaman N, Kuru B, Alagol H, Ozaslan C. Early complications of a reduction mammoplasty technique in the treatment of macromastia with or without breast cancer. *Clin Breast Cancer* 2011; **11**: 395-399 [PMID: 21993009 DOI: 10.1016/j.clbc.2011.08.001]
- 24 **Iwuchukwu OC**, Harvey JR, Dordea M, Critchley AC, Drew PJ. The role of oncoplastic therapeutic mammoplasty in breast cancer surgery--a review. *Surg Oncol* 2012; **21**: 133-141 [PMID: 21411311 DOI: 10.1016/j.suronc.2011.01.002]
- 25 **McIntosh J**, O'Donoghue JM. Therapeutic mammoplasty--a systematic review of the evidence. *Eur J Surg Oncol* 2012; **38**: 196-202 [PMID: 22206704]
- 26 **Kaviani A**, Safavi A, Mirsharifi R. Immediate and delayed contralateral symmetrization in oncoplastic breast reduction: patients' choices and technique formulation. *Plast Reconstr Surg Glob Open* 2015; **3**: e286 [PMID: 25674367 DOI: 10.1197/GOX.0000000000000246]
- 27 **Andree C**, Farhadi J, Goossens D, Masia J, Sarfati I, Germann G, Macmillan RD, Scheffan M, Van Not HP, Catanuto G, Nava MB. A position statement on optimizing the role of oncoplastic breast surgery. *Eplasty* 2012; **12**: e40 [PMID: 22977675]
- 28 **Carty MJ**, Chan R, Huckman R, Snow D, Orgill DP. A detailed analysis of the reduction mammoplasty learning curve: a statistical process model for approaching surgical performance improvement. *Plast Reconstr Surg* 2009; **124**: 706-714 [PMID: 19730289 DOI: 10.1097/PRS.0b013e3181b17a13]
- 29 **Hernanz F**, Santos R. Incorporating the surgical treatment of symptomatic macromastia into a Breast Cancer Unit: could this be a useful management policy? *Breast* 2011; **20**: 190-191 [PMID: 21050760 DOI: 10.16/j.breast.2010.10.006]
- 30 **Hernanz F**, Santos R, Arruabarrena A, Schneider J, Gómez Fleitas M. Treatment of symptomatic macromastia in a breast unit. *World J Surg Oncol* 2010; **8**: 93 [PMID: 21040550 DOI: 10.1186/1477-7819-8-93]

P- Reviewer: Wang SK S- Editor: Ji FF

L- Editor: A E- Editor: Liu SQ





Published by **Baishideng Publishing Group Inc**

8226 Regency Drive, Pleasanton, CA 94588, USA

Telephone: +1-925-223-8242

Fax: +1-925-223-8243

E-mail: bpgoffice@wjgnet.com

Help Desk: <http://www.wjgnet.com/esps/helpdesk.aspx>

<http://www.wjgnet.com>

