

## Boerhaave's syndrome during bowel preparation with polyethylene glycol in a patient with postpolypectomy bleeding

Ji-Youn Yu, Seung-Kyoung Kim, Eun-Chul Jang, Ju-Ok Yeom, Sun-Young Kim, Young-Seok Cho

Ji-Youn Yu, Seung-Kyoung Kim, Eun-Chul Jang, Ju-Ok Yeom, Sun-Young Kim, Young-Seok Cho, Division of Gastroenterology, Department of Internal Medicine, Uijeongbu St. Hospital, the Catholic University of Korea College of Medicine, Uijeongbu 480-717, South Korea

Author contributions: Yu JY, Kim SK, Jang EC, Yeom JO, Kim SY and Cho YS contributed to the manuscript writing and revision.

Correspondence to: Young-Seok Cho, MD, PhD, Division of Gastroenterology, Department of Internal Medicine, Uijeongbu St. Mary's Hospital, the Catholic University of Korea College of Medicine, 65-1 Geumo-dong, Uijeongbu 480-717, South Korea. [yscho@catholic.ac.kr](mailto:yscho@catholic.ac.kr)

Telephone: +82-31-8203658 Fax: +82-31-8472719

Received: January 02, 2013 Revised: April 14, 2013

Accepted: April 18, 2013

Published online: May 16, 2013

### Abstract

Boerhaave's syndrome is spontaneous rupture of the esophagus, a rare condition with high mortality that occurs most often after forceful vomiting. Polyethylene glycol (PEG) solution is the most common preparation used for colonoscopy. Since large volumes have to be ingested, PEG may induce severe vomiting or retching. However, Boerhaave's syndrome has rarely been reported as a potential problem related to PEG solution. We report a case of spontaneous esophageal rupture due to violent vomiting during bowel preparation with PEG solution in a patient with postpolypectomy bleeding.

© 2013 Baishideng. All rights reserved.

**Key words:** Esophageal perforation; Colonoscopy; Polyethylene glycols

**Core tip:** A bowel preparation with polyethylene glycol electrolyte solution should be used with care in patients

with postpolypectomy bleeding.

Yu JY, Kim SK, Jang EC, Yeom JO, Kim SY, Cho YS. Boerhaave's syndrome during bowel preparation with polyethylene glycol in a patient with postpolypectomy bleeding. *World J Gastrointest Endosc* 2013; 5(5): 270-272 Available from: URL: <http://www.wjgnet.com/1948-5190/full/v5/i5/270.htm> DOI: <http://dx.doi.org/10.4253/wjge.v5.i5.270>

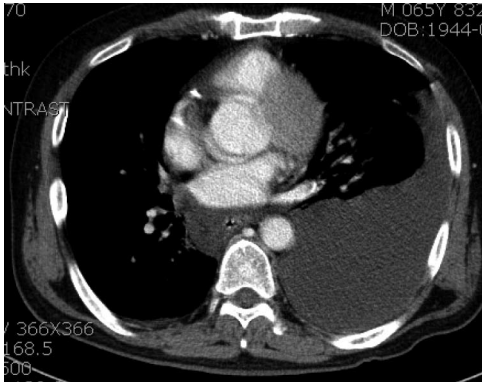
### INTRODUCTION

Boerhaave's syndrome is a form of barogenic rupture caused by a sudden post-emetic rise in the intraluminal pressure in the distal esophagus<sup>[1]</sup>. Esophageal perforation has high mortality, which increases to 40%-60% when treatment is delayed beyond 48 h, leading to mediastinal sepsis and multisystem organ failure<sup>[2]</sup>.

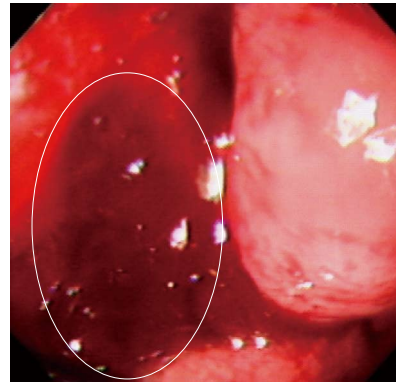
Electrolyte solution with sodium sulfate as the predominant salt and polyethylene glycol (PEG) was developed as an additional osmotic agent in 1980<sup>[3]</sup>. Since PEG-electrolyte lavage solutions were shown to be safe, well-tolerated, and highly effective in patients with renal failure or congestive heart disease, this became the most common method of preparation for colonoscopy<sup>[4]</sup>. The main disadvantage of PEG electrolyte solution is that large volumes have to be ingested. In addition, PEG electrolyte solution is poorly tolerated by some patients and may induce severe vomiting or retching<sup>[5]</sup>. Some cases of Mallory-Weiss syndrome have been reported following the ingestion of PEG-electrolyte solutions<sup>[6]</sup>, but only a few cases of colonoscopy-related esophageal perforation<sup>[7-11]</sup>.

### CASE REPORT

A 61-year-old man underwent a screening colonoscopy.



**Figure 1** Chest computed tomography shows a left pleural effusion and peri-esophageal fluid collection.



**Figure 2** Upper endoscopy shows a 15 mm × 12 mm perforation with stigmata of recent bleeding distal to the Z-line on the left side of the esophagus.

He had been healthy without specific complaints and no significant past medical or family history. The colonoscopy revealed nine small (< 10 mm) sessile polyps from the ascending colon to the descending colon and a 16-mm lateral spreading tumor (LST) in the sigmoid colon. The polyps were resected by hot biopsy for the smaller polyps (< 5 mm), conventional snare polypectomy, or endoscopic mucosal resection for the LST. Hemoclips were applied to the postpolypectomy wound to prevent bleeding, except for the smaller polyps. There were no apparent complications after the colonoscopic polypectomy. Twenty-four hours later, the patient presented to the emergency room with hematochezia. After drinking 2 L of PEG electrolyte solution over a 2-h period for an urgent colonoscopy, the patient had several sudden attacks of vomiting associated with severe chest pain and dyspnea. A chest examination revealed decreased air entry in the lower left lung; there was no subcutaneous emphysema. Abdominal examination revealed tenderness in the epigastric region and right upper quadrant, but no guarding or rigidity. A chest X-ray showed a layered fluid collection in the left chest. Emergency computed tomography (CT) showed a left pleural effusion and peri-esophageal fluid collection (Figure 1), but the esophagus was not clearly identified and no free air or fluid was seen in the abdomen. A left chest drain was inserted and 800 mL of blood tinged fluid were drained. An emergent upper endoscopy revealed a 15 mm × 12 mm perforation with stigmata of recent bleeding distal to the Z-line on the left side of the esophagus, but the perforation could not be clearly demarcated due to blood (Figure 2). Therefore, we diagnosed the patient with Boerhaave's syndrome that developed during bowel preparation using PEG electrolyte solution. The patient took immediate surgical intervention where the primary repair of a ruptured esophagus was reinforced with a pedicled flap of the eighth intercostal muscle. Further evaluation for hematochezia was not performed because it was stopped spontaneously. The patient made an uneventful recovery following surgical management and was discharged soon after without complications, having made a complete recovery.

## DISCUSSION

Esophageal perforation is uncommon condition with a high mortality rate. The causes include endoscopic instrumentation, trauma, swallowed foreign bodies, and Boerhaave's syndrome, which is the most serious form of esophageal perforation<sup>[2]</sup>. Boerhaave's syndrome is often misdiagnosed as acute pancreatitis, myocardial infarction, and peptic ulcer because of its rarity and nonspecific symptoms<sup>[1]</sup>. A delay in diagnosis leads to more extensive contamination and inflammation of the mediastinum and results in a poor outcome. The rupture in Boerhaave's syndrome is usually in the left lateral wall of the esophagus, just superior to the diaphragm<sup>[12]</sup>. This might be due to an anatomic weakness at that point. Distal esophageal perforations, most prevalent in Boerhaave's syndrome, commonly show a left-sided pleural effusion and pneumomediastinum on the chest X-ray<sup>[13]</sup>. The presence and magnitude of these findings are usually related to the length of time since the perforation. The diagnosis can be made earlier and more accurately with additional radiological examinations, such as CT. Since our patient had severe chest pain immediately after violent vomiting in the emergency room, we had a heightened index of suspicion for esophageal perforation and made the diagnosis without delay. The management is still controversial because the treatment modalities range from conservative measures to extensive surgery<sup>[12]</sup>. If the perforation is detected in less than 24 h, primary repair and wide irrigation of the mediastinum are usually possible<sup>[14]</sup>. However, when the treatment is delayed beyond 48 h, the treatment is not clear. Recently, endoscopic treatment with stenting allows for non-operative management in selected patients, even if data on endoscopic management of perforations in benign disease are limited<sup>[15]</sup>. The vacuum endo-sponge therapy, that is a kind of interventional therapy successfully for the treatment of anastomotic insufficiencies in upper gastrointestinal surgery, can be used for small perforation<sup>[11]</sup>. After the prompt diagnosis in our case, operative management was chosen because endoscopy showed a relatively large perforation. Moreover, the patient had

intractable chest pain and hypotension despite the chest tube drainage.

Nausea is a common adverse effect of the use of PEG electrolyte solution and vomiting is sometimes seen because of the large volume needed to clean the colon. Other adverse effects include urticarial reaction, anaphylaxis, hypothermia, obstruction-perforation, and cardiac arrhythmia<sup>[5]</sup>. Some cases of Mallory-Weiss syndrome after vomiting due to bowel preparation have been reported<sup>[6]</sup>. However, only five cases of esophageal perforation related to the use of the PEG electrolyte solutions have been described in the English literature<sup>[7-11]</sup>. Among these cases, the only reported death was of a patient who had been managed conservatively. This complication could have been avoided if the PEG-electrolyte solution had been given *via* a nasogastric tube before the colonoscopy. However, when administering the solution *via* a nasogastric tube, life-threatening complications such as aspiration and pulmonary edema after vomiting have been described<sup>[16]</sup>. In addition, anti-emetic medication during the preparation process can prevent this complication in patients who have a tendency to nausea and vomiting<sup>[11]</sup>.

Urgent colonoscopy for acute lower gastrointestinal bleeding usually requires a PEG electrolyte solution purge, either orally or by nasogastric tube to rid the colon of clots, stool, and blood<sup>[17]</sup>. However, a recent study showed that a bowel preparation for an urgent colonoscopy is not always needed in postpolypectomy patients<sup>[18]</sup>. Therefore, a bowel preparation with PEG electrolyte solution should be used with care in patients with post-polypectomy bleeding.

## REFERENCES

- 1 Bjerke HS. Boerhaave's syndrome and barogenic injuries of the esophagus. *Chest Surg Clin N Am* 1994; **4**: 819-825 [PMID: 7859012]
- 2 Jones WG, Ginsberg RJ. Esophageal perforation: a continuing challenge. *Ann Thorac Surg* 1992; **53**: 534-543 [PMID: 1489367 DOI: 10.1016/0003-4975(92)90294-E]
- 3 Davis GR, Santa Ana CA, Morawski SG, Fordtran JS. Development of a lavage solution associated with minimal water and electrolyte absorption or secretion. *Gastroenterology* 1980; **78**: 991-995 [PMID: 7380204]
- 4 DiPalma JA, Brady CE, Stewart DL, Karlin DA, McKinney MK, Clement DJ, Coleman TW, Pierson WP. Comparison of colon cleansing methods in preparation for colonoscopy. *Gastroenterology* 1984; **86**: 856-860 [PMID: 6706069]
- 5 Toledo TK, DiPalma JA. Review article: colon cleansing preparation for gastrointestinal procedures. *Aliment Pharmacol Ther* 2001; **15**: 605-611 [PMID: 11328253 DOI: 10.1046/j.1365-2036.2001.00966.x]
- 6 Santoro MJ, Chen YK, Collen MJ. Polyethylene glycol electrolyte lavage solution-induced Mallory-Weiss tears. *Am J Gastroenterol* 1993; **88**: 1292-1293 [PMID: 8338109]
- 7 Aljanabi I, Johnston P, Stone G. Spontaneous rupture of the oesophagus after bowel preparation with polyethylene glycol. *ANZ J Surg* 2004; **74**: 176-177 [PMID: 14996171 DOI: 10.1046/j.1445-1433.2003.02809.x]
- 8 Pham T, Porter T, Carroll G. A case report of Boerhaave's syndrome following colonoscopy preparation. *Med J Aust* 1993; **159**: 708 [PMID: 8232021]
- 9 Eisen GM, Jowell PS. Esophageal perforation after ingestion of colon lavage solution. *Am J Gastroenterol* 1995; **90**: 2074 [PMID: 7485041]
- 10 McBride MA, Vanagunas A. Esophageal perforation associated with polyethylene glycol electrolyte lavage solution. *Gastrointest Endosc* 1993; **39**: 856-857 [PMID: 8293924 DOI: 10.1016/S0016-5107(93)70290-4]
- 11 Emmanouilidis N, Jäger MD, Winkler M, Klempnauer J. Boerhaave syndrome as a complication of colonoscopy preparation: a case report. *J Med Case Rep* 2011; **5**: 544 [PMID: 22054124 DOI: 10.1186/1752-1947-5-544]
- 12 de Schipper JP, Pull ter Gunne AF, Oostvogel HJ, van Laarhoven CJ. Spontaneous rupture of the oesophagus: Boerhaave's syndrome in 2008. Literature review and treatment algorithm. *Dig Surg* 2009; **26**: 1-6 [PMID: 19145081 DOI: 10.1159/000191283]
- 13 Phelan HA, Brakenridge SC, Rutland TJ, Maltese C. Boerhaave syndrome presenting as massive hemothorax. *South Med J* 2009; **102**: 202-203 [PMID: 19139705 DOI: 10.1097/SMJ.0b013e318186be00]
- 14 Cho S, Jheon S, Ryu KM, Lee EB. Primary esophageal repair in Boerhaave's syndrome. *Dis Esophagus* 2008; **21**: 660-663 [PMID: 18459985 DOI: 10.1111/j.1442-2050.2008.00833.x]
- 15 Ghassemi KF, Rodriguez HJ, Vesga L, Stewart L, McQuaid KR, Shah JN. Endoscopic treatment of Boerhaave syndrome using a removable self-expandable plastic stent. *J Clin Gastroenterol* 2007; **41**: 863-864 [PMID: 17881934 DOI: 10.1097/01.mcg.0000225597.46943.06]
- 16 Marschall HU, Bartels F. Life-threatening complications of nasogastric administration of polyethylene glycol-electrolyte solutions (Golytely) for bowel cleansing. *Gastrointest Endosc* 1998; **47**: 408-410 [PMID: 9609437 DOI: 10.1016/S0016-5107(98)70229-9]
- 17 Elta GH. Urgent colonoscopy for acute lower-GI bleeding. *Gastrointest Endosc* 2004; **59**: 402-408 [PMID: 14997144 DOI: 10.1016/S0016-5107(03)02721-4]
- 18 Saito K, Inamori M, Sekino Y, Akimoto K, Suzuki K, Tomimoto A, Fujisawa N, Kubota K, Saito S, Koyama S, Nakajima A. Management of acute lower intestinal bleeding: what bowel preparation should be required for urgent colonoscopy? *Hepatogastroenterology* 2009; **56**: 1331-1334 [PMID: 19950786]

P-Reviewer Yoshida S S-Editor Huang XZ L-Editor A  
E-Editor Zhang DN

