

Subtrochanteric fractures after retrograde femoral nailing

Varatharaj Mounasamy, Sathya Mallu, Vishesh Khanna, Senthil Sambandam

Varatharaj Mounasamy, Sathya Mallu, Department of Orthopedics, Virginia Commonwealth University Health System, Richmond, VA 23298, United States

Vishesh Khanna, Senthil Sambandam, Department of Orthopedics, KG Hospital, Coimbatore 641018, Tamil Nadu, India

Author contributions: Mounasamy V, Mallu S, Khanna V and Sambandam S contributed equally to this work; Mounasamy V and Mallu S designed the research; Mounasamy V and Mallu S performed the research; Mounasamy V and Mallu S analysed the data; Mounasamy V, Khanna V and Sambandam S wrote the paper.

Conflict-of-interest statement: Drs. Varatharaj Mounasamy, Sathya Mallu, Vishesh Khanna and Senthil Nathan Sambandam, have not received fees for serving as a speaker, nor have they received research funding from any organization. There are no conflicts of interests.

Open-Access: This article is an open-access article which was selected by an in-house editor and fully peer-reviewed by external reviewers. It is distributed in accordance with the Creative Commons Attribution Non Commercial (CC BY-NC 4.0) license, which permits others to distribute, remix, adapt, build upon this work non-commercially, and license their derivative works on different terms, provided the original work is properly cited and the use is non-commercial. See: <http://creativecommons.org/licenses/by-nc/4.0/>

Correspondence to: Vishesh Khanna, DNB Orthopaedics, Department of Orthopedics, KG Hospital, Arts College Road, Coimbatore 641018, Tamil Nadu, India. visheshkhanna85@gmail.com
 Telephone: +91-981-1844647
 Fax: +91-422-2211212

Received: March 23, 2015
 Peer-review started: March 26, 2015
 First decision: June 3, 2015
 Revised: June 21, 2015
 Accepted: July 21, 2015
 Article in press: July 23, 2015
 Published online: October 18, 2015

Abstract

Secondary fractures around femoral nails placed for the management of hip fractures are well known. We report, two cases of a fracture of the femur at the interlocking screw site in the subtrochanteric area after retrograde femoral nailing of a femoral shaft fracture. Only a few reports in the existing literature have described these fractures. Two young men after sustaining a fall presented to us with pain, swelling and deformity in the upper thigh region. On enquiring, examining and radiographing them, peri-implant fractures of subtrochanteric nature through the distal interlocking screws were revealed in both patients who also had histories of previous falls for which retrograde intramedullary nailing was performed for their respective femora. Both patients were managed with similar surgical routines including removal of the existing hardware, open reduction and ace cephalomedullary antegrade nailing. The second case did show evidence of delayed healing and was additionally stabilized with cerclage wires. Both patients had uneventful postoperative outcomes and union was evident at the end of 6 mo postoperatively with a good range of motion at the hip and knee. Our report suggests that though seldom reported, peri-implant fractures around the subtrochanteric region can occur and pose a challenge to the treating orthopaedic surgeon. We suggest these be managed, after initial stabilization and resuscitation, by implant removal, open reduction and interlocking intramedullary antegrade nailing. Good results and progression to union can be expected in these patients by adhering to basic principles of osteosynthesis.

Key words: Peri-implant fracture; Retrograde femoral nail; Antegrade femoral nailing; Interlocking screw; Subtrochanteric fractures

© The Author(s) 2015. Published by Baishideng Publishing Group Inc. All rights reserved.

Core tip: The occurrence of peri-implant subtrochanteric

fractures in patients operated previously by retrograde nailing for femoral diaphyseal fractures has been rarely reported. This case report provides the description of two such cases with subtrochanteric peri-implant fractures. These challenges are best met, according to our experience, by implant removal, open reduction and interlocking antegrade nailing.

Mounasamy V, Mallu S, Khanna V, Sambandam S. Subtrochanteric fractures after retrograde femoral nailing. *World J Orthop* 2015; 6(9): 738-743 Available from: URL: <http://www.wjgnet.com/2218-5836/full/v6/i9/738.htm> DOI: <http://dx.doi.org/10.5312/wjo.v6.i9.738>

INTRODUCTION

Intramedullary nailing is the surgical treatment of choice in displaced diaphyseal femur fractures with excellent results reported in literature. Antegrade nailing either through the trochanter or the piriform fossa is the usual standard of treatment^[1]. Retrograde intramedullary nailing of the femur was first reported by Green^[2] in 1970. In the last two decades, a significant increase in the use of this technique has been witnessed in patients with difficult access to the proximal femur (obesity, bilateral femur fractures, ipsilateral pelvic fracture, hip fracture, tibia fracture and associated contralateral tibial plateau fractures which need internal fixation or staged external fixation). While knee pain and delay in union requiring dynamization have been reported with retrograde nailing, proclaimed benefits have included decreased blood loss and operative time and improved alignment when fixing distal femoral fractures^[3-9].

Complications associated with nailing include implant failure, angulation, shortening, malunion and nonunion of the fracture with associated migration of the nail. While fractures at the distal end of a short intramedullary nail used to fix hip fractures are well known, peri-implant fractures of the proximal femur at the far end of a retrograde nail placed for a femoral shaft fracture as in our report have been infrequently reported^[10-13]. We present a report of two patients sustaining a subtrochanteric fracture after retrograde femoral nailing.

CASE REPORT

Case 1

A 33-year-old male presented to the emergency room with history of pain in his back and the left hip after sustaining a fall during skydiving. In a similar skydiving accident in the past, he had sustained bilateral femur fractures in addition to a burst fracture of the third lumbar vertebra. He had been operated for the same with bilateral retrograde femoral nails, cannulated screw fixation in the right femur and internal fixation of the L3 burst fracture.

In the current episode, he had sustained a peri-implant fracture of the left femur in the subtrochanteric

region at the far end of the retrograde nail placed through the knee to manage his previous injury (Figure 1).

A computed tomography (CT) scan confirmed the fracture at the locking screw site. The fracture was through the distal of the two interlocking screw-containing holes at the subtrochanteric area. The patient elected operative intervention (Figure 2).

With the patient in a floppy lateral position on a bean bag under general anesthesia, we approached the knee through his previous midline incision and performed a medial parapatellar arthrotomy. The nail was identified and the interlocking screws at the lateral aspect of the femur were removed after connecting the jig to prevent rotation. The proximal screws were then removed through an anterior incision and the nail was extracted. The implants were intact on retrieval. The knee arthrotomy was closed in a routine manner after irrigation. The fracture site was exposed and reduced through a lateral incision over the proximal femur and a trochanteric entry Ace cephalomedullary nail was placed with two screws in the femoral neck and two distally at the knee in appropriate rotation.

He was advised toe-touch weight for 6 wk and then progressed to bear weight as tolerated with interval healing of the fracture. His fracture showed full union at six months postoperatively (Figure 3) and he had full range of movement of the hip and knee.

Case 2

A 45-year-old male alcoholic presented to the emergency room with history of pain in his right hip after a fall. He had a history of internal fixation of right femur with a retrograde nail and internal fixation of a left tibial plateau 4 mo prior to this fall after being involved in a motor vehicle accident.

He sustained, similar to the previous patient, a peri-implant fracture of the right femur in the subtrochanteric region at the far end of the retrograde nail placed through the knee to manage his previous injury (Figure 4). The implants appeared intact on imaging.

A CT scan confirmed the fracture at the locking screw site and delayed union of the previously treated femoral shaft fracture (Figure 5).

The patient opted for operative intervention. The fracture was found to extend through the distal of the two interlocking screw holes at the subtrochanteric area. The patient was positioned and under general anesthesia, the right knee was approached through the previous incision. After a medial parapatellar arthrotomy, the nail was identified and the distal and proximal interlocking screws removed. The implants were intact on retrieval. After the extraction of the nail, the wound was closed as per routine.

Through a lateral incision over the proximal femur, the fracture site was exposed, reduced and held with two cerclage wires. A trochanteric entry Ace cephalomedullary nail was placed with two screws in the femoral neck and two distally at the knee in a manner similar to the first case (Figure 6).

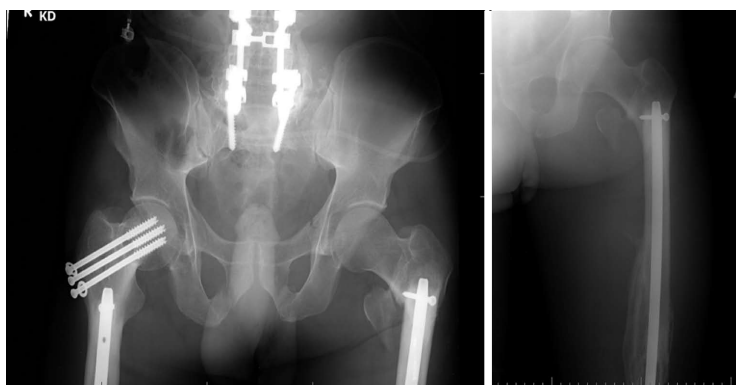


Figure 1 Anteroposterior and lateral radiographs of left femur showing peri-implant fracture involving the interlocking screw site in the subtrochanteric area.

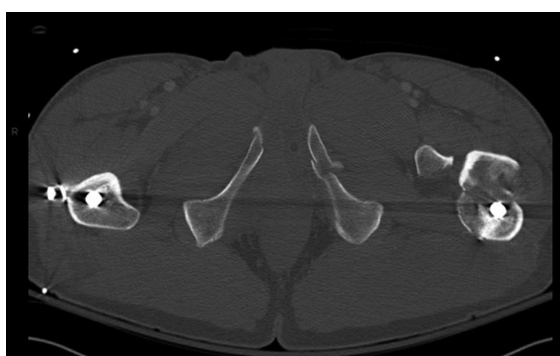


Figure 2 Axial computed tomography scan image showing the fracture at the screw insertion site.

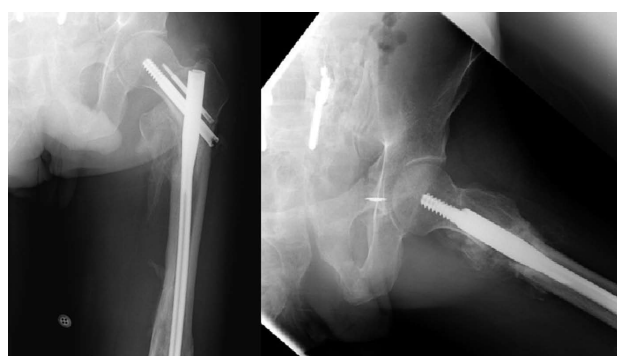

Figure 3 Anteroposterior and lateral radiographs six months after internal fixation of the peri-implant fracture.

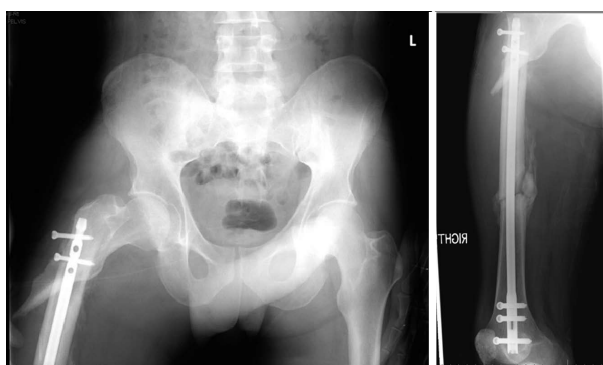

Figure 4 Anteroposterior and lateral radiographs of right femur showing peri-implant fracture involving the Interlocking screw site in the subtrochanteric area. Also seen is the femoral shaft fracture with interval healing.

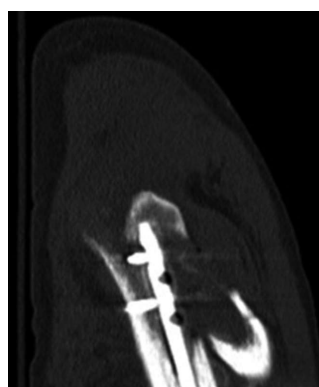


Figure 5 Sagittal computed tomography scan image showing the fracture at the screw insertion site.

Postoperative management was identical to the previous patient. During the last office visit at six months postoperatively, he was full weight bearing on his right lower extremity and had near full range of motion at the hip and knee. Radiographs showed a healed subtrochanteric as well as the shaft fracture with no loss of alignment (Figures 7 and 8).

DISCUSSION

After its first description nearly four and a half decades back, retrograde intramedullary nailing has been often

employed for femoral diaphyseal or supracondylar fractures associated with ipsilateral tibia and/or patella fractures. It is also a useful modality in diaphyseal fractures of femur associated with ipsilateral femoral neck fracture as well as acetabular fractures. In pregnancy, it proves advantageous over the antegrade nail by limiting radiation exposure to abdomen. In a polytrauma patient with multiple fractures and obese patients with bilateral femoral diaphyseal fractures, the retrograde nail negates the necessity of a fracture table or any special positions^[3-9]. At our center, we perform around 75 retrograde femoral nails per year.

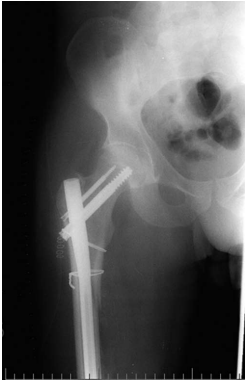

Figure 6 Anteroposterior radiograph of the pelvis post revision fixation.

In a prospective randomized controlled trial, Ostrum *et al*^[3] compared the results, function, and complications of antegrade and retrograde femoral nailing for femoral shaft fractures in one hundred consecutive patients and concluded that both groups yielded high union rates. Knee pain was common in both the groups while antegrade nailing patients complained of thigh pain. They also noted that antegrade nailed femurs healed faster and a few retrograde nailed patients needed dynamization to achieve union.

In a paper on proximal femoral fractures associated with ipsilateral shaft fractures managed by hip screws and reamed retrograde intramedullary nails, Ostrum *et al*^[4] reported union rates of 98% and 91.3% for the femoral neck and shaft fractures respectively. In a systematic review of literature, Papadokostakis *et al*^[14] analyzed retrograde nailing of 544 femoral shaft fractures and observed an overall union rate of 94.6% and a mean time to union of 3.2 mo. They reported that 24.5% patients had knee pain and 17.7% of patients needed reoperations for screw related issues or to achieve union. Though none of them had proximal implant related fractures, 7.4% patients had malunion and the infection rate was 1.1%.

Our second case did show evidence of delayed union following both surgeries. In a case-control study by Taitzman *et al*^[15], identified risk factors for nonunion after femoral nailing of diaphyseal femur fractures were open fractures, tobacco use and delayed weight bearing. Modalities of managing femoral nonunions following nailing have included exchange nailing, plating and augmentative locking plating. All of these have shown excellent results^[16-18]. In a recent retrospective cohort study, Swanson *et al*^[16] described various strategies of exchange nailing for femur nonunions with nail *in-situ* including larger nails (at least 2 mm larger in diameter), nails from a different manufacturer, static interlocking, correction of metabolic and endocrine disorders and secondary dynamization.

Koval *et al*^[19] reported that any drill hole that occupies 20% of the diameter weakens the bone by 40% and that 90% of fractures around fixation implants occur through a drill hole. Proximal-end fractures after retrograde femoral nailing have been reported in the

Table 1 Comparison with previous case reports

Study	No. of cases	Index implant	Revision implant	Outcome
Leibner <i>et al</i> ^[12]	1	Supracondylar nail		
O'Mara <i>et al</i> ^[13]	1	Retrograde nail	95° blade plate	Good
Present	2	Retrograde nail	Antegrade nail	Good

past^[12,13] (Table 1). Leibner *et al*^[12] reported one case of a femoral fracture at the proximal end of an intramedullary supracondylar nail and concluded that it may be due to the proximal end acting as a stress riser and cortical holes drilled for the interlocking screw placement increasing the risk for failure. In their case report, the patient had a supracondylar nail placed for a distal third femur fracture and secondary fracture occurred in the diaphysis of the femur^[12]. In another case report by O'Mara *et al*^[13], a 61-year-old lady presented a month after sustaining a peritrochanteric fracture at the tip of a retrograde femoral nail 4 mo postoperatively with evidence of incomplete bridging callus at the index fracture shaft of the femur. She was managed by fracture reduction with traction and fixation with a 95° angled blade plate. The retrograde nail was left in situ. The authors reported a good outcome 1.5 years postoperatively.

Norris *et al*^[10] reported secondary fracture around femoral nails used to treat hip fractures and noted a slight decrease in the same when longer nails were used in comparison to short nails. The overall incidence was around 1.7%. Biaxial fixation compared to uniaxial fixation had a significantly lower risk of fracture. Further, emerging design changes have decreased the incidence of secondary fractures.

Iatrogenic femoral neck fractures during insertion of antegrade nails have been reported. These may be due to wrong insertion site, forceful insertion, multiple entry points, excessive lateral entry point and oblique insertion of the nail^[20,21]. Parker *et al*^[22] identified several factors responsible for peri-implant fractures including traumatic, stress, iatrogenic, avascular necrosis, implant failure and pathologic causes. These fractures were common in the elderly, osteopenic population. To avoid fatigue failure, multiple and larger diameter screws were added^[23].

Mounasamy *et al*^[24] reported two cases of a peri-implant fracture through distal interlocking screw site after fresh trauma, in patients who had previous intramedullary implant.

We are unsure why these fractures occurred in our patients. Metabolic and osteoporotic parameters of both patients were within normal limits. A probable explanation could be the presence of stress risers at the proximal end of the nail and screw holes. We preferred antegrade nailing with cephalomedullary screw fixation to manage both these secondary fractures in view of the location of both these fractures at the subtrochanteric level. Additionally, the second patient had delayed union

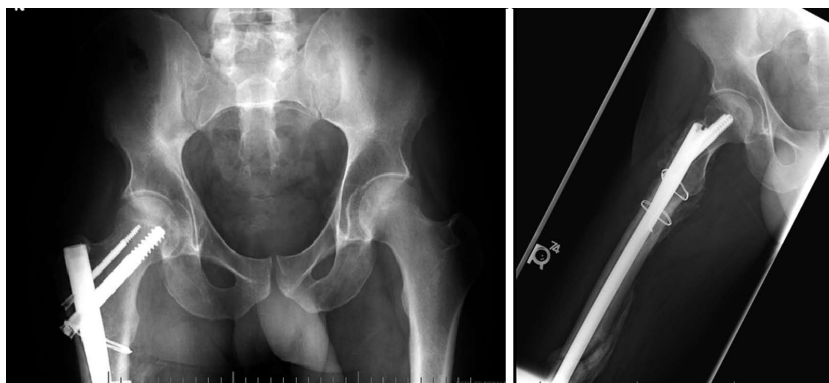

Figure 7 Anteroposterior and lateral radiographs six months after internal fixation of the peri-implant fracture.

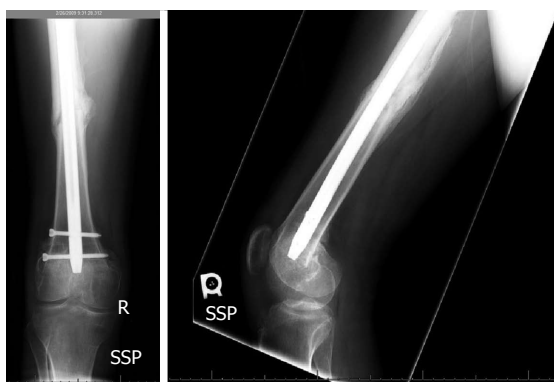

Figure 8 Anteroposterior and lateral radiographs showing healed diaphyseal femur fracture.

of his previously treated femur fracture, which was addressed with reaming and a larger diameter nail.

Other treatment options to manage these fractures would be the use of proximal femoral locking plates, angled blade plates or the dynamic condylar screw plate device. Antegrade intramedullary nailing is the treatment of choice for subtrochanteric femur fractures^[25]. The proximal fragment in a subtrochanteric fracture is displaced in flexion, abduction and external rotation. Afsari *et al*^[26] have reported a high rate of union of subtrochanteric femur fractures treated with open clamp reduction and intramedullary nailing. They also reported that the subtrochanteric region has cortical bone with less vascularity and healing potential as compared to the intertrochanteric region.

To our knowledge, there is no consensus in the current literature regarding fracture at the far end of the retrograde nail placed to treat a femoral shaft fracture. We suggest the removal of the retrograde nail, if the fracture has healed anatomic reduction of subtrochanteric fracture and fixation with antegrade intramedullary nail.

COMMENTS

Case characteristics

Two patients presented with pain, swelling and deformity of the upper thigh following an injury.

Clinical diagnosis

Fracture proximal one third of the femur.

Differential diagnosis

Subtrochanteric fracture, fracture shaft of femur, fracture neck of femur, intertrochanteric fracture femur.

Imaging diagnosis

Case 1: Peri-implant fracture of the left femur in the subtrochanteric region at the far end of the retrograde nail confirmed by a computed tomography (CT) scan; Case 2: Peri-implant fracture of the right femur in the subtrochanteric region at the far end of the retrograde nail and delayed union of the previously treated femoral shaft fracture confirmed by a CT scan.

Treatment

Case 1: Implant removal, open reduction and interlocking antegrade femoral nailing; Case 2: Implant removal, open reduction, cerclage wiring and interlocking antegrade femoral nailing.

Experiences and lessons

This case report of two patients not only represents an unusual pattern of peri-implant femoral shaft fracture, but also confirms the excellent outcome following the management of these cases by antegrade nailing.

Peer-review

The authors have performed a good study, the manuscript is interesting.

REFERENCES

- 1 **Brumback RJ**, Uwagie-Ero S, Lakatos RP, Poka A, Bathon GH, Burgess AR. Intramedullary nailing of femoral shaft fractures. Part II: Fracture-healing with static interlocking fixation. *J Bone Joint Surg Am* 1988; **70**: 1453-1462 [PMID: 3198669]
- 2 **Green S**. Distal intramedullary fixation of supracondylar fractures of femur. *Techniques Orthop* 1988; **3**: 71-76 [DOI: 10.1097/00013611-198810000-00012]
- 3 **Ostrum RF**, Agarwal A, Lakatos R, Poka A. Prospective comparison of retrograde and antegrade femoral intramedullary nailing. *J Orthop Trauma* 2000; **14**: 496-501 [PMID: 11083612 DOI: 10.1097/00005131-200009000-00006]
- 4 **Ostrum RF**, Tornetta P, Watson JT, Christiano A, Vafek E. Ipsilateral proximal femur and shaft fractures treated with hip screws and a reamed retrograde intramedullary nail. *Clin Orthop Relat Res* 2014; **472**: 2751-2758 [PMID: 24014269 DOI: 10.1007/s11999-013-3271-5]
- 5 **Ricci WM**, Gallagher B, Haidukewych GJ. Intramedullary nailing of femoral shaft fractures: current concepts. *J Am Acad Orthop Surg* 2009; **17**: 296-305 [PMID: 19411641]
- 6 **Ostrum RF**. Treatment of floating knee injuries through a single

- percutaneous approach. *Clin Orthop Relat Res* 2000; **(375)**: 43-50 [PMID: 10853152 DOI: 10.1097/00003086-200006000-00006]
- 7 **Gregory P**, DiCicco J, Karpik K, DiPasquale T, Herscovici D, Sanders R. Ipsilateral fractures of the femur and tibia: treatment with retrograde femoral nailing and unreamed tibial nailing. *J Orthop Trauma* 1996; **10**: 309-316 [PMID: 8814571 DOI: 10.1097/00005131-199607000-00004]
 - 8 **Ricci WM**, Bellabarba C, Evanoff B, Herscovici D, DiPasquale T, Sanders R. Retrograde versus antegrade nailing of femoral shaft fractures. *J Orthop Trauma* 2001; **15**: 161-169 [PMID: 11265005 DOI: 10.1097/00005131-200102000-00003]
 - 9 **Sanders R**, Koval KJ, DiPasquale T, Helfet DL, Frankle M. Retrograde reamed femoral nailing. *J Orthop Trauma* 1993; **7**: 293-302 [PMID: 8377037 DOI: 10.1097/00005131-199308000-00001]
 - 10 **Norris R**, Bhattacharjee D, Parker MJ. Occurrence of secondary fracture around intramedullary nails used for trochanteric hip fractures: a systematic review of 13,568 patients. *Injury* 2012; **43**: 706-711 [PMID: 22142841 DOI: 10.1016/j.injury.2011.10.027]
 - 11 **Williams J**, Gibbons M, Trundle H, Murray D, Worlock P. Complications of nailing in closed tibial fractures. *J Orthop Trauma* 1995; **9**: 476-481 [PMID: 8592260 DOI: 10.1097/00005131-199509060-00004]
 - 12 **Leibner ED**, Mosheiff R, Safran O, Abu-Snienh K, Liebergall M. Femoral fracture at the proximal end of an intramedullary supracondylar nail: a case report. *Am J Orthop (Belle Mead NJ)* 1999; **28**: 53-55 [PMID: 10048361]
 - 13 **O'Mara T**, Barei DP, Taitzman LA, Vallier H, Chapman JR. Pertrochanteric femur fracture at the proximal end of a retrograde intramedullary nail-a case report. *Injury Extra* 2005; **36**: 271-276 [DOI: 10.1016/j.injury.2004.12.048]
 - 14 **Papadokostakis G**, Papakostidis C, Dimitriou R, Giannoudis PV. The role and efficacy of retrograding nailing for the treatment of diaphyseal and distal femoral fractures: a systematic review of the literature. *Injury* 2005; **36**: 813-822 [PMID: 15949481 DOI: 10.1016/j.injury.2004.11.029]
 - 15 **Taitzman LA**, Lynch JR, Agel J, Barei DP, Nork SE. Risk factors for femoral nonunion after femoral shaft fracture. *J Trauma* 2009; **67**: 1389-1392 [PMID: 19704386 DOI: 10.1097/TA.0b013e318182afd0]
 - 16 **Swanson EA**, Garrard EC, Bernstein DT, O'Connor DP, Brinker MR. Results of a systematic approach to exchange nailing for the treatment of aseptic femoral nonunions. *J Orthop Trauma* 2015; **29**: 21-27 [PMID: 24978947 DOI: 10.1097/BOT.0000000000000166]
 - 17 **Chen SB**, Zhang CQ, Jin DX, Cheng XG, Sheng JG, Zeng BF. Treatment of aseptic nonunion after intramedullary nailing fixation with locking plate. *Orthop Surg* 2009; **1**: 258-263 [PMID: 22009872 DOI: 10.1111/j.1757-7861.2009.00040.x]
 - 18 **Ye J**, Zheng Q. Augmentative locking compression plate fixation for the management of long bone nonunion after intramedullary nailing. *Arch Orthop Trauma Surg* 2012; **132**: 937-940 [PMID: 22395822 DOI: 10.1007/s00402-012-1497-4]
 - 19 **Koval KJ**, Frankel VH, Kummer F, Green S. Complications of fracture fixation devices. In: Epps CH, ed. *Complications in Orthopaedic Surgery*. 3rd ed. Philadelphia, Pa: JB Lippincott, 1994: 131-154
 - 20 **Khan FA**, Ikram MA, Badr AA, al-Khawashki H. Femoral neck fracture: a complication of femoral nailing. *Injury* 1995; **26**: 319-321 [PMID: 7649647 DOI: 10.1016/0020-1383(95)00049-F]
 - 21 **Christie J**, Court-Brown C. Femoral neck fracture during closed medullary nailing: brief report. *J Bone Joint Surg Br* 1988; **70**: 670 [PMID: 3403626]
 - 22 **Parker MJ**, Handoll HH. Gamma and other cephalocondyltic intramedullary nails versus extramedullary implants for extra capsular hip fractures in adults. *Cochrane Database Syst Rev* 2010; **8**: CD000093
 - 23 **Griffin LV**, Harris RM, Zubak JJ. Fatigue strength of common tibial intramedullary nail distal locking screws. *J Orthop Surg Res* 2009; **4**: 11 [PMID: 19371438 DOI: 10.1186/1749-799X-4-11]
 - 24 **Mounasamy V**, Desai P. Peri-implant fracture of the distal tibia after intra-medullary nailing of a tibial fracture: a report of two cases. *Eur J Orthop Surg Traumatol* 2013; **23** Suppl 2: S279-S283 [PMID: 23412198]
 - 25 **DiCicco JD**, Jenkins M, Ostrum RF. Retrograde nailing for subtrochanteric femur fractures. *Am J Orthop (Belle Mead NJ)* 2000; **29**: 4-8 [PMID: 11011773]
 - 26 **Afsari A**, Liporace F, Lindvall E, Infante A, Sagi HC, Haidukewych GJ. Clamp-assisted reduction of high subtrochanteric fractures of the femur. *J Bone Joint Surg Am* 2009; **91**: 1913-1918 [PMID: 19651949 DOI: 10.2106/JBJS.H.0156]

P- Reviewer: Angelini A, Franklyn MJ, Maheshwari AV, Seijas R

S- Editor: Tian YL **L- Editor:** A **E- Editor:** Liu SQ





Published by **Baishideng Publishing Group Inc**

8226 Regency Drive, Pleasanton, CA 94588, USA

Telephone: +1-925-223-8242

Fax: +1-925-223-8243

E-mail: bpgoffice@wjgnet.com

Help Desk: <http://www.wjgnet.com/esps/helpdesk.aspx>

<http://www.wjgnet.com>

