

## Metachronous intracystic and intraductal papillary neoplasms of the biliary tree

Hirohide Sato, Yasunori Sato, Kenichi Harada, Motoko Sasaki, Katsuyasu Hirano, Yasuni Nakanuma

Hirohide Sato, Yasunori Sato, Kenichi Harada, Motoko Sasaki, Yasuni Nakanuma, Department of Human Pathology, Kanazawa University Graduate School of Medicine, Kanazawa 920-8640, Japan

Katsuyasu Hirano, Department of Surgery, Wajima Hospital, Wajima, Ishikawa 928-8585, Japan

Author contributions: Sato H, Harada K, and Sasaki M contributed to pathological diagnosis of this case; Sato Y contributed to preparation of the manuscript; Hirano K attended to the patient; Nakanuma Y wrote the manuscript.

Correspondence to: Yasuni Nakanuma, MD, Professor, Department of Human Pathology, Kanazawa University Graduate School of Medicine, 13-1 Takara-machi, Kanazawa 920-8640, Japan. [nakanuma@staff.kanazawa-u.ac.jp](mailto:nakanuma@staff.kanazawa-u.ac.jp)

Telephone: +81-76-2652197 Fax: +81-76-2344229

Received: January 9, 2013 Revised: April 26, 2013

Accepted: May 17, 2013

Published online: September 28, 2013

lesions within the lumen of the biliary tree including the gallbladder, papilla of Vater, and pancreatic duct have been proposed collectively as a preinvasive neoplastic lesion. The patient reported here was an interesting case of intraluminal papillary neoplasm involving the gallbladder and metachronously the extrahepatic bile duct. This letter to the editor encourages clinicians to detect more of such neoplastic lesions.

Sato H, Sato Y, Harada K, Sasaki M, Hirano K, Nakanuma Y. Metachronous intracystic and intraductal papillary neoplasms of the biliary tree. *World J Gastroenterol* 2013; 19(36): 6125-6126  
Available from: URL: <http://www.wjgnet.com/1007-9327/full/v19/i36/6125.htm> DOI: <http://dx.doi.org/10.3748/wjg.v19.i36.6125>

### Abstract

A 77-year-old woman complained of epigastralgia, and a tumor (5 cm in diameter) of the gallbladder neck was detected by image analysis. Following cholecystectomy, the tumor was pathologically diagnosed as intraductal papillary neoplasm (IPN), gastric type, with associated invasive carcinoma. About 10 mo later, intraluminal multiple masses (3 foci, up to 1.8 cm) were noted in the extrahepatic bile duct, and the resected specimen showed that all tumors had similar gross and microscopic features as seen in gallbladder IPN without invasion, and they were synchronous multiple lesions. This case showed a papillary tumor of the gallbladder of gastric phenotype, and confirmed that the gallbladder is a target of IPN in addition to the bile ducts.

© 2013 Baishideng. All rights reserved.

**Key words:** Intraductal papillary neoplasm; Intracystic papillary neoplasm; Gastric type; Metachronous occurrence; Synchronous occurrence

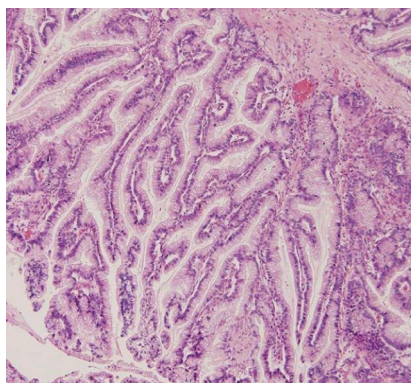
**Core tip:** Recently, the papillary or tumoral neoplastic

### TO THE EDITOR

The World Health Organization (WHO) Classification of Tumours of the Digestive System (2010) recognizes intraductal papillary neoplasms of the bile duct (IPNBs) as a precancerous entity of cholangiocarcinoma<sup>[1,2]</sup>. Before the recognition by WHO, this entity was called by various and many different names, such as biliary papilloma and papillomatosis, and papillary adenocarcinoma<sup>[2-4]</sup>. IPNBs are occasionally multicentric along the intrahepatic and extrahepatic bile duct, synchronously and metachronously.

Interestingly, IPNB shares many features with intraductal papillary mucinous neoplasms of the pancreas (IPMN-Ps). For example, four phenotypes of epithelium are recognized in IPNB as well as IPMN-P<sup>[1,5,6]</sup>: pancreatobiliary, intestinal, oncocytic, and gastric types. Intracystic papillary neoplasm (IPN) of the gallbladder was newly described in addition to papillary adenomas in the 2010 WHO classification.

We have recently experienced a case of IPN of the gallbladder followed by metachronous IPNBs of the extrahepatic bile duct. A 77-year old woman complained of epigastralgia, and a tumor of the gallbladder neck was



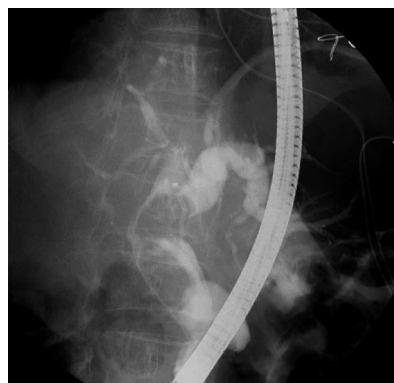
**Figure 1** Cauliflower tumor of the gallbladder shows papillary neoplasm composed of columnar epithelium with fine fibrovascular core, resembling gastric foveola (hematoxylin and eosin, x 100).

detected by computed tomography (CT) and magnetic resonance imaging (MRI). By cholecystectomy, a papillary, cauliflower-like tumor (5 cm × 4.8 cm) growing intraluminally was found at the gallbladder neck, and the remaining gallbladder was distended. Most of the tumor showed a well-differentiated papillary neoplasm composed of columnar epithelium with supranuclear mucin, resembling gastric mucosa, particularly gastric foveola, covering fine vasculo-fibrous cores (Figure 1), and showed moderate- to high-grade intraepithelial neoplasia. There was focal invasion of moderately differentiated tubular adenocarcinoma in the gallbladder wall. There was no metastasis, and the gallbladder mucosa, except for the tumor, did not show dysplastic or metaplastic changes. The tumor was diagnosed as IPN of the gallbladder with associated invasive carcinoma.

About 10 mo later, intraluminal multiple masses of the extrahepatic bile duct and secondary dilatation of the intra/extrahepatic bile ducts were demonstrated by CT, MRI and endoscopic retrograde cholangiography (Figure 2). The affected extrahepatic bile duct was surgically resected. The resected bile duct was dilated and filled with three separate brown papillary masses (1.8 cm × 1.4 cm, 1.5 cm × 1.5 cm, and 1.2 cm × 1.1 cm). There was no mucin within the resected bile ducts. These extrahepatic tumors commonly showed similar gross and microscopic features as seen in gallbladder IPN, but no invasion. There were no significant pathological changes in the background of the extrahepatic bile ducts. There was no continuity between the three lesions and they were regarded as synchronous multiple lesions.

Immunohistochemically, MUC5AC and MUC6 were diffusely positive, whereas MUC2-positive cells were scattered in these IPNs, and MUC1 was not observed in any of the four IPNs of the gallbladder and bile ducts. These IPNs were regarded as gastric type.

Similar to IPNB, IPN of the gallbladder may present with a pancreatobiliary or intestinal phenotype<sup>[2,3]</sup>. Distin-



**Figure 2** Intraluminal masses of the extrahepatic bile ducts and dilatation of extrahepatic bile duct shown by endoscopic retrograde cholangiography.

guishing IPN from papillary adenomas of the gallbladder may be controversial. The vast majority of IPNs of the gallbladder have a biliary phenotype, whereas papillary adenomas exhibit an intestinal or gastric phenotype. This case showed a papillary tumor of the gallbladder of gastric phenotype, and confirmed that the gallbladder is a target of IPN in addition to the bile ducts.

## REFERENCES

- Zen Y**, Fujii T, Itatsu K, Nakamura K, Minato H, Kasashima S, Kurumaya H, Katayanagi K, Kawashima A, Masuda S, Niwa H, Mitsui T, Asada Y, Miura S, Ohta T, Nakanuma Y. Biliary papillary tumors share pathological features with intraductal papillary mucinous neoplasm of the pancreas. *Hepatology* 2006; **44**: 1333-1343 [PMID: 17058219 DOI: 10.1002/hep.21387]
- Nakanuma Y**, Curado MP, Franceschi S, Gores G, Paradis V, Srija B, Tsui WMS, Wee A. Intrahepatic cholangiocarcinoma. In: Bostman FT, Carneiro F, Hruban RH, Theise ND. World Classification of Tumours of the Digestive System. Lyon: IARC, 2010: 217-224
- Albores-Saavedra J**, Adsay NV, Crawford JM, Klimstra DS, Kloppel G, Srija B, Tsui WMS, Paradis V. Carcinoma of the gallbladder and extrahepatic bile duct. In: Bostman FT, Carneiro F, Hruban RH, Theise ND. World Classification of Tumours of the Digestive System. Lyon: IARC, 2010: 266-273
- Kim YS**, Myung SJ, Kim SY, Kim HJ, Kim JS, Park ET, Lim BC, Seo DW, Lee SK, Kim MH, Min YI. Biliary papillomatosis: clinical, cholangiographic and cholangioscopic findings. *Endoscopy* 1998; **30**: 763-767 [PMID: 9932755]
- Chen TC**, Nakanuma Y, Zen Y, Chen MF, Jan YY, Yeh TS, Chiu CT, Kuo TT, Kamiya J, Oda K, Hamaguchi M, Ohno Y, Hsieh LL, Nimura Y. Intraductal papillary neoplasia of the liver associated with hepatolithiasis. *Hepatology* 2001; **34**: 651-658 [PMID: 11584359 DOI: 10.1053/jhep.2001.28199]
- Naito Y**, Kusano H, Nakashima O, Sadashima E, Hattori S, Taira T, Kawahara A, Okabe Y, Shimamatsu K, Taguchi J, Momosaki S, Irie K, Yamaguchi R, Yokomizo H, Nagamine M, Fukuda S, Sugiyama S, Nishida N, Higaki K, Yoshitomi M, Yasunaga M, Okuda K, Kinoshita H, Nakayama M, Yasumoto M, Akiba J, Kage M, Yano H. Intraductal neoplasm of the intrahepatic bile duct: clinicopathological study of 24 cases. *World J Gastroenterol* 2012; **18**: 3673-3680 [PMID: 22851859 DOI: 10.3748/wjg.v18.i28.3673]

**P-Reviewer** Han X **S-Editor** Huang XZ **L-Editor** Kerr C  
**E-Editor** Zhang DN





Published by **Baishideng Publishing Group Co., Limited**

Flat C, 23/F., Lucky Plaza,

315-321 Lockhart Road, Wan Chai, Hong Kong, China

Fax: +852-65557188

Telephone: +852-31779906

E-mail: [bpgoffice@wjgnet.com](mailto:bpgoffice@wjgnet.com)

<http://www.wjgnet.com>



ISSN 1007-9327

