

Strategies to increase the resectability of hepatocellular carcinoma

Wong Hoi She, Kenneth SH Chok

Wong Hoi She, Kenneth SH Chok, Department of Surgery, the University of Hong Kong, Hong Kong, China

Author contributions: She WH drafted the manuscript; Chok KSH reviewed the manuscript; both of them approved the submitted version of the manuscript.

Conflict-of-interest statement: None of the authors has any conflict of interest with regard to the study or its publication.

Open-Access: This article is an open-access article which was selected by an in-house editor and fully peer-reviewed by external reviewers. It is distributed in accordance with the Creative Commons Attribution Non Commercial (CC BY-NC 4.0) license, which permits others to distribute, remix, adapt, build upon this work non-commercially, and license their derivative works on different terms, provided the original work is properly cited and the use is non-commercial. See: <http://creativecommons.org/licenses/by-nc/4.0/>

Correspondence to: Dr. Kenneth SH Chok, MBBS, Department of Surgery, the University of Hong Kong, 102 Pok Fu Lam Road, Hong Kong, China. kennethchok@gmail.com
Telephone: +852-22553025
Fax: +852-28165284

Received: April 27, 2015
Peer-review started: April 30, 2015
First decision: July 25, 2015
Revised: August 10, 2015
Accepted: August 20, 2015
Article in press: August 21, 2015
Published online: August 28, 2015

Abstract

Hepatocellular carcinoma (HCC) is best treated by liver transplantation, but the applicability of transplantation is greatly limited. Tumor resection in partial hepatectomy is hence resorted to. However, in most parts of the world, only 20%-30% of HCCs are resectable. The main reason for such a low resectability is a future liver remnant

too small to be sufficient for the patient. To allow more HCC patients to undergo curative hepatectomy, a variety of ways have been developed to increase the resectability of HCC, mainly ways to increase the future liver remnants in patients through hypertrophy. They include portal vein embolization, sequential transarterial chemoembolization and portal vein embolization, staged hepatectomy, two-staged hepatectomy with portal vein ligation, and Associating Liver Partition and Portal Vein Ligation in Staged Hepatectomy. Herein we review, describe and evaluate these different ways, ways that can be life-saving.

Key words: Hepatocellular carcinoma; Hepatectomy; Portal vein ligation; Associating Liver Partition and Portal Vein Ligation in Staged Hepatectomy; Portal vein embolization

© **The Author(s) 2015.** Published by Baishideng Publishing Group Inc. All rights reserved.

Core tip: There are different ways to increase the resectability of hepatocellular carcinoma by increasing the volume of the future liver remnant (FLR) through hypertrophy. Portal vein embolization features the embolization of the ipsilateral side of the portal vein which supplies the liver lobe harboring the tumor, either in an open or percutaneous manner. Sequential transarterial chemoembolization and portal vein embolization is a way to augment the effect of portal vein embolization and prevent tumor progression. Staged hepatectomy is mainly for liver tumors with bilobar involvement and colorectal liver metastasis and is often aided by effective adjuvant chemotherapy. Its aim is to strike a balance between complete tumor removal and preservation of the FLR. Two-staged hepatectomy with portal vein ligation is also mainly for liver tumors with bilobar involvement and colorectal liver metastasis. In the first-stage operation, tumor in the liver portion which is designated as the FLR is cleared, and portal vein ligation is performed. The liver parenchyma is transected

only in the second-stage operation. Associating Liver Partition and Portal Vein Ligation in Staged Hepatectomy is used to speed up hypertrophy in the hope that the FLR will grow large enough for a safe hepatectomy before tumor progression occurs. It features right portal vein ligation and in-situ splitting of the intended transection surface down to the inferior vena cava. In the first-stage operation, the anterior approach is encouraged and the Pringle maneuver is discouraged, and the hilar plate is left untouched.

She WH, Chok KSH. Strategies to increase the resectability of hepatocellular carcinoma. *World J Hepatol* 2015; 7(18): 2147-2154 Available from: URL: <http://www.wjgnet.com/1948-5182/full/v7/i18/2147.htm> DOI: <http://dx.doi.org/10.4254/wjh.v7.i18.2147>

INTRODUCTION

Hepatocellular carcinoma (HCC) is the fifth most common cancer and the most common primary liver malignancy^[1,2]. Most cases of HCC in Asia are related to hepatitis B, which is prevalent in the region^[3]. The best treatment for HCC is liver transplant because it removes both the tumor and the diseased liver, and a 5-year post-transplant survival rate of > 70% is expected^[4-7]. Unfortunately, its applicability is limited by the shortage of liver grafts^[8]. Moreover, only patients who have HCC within selection criteria (e.g., the Milan criteria^[9], the University of California, San Francisco criteria^[10]) are eligible for liver transplant. A study reported that for patients with HCC within the Milan criteria, the 5-year survival rate was 81% with living donor liver transplant and 72.8% with partial hepatectomy^[11]. In the face of perpetual liver graft shortage, hepatectomy remains an important curative measure as it can achieve a satisfactory survival outcome.

Hepatectomy has been evolving and is getting more technically challenging as surgeons are pushing limits. They are trying to operate on HCCs larger and larger and with more and more nodules, but a R0 resection is always the ultimate goal. The applicability of hepatectomy is often limited by an inadequate future liver remnant (FLR) or a marginal liver, especially in patients with underlying hepatitis or cirrhosis. The success of hepatectomy depends on many factors, which include status of the tumor, the patient's clinical status and underlying liver function, and the size of the FLR of the patient^[12-14]. Aggressive hepatectomy may still be beneficial for patients who have advanced HCC with large or multiple tumors or intrahepatic venous invasion if they are properly selected^[15]. Curative hepatectomy is the first-line treatment for HCC at many centers. The resectability of HCC often rises with the volume of the FLR, and therefore different measures are employed for increasing such volume. Moreover, a larger FLR would probably mean better overall and disease-free survival.

SURGICAL RESECTION

In the management of HCC, liver resection for tumor clearance is the first-line curative treatment for patients with preserved liver function^[11,14,16]. Major hepatectomy can be performed safely nowadays with careful patient selection^[12,14], better understanding of the liver anatomy^[17], improvement of surgical techniques, and advances of surgical instruments. Widely adopted techniques include the hanging maneuver^[18], the anterior approach for avoidance of mobilization and rupture of large tumors^[19,20], the Pringle maneuver^[21], and meticulous control of central venous pressure for reduction of reduce blood loss^[22]. Widely employed instruments include Cavitron Ultrasound Surgical Aspirator, hydrojet^[23,24], the Harmonic scalpel, LigaSure, Harmonic Ace, and Thunderbeat^[25]. Although complications and perioperative mortalities still occur, the rates are acceptable^[13,14,26,27]. However, major hepatectomy may not be suitable for patients with marginal liver function or a relatively small FLR. The University of Hong Kong uses indocynaine green clearance test as an important tool to assess their patients' preoperative liver function^[28]. Unfortunately, there is no perfect test for the prediction of postoperative mortality^[29,30]. For risk stratification for major hepatectomy, usually a combination of assessment modalities is adopted, which usually includes measurement of the disease's Child-Pugh grading, indocynaine green clearance test, renal function test by creatinine level check, and platelet count.

Location of tumors is a decisive factor in surgical planning. The amount of liver removed in hepatectomy decides the volume of the liver remnant. Major hepatectomy can only be offered to patients with an adequate FLR and adequate post-resection liver function. To avoid massive bleeding and vascular insult to the liver, preservation or reconstruction of major hepatic veins in addition to meticulous surgical skills is needed^[29]. A patient's liver volume can be measured by tracing the liver contour in the cross-sectional image on computed tomography volumetry^[31], and a patient's standard liver volume can be derived from his weight and height with different formulae^[32,33]. The volume of his FLR can then be calculated. Patients with cirrhosis have relatively poor liver function, and thus need a larger FLR^[34-37] to lower the risk of liver failure. At The University of Hong Kong, for patients who have Child-Pugh A cirrhosis and an indocynaine green retention rate $\leq 20\%$ at 15 min, an FLR > 30% of the estimated standard liver volume is preferred for right hepatectomy, and an FLR > 35% of the estimated standard liver volume is preferred for extended right hepatectomy or right trisectionectomy. Patients who have cirrhosis and an inadequate FLR have a high risk of post-hepatectomy liver failure^[37,38].

REGENERATION OF LIVER REMNANT

Different types of injury (e.g., ischemia/reperfusion, resection) will induce a hypertrophic response called

the atrophy-hypertrophy complex in a liver remnant. Hypertrophy is simultaneously caused by increased endothelial shear stress, hepatocellular swelling, and activated growth factors/cytokines due to increased portal flow^[39]. The idea of portal vein embolization (PVE) is to occlude a liver segment or lobule so as to bring about its ischemia^[40,41] and consequent atrophy, thereby inducing hypertrophy of the part of liver not atrophied.

PVE

PVE is indicated for patients who are considered for right or extended right hepatectomy but with a relatively small FLR. By PVE, the size of an FLR can be increased. PVE features the embolization of the ipsilateral side of the portal vein which supplies the liver lobe harboring the tumor, either in an open or percutaneous manner, thereby inducing hypertrophy of the FLR^[42,43]. To date, there is still no straight value on the minimum volume of an FLR which allows major hepatectomy to be performed safely. An FLR > 35% of the estimated standard liver volume has been recommended for patients with cirrhosis, steatosis, or chronic hepatitis^[28,36,37,44-48]. PVE is rarely required before extended left hepatectomy or left trisectionectomy, since the right posterior section usually constitutes about 30% of the total liver volume^[49,50]. The technique for embolizing the segment-4 portal vein is crucial; if the vein is not properly blocked, suboptimal hypertrophy may results.

Liver volume assessment after PVE

The FLR volume will be reassessed 4-8 wk after PVE^[51,52]. Rapid growth of the FLR is anticipated in the first 3-4 wk. Generally, an 8%-30% enlargement over 2-6 wk is expected^[43,52-55]. Hypertrophy is usually slower in the presence of cirrhosis^[56]. Studies comparing major hepatectomy with and without preceding PVE reported that comparable and even superior long-term outcomes were achieved with PVE^[45,57-63]. With PVE, patients who would have been considered inoperable in the past because of their small FLR have the option of hepatectomy with reasonable long-term surgical outcomes.

Complications of PVE

PVE can be performed in an open or percutaneous manner. Open right portal vein ligation often renders the subsequent surgery difficult due to vascular or fibrotic adhesions around the hilar structure. Open transileocolic PVE is performed with cannulation of the ileocolic vein in addition to embolization of the right portal vein in an antegrade manner or percutaneous portal vein cannulation and retrograde embolization. Ipsilateral percutaneous PVE is generally preferred because of the low invasiveness and an easier access to segment-4 portal vein branches^[64-66]. Different ways of PVE all carry a risk of complication, such as main portal vein thrombosis. Prompt surgical intervention or

anticoagulation is needed if the embolic agent crosses the contralateral side of the portal vein, which would cause liver failure in the case of bilateral PVE, resulting in death^[67]. Hemorrhage or catastrophic bleeding at the puncture site may also occur, which also requires prompt surgical intervention. In addition, PVE induces inflammatory response near the hilar structure, which may increase the difficulty in dissection in the subsequent hepatectomy and raise the surgical risk.

SEQUENTIAL TRANSARTERIAL CHEMOEMBOLIZATION AND PVE

PVE can be given to HCC patients with underlying cirrhosis, but hepatic regeneration and thus hypertrophy of the FLR would be impaired in the presence of cirrhosis^[68-70]. On the other hand, it is likely that the arterial flow increases compensatorily in segments with PVE, thereby stimulating tumor progression as HCC is a hypervascular tumor supplied by the hepatic artery blood flow^[71-73]. To augment the effect of PVE and prevent tumor progression, the treatment sequential transarterial chemoembolization and PVE is used^[57]. Studies comparing patients who received this treatment and patients who did not found that patients who did showed a higher rate of hypertrophy of FLR and a bigger increase in their FLR^[57,58], and the rate of tumor progression was lower as tumor necrosis was evident^[74]. This treatment is not without risk; it could cause ischemic parenchymal damage^[75], but overall, it is feasible and safe, and it allows HCC patients who would otherwise be denied hepatectomy to undergo curative resection with reasonable postoperative 5-year overall and disease-free survival^[57,58,76].

STAGED HEPATECTOMY

Staged hepatectomy is mainly for HCC with bilobar involvement and colorectal liver metastasis, and is often aided by effective adjuvant chemotherapy^[77-79]. In staged hepatectomy, two or more planned hepatectomies are performed at different time to achieve a R0 resection. It is distinguished from unplanned repeat hepatectomies for recurrent disease^[80]. Its aim is to strike a balance between complete tumor removal and preservation of the FLR. The chance of postoperative liver failure can be reduced if bilobar tumors are removed in a staged manner. The preserved portion of the liver should be relatively spared by the disease with sufficient FLR and adequate vascular inflow and outflow^[81]. However, there is always the chance that the tumor tissue is cut across during the first-stage procedure, resulting in tumor spillage and peritoneal metastasis, and rendering the planned second-stage procedure unfeasible. Besides, tumors may grow despite temporary chemotherapy during the hepatic regenerative period, which may also preclude further operation. Repeat resection is technically demanding, as not only all the dissection

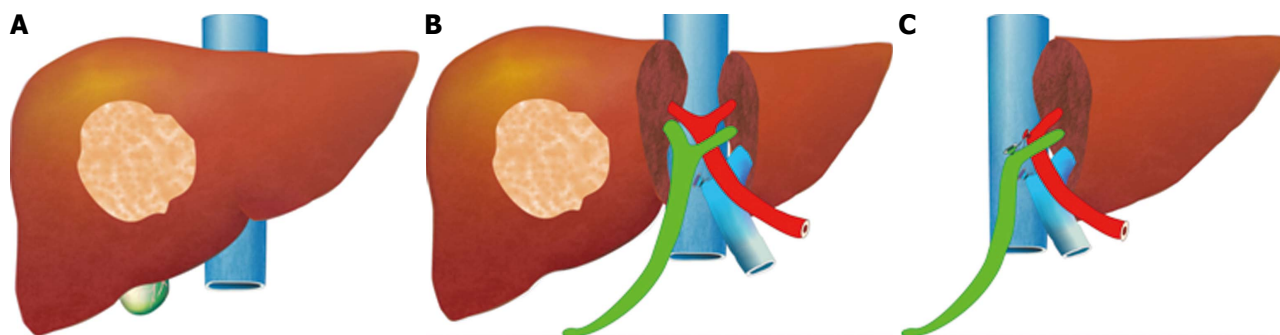


Figure 1 Associating Liver Partition and Portal Vein Ligation in Staged Hepatectomy. A: Tumor in the right liver lobe, the future liver remnant (the left liver lobe) will be small; B: In stage-1 ALPPS, the right portal vein is ligated, liver transected, inferior vena cava exposed, and gallbladder resected; C: In stage-2 ALPPS, the left liver lobe has hypertrophied, the right lobe with tumor is resected, right hepatic artery and right hepatic duct transected and ligated. Green: Bile duct; Red: Hepatic artery; Blue: Posterior inferior vena cava and anterior portal vein. ALPPS: Associating Liver Partition and Portal Vein Ligation in Staged Hepatectomy.

planes have already been disturbed, adhesiolysis can also be very difficult. Adhesiolysis near the liver hilum and the inferior vena cava is particularly challenging, as massive bleeding may occur. Staged hepatectomy for HCC was not common^[79]; it was mostly for colorectal liver metastasis^[78,82-85].

TWO-STAGED HEPATECTOMY WITH PORTAL VEIN LIGATION

This treatment requires two laparotomies and is also mainly for HCC with bilobar involvement and colorectal liver metastasis. In the first laparotomy, tumor in the liver portion which is designated as the FLR is cleared, and portal vein ligation is performed. Other required resection such as that of colorectal primary tumor is also done in the first laparotomy. The liver parenchyma is transected only in the second laparotomy but not in the first. The portal vein ligation is to induce hypertrophy of the FLR, allowing hepatectomy in the second-stage procedure and decreasing the risk of postoperative liver failure. Portal vein ligation has been found to be as effective as PVE^[86]. However, open portal vein ligation poses the risk of adhesion formation over the hilum, which may increase the difficulty of dissection in the second-stage operation.

ASSOCIATING LIVER PARTITION AND PORTAL VEIN LIGATION IN STAGED HEPATECTOMY

For hepatectomy, one of the limiting factors is inadequate volume of the FLR. Although the aforesaid methods are effective in inducing hypertrophy of the FLR, it takes several weeks for it to reach a satisfactory volume^[43]. Tumor progression may occur before the FLR is large enough for the planned hepatectomy to be conducted. If a major vessel such as the ipsilateral portal vein is invaded by tumor, the tumor will progress in terms of days and contralateral deposition and metastasis of the tumor will occur, rendering the tumor inoperable^[72,73,87].

Associating Liver Partition and Portal Vein Ligation in Staged Hepatectomy (ALPPS) is one of the main surgical innovations in recent years. The procedure, which was invented by chance, was initially carried out by Dr. Hans Schlitt from Germany in an intended extended right hepatectomy for hilar cholangiocarcinoma^[88]. In the surgery, palliative left hepaticojejunostomy was performed because the FLR was small, with division of the liver parenchyma along the falciform ligament and ligation of the right portal vein. On day 8 after the surgery, computed tomography was performed. To Dr. Schlitt's surprise, the left lateral section had grown enormously in size. The diseased portion of the liver was subsequently removed in another surgery. This novel technique was later termed "ALPPS"^[89]. The idea of ALPPS is to speed up hypertrophy of the FLR (the left lobe or the left lateral section) by right portal vein ligation and in-situ splitting of the intended transection surface down to the inferior vena cava (Figure 1). Generally, the FLR regenerates to a volume adequate for a safe hepatectomy in days.

ALPPS was initially applied to relatively normal livers, such as in the case of colorectal liver metastasis. Later it was also applied to livers with steatosis or cirrhosis^[88,90-94]. A 70% increase in FLR volume has been reported^[95]. ALPPS is better than conventional PVE when the rate and the percentage of hypertrophy are concerned^[96,97]. The shorter the interval between the two operations is, the less mature the adhesions would be, and hence the second operation would also be easier.

Most of the reported cases of ALPPS are on non-cirrhotic livers, and there has not been any report on the rate of hypertrophy in cirrhotic livers. However, one would anticipate that some patients would not have adequate hypertrophy of the contralateral side and hence the second stage operation is not possible. ALPPS carries certain risks. The right hepatic artery could be injured, and liver failure could occur after right portal vein ligation. The Pringle maneuver would pose a further risk of liver injury and is thus not recommended. In the first-stage operation, adoption of the anterior approach allows liver transection without mobilization of the right

lobe, thereby minimizing adhesion formation^[98], and the hilar plate is left untouched so as to minimize the chance of biliary complication. Bile leakage from the transection surface can result in biloma and increases the chance of infection and thus the risk of sepsis, which may forbid the second-stage operation. ALPPS is very technically challenging and demanding, and therefore should not be carried out by inexperienced surgeons.

Indications for ALPPS

ALPPS should be carried out with a curative intent. It is indicated for patients who have a large tumor load and a marginal FLR^[96], even with tumor invasion of major vessels, such as the portal vein^[92]. ALPPS renders some inoperable tumors potentially operable.

Morbidity and mortality after ALPPS

Complication and mortality are inevitable with any surgery; ALPPS is no exception. Perioperative mortality rates of 12%-28% have been reported, which are overall higher than those of conventional major hepatectomy^[95,96,99,100]. A complication rate high at 50% has been recorded^[99,101]. Complications include ascites, bile leakage, persisting cholestasis and sepsis, wound infection, and other inflammatory and infective complications. ALPPS increases operability at the price of a heightened morbidity and mortality. Keeping morbidity and mortality at the minimum requires careful patient selection, meticulous surgical technique, and accurate decision as to proceeding to the second-stage operation or not.

The long-term outcome of ALPPS is still unknown. Long-term overall survival and disease-free survival are still pending. Further studies as well as input from different centers are required but not yet available. However, ALPPS has improved the operative rate, and it is hoped that it will improve the overall and disease-free survival of patients. Nonetheless, larger trials are needed to document its efficacy especially for those patient with HCC and background cirrhosis.

CONCLUSION

There are revolutionary changes of surgical methods to increase the resectability of HCCs, and various ways to increase the volume of the FLR of patients considered for major hepatectomy have been developed. Improvement in surgical techniques also allows patients to benefit from surgical resection with safety. Treatment modalities are always evolving for the better. Hopefully, ALPPS will continue to develop and long-term results will be available in the near future.

REFERENCES

- 1 Llovet JM, Burroughs A, Bruix J. Hepatocellular carcinoma. *Lancet* 2003; **362**: 1907-1917 [PMID: 14667750 DOI: 10.1016/S0140-6736(03)14964-1]
- 2 Kim do Y, Han KH. Epidemiology and surveillance of hepatocellular carcinoma. *Liver Cancer* 2012; **1**: 2-14 [PMID: 24159567 DOI: 10.1159/000339016]
- 3 Ferlay J, Shin HR, Bray F, Forman D, Mathers C, Parkin DM. Estimates of worldwide burden of cancer in 2008: GLOBOCAN 2008. *Int J Cancer* 2010; **127**: 2893-2917 [PMID: 21351269 DOI: 10.1002/ijc.25516]
- 4 Mazzaferro V, Llovet JM, Miceli R, Bhoori S, Schiavo M, Mariani L, Camerini T, Roayaie S, Schwartz ME, Grazi GL, Adam R, Neuhaus P, Salizzoni M, Bruix J, Forner A, De Carlis L, Cillo U, Burroughs AK, Troisi R, Rossi M, Gerunda GE, Lerut J, Belghiti J, Boin I, Gugenheim J, Rochling F, Van Hoek B, Majno P. Predicting survival after liver transplantation in patients with hepatocellular carcinoma beyond the Milan criteria: a retrospective, exploratory analysis. *Lancet Oncol* 2009; **10**: 35-43 [PMID: 19058754 DOI: 10.1016/S1470-2045(08)70284-5]
- 5 Lee KK, Kim DG, Moon IS, Lee MD, Park JH. Liver transplantation versus liver resection for the treatment of hepatocellular carcinoma. *J Surg Oncol* 2010; **101**: 47-53 [PMID: 19798686 DOI: 10.1002/jso.21415]
- 6 Ito T, Takada Y, Ueda M, Haga H, Maetani Y, Oike F, Ogawa K, Sakamoto S, Ogura Y, Egawa H, Tanaka K, Uemoto S. Expansion of selection criteria for patients with hepatocellular carcinoma in living donor liver transplantation. *Liver Transpl* 2007; **13**: 1637-1644 [PMID: 18044766 DOI: 10.1002/lt.21281]
- 7 Tamura S, Sugawara Y, Kokudo N. Living donor liver transplantation for hepatocellular carcinoma: the Japanese experience. *Oncology* 2011; **81** Suppl 1: 111-115 [PMID: 22212944 DOI: 10.1159/000333270]
- 8 Lo CM, Fan ST, Liu CL, Chan SC, Wong J. The role and limitation of living donor liver transplantation for hepatocellular carcinoma. *Liver Transpl* 2004; **10**: 440-447 [PMID: 15004774 DOI: 10.1002/lt.20097]
- 9 Mazzaferro V, Regalia E, Doci R, Andreola S, Pulvirenti A, Bozzetti F, Montalto F, Ammatuna M, Morabito A, Gennari L. Liver transplantation for the treatment of small hepatocellular carcinomas in patients with cirrhosis. *N Engl J Med* 1996; **334**: 693-699 [PMID: 8594428 DOI: 10.1056/NEJM199603143341104]
- 10 Yao FY, Ferrell L, Bass NM, Watson JJ, Bacchetti P, Venook A, Ascher NL, Roberts JP. Liver transplantation for hepatocellular carcinoma: expansion of the tumor size limits does not adversely impact survival. *Hepatology* 2001; **33**: 1394-1403 [PMID: 11391528 DOI: 10.1053/jhep.2001.24563]
- 11 Fan ST, Poon RT, Yeung C, Lam CM, Lo CM, Yuen WK, Ng KK, Liu CL, Chan SC. Outcome after partial hepatectomy for hepatocellular cancer within the Milan criteria. *Br J Surg* 2011; **98**: 1292-1300 [PMID: 21656513 DOI: 10.1002/bjs.7583]
- 12 Poon RT, Fan ST. Assessment of hepatic reserve for indication of hepatic resection: how I do it. *J Hepatobiliary Pancreat Surg* 2005; **12**: 31-37 [PMID: 15754097 DOI: 10.1007/s00534-004-0945-0]
- 13 Poon RT, Fan ST, Lo CM, Liu CL, Lam CM, Yuen WK, Yeung C, Wong J. Extended hepatic resection for hepatocellular carcinoma in patients with cirrhosis: is it justified? *Ann Surg* 2002; **236**: 602-611 [PMID: 12409666 DOI: 10.1097/01.SLA.0000033038.38956.5E]
- 14 Fan ST, Mau Lo C, Poon RT, Yeung C, Leung Liu C, Yuen WK, Ming Lam C, Ng KK, Ching Chan S. Continuous improvement of survival outcomes of resection of hepatocellular carcinoma: a 20-year experience. *Ann Surg* 2011; **253**: 745-758 [PMID: 21475015 DOI: 10.1097/SLA.0b013e3182111195]
- 15 Yau T, Tang VY, Yao TJ, Fan ST, Lo CM, Poon RT. Development of Hong Kong Liver Cancer staging system with treatment stratification for patients with hepatocellular carcinoma. *Gastroenterology* 2014; **146**: 1691-700.e3 [PMID: 24583061 DOI: 10.1053/j.gastro.2014.02.032]
- 16 Cauchy F, Soubrane O, Belghiti J. Liver resection for HCC: patient's selection and controversial scenarios. *Best Pract Res Clin Gastroenterol* 2014; **28**: 881-896 [PMID: 25260315 DOI: 10.1016/j.bpg.2014.08.013]
- 17 Couinaud C. Liver anatomy: portal (and suprahepatic) or biliary segmentation. *Dig Surg* 1999; **16**: 459-467 [PMID: 10805544 DOI: 10.1159/000018770]
- 18 Belghiti J, Guevara OA, Noun R, Saldinger PF, Kianmanesh R. Liver hanging maneuver: a safe approach to right hepatectomy

- without liver mobilization. *J Am Coll Surg* 2001; **193**: 109-111 [PMID: 11442247 DOI: 10.1016/S1072-7515(01)00909-7]
- 19 **Liu CL**, Fan ST, Lo CM, Tung-Ping Poon R, Wong J. Anterior approach for major right hepatic resection for large hepatocellular carcinoma. *Ann Surg* 2000; **232**: 25-31 [PMID: 10862191 DOI: 10.1097/0000658-200007000-00004]
- 20 **Fan ST**, Liu CL. Anterior approach for major right hepatic resection. *J Hepatobiliary Pancreat Surg* 2005; **12**: 356-361 [PMID: 16258802 DOI: 10.1007/s00534-005-1000-5]
- 21 **Man K**, Fan ST, Ng IO, Lo CM, Liu CL, Wong J. Prospective evaluation of Pringle maneuver in hepatectomy for liver tumors by a randomized study. *Ann Surg* 1997; **226**: 704-711; discussion 711-713 [PMID: 9409569 DOI: 10.1097/0000658-199712000-00007]
- 22 **Melendez JA**, Arslan V, Fischer ME, Wuest D, Jarnagin WR, Fong Y, Blumgart LH. Perioperative outcomes of major hepatic resections under low central venous pressure anesthesia: blood loss, blood transfusion, and the risk of postoperative renal dysfunction. *J Am Coll Surg* 1998; **187**: 620-625 [PMID: 9849736 DOI: 10.1016/S1072-7515(98)00240-3]
- 23 **Lesurtel M**, Selzner M, Petrowsky H, McCormack L, Clavien PA. How should transection of the liver be performed?: a prospective randomized study in 100 consecutive patients: comparing four different transection strategies. *Ann Surg* 2005; **242**: 814-22, discussion 822-3 [PMID: 16327491 DOI: 10.1097/01.sla.0000189121.35617.d7]
- 24 **Takayama T**, Makuuchi M, Kubota K, Harihara Y, Hui AM, Sano K, Ijichi M, Hasegawa K. Randomized comparison of ultrasonic vs clamp transection of the liver. *Arch Surg* 2001; **136**: 922-928 [PMID: 11485528 DOI: 10.1001/archsurg.136.8.922]
- 25 **Milsom J**, Trencheva K, Monette S, Pavor R, Shukla P, Ma J, Sonoda T. Evaluation of the safety, efficacy, and versatility of a new surgical energy device (THUNDERBEAT) in comparison with Harmonic ACE, LigaSure V, and EnSeal devices in a porcine model. *J Laparoendosc Adv Surg Tech A* 2012; **22**: 378-386 [PMID: 22364404 DOI: 10.1089/lap.2011.0420]
- 26 **Fan ST**, Lai EC, Lo CM, Ng IO, Wong J. Hospital mortality of major hepatectomy for hepatocellular carcinoma associated with cirrhosis. *Arch Surg* 1995; **130**: 198-203 [PMID: 7848092 DOI: 10.1001/archsurg.1995.01430020088017]
- 27 **Fan ST**, Lo CM, Liu CL, Lam CM, Yuen WK, Yeung C, Wong J. Hepatectomy for hepatocellular carcinoma: toward zero hospital deaths. *Ann Surg* 1999; **229**: 322-330 [PMID: 10077043 DOI: 10.1097/0000658-199903000-00004]
- 28 **Lau H**, Man K, Fan ST, Yu WC, Lo CM, Wong J. Evaluation of preoperative hepatic function in patients with hepatocellular carcinoma undergoing hepatectomy. *Br J Surg* 1997; **84**: 1255-1259 [PMID: 9313707 DOI: 10.1002/bjs.1800840917]
- 29 **Fan ST**. Liver functional reserve estimation: state of the art and relevance for local treatments: the Eastern perspective. *J Hepatobiliary Pancreat Sci* 2010; **17**: 380-384 [PMID: 19865790 DOI: 10.1007/s00534-009-0229-9]
- 30 **Manizate F**, Hiotis SP, Labow D, Roayaie S, Schwartz M. Liver functional reserve estimation: state of the art and relevance for local treatments: the Western perspective. *J Hepatobiliary Pancreat Sci* 2010; **17**: 385-388 [PMID: 19936599 DOI: 10.1007/s00534-009-0228-x]
- 31 **Heysfield SB**, Fulenwider T, Nordlinger B, Barlow R, Sones P, Kutner M. Accurate measurement of liver, kidney, and spleen volume and mass by computerized axial tomography. *Ann Intern Med* 1979; **90**: 185-187 [PMID: 443650 DOI: 10.7326/0003-4819-90-2-185]
- 32 **Chan SC**, Lo CM, Chok KS, Sharr WW, Cheung TT, Tsang SH, Chan AC, Fan ST. Validation of graft and standard liver size predictions in right liver living donor liver transplantation. *Hepatol Int* 2011; **5**: 913-917 [PMID: 21484120 DOI: 10.1007/s12072-011-9264-0]
- 33 **Urata K**, Kawasaki S, Matsunami H, Hashikura Y, Ikegami T, Ishizone S, Momose Y, Komiyama A, Makuuchi M. Calculation of child and adult standard liver volume for liver transplantation. *Hepatology* 1995; **21**: 1317-1321 [PMID: 7737637 DOI: 10.1002/hep.1840210515]
- 34 **Shoup M**, Gonen M, D'Angelica M, Jarnagin WR, DeMatteo RP, Schwartz LH, Tuorto S, Blumgart LH, Fong Y. Volumetric analysis predicts hepatic dysfunction in patients undergoing major liver resection. *J Gastrointest Surg* 2003; **7**: 325-330 [PMID: 12654556 DOI: 10.1016/S1091-255X(02)00370-0]
- 35 **Vauthey JN**, Chaoui A, Do KA, Bilimoria MM, Fenstermacher MJ, Charnsangavej C, Hicks M, Alsasser G, Lauwers G, Hawkins IF, Caridi J. Standardized measurement of the future liver remnant prior to extended liver resection: methodology and clinical associations. *Surgery* 2000; **127**: 512-519 [PMID: 10819059 DOI: 10.1067/msy.2000.105294]
- 36 **Kubota K**, Makuuchi M, Kusaka K, Kobayashi T, Miki K, Hasegawa K, Harihara Y, Takayama T. Measurement of liver volume and hepatic functional reserve as a guide to decision-making in resectional surgery for hepatic tumors. *Hepatology* 1997; **26**: 1176-1181 [PMID: 9362359 DOI: 10.1053/jhep.1997.v26.pm0009362359]
- 37 **Shirabe K**, Shimada M, Gion T, Hasegawa H, Takenaka K, Utsunomiya T, Sugimachi K. Postoperative liver failure after major hepatic resection for hepatocellular carcinoma in the modern era with special reference to remnant liver volume. *J Am Coll Surg* 1999; **188**: 304-309 [PMID: 10065820 DOI: 10.1016/S1072-7515(98)00301-9]
- 38 **Schindl MJ**, Redhead DN, Fearon KC, Garden OJ, Wigmore SJ. The value of residual liver volume as a predictor of hepatic dysfunction and infection after major liver resection. *Gut* 2005; **54**: 289-296 [PMID: 15647196 DOI: 10.1136/gut.2004.046524]
- 39 **Kim RD**, Kim JS, Watanabe G, Mohuczy D, Behrns KE. Liver regeneration and the atrophy-hypertrophy complex. *Semin Intervent Radiol* 2008; **25**: 92-103 [PMID: 21326550 DOI: 10.1055/s-2008-1076679]
- 40 **Lemasters JJ**, Ji S, Thurman RG. Centrilobular injury following hypoxia in isolated, perfused rat liver. *Science* 1981; **213**: 661-663 [PMID: 7256265 DOI: 10.1126/science.7256265]
- 41 **Jungermann K**, Kietzmann T. Oxygen: modulator of metabolic zonation and disease of the liver. *Hepatology* 2000; **31**: 255-260 [PMID: 10655244 DOI: 10.1002/hep.510310201]
- 42 **Kinoshita H**, Sakai K, Hirohashi K, Igawa S, Yamasaki O, Kubo S. Preoperative portal vein embolization for hepatocellular carcinoma. *World J Surg* 1986; **10**: 803-808 [PMID: 3022488 DOI: 10.1007/BF01655244]
- 43 **Abulkhir A**, Limongelli P, Healey AJ, Damrah O, Tait P, Jackson J, Habib N, Jiao LR. Preoperative portal vein embolization for major liver resection: a meta-analysis. *Ann Surg* 2008; **247**: 49-57 [PMID: 18156923 DOI: 10.1097/SLA.0b013e31815f6e5b]
- 44 **Zorzi D**, Laurent A, Pawlik TM, Lauwers GY, Vauthey JN, Abdalla EK. Chemotherapy-associated hepatotoxicity and surgery for colorectal liver metastases. *Br J Surg* 2007; **94**: 274-286 [PMID: 17315288 DOI: 10.1002/bjs.5719]
- 45 **Palavecino M**, Chun YS, Madoff DC, Zorzi D, Kishi Y, Kaseb AO, Curley SA, Abdalla EK, Vauthey JN. Major hepatic resection for hepatocellular carcinoma with or without portal vein embolization: Perioperative outcome and survival. *Surgery* 2009; **145**: 399-405 [PMID: 19303988 DOI: 10.1016/j.surg.2008.10.009]
- 46 **Ribero D**, Curley SA, Imamura H, Madoff DC, Nagorney DM, Ng KK, Donadon M, Vilgrain V, Torzilli G, Roh M, Vauthey JN. Selection for resection of hepatocellular carcinoma and surgical strategy: indications for resection, evaluation of liver function, portal vein embolization, and resection. *Ann Surg Oncol* 2008; **15**: 986-992 [PMID: 18236112 DOI: 10.1245/s10434-007-9731-y]
- 47 **Mullin EJ**, Metcalfe MS, Maddern GJ. How much liver resection is too much? *Am J Surg* 2005; **190**: 87-97 [PMID: 15972178 DOI: 10.1016/j.amjsurg.2005.01.043]
- 48 **Yanaga K**, Honda H, Ikeda Y, Nishizaki AT, Yamamoto K, Sugimachi K. Significance of liver size in hepatic surgery. *HPB Surg* 1997; **10**: 195-199; discussion 199-200 [PMID: 9184872 DOI: 10.1155/1997/34842]
- 49 **Abdalla EK**, Denys A, Chevalier P, Nemr RA, Vauthey JN. Total and segmental liver volume variations: implications for liver

- surgery. *Surgery* 2004; **135**: 404-410 [PMID: 15041964 DOI: 10.1016/j.surg.2003.08.024]
- 50 **Nagino M**, Nimura Y, Kamiya J, Kondo S, Uesaka K, Kin Y, Kutsuna Y, Hayakawa N, Yamamoto H. Right or left trisegment portal vein embolization before hepatic trisegmentectomy for hilar bile duct carcinoma. *Surgery* 1995; **117**: 677-681 [PMID: 7778031 DOI: 10.1016/S0039-6060(95)80012-3]
 - 51 **Corrêa D**, Schwartz L, Jarnagin WR, Tuorto S, DeMatteo R, D'Angelica M, Allen P, Brown K, Fong Y. Kinetics of liver volume changes in the first year after portal vein embolization. *Arch Surg* 2010; **145**: 351-354; discussion 354-355 [PMID: 20404285 DOI: 10.1001/archsurg.2010.42]
 - 52 **Ribero D**, Abdalla EK, Madoff DC, Donadon M, Loyer EM, Vauthey JN. Portal vein embolization before major hepatectomy and its effects on regeneration, resectability and outcome. *Br J Surg* 2007; **94**: 1386-1394 [PMID: 17583900 DOI: 10.1002/bjs.5836]
 - 53 **Abdalla EK**, Barnett CC, Doherty D, Curley SA, Vauthey JN. Extended hepatectomy in patients with hepatobiliary malignancies with and without preoperative portal vein embolization. *Arch Surg* 2002; **137**: 675-680; discussion 680-681 [PMID: 12049538 DOI: 10.1001/archsurg.137.6.675]
 - 54 **Nagino M**, Nimura Y, Kamiya J, Kondo S, Uesaka K, Kin Y, Hayakawa N, Yamamoto H. Changes in hepatic lobe volume in biliary tract cancer patients after right portal vein embolization. *Hepatology* 1995; **21**: 434-439 [PMID: 7843717 DOI: 10.1002/hep.1840210226]
 - 55 **Imamura H**, Shimada R, Kubota M, Matsuyama Y, Nakayama A, Miyagawa S, Makuuchi M, Kawasaki S. Preoperative portal vein embolization: an audit of 84 patients. *Hepatology* 1999; **29**: 1099-1105 [PMID: 10094953 DOI: 10.1002/hep.510290415]
 - 56 **Farges O**, Belghiti J, Kianmanesh R, Regimbeau JM, Santoro R, Vilgrain V, Denys A, Sauvanet A. Portal vein embolization before right hepatectomy: prospective clinical trial. *Ann Surg* 2003; **237**: 208-217 [PMID: 12560779 DOI: 10.1097/01.SLA.00-00048447.16651.7B]
 - 57 **Aoki T**, Imamura H, Hasegawa K, Matsukura A, Sano K, Sugawara Y, Kokudo N, Makuuchi M. Sequential preoperative arterial and portal venous embolizations in patients with hepatocellular carcinoma. *Arch Surg* 2004; **139**: 766-774 [PMID: 15249411 DOI: 10.1001/archsurg.139.7.766]
 - 58 **Ogata S**, Belghiti J, Farges O, Varma D, Sibert A, Vilgrain V. Sequential arterial and portal vein embolizations before right hepatectomy in patients with cirrhosis and hepatocellular carcinoma. *Br J Surg* 2006; **93**: 1091-1098 [PMID: 16779884 DOI: 10.1002/bjs.5341]
 - 59 **Seo DD**, Lee HC, Jang MK, Min HJ, Kim KM, Lim YS, Chung YH, Lee YS, Suh DJ, Ko GY, Lee YJ, Lee SG. Preoperative portal vein embolization and surgical resection in patients with hepatocellular carcinoma and small future liver remnant volume: comparison with transarterial chemoembolization. *Ann Surg Oncol* 2007; **14**: 3501-3509 [PMID: 17899289 DOI: 10.1245/s10434-007-9553-y]
 - 60 **Azoulay D**, Castaing D, Krissat J, Smail A, Hargreaves GM, Lemoine A, Emile JF, Bismuth H. Percutaneous portal vein embolization increases the feasibility and safety of major liver resection for hepatocellular carcinoma in injured liver. *Ann Surg* 2000; **232**: 665-672 [PMID: 11066138 DOI: 10.1097/0000658-200011000-00008]
 - 61 **Tanaka H**, Hirohashi K, Kubo S, Shuto T, Higaki I, Kinoshita H. Preoperative portal vein embolization improves prognosis after right hepatectomy for hepatocellular carcinoma in patients with impaired hepatic function. *Br J Surg* 2000; **87**: 879-882 [PMID: 10931022 DOI: 10.1046/j.1365-2168.2000.01438.x]
 - 62 **Wakabayashi H**, Ishimura K, Okano K, Izuishi K, Karasawa Y, Goda F, Maeba T, Maeta H. Is preoperative portal vein embolization effective in improving prognosis after major hepatic resection in patients with advanced-stage hepatocellular carcinoma? *Cancer* 2001; **92**: 2384-2390 [PMID: 11745294 DOI: 10.1002/1097-0142(20011101)]
 - 63 **Hayashi S**, Baba Y, Ueno K, Nakajo M, Kubo F, Ueno S, Aikou T, Komokata T, Nakamura N, Sakata R. Acceleration of primary liver tumor growth rate in embolized hepatic lobe after portal vein embolization. *Acta Radiol* 2007; **48**: 721-727 [PMID: 17729001 DOI: 10.1080/02841850701424514]
 - 64 **Nagino M**, Nimura Y, Kamiya J, Kondo S, Kanai M. Selective percutaneous transhepatic embolization of the portal vein in preparation for extensive liver resection: the ipsilateral approach. *Radiology* 1996; **200**: 559-563 [PMID: 8685357 DOI: 10.1148/radiology.200.2.8685357]
 - 65 **Gibo M**, Unten S, Yogi A, Nakayama T, Ayukawa Y, Gibo S, Murayama S, Takara M, Shiraishi M. Percutaneous ipsilateral portal vein embolization using a modified four-lumen balloon catheter with fibrin glue: initial clinical experience. *Radiat Med* 2007; **25**: 164-172 [PMID: 17514367 DOI: 10.1007/s11604-007-0120-z]
 - 66 **Madoff DC**, Abdalla EK, Gupta S, Wu TT, Morris JS, Denys A, Wallace MJ, Morello FA, Ahrar K, Murthy R, Lunagomez S, Hicks ME, Vauthey JN. Transhepatic ipsilateral right portal vein embolization extended to segment IV: improving hypertrophy and resection outcomes with spherical particles and coils. *J Vasc Interv Radiol* 2005; **16**: 215-225 [PMID: 15713922 DOI: 10.1097/01.RVI.0000147067.79223.85]
 - 67 **Shaw CM**, Madoff DC. Acute Thrombosis of Left Portal Vein during Right Portal Vein Embolization Extended to Segment 4. *Semin Intervent Radiol* 2011; **28**: 156-161 [PMID: 22654253 DOI: 10.1055/s-0031-1280655]
 - 68 **Nagasue N**, Yukaya H, Ogawa Y, Kohno H, Nakamura T. Human liver regeneration after major hepatic resection. A study of normal liver and livers with chronic hepatitis and cirrhosis. *Ann Surg* 1987; **206**: 30-39 [PMID: 3038039]
 - 69 **Chen MF**, Hwang TL, Hung CF. Human liver regeneration after major hepatectomy. A study of liver volume by computed tomography. *Ann Surg* 1991; **213**: 227-229 [PMID: 1998403 DOI: 10.1097/0000658-199103000-00008]
 - 70 **Yamanaka N**, Okamoto E, Kawamura E, Kato T, Oriyama T, Fujimoto J, Furukawa K, Tanaka T, Tomoda F, Tanaka W. Dynamics of normal and injured human liver regeneration after hepatectomy as assessed on the basis of computed tomography and liver function. *Hepatology* 1993; **18**: 79-85 [PMID: 8392029 DOI: 10.1002/hep.1840180114]
 - 71 **Nagino M**, Nimura Y, Kamiya J, Kanai M, Hayakawa N, Yamamoto H. Immediate increase in arterial blood flow in embolized hepatic segments after portal vein embolization: CT demonstration. *AJR Am J Roentgenol* 1998; **171**: 1037-1039 [PMID: 9762992 DOI: 10.2214/ajr.171.4.9762992]
 - 72 **Elias D**, De Baere T, Roche A, Mducreux J, Lasser P. During liver regeneration following right portal embolization the growth rate of liver metastases is more rapid than that of the liver parenchyma. *Br J Surg* 1999; **86**: 784-788 [PMID: 10383579 DOI: 10.1046/j.1365-2168.1999.01154.x]
 - 73 **Kokudo N**, Tada K, Seki M, Ohta H, Azekura K, Ueno M, Ohta K, Yamaguchi T, Matsubara T, Takahashi T, Nakajima T, Muto T, Ikari T, Yanagisawa A, Kato Y. Proliferative activity of intrahepatic colorectal metastases after preoperative hemihepatic portal vein embolization. *Hepatology* 2001; **34**: 267-272 [PMID: 11481611 DOI: 10.1053/jhep.2001.26513]
 - 74 **de Graaf W**, van Lienden KP, van den Esschert JW, Bennink RJ, van Gulik TM. Increase in future remnant liver function after preoperative portal vein embolization. *Br J Surg* 2011; **98**: 825-834 [PMID: 21484773 DOI: 10.1002/bjs.7456]
 - 75 **Okabe H**, Beppu T, Ishiko T, Masuda T, Hayashi H, Otao R, Hasita H, Okabe K, Sugiyama S, Baba H. Preoperative portal vein embolization (PVE) for patients with hepatocellular carcinoma can improve resectability and may improve disease-free survival. *J Surg Oncol* 2011; **104**: 641-646 [PMID: 21520093 DOI: 10.1002/jso.21928]
 - 76 **Xu C**, Lv PH, Huang XE, Wang SX, Sun L, Wang FA, Wang LF. Safety and efficacy of sequential transcatheter arterial chemoembolization and portal vein embolization prior to major hepatectomy for patients with HCC. *Asian Pac J Cancer Prev*

- 2014; **15**: 703-706 [PMID: 24568482 DOI: 10.7314/APJCP.2014.15.2.703]
- 77 **Bismuth H**, Adam R, Lévi F, Farabos C, Waechter F, Castaing D, Majno P, Engerran L. Resection of nonresectable liver metastases from colorectal cancer after neoadjuvant chemotherapy. *Ann Surg* 1996; **224**: 509-520; discussion 520-522 [PMID: 8857855 DOI: 10.1097/0000658-199610000-00009]
- 78 **Adam R**, Laurent A, Azoulay D, Castaing D, Bismuth H. Two-stage hepatectomy: A planned strategy to treat irresectable liver tumors. *Ann Surg* 2000; **232**: 777-785 [PMID: 11088072 DOI: 10.1097/0000658-200012000-00006]
- 79 **Moussa ME**, Bean AG, Habib NA. Repeated resection for malignant liver tumours. *Ann R Coll Surg Engl* 1995; **77**: 364-368 [PMID: 7486764]
- 80 **de Jong MC**, Pulitano C, Ribero D, Strub J, Mentha G, Schulick RD, Choti MA, Aldrighetti L, Capussotti L, Pawlik TM. Rates and patterns of recurrence following curative intent surgery for colorectal liver metastasis: an international multi-institutional analysis of 1669 patients. *Ann Surg* 2009; **250**: 440-448 [PMID: 19730175 DOI: 10.1097/SLA.0b013e3181b4539b]
- 81 **Charnsangavej C**, Clary B, Fong Y, Grothey A, Pawlik TM, Choti MA. Selection of patients for resection of hepatic colorectal metastases: expert consensus statement. *Ann Surg Oncol* 2006; **13**: 1261-1268 [PMID: 16947009 DOI: 10.1245/s10434-006-9023-y]
- 82 **Jamal MH**, Hassanain M, Chaudhury P, Tran TT, Wong S, Yousef Y, Jozaghi Y, Salman A, Jabbour S, Simoneau E, Al-Abbad S, Al-Jiffry M, Arena G, Kavan P, Metrakos P. Staged hepatectomy for bilobar colorectal hepatic metastases. *HPB (Oxford)* 2012; **14**: 782-789 [PMID: 23043668 DOI: 10.1111/j.1477-2574.2012.00543.x]
- 83 **Tsai S**, Marques HP, de Jong MC, Mira P, Ribeiro V, Choti MA, Schulick RD, Barroso E, Pawlik TM. Two-stage strategy for patients with extensive bilateral colorectal liver metastases. *HPB (Oxford)* 2010; **12**: 262-269 [PMID: 20590896 DOI: 10.1111/j.1477-2574.2010.00161.x]
- 84 **Togo S**, Nagano Y, Masui H, Tanaka K, Miura Y, Morioka D, Endo I, Sekido H, Ike H, Shimada H. Two-stage hepatectomy for multiple bilobular liver metastases from colorectal cancer. *Hepatogastroenterology* 2005; **52**: 913-919 [PMID: 15966231]
- 85 **Shimada H**, Tanaka K, Masui H, Nagano Y, Matsuo K, Kijima M, Ichikawa Y, Ike H, Ooki S, Togo S. Results of surgical treatment for multiple (> or =5 nodules) bi-lobar hepatic metastases from colorectal cancer. *Langenbecks Arch Surg* 2004; **389**: 114-121 [PMID: 14714186 DOI: 10.1007/s00423-003-0447-6]
- 86 **Aussilhou B**, Lesurtel M, Sauvanet A, Farges O, Dokmak S, Goasguen N, Sibert A, Vilgrain V, Belghiti J. Right portal vein ligation is as efficient as portal vein embolization to induce hypertrophy of the left liver remnant. *J Gastrointest Surg* 2008; **12**: 297-303 [PMID: 18060468 DOI: 10.1007/s11605-007-0410-x]
- 87 **Heinrich S**, Jochum W, Graf R, Clavien PA. Portal vein ligation and partial hepatectomy differentially influence growth of intrahepatic metastasis and liver regeneration in mice. *J Hepatol* 2006; **45**: 35-42 [PMID: 16698111 DOI: 10.1016/j.jhep.2006.02.020]
- 88 **Baumgart JLS**, Lang H. A new method for induction of liver hypertrophy prior to right trisectionectomy: a report of three cases. *HPB (Oxford)* 2011; **(13)**: 71-72 [DOI: 10.1111/j.1477-2574.2011.00308.x]
- 89 **de Santibañes E**, Clavien PA. Playing Play-Doh to prevent postoperative liver failure: the "ALPPS" approach. *Ann Surg* 2012; **255**: 415-417 [PMID: 22330039 DOI: 10.1097/SLA.0b013e318248577d]
- 90 **Schadde E**, Ardiles V, Robles-Campos R, Malago M, Machado M, Hernandez-Alejandro R, Soubrane O, Schnitzbauer AA, Raptis D, Tschuor C, Petrowsky H, De Santibanes E, Clavien PA. Early survival and safety of ALPPS: first report of the International ALPPS Registry. *Ann Surg* 2014; **260**: 829-836; discussion 836-838 [PMID: 25379854 DOI: 10.1097/SLA.0000000000000947]
- 91 **Cavaness KM**, Doyle MB, Lin Y, Maynard E, Chapman WC. Using ALPPS to induce rapid liver hypertrophy in a patient with hepatic fibrosis and portal vein thrombosis. *J Gastrointest Surg* 2013; **17**: 207-212 [PMID: 22996934 DOI: 10.1007/s11605-012-029-9]
- 92 **Vennarecci G**, Laurenzi A, Santoro R, Colasanti M, Lepiane P, Ettorre GM. The ALPPS procedure: a surgical option for hepatocellular carcinoma with major vascular invasion. *World J Surg* 2014; **38**: 1498-1503 [PMID: 24146197 DOI: 10.1007/s00268-013-2296-y]
- 93 **Vennarecci G**, Laurenzi A, Levi Sandri GB, Busi Rizzi E, Cristofaro M, Montalbano M, Piselli P, Andreoli A, D'Offizi G, Ettorre GM. The ALPPS procedure for hepatocellular carcinoma. *Eur J Surg Oncol* 2014; **40**: 982-988 [PMID: 24767805 DOI: 10.1016/j.ejso.2014.04.002]
- 94 **Levi Sandri GB**, Lai Q, Rayar M, Sulpice L. ALPPS procedure for hepatocellular carcinoma with macrovascular thrombosis: a new opportunity? *J Hepatol* 2015; **62**: 241-242 [PMID: 25200909 DOI: 10.1016/j.jhep.2014.08.048]
- 95 **Schnitzbauer AA**, Lang SA, Goessmann H, Nadalin S, Baumgart J, Farkas SA, Fichtner-Feigl S, Lorf T, Goralczyk A, Hörbelt R, Kroemer A, Loss M, Rümmele P, Scherer MN, Padberg W, Königsrainer A, Lang H, Obed A, Schlitt HJ. Right portal vein ligation combined with in situ splitting induces rapid left lateral liver lobe hypertrophy enabling 2-staged extended right hepatic resection in small-for-size settings. *Ann Surg* 2012; **255**: 405-414 [PMID: 22330038 DOI: 10.1097/SLA.0b013e31824856f5]
- 96 **Schadde E**, Ardiles V, Slankamenac K, Tschuor C, Sergeant G, Amacker N, Baumgart J, Croome K, Hernandez-Alejandro R, Lang H, de Santibañes E, Clavien PA. ALPPS offers a better chance of complete resection in patients with primarily unresectable liver tumors compared with conventional-staged hepatectomies: results of a multicenter analysis. *World J Surg* 2014; **38**: 1510-1519 [PMID: 24748319 DOI: 10.1007/s00268-014-2513-3]
- 97 **Ielpo B**, Quijano Y, Vicente E. Pearls and pitfalls on ALPPS procedure: new complications in a new technique. *Updates Surg* 2014; **66**: 159-161 [PMID: 24584837 DOI: 10.1007/s13304-014-0249-0]
- 98 **Chan AC**, Pang R, Poon RT. Simplifying the ALPPS procedure by the anterior approach. *Ann Surg* 2014; **260**: e3 [PMID: 24866543 DOI: 10.1097/SLA.0000000000000736]
- 99 **Nadalin S**, Capobianco I, Li J, Girotti P, Königsrainer I, Königsrainer A. Indications and limits for associating liver partition and portal vein ligation for staged hepatectomy (ALPPS). Lessons Learned from 15 cases at a single centre. *Z Gastroenterol* 2014; **52**: 35-42 [PMID: 24420797 DOI: 10.1055/s-0033-1356364]
- 100 **Knoefel WT**, Gabor I, Rehders A, Alexander A, Krausch M, Schulte am Esch J, Fürst G, Topp SA. In situ liver transection with portal vein ligation for rapid growth of the future liver remnant in two-stage liver resection. *Br J Surg* 2013; **100**: 388-394 [PMID: 23124776 DOI: 10.1002/bjs.8955]
- 101 **Schadde E**, Schnitzbauer AA, Tschuor C, Raptis DA, Bechstein WO, Clavien PA. Systematic Review and Meta-Analysis of Feasibility, Safety, and Efficacy of a Novel Procedure: Associating Liver Partition and Portal Vein Ligation for Staged Hepatectomy. *Ann Surg Oncol* 2015; **22**: 3109-3120 [PMID: 25448799 DOI: 10.1245/s10434-014-4213-5]

P- Reviewer: Peng B, Smith RC S- Editor: Ji FF

L- Editor: A E- Editor: Liu SQ





Published by **Baishideng Publishing Group Inc**

8226 Regency Drive, Pleasanton, CA 94588, USA

Telephone: +1-925-223-8242

Fax: +1-925-223-8243

E-mail: bpgoffice@wjgnet.com

Help Desk: <http://www.wjgnet.com/esps/helpdesk.aspx>

<http://www.wjgnet.com>

