

Caudal approach to pure laparoscopic posterior sectionectomy under the laparoscopy-specific view

Hirokazu Tomishige, Zenichi Morise, Norihiko Kawabe, Hidetoshi Nagata, Hisanori Ohshima, Jin Kawase, Satoshi Arakawa, Rie Yoshida, Masashi Isetani

Hirokazu Tomishige, Zenichi Morise, Norihiko Kawabe, Hidetoshi Nagata, Hisanori Ohshima, Jin Kawase, Satoshi Arakawa, Rie Yoshida, Masashi Isetani, Department of Surgery, Fujita Health University School of Medicine, Banbuntane Houtokukai Hospital, Nagoya Aichi 454-8509, Japan

Author contributions: Tomishige H wrote the manuscript; Morise Z designed and performed this surgery and edited the manuscript; Kawabe N, Nagata H, Ohshima H, Kawase J, Arakawa S, Yoshida R and Isetani M collected the data, assisted during the surgery, and contributed to writing the manuscript.

Correspondence to: Zenichi Morise, MD, PhD, Professor and Chairman of Department of Surgery, Fujita Health University School of Medicine, Banbuntane Houtokukai Hospital, 3-6-10 Otobashi Nakagawa-ku, Nagoya Aichi 454-8509, Japan. zmorise@aol.com

Telephone: +81-52-3235680 Fax: +81-52-3234502

Received: January 11, 2013 Revised: April 20, 2013

Accepted: May 9, 2013

Published online: June 27, 2013

Abstract

AIM: To study our novel caudal approach laparoscopic posterior-sectionectomy with parenchymal transection prior to mobilization under laparoscopy-specific view.

METHODS: Points of the procedure are: (1) Patients are put in left lateral position and posterior sector is not mobilized; (2) Glissonian pedicle of the sector is encircled and clamped extra-hepatically and divided afterward during the transection; (3) Dissection of inferior vena cava (IVC) anterior wall behind the liver is started from caudal. Simultaneously, liver transection is performed to search right hepatic vein (RHV) from caudal; (4) Liver transection proceeds to the bifurcation of the vessels from caudal to cranial, exposing the surfaces of IVC and RHV. Since the remnant liver sinks down, the cutting surface is well-opened; and (5) After the completion of transection, dissection of the resected liver from

retroperitoneum is easily performed using the gravity. This approach was performed for a 63 years old woman with liver metastasis close to RHV.

RESULTS: RHV exposure is required for R0 resection of the lesion. Although the cutting plane is horizontal in supine position and the gravity obstructs the exposure in the small subphrenic space, the use of specific characteristics of laparoscopic hepatectomy, such as the good vision for the dorsal part of the liver and IVC and facilitated dissection using the gravity with the patient positioning, made the complete RHV exposure during the liver transection easy to perform. The operation time was 341 min and operative blood loss was 1356 mL. Her postoperative hospital stay was uneventful and she is well without any signs of recurrences 14 mo after surgery.

CONCLUSION: The new procedure is feasible and useful for the patients with tumors close to RHV and the need of the exposure of RHV.

© 2013 Baishideng. All rights reserved.

Key words: Laparoscopic hepatectomy; Posterior sectionectomy; Caudal approach; Right hepatic vein; Mobilization of the liver; Left lateral position

Tomishige H, Morise Z, Kawabe N, Nagata H, Ohshima H, Kawase J, Arakawa S, Yoshida R, Isetani M. Caudal approach to pure laparoscopic posterior sectionectomy under the laparoscopy-specific view. *World J Gastrointest Surg* 2013; 5(6): 173-177 Available from: URL: <http://www.wjgnet.com/1948-9366/full/v5/i6/173.htm> DOI: <http://dx.doi.org/10.4240/wjgs.v5.i6.173>

INTRODUCTION

In the 1990s and 2000s, when the procedure was first

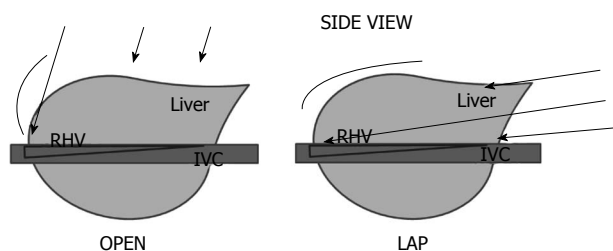


Figure 1 Differences in the view and approach between open and laparoscopic liver surgery. An illustration depicting the differences between the different surgery types. Since the view of operative field is in caudal-to-cranial direction in the laparoscopic procedure (LAP, right), not anterior-to-posterior (dorsal) as in the open procedure (OPEN, left), there is an advantage of good vision for the dorsal part of the liver and inferior vena cava. IVC: Inferior vena cava.

being used, laparoscopic hepatectomy mainly applied to local resections in antero-lateral segments of the liver^[1-3]; major hepatectomies were often performed using hand-assisted^[4-6] or hybrid^[7-10] procedures. However, there are increasing reports for anatomical resections with intra-hepatic^[11-14] and extrahepatic^[15] Glissonian approach and also of the right side liver^[16-19]. The laparoscopic Glissonian approach, resection with the control of Glissonian pedicle for the area not dissecting vessels, facilitates anatomical liver resection. However, the boundary plane between the anterior and posterior sectors of the liver, the cutting plane of posterior sectionectomy, is horizontal in supine position. Although the cutting plane should be well opened in the small subphrenic space for successful laparoscopic posterior sectionectomy, gravity obstructs the exposure of the cutting plane in the position of patients. Also, one of the advantages of laparoscopic hepatic surgery is a clear view for the surgeon from caudal and dorsal directions (Figure 1). We have developed a new procedure that facilitates the exposure of the cutting plane in pure laparoscopic posterior sectionectomy. Herein we describe a caudal approach with parenchymal transection prior to mobilization of the liver under the laparoscopy-specific view in the left lateral position.

MATERIALS AND METHODS

A 63-year-old woman was admitted to our hospital for the surgical resection of a 1.5 cm metachronous colorectal liver metastasis in segment six near the right hepatic vein. This procedure was performed for the patient under the permission of the patient with informed consent. The patient was placed in a left lateral position, in which the cutting plane turns to be vertical. The posterior sector was not mobilized and was fixed to the retroperitoneum. The Glissonian pedicle of the posterior sector was encircled and clamped extra-hepatically. A cutting line of the liver surface was defined by ischemic color change. Dissection of inferior vena cava (IVC) anterior wall behind the liver parenchyma was started from caudal. Simultaneously, liver parenchymal transection was performed to search the right hepatic vein (RHV) branch to the main trunk from caudal edge. Liver transection proceeded, exposing the surface of IVC and RHV, to cranial direction.

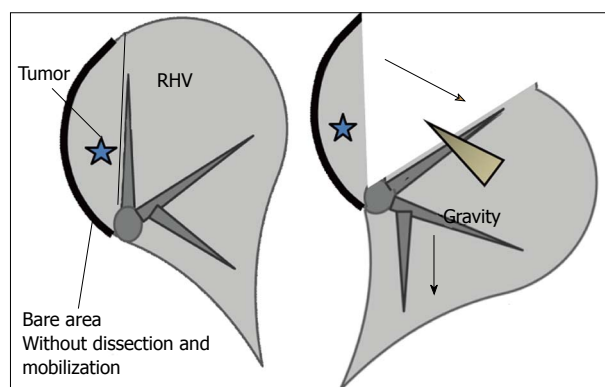


Figure 2 A schematic diagram of the caudal approach of pure laparoscopic posterior sectionectomy without mobilization under laparoscopy-specific view. Since the remnant liver sinks down and the resected liver is fixed to retroperitoneum, the cutting surface is well-opened and the exposure of right hepatic vein (RHV) is facilitated (arrow). Transection of the liver and exposure of the right hepatic vein, dividing its posterior branches one by one, proceed in one direction from caudal to cranial, simultaneously with the dissection of inferior vena cava anterior wall.

The Glissonian pedicle of the posterior sector was divided with a linear stapler during liver transection. Dissection of the IVC anterior wall and transection of the liver with the exposure of RHV simultaneously proceed to the bifurcation of RHV and IVC in one direction from caudal to cranial. Since the remnant liver sinks down and the resected liver was fixed to the retroperitoneum, the cutting surface was well opened and the exposure of RHV facilitated (Figure 2). Liver transection was completed at the point to reach to diaphragm. Dissection of the resected liver from the retroperitoneum was performed and the resected liver was removed. Dissection of the resected liver from the retroperitoneum was easily performed with the use of gravity.

RESULTS

A caudal approach to pure laparoscopic posterior sectionectomy was performed for a 63-year-old woman with a 1.5 cm metachronous colorectal liver metastasis in segment six near the right hepatic vein (Figure 3). She had undergone post-operative adjuvant chemotherapy after open colorectal surgery and her liver had severe fatty change. Although good surgical margins would be achieved with a right hepatectomy, the much smaller liver remnant could cause postoperative liver failure. Therefore, posterior sectionectomy was applied to her lesion. However, since the lesion was close to the RHV, RHV exposure was required for R0 resection of the lesion. Complete RHV exposure was performed during the liver transection, the operation time was 341 min, and operative blood loss was 1356 mL (Figure 4). Her postoperative hospital stay was uneventful and she is well without any signs of recurrences one year and two months after surgery.

DISCUSSION

Most reports of laparoscopic anatomical hepatectomy

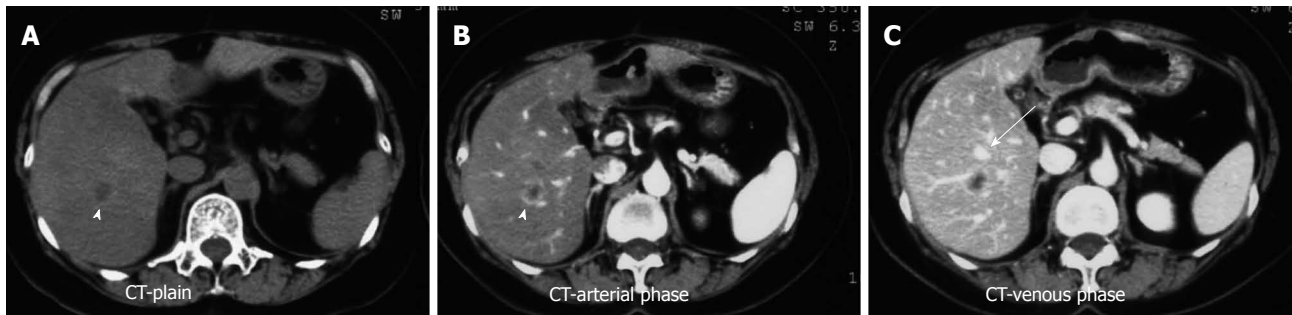

Figure 3 Computed tomography scan findings. A 63-year-old woman with a 1.5 cm metachronous colorectal liver metastasis in the segment 6 close to the right hepatic vein underwent adjuvant chemotherapy after open colorectal surgery and her liver had severe fatty change. Therefore, posterior sectionectomy was applied to her lesion, not right hepatectomy. However, since the lesion is close to the right hepatic vein (RHV), RHV exposure was required for R0 resection.

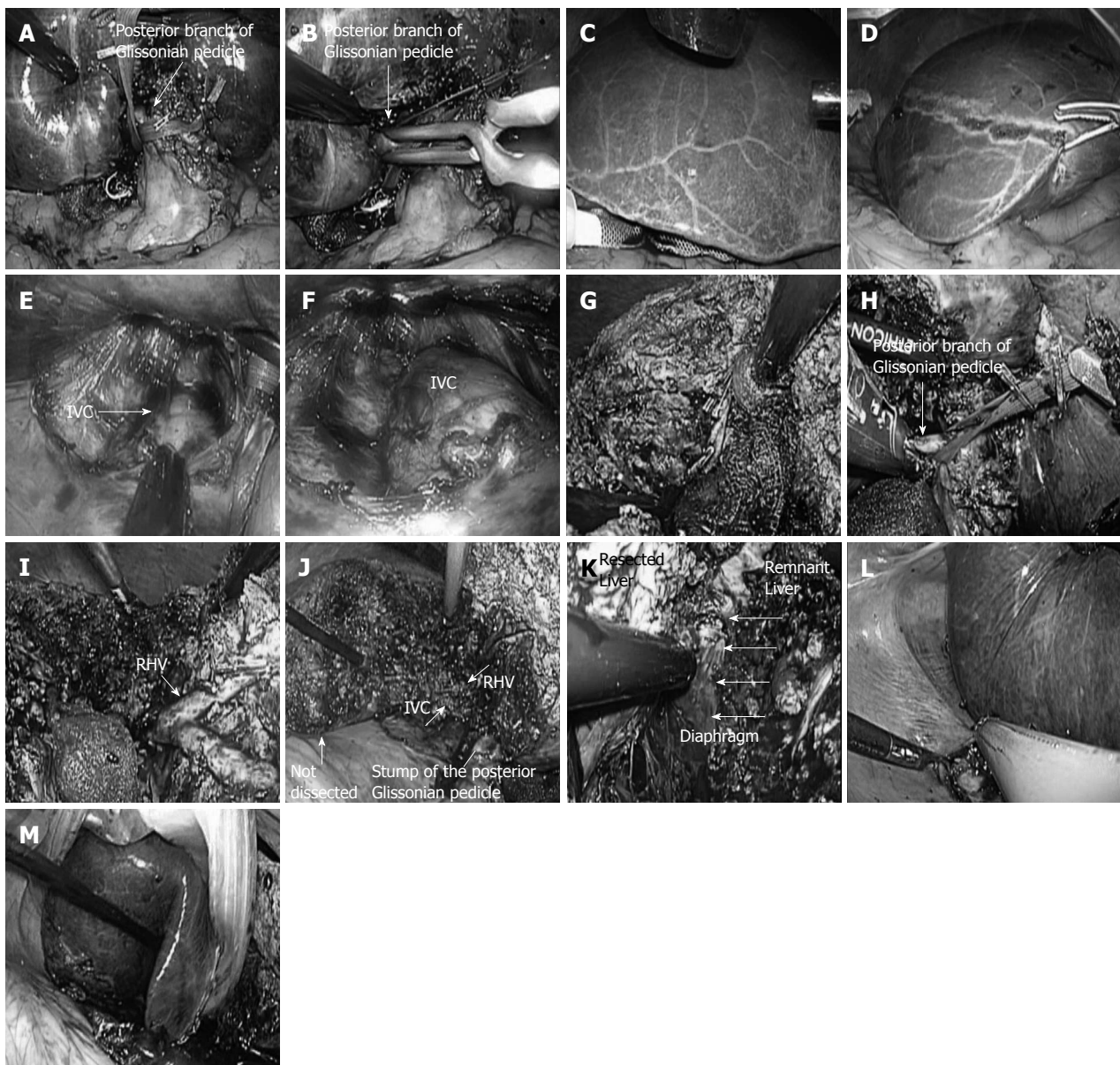


Figure 4 Intraoperative findings of the case. A-D: Part I; E-H: Part II; I, J: Part III; K-M: Part IV. After cholecystectomy, Glissonian pedicle of the right lobe and posterior sector was encircled (A). The posterior pedicle was clamped (B), allowing the resection line to be visualized as; an ischemic demarcation line (C, D). E, F: The anterior wall of the inferior vena cava was dissected behind the liver; G: Liver parenchyma was transected on the demarcation line, and the peripheral part of the right hepatic vein was exposed, clipped, and divided; H: After the cutting line reached the level of Glissonian, the posterior pedicle was divided with a linear stapler. Transection of the liver and the exposure of the right hepatic vein (RHV) by dividing its posterior branched one-by-one proceeded in one direction from caudal to

cranial, simultaneously with the dissection of the inferior vena cava anterior wall. Since remnants of the liver sunk down and the resected liver was fixed to the retroperitoneum, the cutting surface was well opened and the exposure of the RHV was facilitated. K: Following completion of the liver parenchymal transection; L: Dissection of the resected liver from retroperitoneum was performed; M: The resected liver was removed. Dissection of the resected liver from retroperitoneum was easily performed with the use of gravity. The operation time was 341 min and operative blood loss was 1356 mL. The patient's postoperative hospital stay was uneventful and she was well without any signs of recurrences one year and two months after surgery.

of the right lobe of the liver describe mobilization of the right liver as the first step in the procedure^[20-23]. Although Cheng *et al.*^[24] reported performing a posterior approach to laparoscopic anatomic resection hepatocellular carcinoma at segment seven; they also described the traditional mobilization of the right liver. We had experienced the challenge of exposing the cutting plane in pure laparoscopic posterior sectionectomy due to the direction of cutting plane, especially when exposure of the right hepatic vein was necessary. The cutting plane is horizontal the patient is in a supine position and gravity obstructs the exposure of the cutting plane in the small subphrenic space during laparoscopic surgery.

Here we presented a novel procedure whereby we considered the use of specific characteristics of laparoscopic hepatectomy. These characteristics included a clear view of the dorsal part of the liver and IVC created by a caudal-to-cranial operative field as opposed to the traditional anterior-to-posterior (dorsal) (Figure 1), and facilitated dissection using gravity and unique patient positioning^[25]. The operation time of this case was 341 min including the dissection of adhesion after open colorectal surgery and short and mid-term prognosis; an acceptable time for such a procedure. Although, the operative blood loss of 1356 mL is larger than some cases^[16,20,21,23,24], the total exposure of right hepatic vein main trunk may have influenced this in part, and this number should be decreased in the future with more experience. In conclusion, this new procedure, "caudal approach pure laparoscopic posterior sectionectomy with parenchymal transaction prior to mobilization of the liver under the laparoscopy-specific view", is feasible and useful for patients with tumors close to the RHV and when exposure of the RHV is necessary.

COMMENTS

Background

From the first report of laparoscopic hepatectomy in 1992, there are increasing experience worldwide and also of anatomical resections. However, the procedures and techniques are far from standardization and there are still tries to innovate the procedure.

Research frontiers

The cutting plane of posterior sectionectomy is horizontal in supine position. Although the cutting plane should be well-opened in the small subphrenic space for the successful laparoscopic posterior sectionectomy, the gravity obstructs the exposure of the cutting plane in the position. On the other hand, one of the advantages of laparoscopic hepatic surgery is a good vision from caudal and dorsal direction.

Innovations and breakthroughs

Here is figured out the novel procedure, caudal approach with parenchymal transection prior to mobilization of the liver under the laparoscopy-specific view in the left lateral position, which facilitates the exposure of cutting plane in laparoscopic posterior sectionectomy.

Applications

This reported new procedure is a feasible and useful innovative procedure for the patients with tumors close to right hepatic vein (RHV) and the need of the exposure of RHV.

Peer review

It is an interesting case report on a technically demanded new method of laparoscopic posterior approach for liver resection with nice operative views.

REFERENCES

- 1 Buell JF, Cherqui D, Geller DA, O'Rourke N, Iannitti D, Dagher I, Koffron AJ, Thomas M, Gayet B, Han HS, Wakabayashi G, Belli G, Kaneko H, Ker CG, Scatton O, Laurent A, Abdalla EK, Chaudhury P, Dutson E, Gamblin C, D'Angelica M, Nagorney D, Testa G, Labow D, Manas D, Poon RT, Nelson H, Martin R, Clary B, Pinson WC, Martinie J, Vauthey JN, Goldstein R, Roayaie S, Barlet D, Espat J, Abecassis M, Rees M, Fong Y, McMasters KM, Broelsch C, Busuttill R, Belghiti J, Strasberg S, Chari RS. The international position on laparoscopic liver surgery: The Louisville Statement, 2008. *Ann Surg* 2009; **250**: 825-830 [PMID: 19916210 DOI: 10.1097/SLA.0b013e3181b3b2d8]
- 2 Descottes B, Glineur D, Lachachi F, Valleix D, Paineau J, Hamy A, Morino M, Bismuth H, Castaing D, Savier E, Honore P, Detry O, Legrand M, Azagra JS, Goergen M, Ceuterick M, Marescaux J, Mutter D, de Hemptinne B, Troisi R, Weerts J, Dallemagne B, Jehaes C, Gelin M, Donckier V, Aerts R, Topal B, Bertrand C, Mansvelt B, Van Krunckelsven L, Herman D, Kint M, Totte E, Schockmel R, Gigot JF. Laparoscopic liver resection of benign liver tumors. *Surg Endosc* 2003; **17**: 23-30 [PMID: 12364994 DOI: 10.1007/s00464-002-9047-8]
- 3 Gigot JF, Glineur D, Santiago Azagra J, Goergen M, Ceuterick M, Morino M, Etienne J, Marescaux J, Mutter D, van Krunckelsven L, Descottes B, Valleix D, Lachachi F, Bertrand C, Mansvelt B, Hubens G, Saey JP, Schockmel R. Laparoscopic liver resection for malignant liver tumors: preliminary results of a multicenter European study. *Ann Surg* 2002; **236**: 90-97 [PMID: 12131090 DOI: 10.1097/0000658-200207000-00014]
- 4 Inagaki H, Kurokawa T, Yokoyama T, Konishi T, Kikuchi M, Yokoyama Y, Nonami T. Hand-assisted laparoscopic hepatectomy for tumors located in posterior segment. *Hepatogastroenterology* 2008; **55**: 1695-1698 [PMID: 19102372]
- 5 Huang MT, Lee WJ, Wang W, Wei PL, Chen RJ. Hand-assisted laparoscopic hepatectomy for solid tumor in the posterior portion of the right lobe: initial experience. *Ann Surg* 2003; **238**: 674-679 [PMID: 14578728 DOI: 10.1097/01.sla.0000094301.21038.8d]
- 6 Koffron AJ, Auffenberg G, Kung R, Abecassis M. Evaluation of 300 minimally invasive liver resections at a single institution: less is more. *Ann Surg* 2007; **246**: 385-392; discussion 392-394 [PMID: 17717442 DOI: 10.1097/SLA.0b013e318146996c]
- 7 Kawashita Y, Iwata T, Kanetaka K, Ono S, Kawahara Y, Fujisawa H, Yoshida T, Miyahara S, Eto S, Kanematsu T. Laparoscopy-assisted right hepatectomy in a case of Fasciola hepatica. *Surg Laparosc Endosc Percutan Tech* 2011; **21**: e54-e58 [PMID: 21304377 DOI: 10.1097/SLE.0b013e318200a263]
- 8 Cho A, Asano T, Yamamoto H, Nagata M, Takiguchi N, Kainuma O, Souda H, Gunji H, Miyazaki A, Nojima H, Ikeda A, Matsumoto I, Ryu M, Makino H, Okazumi S. Laparoscopic posterior sectionectomy for hepatocellular carcinoma: a retrospective analysis of 100 cases. *Surg Endosc* 2011; **25**: 100-105 [PMID: 21304377 DOI: 10.1097/SLE.0b013e318200a263]

- roscopy-assisted hepatic lobectomy using hilar Glissonean pedicle transection. *Surg Endosc* 2007; **21**: 1466-1468 [PMID: 17356935 DOI: 10.1007/s00464-007-9253-5]
- 9 **Koffron AJ**, Kung R, Baker T, Fryer J, Clark L, Abecassis M. Laparoscopic-assisted right lobe donor hepatectomy. *Am J Transplant* 2006; **6**: 2522-2525 [PMID: 16889605]
 - 10 **Eguchi D**, Nishizaki T, Ohta M, Ishizaki Y, Hanaki N, Okita K, Ohga T, Takahashi I, Ojima Y, Wada H, Tsutsui S. Laparoscopy-assisted right hepatic lobectomy using a wall-lifting procedure. *Surg Endosc* 2006; **20**: 1326-1328 [PMID: 16763923 DOI: 10.1007/s00464-005-0723-3]
 - 11 **Topal B**, Aerts R, Penninckx F. Laparoscopic intrahepatic Glissonian approach for right hepatectomy is safe, simple, and reproducible. *Surg Endosc* 2007; **21**: 2111 [PMID: 17479334 DOI: 10.1007/s00464-007-9303-z]
 - 12 **Machado MA**, Makdissi FF, Galvão FH, Machado MC. Intrahepatic Glissonian approach for laparoscopic right segmental liver resections. *Am J Surg* 2008; **196**: e38-e42 [PMID: 18614140 DOI: 10.1016/j.amjsurg.2007.10.027]
 - 13 **Machado MA**, Makdissi FF, Surjan RC, Herman P, Teixeira AR, C Machado MC. Laparoscopic resection of left liver segments using the intrahepatic Glissonian approach. *Surg Endosc* 2009; **23**: 2615-2619 [PMID: 19296173 DOI: 10.1007/s00464-009-0423-5]
 - 14 **Machado MA**, Makdissi FF, Surjan RC, Oliveira AC, Pilla VF, Teixeira AR. Intrahepatic Glissonian approach for laparoscopic right trisectionectomy. *J Laparoendosc Adv Surg Tech A* 2009; **19**: 777-778; discussion 777-778 [PMID: 19961367 DOI: 10.1089/lap.2009.0162]
 - 15 **Rotellar F**, Pardo F, Benito A, Martí-Cruchaga P, Zozaya G, Pedano N. A novel extra-glissonian approach for totally laparoscopic left hepatectomy. *Surg Endosc* 2012; **26**: 2617-2622 [PMID: 22447286 DOI: 10.1007/s00464-012-2242-3]
 - 16 **Costi R**, Capelluto E, Sperduto N, Bruyns J, Himpens J, Cadière GB. Laparoscopic right posterior hepatic bisegmentectomy (Segments VII-VIII). *Surg Endosc* 2003; **17**: 162 [PMID: 12384767]
 - 17 **Andoh H**, Sato T, Yasui O, Shibata S, Kurokawa T. Laparoscopic right hemihepatectomy for a case of polycystic liver disease with right predominance. *J Hepatobiliary Pancreat Surg* 2004; **11**: 116-118 [PMID: 15127274 DOI: 10.1007/s00534-003-0845-8]
 - 18 **Ishizawa T**, Gumbs AA, Kokudo N, Gayet B. Laparoscopic segmentectomy of the liver: from segment I to VIII. *Ann Surg* 2012; **256**: 959-964 [PMID: 22968066 DOI: 10.1097/SLA.0b013e31825ffed3]
 - 19 **Yoon YS**, Han HS, Cho JY, Kim JH, Kwon Y. Laparoscopic liver resection for centrally located tumors close to the hilum, major hepatic veins, or inferior vena cava. *Surgery* 2013; **153**: 502-509 [PMID: 23257080 DOI: 10.1016/j.surg.2012.10.004]
 - 20 **Han HS**, Yoon YS, Cho JY, Ahn KS. Laparoscopic right hemihepatectomy for hepatocellular carcinoma. *Ann Surg Oncol* 2010; **17**: 2090-2091 [PMID: 20397056 DOI: 10.1245/s10434-010-1066-4]
 - 21 **Cho JY**, Han HS, Yoon YS, Shin SH. Outcomes of laparoscopic liver resection for lesions located in the right side of the liver. *Arch Surg* 2009; **144**: 25-29 [PMID: 19153321 DOI: 10.1001/archsurg.2008.510]
 - 22 **Nitta H**, Sasaki A, Fujita T, Itabashi H, Hoshikawa K, Takahara T, Takahashi M, Nishizuka S, Wakabayashi G. Laparoscopy-assisted major liver resections employing a hanging technique: the original procedure. *Ann Surg* 2010; **251**: 450-453 [PMID: 20083994 DOI: 10.1097/SLA.0b013e3181cf87da]
 - 23 **Cho JY**, Han HS, Yoon YS, Shin SH. Feasibility of laparoscopic liver resection for tumors located in the posterosuperior segments of the liver, with a special reference to overcoming current limitations on tumor location. *Surgery* 2008; **144**: 32-38 [PMID: 18571582 DOI: 10.1016/j.surg.2008.03.020]
 - 24 **Cheng KC**, Yeung YP, Hui J, Ho KM, Yip AW. Multimedia manuscript: laparoscopic resection of hepatocellular carcinoma at segment 7: the posterior approach to anatomic resection. *Surg Endosc* 2011; **25**: 3437 [PMID: 21667209 DOI: 10.1007/s00464-011-1685-2]
 - 25 **Ikeda T**, Yonemura Y, Ueda N, Kabashima A, Shirabe K, Taketomi A, Yoshizumi T, Uchiyama H, Harada N, Ijichi H, Kakeji Y, Morita M, Tsujitani S, Maehara Y. Pure laparoscopic right hepatectomy in the semi-prone position using the intrahepatic Glissonian approach and a modified hanging maneuver to minimize intraoperative bleeding. *Surg Today* 2011; **41**: 1592-1598 [PMID: 21969190 DOI: 10.1007/s00595-010-4479-6]

P- Reviewers Morris DL, Pavlidis TE

S- Editor Huang XZ L- Editor A E- Editor Lu YJ

