

## Hepatic applications of endoscopic ultrasound: Current status and future directions

Indu Srinivasan, Shou-Jiang Tang, Andreas S Vilmann, John Menachery, Peter Vilmann

Indu Srinivasan, Shou-Jiang Tang, Division of Digestive Diseases, Department of Medicine, University of Mississippi Medical Center, Jackson, MS 39216, United States

Andreas S Vilmann, Peter Vilmann, Department of Surgical Gastroenterology, Copenhagen University Hospital Herlev, 2730 Herlev, Denmark

John Menachery, Department of Gastroenterology, Rajagiri Hospital Aluva, Kerala 683112, India

**Author contributions:** All authors were involved in the planning the design and conduct of the review paper; Srinivasan I initial research was conducted; Srinivasan I and Tang SJ were involved in drafting the manuscript; all the authors then contributed equally in revising the manuscript and approving the final version.

**Conflict-of-interest statement:** No potential conflicts of interest relevant to this article were reported.

**Open-Access:** This article is an open-access article which was selected by an in-house editor and fully peer-reviewed by external reviewers. It is distributed in accordance with the Creative Commons Attribution Non Commercial (CC BY-NC 4.0) license, which permits others to distribute, remix, adapt, build upon this work non-commercially, and license their derivative works on different terms, provided the original work is properly cited and the use is non-commercial. See: <http://creativecommons.org/licenses/by-nc/4.0/>

**Correspondence to:** Peter Vilmann, MD, DSc, HC, FASGE, Department of Surgical Gastroenterology, Copenhagen University Hospital Herlev, Nørregade 10, Herlev 2730, Denmark. [peter.vilmann@regionh.dk](mailto:peter.vilmann@regionh.dk)  
Telephone: +45-38-682164

Received: May 8, 2015  
Peer-review started: May 11, 2015  
First decision: September 11, 2015  
Revised: September 28, 2015  
Accepted: October 12, 2015  
Article in press: October 13, 2015  
Published online: November 28, 2015

### Abstract

The diagnosis and staging of various gastrointestinal malignancies have been made possible with the use of endoscopic ultrasound, which is a relatively safe procedure. The field of endoscopic ultrasound is fast expanding due to advancements in therapeutic endoscopic ultrasound. Though various studies have established its role in gastrointestinal malignancies and pancreatic conditions, its potential in the field of hepatic lesions still remains vastly untapped. In this paper the authors attempt to review important and landmark trials, case series and case studies involving hepatic applications of endoscopic ultrasound, thus not only providing an overview of utilization of endoscopic ultrasound in various liver conditions but also speculating its future role.

**Key words:** Endoscopic ultrasound; Drainage; Liver; Intrahepatic lesion

© **The Author(s) 2015.** Published by Baishideng Publishing Group Inc. All rights reserved.

**Core tip:** To review the available published trials, case series and case reports, discuss the implications and the future role of endoscopic ultrasound in the management of various liver conditions. Through this review paper we aim to provide a unified one stop educational experience as we have attempted to amalgamate all the published data.

Srinivasan I, Tang SJ, Vilmann AS, Menachery J, Vilmann P. Hepatic applications of endoscopic ultrasound: Current status and future directions. *World J Gastroenterol* 2015; 21(44): 12544-12557 Available from: URL: <http://www.wjgnet.com/1007-9327/full/v21/i44/12544.htm> DOI: <http://dx.doi.org/10.3748/wjg.v21.i44.12544>

## INTRODUCTION

Since the initial description of endoscopic ultrasonography (EUS) in 1980's, EUS has become an indispensable method not only in diagnosing various gastrointestinal (GI) lesions but also in performing various therapeutic maneuvers<sup>[1-4]</sup>. It was the limitations imposed by standard ultrasonography that prompted the development of EUS. By placing the ultrasound transducer within the body, interposed air filled or bony structures could be avoided and simultaneously by reducing the distance it became feasible to adequately visualize deeper structures. The method is basically an endoscopy with ultrasound at the tip which helps to visualize not only the GI tract but also produce images of nearby structures such as the gall bladder and bile ducts, pancreas, liver, *etc.* Echoendoscopes are designed using either a radial or curvilinear array system<sup>[1]</sup>. Radial endosonography provides a high-resolution, 360 degrees circumferential imaging of the GI tract and its surrounding structures. However, it does not allow for fine needle aspiration (FNA), thus making way for development of the linear echoendoscope enabling FNA of lesions both within and adjacent to GI tract<sup>[2,3]</sup>. This ability is the cornerstone of interventional EUS and the method has been proven safe and reliable in diagnosing various benign and malignant conditions in the upper and lower GI tract as well as the mediastinum<sup>[3,4]</sup>. When compared with other techniques EUS-FNA has demonstrated improved accuracy and cost effectiveness. This was especially well demonstrated in pancreatic lesions and malignant tumors of the esophagus<sup>[3,4]</sup>.

Till late 1990's the role of EUS in evaluating hepatic lesions was only described in a few case studies<sup>[5]</sup> but the case series by Nguyen *et al.*<sup>[6]</sup> paved the way. They theorized that close proximity of the transducer to lesions coupled with clear visualizations and accessibility of the left lobe and central segments of the liver should facilitate the use of EUS in hepatic lesions. Since EUS-FNA was first reported in 1992<sup>[2]</sup>, we have seen a tremendous growth of interventional EUS with various innovations such as EUS guided tru-cut biopsy, tumor ablative therapy, vascular interventions, and various transmural drainage procedures. However, though case series have been described limited trials advocating the use of EUS for liver lesions have been published and there are no dedicated guidelines establishing the role of EUS in hepatic applications at present. The aims of this review are to summarize the published reports on hepatic applications of EUS and to speculate on its future roles.

## ANATOMICAL DESCRIPTION OF THE LIVER

The adjacent organs next to the liver include the stomach and duodenum (Figure 1). The liver has a dual blood supply with the portal vein (formed

by the confluence of superior mesenteric vein and splenic vein) and the hepatic artery (branch of celiac artery). These vessels terminate at porta hepatis by dividing into right and left liver branches which undergo secondary and tertiary divisions to supply the various segments. Right, middle and left hepatic veins formed by the union of intersegmental collecting veins open into the inferior vena cava (IVC). The liver can subsequently be divided into 8 segments that are served independently by a secondary or tertiary branch of the portal triad. The caudate lobe is considered to be separate as it is supplied by both branches of the portal vein and drains independently into the IVC via hepatic veins. It is located posteriorly and considered to be segment one. The rest of the liver is divided by the main portal fissure hosting the middle hepatic vein which extends from the fundus of the gall bladder to the IVC. The left hepatic vein divides the left lobe into lateral (2, 3) and medial (4a, 4b) segments. The right hepatic vein divides the right lobe into anterior (5, 8) and posterior (6, 7) segments. The portal vein divides the liver into upper (2, 4a, 8, 7) and lower (3, 4b, 5, 6) segments. The segments are labeled in a clockwise manner. In a normal frontal view segments 1, 6 and 7 are not visible.

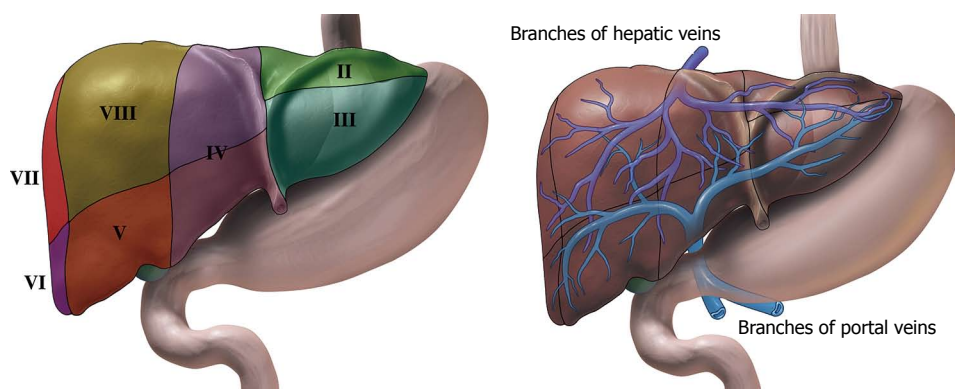
## VISUALIZATION OF THE LIVER BY EUS

With currently available echoendoscopes, both mechanical and electronic transducers can scan over a range of frequencies ranging between 5 to 20 MHz. Scanning at higher frequencies improves image resolution but limits the penetration of the ultrasound beam to 1 to 2 cm from the probe, whereas scanning with lower frequency provides images of structures up to 6 to 8 cm from the probe. In 1986, Rifkin *et al.*<sup>[7]</sup> incorporated 9 MHz electronic transducer on to a traditional fiber optic gastro scope and concluded that it had a better resolution than 0.5 mm.

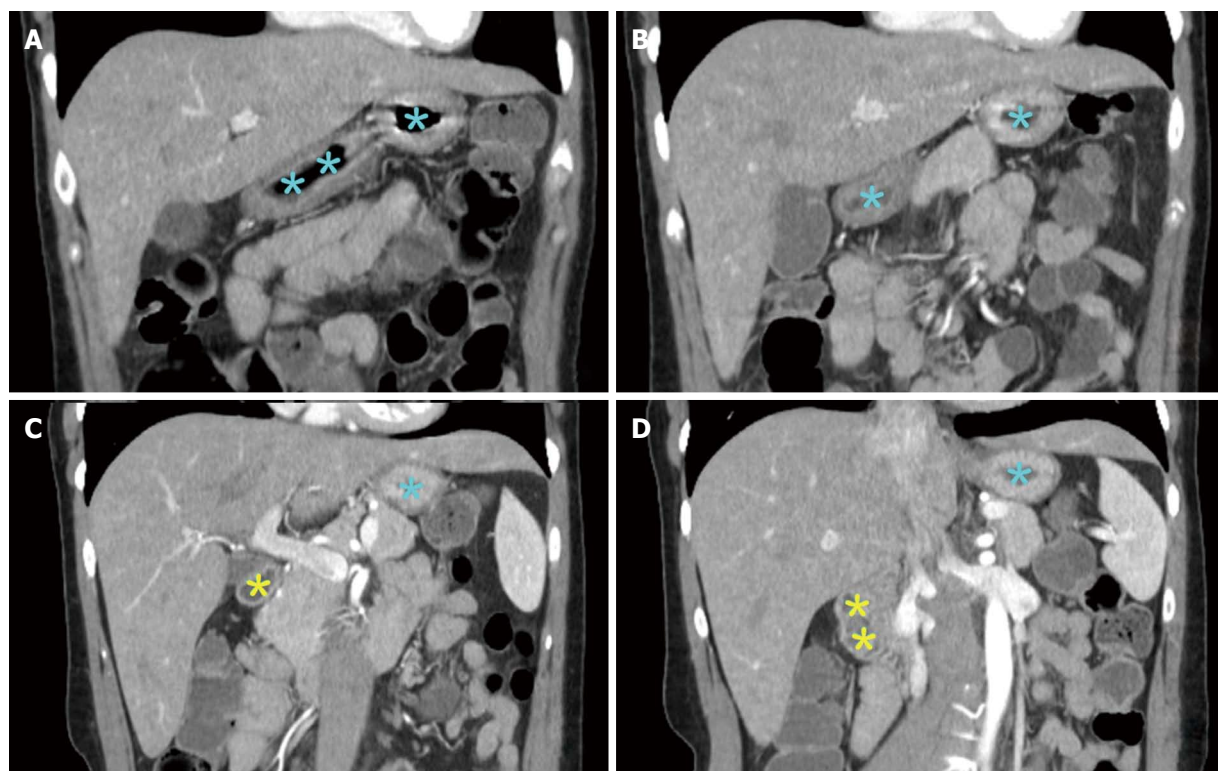
Both the left lobe and caudate lobe lie in close proximity to the stomach and duodenum, hence providing an easy access during EUS (Figures 2 and 3). The caudate lobe and gastrohepatic space can be accessed by EUS while these are anatomically more difficult to approach by trans-abdominal ultrasound. EUS is limited in its ability to access the portion of the right lobe adjacent to the dome of the diaphragm along with its lateral and inferior portions. In spite of this, most of the right lobe is visible from the duodenum as well as the portal hilum with its structures.

## PubMed SEARCH

On December 20<sup>th</sup>, 2014, the authors performed PubMed search using these key word sets: EUS in combination with hepatic lesion, hepatic application, hepatic intervention, hepatocellular carcinoma, and hepaticogastrostomy (HGS). The inclusion criteria are: (1) english language publications only; (2) EUS



**Figure 1** Illustrations of liver and its surrounding stomach and duodenum. A: The liver can subsequently be divided into 8 segments that is served independently by a secondary or tertiary branch of the portal triad. B: The left hepatic vein divides the left lobe into lateral (II2, III3) and medial (IV4a, IV4b) segments. The right hepatic vein divides the right lobe into anterior (V5, VIII8) and posterior (VI6, VII7) segments. The portal vein divides the liver into upper (II2, IV4a, VIII8, VII7) and lower (III3, IV4b, V5, VI6) segments. The segments are labeled in a clockwise manner. In a normal frontal view segments I1, VI6 and VII7 are not visible.



**Figure 2** Selected computerized tomography scan images showing the liver and its surrounding stomach and duodenum. Both the left lobe and caudate lobe lie in close proximity to stomach (blue colored asterisk indicated gastric lumen) and duodenum (yellow colored asterisk indicated bulb and duodenal lumen), hence providing an easy access during endoscopic ultrasonography (EUS). The caudate lobe and gastrohepatic space can be accessed by EUS while are anatomically difficult to approached by trans-abdominal ultrasound. EUS is limited in its ability to access the portion of the right lobe adjacent to the dome of the diaphragm along with its lateral and inferior portions.

is utilized; and (3) case report, series, clinical studies, potential hepatic applications in animal models, reviews on this topic. The authors excluded reports about EUS utilization in extrahepatic bile duct, gallbladder, and other extrahepatic structures except in management and diagnosis of complications of portal hypertension. We also excluded intraductal EUS application. Each published paper was reviewed and only important information was extracted for this review. Initial search yielded 731 articles out of which 584 were discarded as they did not meet the inclusion criteria. Please refer

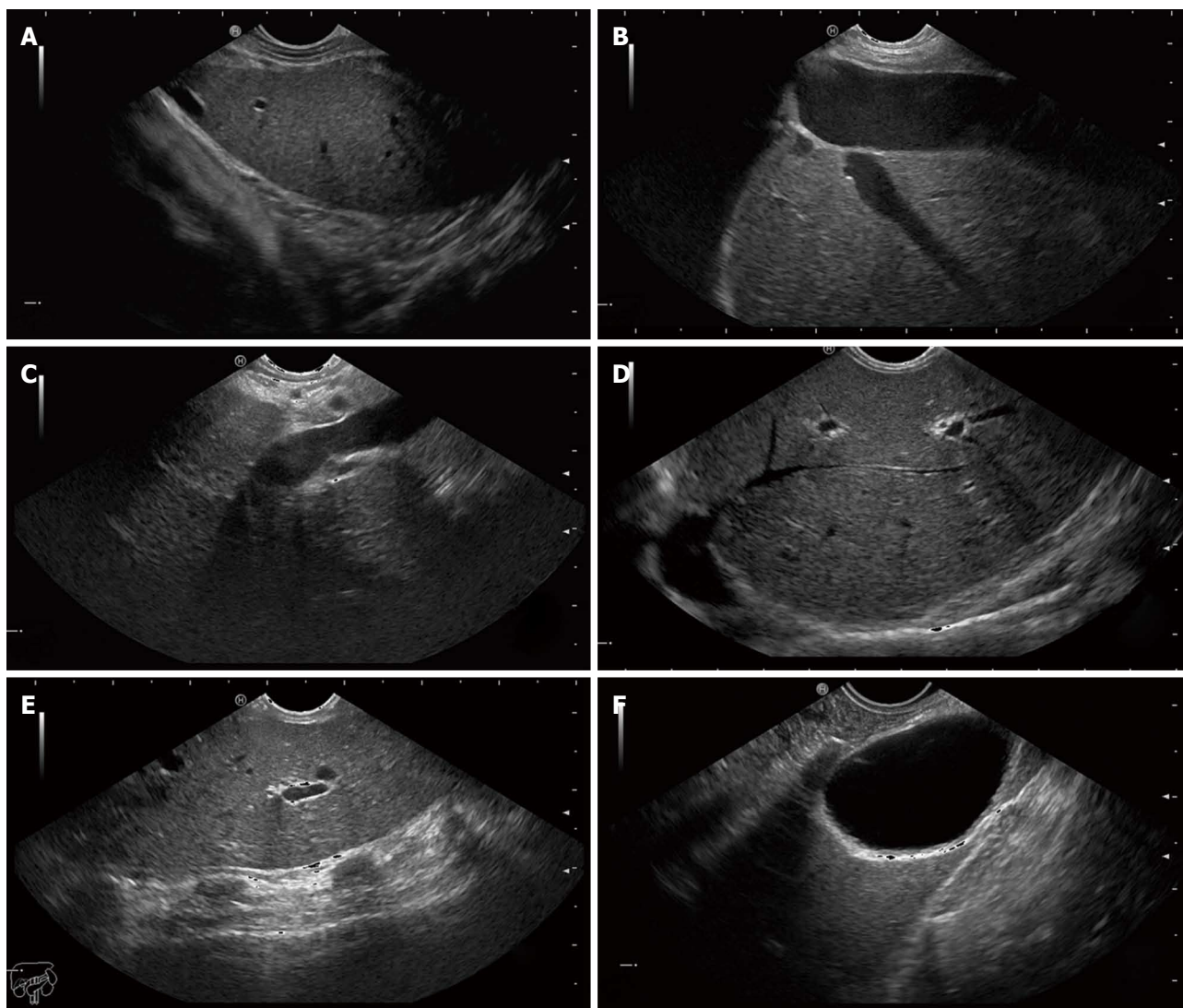
to the attached PubMed result search flow sheet for further details (Figure 4).

## ROLES OF EUS IN THE EVALUATION OF HEPATIC LESIONS

### Focal liver lesions

**Diagnostic EUS:** Focal liver lesions include both benign (such as hepatic cysts, abscess, adenoma or hemangioma) and malignant (such as hepatocellular

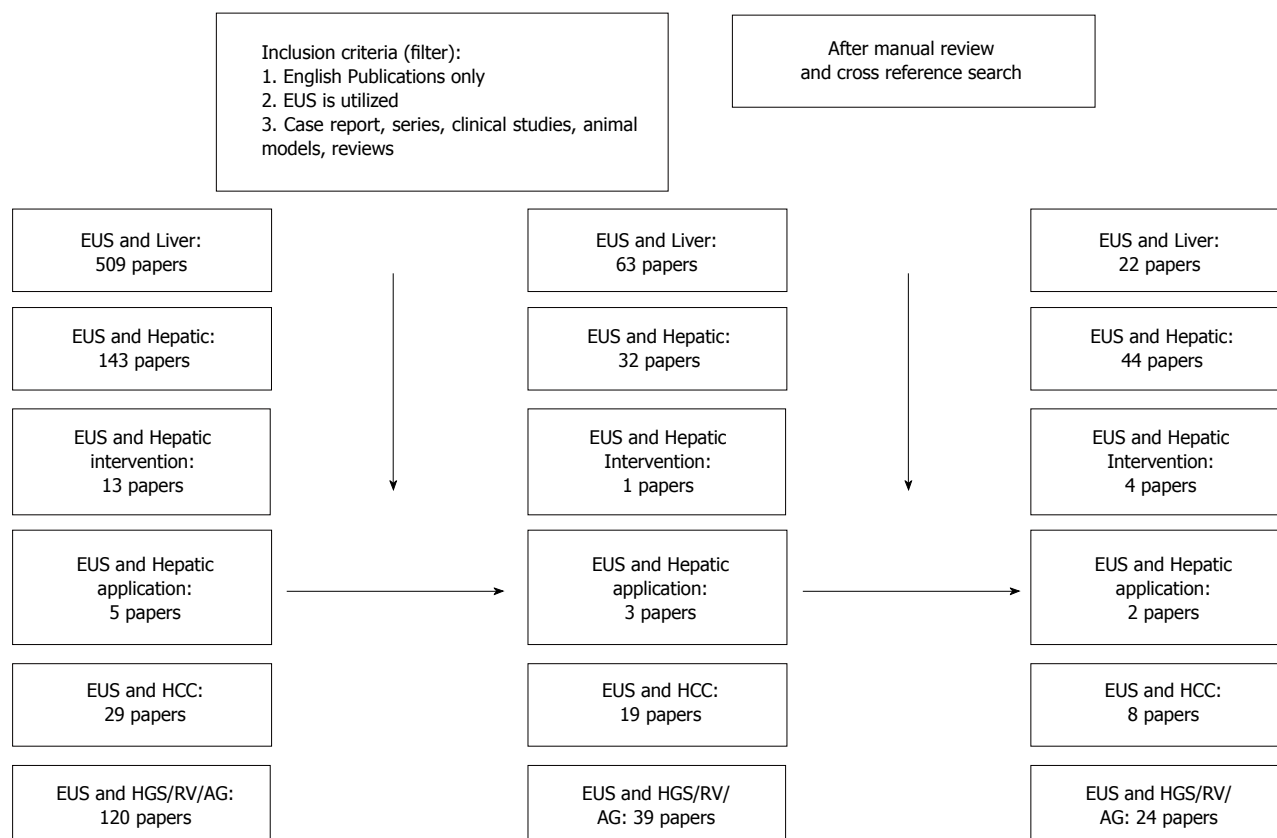




**Figure 3** Endoscopic ultrasound images of the hepatic structures with the tip of the linear echoendoscope at different positions. A: Endoscopic ultrasound (EUS) image of the left liver lobe with the diaphragm. The image is obtained from the cardia region; B: EUS image of the left liver lobe with the inferior vena cava and a hepatic vein; C: EUS image of the liver at the portal ligament region showing from the transducer, the hepatic artery, the portal vein and a short segment of the common bile duct. The transducer is located in the stomach; D: EUS image of the liver looking over the hepatic dome; E: EUS image of the right hepatic lobe. Note the shadows from the ribs at the anterior abdominal wall; F: EUS image of the liver with the gall bladder. The transducer is located in the first part of the duodenum.

carcinoma, intrahepatic cholangiocarcinoma, biliary cystadenoma, and metastatic liver disease) lesions (Figure 5 and Table 1). These lesions were most often diagnosed by either abdominal imaging or by percutaneous tissue diagnosis. The last 15 to 20 years have seen rapid advancements in the applicability of EUS, especially combined with FNA cytology. Studies<sup>[8,9]</sup> have not only established its efficacy in evaluating intra-abdominal lesions but in also staging<sup>[10]</sup> of various GI tumors. However it was not till 1999<sup>[5]</sup> when EUS was used for clinical imaging of the liver. Studies<sup>[11,12]</sup> comparing intraoperative ultrasound to preoperative computed tomography (CT) scan and magnetic resonance imaging (MRI) had proven it to be superior owing to the proximity of the ultrasound probe to the liver parenchyma and the use of color flow Doppler - hence the idea of EUS for liver lesions was considered. Nguyen *et al*<sup>[6]</sup> evaluated the

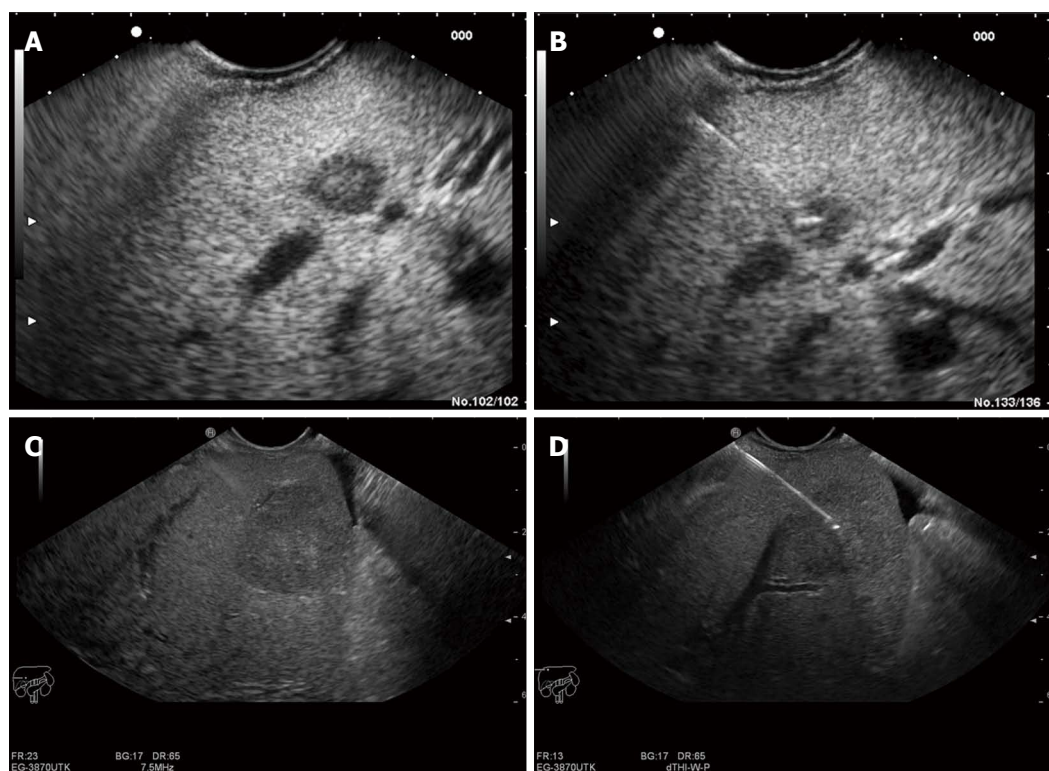
liver in 574 consecutive patients undergoing upper EUS examination for suspicion or history of GI or pulmonary tumor: 15 liver lesions were identified (5 were in the right lobe and 9 were in the left lobe) and underwent EUS-FNA, 14 of them were found to be malignant (one of the patients underwent FNA of two lesions as the first lesion revealed normal cytology). Surprisingly CT scan done prior to EUS identified only 3 of these liver lesions: 12 of the 15 lesions were less than 2 cm. Thus EUS became recognized as a modality to help detect small focal liver lesions. This was also demonstrated by a retrospective study reported by Prasad *et al*<sup>[13]</sup> where in liver lesions as small as 5 mm not seen by previously conducted noninvasive imaging were detected by EUS. The detection of metastatic disease is particularly important as it influences management of these patients. It is important to realize that EUS is a semi-invasive test



**Figure 4 PubMed result search flow sheet.** PubMed search was performed on December 20, 2014. EUS: Endoscopic ultrasound; HCC: Hepatocellular carcinoma; HGS: Hepaticogastrostomy.

with complications. Two patients in this study had duodenal injury. Hence, though the data appears promising more studies are needed to compare the risk benefit ratio and to establish a protocol for detection of liver masses. Awad *et al*<sup>[14]</sup> then evaluated 14 consecutive patients with a history of a known liver mass. They underwent both dynamic CT scan and EUS. EUS not only identified the lesions in all the 14 patients but it also recognized 4 new lesions smaller than 0.5 cm which had not been visualized by CT scan. In 2002 Tenberge *et al*<sup>[15]</sup> published a retrospective study wherein they sent a questionnaire to EUS-FNA centers around the world. Out of the 130 centers, 21 of them reported 167 cases of EUS-FNA of the liver with a complication rate of only 4%. Further, it helped to diagnose malignancy in cases of non-diagnostic FNA obtained under trans-abdominal ultrasound and localize primary tumor in cases where CT only reported liver metastasis. Thus the authors concluded that EUS-FNA of the liver was a safe procedure which should be considered in case the lesion is not accessible by trans-abdominal ultrasound or CT or when FNA is non diagnostic by these methods or when a liver lesion is detected during routine EUS. As described in the anatomy section EUS provides good visualization of the left hepatic lobe and EUS-FNA of liver lesions may provide important management information especially in case of detection of metastasis or hepatocellular

carcinoma. Further it is hypothesized that in patients with cirrhosis percutaneous biopsy may be difficult owing to presence of ascites and coagulopathy. In such cases EUS may be a safer option as the transducer is only 1.5-3 cm away from the lesion and biopsy occurs under EUS guidance. A retrospective study<sup>[16]</sup> of 77 patients who underwent EUS FNA of various solid liver lesions helped to detect malignancy in 41% of patients who had previously had negative examination. This was the first study to include both malignant and benign lesions. They concluded that sensitivity of diagnosing malignancy ranged from 82% to 94% (7 patients from the nonmalignant group died without follow up imaging, biopsy or autopsy and hence could not be classified) and this group did not have any complications. The presence of two or more lesions with regular outer margins is more indicative of a malignant lesion. In a prospective study by Hollerbach *et al*<sup>[17]</sup> EUS-FNA provided appropriate biopsy specimen in 40/41 patients with an average of 1.4 needle passes. On combining both histological and cytological examination of the specimens they had a sensitivity of 94% and a specificity of 100% with a low 2.5% rate of minor complication. A Fritscher-Ravens *et al*<sup>[18]</sup> reported a case series of 10 patients with a biliary stricture at the hepatic hilum who underwent EUS-FNA. In 9/10 patients' adequate specimens were obtained and 8 of these lesions were found to be malignant



**Figure 5** Endoscopic ultrasound image of lesion in the liver. A: Endoscopic ultrasound (EUS) image of an 8 mm metastatic lesion in the liver; B: Endoscopic ultrasound (guided biopsy from the same lesion; C: EUS image of a 25 mm lesion in the liver; D: EUS guided aspiration biopsy from the same lesion.

but one lesion was falsely identified as benign. This study highlights an important implication of EUS as various advances are being made in the management of cholangiocarcinoma, thus it is imperative that we have not only have accurate diagnosis but also stage the disease adequately. Studies so far have revealed that brush cytology from endoscopic retrograde cholangiopancreatography (ERCP) has variable sensitivity. Ryan<sup>[19]</sup> reported a sensitivity of only 44% while Glasbrenner *et al*<sup>[20]</sup> reported a sensitivity of 80%. Subsequently Crowe *et al*<sup>[21]</sup> in 2006 compared 34 percutaneous CT-FNA liver biopsies to 16 EUS-FNA liver biopsies and concluded that though they were comparable in terms of diagnostic utility for hepatic lesions, EUS was limited in its ability to access the portion of the right lobe adjacent to the dome of the diaphragm along with its lateral and inferior portions. Thus, EUS is an important tool to use in adjunction with other noninvasive imaging methods to not only detect occult metastasis but also to diagnose focal malignant lesions more so in the left hepatic lobe.

More recently, EUS elastography used for visualization of tissue elasticity during routine EUS<sup>[22]</sup> is an upcoming modality for diagnosing focal liver lesions. It is based on the same principle of trans-abdominal elastography but it offers an additional advantage of comparing the echoes over several seconds of normal breathing and blood circulation thus overcoming the need for applying manual pressure. This technique was utilized by Rustemovic *et al*<sup>[23]</sup> in diagnosis of focal liver masses. Since the malignant tumor tissue is harder

than benign tumors, efforts have been made to utilize this modality in differentiating benign from malignant tumors. This principle was already established in other tumors such as prostate<sup>[24]</sup>, pancreas<sup>[25]</sup> and breast<sup>[26]</sup>. In 2008 Kato *et al*<sup>[27]</sup> established that intraoperative usage of real time elastography could help distinguish between HCC and metastases by dividing the tumors into four different types based on elasticity. In 2012, Sandulesco *et al*<sup>[28]</sup> published a pilot study using real time sonography to differentiate focal liver lesions and concluded that the sensitivity, specificity, and accuracy of differentiation of benign and malignant masses were 92.5%, 88.8%, and 88.6%, respectively. Hara *et al*<sup>[29]</sup> described a novel approach to assess vascular invasion at the hepatic hilum by using the linear scanning which they postulated had a superior visualization of abdominal vessels than radial scanning.

**Therapeutic EUS in focal liver lesions:** More recently there are case reports pushing the frontiers of EUS from being just a diagnostic tool to one with therapeutic benefits. EUS guided ethanol injection in treatment of hepatic metastasis was first described in 2002<sup>[30]</sup>. Since then few more cases<sup>[31-33]</sup> have been reported but unfortunately there are no long term data or larger case series to draw any significant conclusions. In 2011 Di Matteo *et al*<sup>[34]</sup> described the use of Nd: YAG laser ablation of hepatocellular carcinoma in the caudate lobe. More recently fiducial placement for stereotactic body radiation under EUS guidance for hepatic and pancreatic malignancies was

**Table 1** Reported diagnostic yields of endoscopic ultrasound guided fine needle aspiration of hepatic solitary lesions

Ref.	Patient number/lesion sampled	Diagnostic yields
Nguyen <i>et al</i> <sup>[6]</sup>	574/15	CT before EUS depicted liver lesions in 3 of the 14 patients (21%)
Awad <i>et al</i> <sup>[14]</sup>	14/9	EUS identified additional lesions in 28% of the patients and changed clinical management in 67% of the patients
TenBerge <i>et al</i> <sup>[15]</sup>	167/167	EUS-FNA diagnosed malignancy in 89% of cases after non diagnostic FNA under trans abdominal US guidance
DeWitt <i>et al</i> <sup>[16]</sup>	77/77	45 (58%) were diagnostic for malignancy, 25 (33%) were benign and seven (9%) were non diagnostic. EUS detected malignancy in 41% of patients with previously negative exam
Hollerbach <i>et al</i> <sup>[17]</sup>	41/41	With combination of histological and cytological examination sensitivity and specificity for detecting malignancy was 94% and 100%
Prasad <i>et al</i> <sup>[13]</sup>	222/21	Diagnostic of malignancy in 15 (6.8%) 5 of whom (2.3%) had normal imaging prior
Crowe <i>et al</i> <sup>[21]</sup>	50/16	Diagnostic of malignancy in 56% of the cases, comparable to CT scan
McGrath <i>et al</i> <sup>[105]</sup>	98/5	The sensitivity of EUS-FNA for liver lesions was 80%. These lesions were not evident on prior noninvasive imaging
Singh <i>et al</i> <sup>[106]</sup>	132/26	The diagnostic accuracy of EUS/EUS-FNA and CT scan was 98% and 92% respectively

EUS: Endoscopic ultrasonography; FNA: Fine needle aspiration; CT: Computed tomography.

reported<sup>[35]</sup>.

### Hepatic cysts

With the increasing imaging using ultrasound and CT scan, simple hepatic cysts are now routinely detected in 2.5%-7% of the population<sup>[36]</sup>. In majority of the time they are asymptomatic and need no further treatment. Only 10%-16% of such cysts are producing symptoms such as abdominal pain, hepatomegaly, early satiety, bile duct compression necessitating the need for treatment. Traditionally a surgical approach (complete cyst excision or fenestration of cyst) or percutaneous aspiration were the modalities used to treat large symptomatic hepatic cysts. Percutaneous aspiration is associated with a recurrence rate of nearly 100% in 2 years<sup>[37]</sup>. In 1985 Bean and Rodan<sup>[38]</sup> described successful percutaneous aspiration of 6 hepatic cysts followed by sclerotherapy with alcohol. No recurrence was noted during a 6-18 mo follow up period. These authors concluded that alcohol caused cellular destruction followed by fibrotic obliteration of the cysts. Since then multiple studies have established the efficacy of percutaneous aspiration with sclerotherapy. Lee *et al*<sup>[39]</sup> conducted a retrospective study where he hypothesized that EUS guided aspiration and lavage therapy without a percutaneous drainage catheter, would enable it to be performed in a single step. A total of 17 patients with 19 hepatic cysts were enrolled with a median cysts volume of 368.9 mL. Ten cysts were drained by a percutaneous approach and 8 cysts underwent EUS guided aspiration and lavage treatment. In a 15-mo follow up the EUS guided group showed 100% reduction. The authors concluded that EUS guided drainage was a safe method for left sided hepatic cysts while percutaneous catheter drainage is preferred for large right sided cysts.

### Hepatic abscesses

Hepatic abscesses are collections of infected materials in the parenchyma which usually develop directly from

the biliary tree or from extension of intra-abdominal infection or hematogenously from bacteremia. Conventionally hepatic abscesses have been treated with either surgical or percutaneous drainage<sup>[40,41]</sup>. Owing to high morbidity and mortality (almost 32%) associated with surgical drainage<sup>[40,41]</sup>, percutaneous drainage with success rates of 80%-100% has emerged as the first line of therapy<sup>[42]</sup>. Unfortunately this is also associated with certain side effects<sup>[43]</sup> such as injury to surrounding vascular structures, intraperitoneal bleeding, hepato-venous fistula<sup>[44]</sup> and patient discomfort due to external drainage. EUS guided hepatic abscess drainage<sup>[45]</sup> was suggested as an alternative to overcome some of the complications. As described before, both the left lobe and caudate lobe lie in close proximity to the stomach and duodenum, hence providing an easy access during EUS. In 2005 Seewald *et al*<sup>[45]</sup> described a case report of a large hepatic abscess in the lateral segments of the left lobe that did not resolve with one week of intravenous antibiotic therapy. The authors performed EUS guided transgastric drainage of the hepatic abscess. At 6 mo follow up the patient still remained asymptomatic. In 2010 Noh *et al*<sup>[46]</sup> described a case series of three hepatic abscesses localized to the caudate lobe and the gastrohepatic space which were anatomically difficult to drain percutaneously. These patients underwent EUS guided drainage and had complete resolution on follow up. The EUS method was hypothesized to be better as it provided excellent visualization of the abscess cavity and the close approximation of the transducer to the cavity wall aided in direct passage of the needle into the cavity. Color Doppler prevented accidental puncturing of interposed vessels. A total of 7 cases have been reported with no single complication and a success rate of 100%<sup>[47]</sup>. Moving forward we need further studies to establish its efficacy and recommend as a standard therapy. Further, its use may be limited in right sided abscesses. As of now it can be offered to patients as an attractive alternative especially if percutaneous



drainage fails.

### Hemobilia

With the advent of invasive hepatobiliary procedures<sup>[48]</sup> such as percutaneous biopsy, biliary drainage and transhepatic cholecystography the incidence of hemobilia has been on a rise. Most common causes include accidental or iatrogenic trauma. The bleeding typically starts within 4 wk<sup>[48]</sup> of the trauma though cases with longer time periods have been reported. They are most commonly diagnosed by hepatic angiography and often treated with embolization<sup>[49]</sup>. Cattan *et al*<sup>[50]</sup> described a case report where in hemobilia occurred nearly 4 mo after hepatic injury and was diagnosed successfully by EUS. The patient underwent upper endoscopy with both front viewing and side viewing endoscopy along with EUS which revealed the presence of mobile hyperechoic material with no acoustic shadow in the bile duct and gall bladder suggestive of hemobilia. Trakarnsanga *et al*<sup>[51]</sup> described another case where a patient presented with abdominal pain and jaundice and underwent EUS with Doppler which revealed a large cystic lesion with a detectable to and fro color flow arising from the common hepatic artery. Diagnosing hemobilia is always challenging, ultrasound and CT scan help by detecting the presence of hematoma or arteriovenous fistula. On occasions they may also detect blood clots in the bile ducts, however these findings are not always present<sup>[52]</sup>. Hence we postulate that in cases of unexplained GI bleeding especially after hepatic trauma, certain imaging studies such as EUS should be considered.

### Portal hypertensive complications and hepatic cirrhosis

The past decade has seen increasing interest in using EUS for not only early diagnosis of portal hypertension but also for treatment of varices. EUS combined with the Doppler technique helps in the detailed evaluation of the distal esophagus. Though initial studies<sup>[53]</sup> were not encouraging, later studies<sup>[54]</sup> showed that EUS could adequately identify high risks of bleeding by determining the size of the varix. Careful examination of the gastroesophageal junction with upper endoscopy helps to identify large varices, however small varices and gastric varices may be missed. In a study by Choudhuri *et al*<sup>[55]</sup>, gastric varices were detected more often with EUS than with endoscopy alone. In addition EUS can also help to identify deep venous plexus such as peri-esophageal and para-esophageal varices. In his study, Lee *et al*<sup>[56]</sup> compared cirrhotics and patients with dyspepsia to assess gastroesophageal varices and extra luminal venous abnormalities. EUS detected gastric varices in 30.8% when compared to 17.3% detected via upper endoscopy alone. Further with EUS extraluminal venous abnormality was noted in 92% of people with cirrhosis. These changes include early formation and engorgement of collateral vessels in the

distal esophagus, proximal stomach and splenic vein. Thus there is a potential for possible early detection of cirrhosis as these changes cannot be seen by regular endoscopy. This was further demonstrated by a study done by Mckiernan *et al*<sup>[57]</sup> in Birmingham, United Kingdom where 16 children with intestinal failure underwent both endoscopy and EUS to assess for the need of combined intestinal and liver transplant if indicated by presence of intestinal failure associated liver disease. In 7 patients gastroesophageal varices was only detected by EUS and not by regular endoscopy thus resulting in fewer liver biopsies in this subset of patients. Various studies conducted over the last decade helped to establish that EUS can also be used to predict the recurrences of esophageal varices after therapy. Irisawa *et al*<sup>[58]</sup> in 2001 published a retrospective study of 38 patients who had undergone endoscopic injection sclerotherapy. Presence of severe type peri-esophageal collateral veins and large perforating veins were associated with increased recurrence of esophageal varices. In 2003<sup>[59]</sup> he studied 18 patients and concluded that para-esophageal collateral veins detected after the sclerotherapy sessions predicted recurrence. Sato *et al*<sup>[60]</sup> studied 306 patients whose varices had been treated with endoscopic injection sclerotherapy with endoscopic color Doppler ultrasonography and concluded that presence of patent inflowing perforating veins before and after sclerotherapy was predictive of early variceal recurrence. Presence of severe cardiac sub mucosal veins and severe grade perforating veins<sup>[54]</sup> and presence of rapid hepatofugal flow velocity of 12 cm/s or more (The group tested a variety of cutoff points from 5 to 18 cm/s, and chose 12 cm/second as the cutoff point since it gave the maximal differences in prognoses between the low- and high-risk groups) in the left gastric vein<sup>[61]</sup> have also been reported to be associated with early recurrence of esophageal varices after treatment. Benefits of EUS extend not only to diagnosis but studies have shown therapeutic benefits as well. Especially in fundal varices which are not amenable to band ligation, EUS guided techniques such as injection of cyanoacrylate<sup>[62]</sup> and/or cyanoacrylate with coiling<sup>[63]</sup> eradicating of gastric varices have been useful. Romero-Castro *et al*<sup>[63]</sup> conducted a multicenter study comparing cyanoacrylate against EUS guided coil application. Though it was a small non randomized group, the EUS guided coil application group required fewer endoscopies and had fewer adverse effects. In a randomized control trial by de Paulo *et al*<sup>[64]</sup>, EUS guided sclerotherapy was proven to be as effective as endoscopic sclerotherapy. However larger randomized controlled trials are needed to substantiate the claim.

Initially described in 1969<sup>[65]</sup>, transjugular intra-hepatic portosystemic shunt has certainly come a long way to becoming an effective tool in the management of portal hypertension<sup>[66]</sup>, especially in the management of refractory ascites and variceal bleeding



not responding to endoscopic therapy<sup>[67]</sup>. With the emerging role of EUS in diagnosis and management of various hepatobiliary conditions there have been studies conducted which push the boundaries a bit further. In 2004 Lai *et al*<sup>[68]</sup> demonstrated for the first time the feasibility of EUS guided extrahepatic portal vein puncture and portography in an animal model. Since then few studies<sup>[69,70]</sup> on porcine models have established the efficacy and feasibility of EUS guided portal vein catheterization in portal angiography and portal vein pressure measurements. Subsequently, in 2009 Buscaglia *et al*<sup>[71]</sup> reported the first successful endoscopic creation of intrahepatic portosystemic shunt (IPSS) in 10 porcine models without any complications. They concluded that their technique of EUS guided IPSS was technically feasible and a comparative alternative with few advantages such as avoiding the entrance through heart or IVC and decreasing the radiation exposure to both the patient and physician. Further studies are needed with large diameter covered stents<sup>[72]</sup>, deployment of the proximal end of the stent into the hepatic vein-IVC confluence to promote stent patency<sup>[73]</sup> and in cirrhotics to test the safety of this technique prior to conducting human studies.

Detection of fibrosis of the liver has important management implications and although liver biopsy is still considered "a gold standard", studies have proven this technique to be less perfect owing to sampling errors, inter-observer variability<sup>[74]</sup> and complications<sup>[75]</sup>. Various serum markers and imaging tests<sup>[76]</sup> such as FibroScan (EchoSens, Paris, France)<sup>[77]</sup> have been developed and are being tested to assess their efficacy in staging the liver disease. In 2009, Rimbaş *et al*<sup>[78]</sup> postulated that mapping of the tissue elasticity distribution might prove to be useful in accurately determining stages of liver disease. He further commented that in comparison to FibroScan, real time EUS elastography not only allows for estimation of liver stiffness in all patients (irrespective of obesity) but it can also differentiate between steatosis and fibrosis thus giving it an edge. Further studies are needed to confirm these hypotheses.

### Portal vein

In patients undergoing extensive hepatectomy preoperative embolization of portal vein branches causing atrophy of the segments to be removed with subsequent compensatory hypertrophy of the remaining segments<sup>[79]</sup> has proven to be safe and effective<sup>[79,80]</sup>. Matthes *et al*<sup>[81]</sup> reported the first successful EUS guided selective embolization of the portal vein with Enteryx (ethylene-vinyl alcohol copolymer) in a single swine model. The group thus concluded that EUS guidance appears to be feasible and a potential minimally invasive preoperative treatment option for patients undergoing extensive hepatectomy. Moving forward more studies need to be

conducted to establish its clinical efficacy.

## INTRAHEPATIC BILE DUCT

Currently ERCP is considered be a gold standard for relieving biliary obstruction and when this fails the only alternative is surgery or percutaneous approach both of which are unfortunately associated with higher mortality and morbidity<sup>[82]</sup>. With the advent of EUS and the easy access of left hepatic duct from the gastric wall paved the way for EUS guided transgastric approach to biliary system. This was initially described<sup>[83]</sup> in patients with biliary obstruction who had failed either endoscopic or percutaneous transhepatic drainage by Giovannini *et al*<sup>[83]</sup> in 2003. Following this few more case reports<sup>[84,85]</sup> were published expanding interventional EUS guided biliary drainage as an attractive alternative. Subsequently, Bories *et al*<sup>[86]</sup> published a pilot series of 11 patients who underwent EUS guided transgastric drainage of the left hepatic system. Out of 11 patients the procedure was a success in 10 of them. Panpimanmas *et al*<sup>[87]</sup> also reported successful EUS guided HGS in two patients with hilar cholangiocarcinoma who had failed ERCP. Currently there are three endoscopic drainage procedures<sup>[88,89]</sup> described in the literature which includes above mentioned EUS-guided transluminal biliary drainage including choledocoduodenostomy and hepaticogastrostomy (EUS-HGS), EUS-rendezvous technique (EUS-RV), and EUS-antegrade approach (EUS-AG) of which EUS-HGS is indicated in cases of surgically altered anatomy and duodenal obstruction with tumor invasion that precludes the passage of echo endoscope. There are certain limitations to this approach as were listed by Itoi *et al*<sup>[90]</sup> in his review such as nonapposed gastric wall and left liver lobe causing procedure failure, difficulty of puncture in cases of liver cirrhosis and risk of puncturing the portal vein. A multicenter retrospective study<sup>[91]</sup> was conducted across seven tertiary centers in Japan where 64 patients were enrolled. Out of these 20 of them underwent EUS-HGS. Technical success rate was 95% but the stent dysfunction rate and 3 mo dysfunction free patency rate was 32% and 51% respectively with 6/20 patients experiencing procedure related complications. The most common complications associated with this include bile leakage and stent misplacement. EUS guided ante grade stenting (EUS-AS) was developed as an alternative to reduce the complications. Ogura *et al*<sup>[92]</sup> described a pilot study in 12 patients where he combined the EUS-HGS with EUS-AS of the biliary obstruction using an uncovered metallic stent. At the time of follow up only one patient had experienced mild pancreatitis. Ogura *et al*<sup>[93]</sup> also described a novel method called locking stent method using the end-bare covered metallic stents to prevent stent dysfunction. Initially its scope was limited only to the left intrahepatic drainage but in 2014 Ogura *et al*<sup>[94]</sup>

described a successful biliary drainage of hepatic hilar obstruction further expanding its horizons. EUS-RV technique is indicated when the biliary cannulation fails or there is a biliary stricture that cannot be passed. It involves creation of temporary fistula using EUS and placement of guidewire via the biliary duct and ampulla into the duodenum. After this ERCP is re attempted to cannulate the bile duct using the guidewire. It can be divided into two types transhepatic and transduodenal. Transduodenal can be further divided into two types according to the endoscope position: long (push) and short (pull)<sup>[95]</sup>. In 2004 Mallery *et al*<sup>[96]</sup> described feasibility of rendezvous technique for biliary drainage in 6 cases. Few studies<sup>[97,98]</sup> with over 40 patients have been published which have reported technical success rate in 60's and 70's. A retrospective study by Dhir *et al*<sup>[99]</sup> comparing the precut papillotomy to Rendezvous technique in patients with failed cannulation revealing higher success rate with EUS-RV.

EUS guided antegrade techniques are suitable for patients with altered surgical anatomy<sup>[100]</sup> or upper intestinal obstruction which prohibits the scope from reaching the biliary orifice. It involves accessing the intrahepatic biliary duct by creation of a temporary fistula between the intestine and IHBD followed by dilation of the fistula with subsequent stent placement or balloon dilation for biliary obstruction.

Park *et al*<sup>[101]</sup> in 2012 successfully described EUS-guided transhepatic antegrade balloon dilation in a 45-year-old female with hepaticojejunostomy. She had presented with bilioenteric anastomotic stricture and had failed deep enteroscopy with a pediatric colonoscopy and double balloon enteroscopy. Further in a prospective series by Park *et al*<sup>[102]</sup> 14 patients underwent antegrade technique out of which it was successful in 8 of them. A retrospective study by Shah *et al*<sup>[103]</sup> reported a success rate of 81%.

In 2013, Park *et al*<sup>[104]</sup> published a prospective series in which he not only described but also evaluated the technical feasibility and safety of EUS-guided hepaticoduodenostomy (EUS-HD) in cases of isolated right intrahepatic duct (IHD) obstruction. EUS guided cholangiography of the right IHD was successfully performed in all 6 patients and he described 3 kinds of approaches: (1) using a cholangiogram obtained by EUS-guided transduodenal puncture of the right hepatic duct as a "roadmap" to assist retrograde cannulation; (2) EUS-guided antegrade transanastomotic balloon dilation with or without stenting; and (3) EUS-BD with transluminal stenting between the right hepatic duct and the duodenal wall as an antegrade bypass stenting. Though it is an attractive alternative to PTBD in patients with isolated IHD more studies are needed to establish its efficacy.

## CONCLUSION

Although diagnostic and therapeutic EUS is an

established tool for upper GI and pancreatic applications, the authors believe that its indications and utilizations in hepatic pathologies are under-recognized. For example, EUS is able to depict and biopsy even small solid lesions in the liver that are either not visualized by other imaging modalities or visualized during routine staging procedures of GI or pulmonary cancers. However, its diagnostic role for hepatic applications is at present not fully defined. Comparative studies are needed. The therapeutic role of EUS in hepatic applications is increasing in particular regarding internal drainage procedures in patients with intrahepatic abscesses in the left lobe and in patients with biliary obstruction and altered anatomy of the GI tract. However close monitoring of the results is mandatory due to the risk of complications such as bile leakage.

EUS is definitely one of the most emerging technologies with significant clinical ramifications. There has also been a substantial interest in the future roles of EUS. The authors expect future development and expanded hepatic applications of EUS in two directions: improved diagnostic yield and evolved indications with new EUS imaging technologies and hard wares, and growth in therapeutic EUS with new EUS and other endoscopic devices. Since the left lobe and caudate lobe lie in close proximity to stomach and duodenum, providing an easy access during EUS, more EUS applications should be seen within left, caudate lobe, and gastrohepatic space. With current technology, EUS is limited in its ability to access the portion of the right lobe adjacent to the dome of the diaphragm along with its lateral and inferior portions, trans-abdominal ultrasound can complement EUS and achieve total hepatic coverage by ultrasound imaging. Interventional EUS and/or trans-abdominal ultrasound can be utilized to approach various pathologies associated with hepatic parenchyma, intrahepatic biliary system, and vascular structures. The authors expect to see more EUS guided injection ablative therapy for hepatic tumors or cysts with ethanol, sclerosant, chemotherapeutics, and biologics, and EUS guided fiducial placement for stereotactic body radiation.

## REFERENCES

- 1 Tierney WM, Adler DG, Chand B, Conway JD, Croffie JM, DiSario JA, Mishkin DS, Shah RJ, Somogyi L, Wong Kee Song LM, Petersen BT. Echoendoscopes. *Gastrointest Endosc* 2007; **66**: 435-442 [PMID: 17640635 DOI: 10.1016/j.gie.2007.05.028]
- 2 Vilmann P, Jacobsen GK, Henriksen FW, Hancke S. Endoscopic ultrasonography with guided fine needle aspiration biopsy in pancreatic disease. *Gastrointest Endosc* 1992; **38**: 172-173 [PMID: 1568614 DOI: 10.1016/S0016-5107(92)70385-X]
- 3 Kaul V, Adler DG, Conway JD, Farraye FA, Kantsevov SV, Kethu SR, Kwon RS, Mamula P, Pedrosa MC, Rodriguez SA, Tierney WM. Interventional EUS. *Gastrointest Endosc* 2010; **72**: 1-4 [PMID: 20381044 DOI: 10.1016/j.gie.2010.01.023]
- 4 Alvarez-Sánchez MV, Jenssen C, Faiss S, Napoléon B. Interventional endoscopic ultrasonography: an overview of safety and complications. *Surg Endosc* 2014; **28**: 712-734 [PMID: 24555555 DOI: 10.1007/s00464-014-3333-3]

- 24196551 DOI: 10.1007/s00464-013-3260-5]
- 5 **Bogstad J**, Vilman P, Burchard F. Early detection of recurrent hepatocellular carcinoma by endosonographically guided fine-needle aspiration biopsy. *Endoscopy* 1997; **29**: 322-324 [PMID: 9255540 DOI: 10.1055/s-2007-1004198]
- 6 **Nguyen P**, Feng JC, Chang KJ. Endoscopic ultrasound (EUS) and EUS-guided fine-needle aspiration (FNA) of liver lesions. *Gastrointest Endosc* 1999; **50**: 357-361 [PMID: 10462656 DOI: 10.1053/ge.1999.v50.97208]
- 7 **Rifkin MD**, Gordon SJ. Sonoendoscopic evaluation of extraesophageal and extragastric abnormalities: a review. *Scand J Gastroenterol Suppl* 1986; **123**: 68-73 [PMID: 3535042 DOI: 10.3109/00365528609091865]
- 8 **Jhala NC**, Jhala DN, Chhieng DC, Eloubeidi MA, Eltoun IA. Endoscopic ultrasound-guided fine-needle aspiration. A cytopathologist's perspective. *Am J Clin Pathol* 2003; **120**: 351-367 [PMID: 14502798 DOI: 10.1309/MFRF-J0XY-JLN8-NVDP]
- 9 **Shin HJ**, Lahoti S, Sneige N. Endoscopic ultrasound-guided fine-needle aspiration in 179 cases: the M. D. Anderson Cancer Center experience. *Cancer* 2002; **96**: 174-180 [PMID: 12115306 DOI: 10.1002/cncr.10614]
- 10 **Chang KJ**, Katz KD, Durbin TE, Erickson RA, Butler JA, Lin F, Wuerker RB. Endoscopic ultrasound-guided fine-needle aspiration. *Gastrointest Endosc* 1994; **40**: 694-699 [PMID: 7859967]
- 11 **Clarke MP**, Kane RA, Steele G, Hamilton ES, Ravikumar TS, Onik G, Clouse ME. Prospective comparison of preoperative imaging and intraoperative ultrasonography in the detection of liver tumors. *Surgery* 1989; **106**: 849-855 [PMID: 2554519 DOI: 10.1002/bjs.1800761235]
- 12 **Soyer P**, Elias D, Zeitoun G, Roche A, Levesque M. Surgical treatment of hepatic metastases: impact of intraoperative sonography. *AJR Am J Roentgenol* 1993; **160**: 511-514 [PMID: 8430544 DOI: 10.2214/ajr.160.3.8430544]
- 13 **Prasad P**, Schmulewitz N, Patel A, Varadarajulu S, Wildi SM, Roberts S, Tutuian R, King P, Hawes RH, Hoffman BJ, Wallace MB. Detection of occult liver metastases during EUS for staging of malignancies. *Gastrointest Endosc* 2004; **59**: 49-53 [PMID: 14722547 DOI: 10.1016/S0016-5107(03)02378-2]
- 14 **Awad SS**, Fagan S, Abudayyeh S, Karim N, Berger DH, Ayub K. Preoperative evaluation of hepatic lesions for the staging of hepatocellular and metastatic liver carcinoma using endoscopic ultrasonography. *Am J Surg* 2002; **184**: 601-64; discussion 601-64; [PMID: 12488184 DOI: 10.1016/S0002-9610(02)01092-9]
- 15 **tenBerge J**, Hoffman BJ, Hawes RH, Van Enckevort C, Giovannini M, Erickson RA, Catalano MF, Fogel R, Mallery S, Faigel DO, Ferrari AP, Waxman I, Palazzo L, Ben-Menachem T, Jowell PS, McGrath KM, Kowalski TE, Nguyen CC, Wassef WY, Yamao K, Chak A, Greenwald BD, Woodward TA, Vilman P, Sabbagh L, Wallace MB. EUS-guided fine needle aspiration of the liver: indications, yield, and safety based on an international survey of 167 cases. *Gastrointest Endosc* 2002; **55**: 859-862 [PMID: 12024141 DOI: 10.1067/mge.2002.124557]
- 16 **DeWitt J**, LeBlanc J, McHenry L, Ciaccia D, Imperiale T, Chappo J, Cramer H, McGreevy K, Chriswell M, Sherman S. Endoscopic ultrasound-guided fine needle aspiration cytology of solid liver lesions: a large single-center experience. *Am J Gastroenterol* 2003; **98**: 1976-1981 [PMID: 14499774 DOI: 10.1111/j.1572-0241.2003.07638.x]
- 17 **Hollerbach S**, Willert J, Topalidis T, Reiser M, Schmiegeler W. Endoscopic ultrasound-guided fine-needle aspiration biopsy of liver lesions: histological and cytological assessment. *Endoscopy* 2003; **35**: 743-749 [PMID: 12929021 DOI: 10.1055/s-2003-41593]
- 18 **Fritscher-Ravens A**, Broering DC, Sriram PV, Topalidis T, Jaeckle S, Thonke F, Soehendra N. EUS-guided fine-needle aspiration cytodiagnosis of hilar cholangiocarcinoma: a case series. *Gastrointest Endosc* 2000; **52**: 534-540 [PMID: 11023576 DOI: 10.1067/mge.2000.109589]
- 19 **Ryan ME**. Cytologic brushings of ductal lesions during ERCP. *Gastrointest Endosc* 1991; **37**: 139-142 [PMID: 1851708 DOI: 10.1016/S0016-5107(91)70671-8]
- 20 **Glabrenner B**, Ardan M, Boeck W, Preclik G, Möller P, Adler G. Prospective evaluation of brush cytology of biliary strictures during endoscopic retrograde cholangiopancreatography. *Endoscopy* 1999; **31**: 712-717 [PMID: 10604612 DOI: 10.1055/s-1999-73]
- 21 **Crowe DR**, Eloubeidi MA, Chhieng DC, Jhala NC, Jhala D, Eltoun IA. Fine-needle aspiration biopsy of hepatic lesions: computerized tomographic-guided versus endoscopic ultrasound-guided FNA. *Cancer* 2006; **108**: 180-185 [PMID: 16634071 DOI: 10.1002/cncr.21912]
- 22 **Saftoiu A**, Vilman P. Endoscopic ultrasound elastography-- a new imaging technique for the visualization of tissue elasticity distribution. *J Gastrointest Liver Dis* 2006; **15**: 161-165 [PMID: 16802011]
- 23 **Rustemovic N**, Hratic I, Opacic M, Ostojic R, Jakic-Razumovic J, Kvarantan M, Pulanic R, Vucelic B. EUS elastography in the diagnosis of focal liver lesions. *Gastrointest Endosc* 2007; **66**: 823-824; discussion 824 [PMID: 17681503 DOI: 10.1016/j.gie.2007.06.047]
- 24 **Tsutsumi M**, Miyagawa T, Matsumura T, Kawazoe N, Ishikawa S, Shimokama T, Shiina T, Miyanaga N, Akaza H. The impact of real-time tissue elasticity imaging (elastography) on the detection of prostate cancer: clinicopathological analysis. *Int J Clin Oncol* 2007; **12**: 250-255 [PMID: 17701002 DOI: 10.1007/s10147-007-0669-7]
- 25 **Săftoiu A**, Vilman P, Gorunescu F, Gheonea DI, Gorunescu M, Ciurea T, Popescu GL, Iordache A, Hassan H, Iordache S. Neural network analysis of dynamic sequences of EUS elastography used for the differential diagnosis of chronic pancreatitis and pancreatic cancer. *Gastrointest Endosc* 2008; **68**: 1086-1094 [PMID: 18656186 DOI: 10.1016/j.gie.2008.04.031]
- 26 **Itoh A**, Ueno E, Tohno E, Kamma H, Takahashi H, Shiina T, Yamakawa M, Matsumura T. Breast disease: clinical application of US elastography for diagnosis. *Radiology* 2006; **239**: 341-350 [PMID: 16484352 DOI: 10.1148/radiol.2391041676]
- 27 **Kato K**, Sugimoto H, Kanazumi N, Nomoto S, Takeda S, Nakao A. Intra-operative application of real-time tissue elastography for the diagnosis of liver tumours. *Liver Int* 2008; **28**: 1264-1271 [PMID: 18331239 DOI: 10.1111/j.1478-3231.2008.01701.x]
- 28 **Sandulescu L**, Padureanu V, Dumitrescu C, Braia N, Streba CT, Gheonea DI, Cazacu S, Ciurea T, Rogoveanu I, Saftoiu A. A pilot study of real time elastography in the differentiation of focal liver lesions. *Curr Health Sci J* 2012; **38**: 32-35 [PMID: 24778839]
- 29 **Hara K**, Bhatia V, Hijioka S, Mizuno N, Yamao K. A convex EUS is useful to diagnose vascular invasion of cancer, especially hepatic hilus cancer. *Dig Endosc* 2011; **23** Suppl 1: 26-28 [PMID: 21535196 DOI: 10.1111/j.1443-1661.2011.01137.x]
- 30 **Barclay RL**, Perez-Miranda M, Giovannini M. EUS-guided treatment of a solid hepatic metastasis. *Gastrointest Endosc* 2002; **55**: 266-270 [PMID: 11818938 DOI: 10.1067/mge.2002.120784]
- 31 **Hu YH**, Tuo XP, Jin ZD, Liu Y, Guo Y, Luo L. Endoscopic ultrasound (EUS)-guided ethanol injection in hepatic metastatic carcinoma: a case report. *Endoscopy* 2010; **42** Suppl 2: E256-E257 [PMID: 20931470 DOI: 10.1055/s-0030-1255653]
- 32 **Nakaji S**, Hirata N, Iwaki K, Shiratori T, Kobayashi M, Inase M. Endoscopic ultrasound (EUS)-guided ethanol injection for hepatocellular carcinoma difficult to treat with percutaneous local treatment. *Endoscopy* 2012; **44** Suppl 2 UCTN: E380 [PMID: 23139031 DOI: 10.1055/s-0032-1309918]
- 33 **DiMaio CJ**, Krishnan S, Roayaie S. EUS-guided ethanol ablation for management of metastatic hepatocellular carcinoma. *J Intervent Gastroenterol* 2014; **4**: 13-14 [DOI: 10.7178/jig.138]
- 34 **Di Matteo F**, Grasso R, Pacella CM, Martino M, Pandolfi M, Rea R, Luppi G, Silvestri S, Zardi E, Costamagna G. EUS-guided Nd: YAG laser ablation of a hepatocellular carcinoma in the caudate lobe. *Gastrointest Endosc* 2011; **73**: 632-636 [PMID: 21030019 DOI: 10.1016/j.gie.2010.08.019]
- 35 **Choi JH**, Seo DW, Park do H, Lee SK, Kim MH. Fiducial placement for stereotactic body radiation therapy under only endoscopic ultrasonography guidance in pancreatic and hepatic malignancy: practical feasibility and safety. *Gut Liver* 2014; **8**:



- 88-93 [PMID: 24516706 DOI: 10.5009/gnl.2014.8.1.88]
- 36 **Karam AR**, Connolly C, Fulwadhva U, Hussain S. Alcohol sclerosis of a giant liver cyst following failed derofings. *J Radiol Case Rep* 2011; **5**: 19-22 [PMID: 22470778 DOI: 10.3941/jrcr.v5i2.634]
  - 37 **Saini S**, Mueller PR, Ferrucci JT, Simeone JF, Wittenberg J, Butch RJ. Percutaneous aspiration of hepatic cysts does not provide definitive therapy. *AJR Am J Roentgenol* 1983; **141**: 559-560 [PMID: 6603770 DOI: 10.2214/ajr.141.3.559]
  - 38 **Bean WJ**, Rodan BA. Hepatic cysts: treatment with alcohol. *AJR Am J Roentgenol* 1985; **144**: 237-241 [PMID: 3880981 DOI: 10.2214/ajr.144.2.237]
  - 39 **Lee S**, Seo DW, Paik WH, Park do H, Lee SS, Lee SK, Kim MH. Ethanol lavage of huge hepatic cysts by using EUS guidance and a percutaneous approach. *Gastrointest Endosc* 2014; **80**: 1014-1021 [PMID: 24890421 DOI: 10.1016/j.gie.2014.03.037]
  - 40 **Bertel CK**, van Heerden JA, Sheedy PF. Treatment of pyogenic hepatic abscesses. Surgical vs percutaneous drainage. *Arch Surg* 1986; **121**: 554-558 [PMID: 3707333 DOI: 10.1001/archsurg.1986.01400050072009]
  - 41 **Bergamini TM**, Larson GM, Malangoni MA, Richardson JD. Liver abscess. Review of a 12-year experience. *Am Surg* 1987; **53**: 596-599 [PMID: 3674604]
  - 42 **Liu CH**, Gervais DA, Hahn PF, Arellano RS, Uppot RN, Mueller PR. Percutaneous hepatic abscess drainage: do multiple abscesses or multiloculated abscesses preclude drainage or affect outcome? *J Vasc Interv Radiol* 2009; **20**: 1059-1065 [PMID: 19560374 DOI: 10.1016/j.jvir.2009.04.062]
  - 43 **Tazawa J**, Sakai Y, Maekawa S, Ishida Y, Maeda M, Marumo F, Sato C. Solitary and multiple pyogenic liver abscesses: characteristics of the patients and efficacy of percutaneous drainage. *Am J Gastroenterol* 1997; **92**: 271-274 [PMID: 9040204]
  - 44 **Chung YF**, Tay KH, Stan B, Htoo AM, Thng CH, Chow PK, Ooi LL, Lau TN. Percutaneous drainage of liver abscess complicated by hepato-venous fistula. *Singapore Med J* 2003; **44**: 299-301 [PMID: 14560862]
  - 45 **Seewald S**, Imazu H, Omar S, Groth S, Seitz U, Brand B, Zhong Y, Sikka S, Thonke F, Soehendra N. EUS-guided drainage of hepatic abscess. *Gastrointest Endosc* 2005; **61**: 495-498 [PMID: 15758937 DOI: 10.1016/S0016-5107(04)02848-2]
  - 46 **Noh SH**, Park do H, Kim YR, Chun Y, Lee HC, Lee SO, Lee SS, Seo DW, Lee SK, Kim MH. EUS-guided drainage of hepatic abscesses not accessible to percutaneous drainage (with videos). *Gastrointest Endosc* 2010; **71**: 1314-1319 [PMID: 20400078 DOI: 10.1016/j.gie.2009.12.045]
  - 47 **Singhal S**, Changela K, Lane D, Anand S, Duddempudi S. Endoscopic ultrasound-guided hepatic and perihepatic abscess drainage: an evolving technique. *Therap Adv Gastroenterol* 2014; **7**: 93-98 [PMID: 24587822 DOI: 10.1177/1756283X13506178]
  - 48 **Yoshida J**, Donahue PE, Nyhus LM. Hemobilia: review of recent experience with a worldwide problem. *Am J Gastroenterol* 1987; **82**: 448-453 [PMID: 3578223]
  - 49 **Curet P**, Baumer R, Roche A, Grellet J, Mercadier M. Hepatic hemobilia of traumatic or iatrogenic origin: recent advances in diagnosis and therapy, review of the literature from 1976 to 1981. *World J Surg* 1984; **8**: 2-8 [PMID: 6367231]
  - 50 **Cattan P**, Cuillerier E, Cellier C, Cuenod CA, Roche A, Landi B, Barbier JP. Hemobilia caused by a pseudoaneurysm of the hepatic artery diagnosed by EUS. *Gastrointest Endosc* 1999; **49**: 252-255 [PMID: 9925709 DOI: 10.1016/S0016-5107(99)70497-9]
  - 51 **Trakarnsanga A**, Sriprayoon T, Akaraviputh T, Tongdee T. Massive hemobilia from a ruptured hepatic artery aneurysm detected by endoscopic ultrasound (EUS) and successfully treated. *Endoscopy* 2010; **42** Suppl 2: E340-E341 [PMID: 21170839 DOI: 10.1055/s-0030-1255940]
  - 52 **Bloechle C**, Izbicki JR, Rashed MY, el-Sefi T, Hosch SB, Knoefel WT, Rogiers X, Broelsch CE. Hemobilia: presentation, diagnosis, and management. *Am J Gastroenterol* 1994; **89**: 1537-1540 [PMID: 8079933]
  - 53 **Caletti G**, Brocchi E, Baraldini M, Ferrari A, Gibilaro M, Barbara L. Assessment of portal hypertension by endoscopic ultrasonography. *Gastrointest Endosc* 1990; **36**: S21-S27 [PMID: 2184082 DOI: 10.1016/S0016-5107(90)71011-5]
  - 54 **Konishi Y**, Nakamura T, Kida H, Seno H, Okazaki K, Chiba T. Catheter US probe EUS evaluation of gastric cardia and perigastric vascular structures to predict esophageal variceal recurrence. *Gastrointest Endosc* 2002; **55**: 197-203 [PMID: 11818922 DOI: 10.1067/mge.2002.121338]
  - 55 **Choudhuri G**, Dhiman RK, Agarwal DK. Endosonographic evaluation of the venous anatomy around the gastro-esophageal junction in patients with portal hypertension. *Hepatogastroenterology* 1996; **43**: 1250-1255 [PMID: 8908559]
  - 56 **Lee YT**, Chan FK, Ching JY, Lai CW, Leung VK, Chung SC, Sung JJ. Diagnosis of gastroesophageal varices and portal collateral venous abnormalities by endosonography in cirrhotic patients. *Endoscopy* 2002; **34**: 391-398 [PMID: 11972271 DOI: 10.1055/s-2002-25286]
  - 57 **McKiernan PJ**, Sharif K, Gupte GL. The role of endoscopic ultrasound for evaluating portal hypertension in children being assessed for intestinal transplantation. *Transplantation* 2008; **86**: 1470-1473 [PMID: 19034020 DOI: 10.1097/TP.0b013e3181891d63]
  - 58 **Irisawa A**, Saito A, Obara K, Shibukawa G, Takagi T, Shishido H, Sakamoto H, Sato Y, Kasukawa R. Endoscopic recurrence of esophageal varices is associated with the specific EUS abnormalities: severe periesophageal collateral veins and large perforating veins. *Gastrointest Endosc* 2001; **53**: 77-84 [PMID: 11154493 DOI: 10.1067/mge.2001.108479]
  - 59 **Irisawa A**, Obara K, Bhutani MS, Saito A, Shishido H, Shibukawa G, Takagi T, Yamamoto G, Seino O, Shishido F, Kasukawa R, Sato Y. Role of para-esophageal collateral veins in patients with portal hypertension based on the results of endoscopic ultrasonography and liver scintigraphy analysis. *J Gastroenterol Hepatol* 2003; **18**: 309-314 [PMID: 12603532 DOI: 10.1046/j.1440-1746.2003.02956.x]
  - 60 **Sato T**, Yamazaki K, Toyota J, Karino Y, Ohmura T, Akaike J. Endoscopic ultrasonographic evaluation of hemodynamics related to variceal relapse in esophageal variceal patients. *Hepatol Res* 2009; **39**: 126-133 [PMID: 19208033 DOI: 10.1111/j.1872-034X.2008.00415.x]
  - 61 **Kuramochi A**, Imazu H, Kakutani H, Uchiyama Y, Hino S, Urashima M. Color Doppler endoscopic ultrasonography in identifying groups at a high-risk of recurrence of esophageal varices after endoscopic treatment. *J Gastroenterol* 2007; **42**: 219-224 [PMID: 17380280 DOI: 10.1007/s00535-006-1992-x]
  - 62 **Romero-Castro R**, Pellicer-Bautista FJ, Jimenez-Saenz M, Marcos-Sanchez F, Caunedo-Alvarez A, Ortiz-Moyano C, Gomez-Parra M, Herrerias-Gutierrez JM. EUS-guided injection of cyanoacrylate in perforating feeding veins in gastric varices: results in 5 cases. *Gastrointest Endosc* 2007; **66**: 402-407 [PMID: 17643723 DOI: 10.1016/j.gie.2007.03.008]
  - 63 **Romero-Castro R**, Ellrichmann M, Ortiz-Moyano C, Subtil-Inigo JC, Junquera-Florez F, Gornals JB, Repiso-Ortega A, Vila-Costas J, Marcos-Sanchez F, Muñoz-Navas M, Romero-Gomez M, Brullet-Benedi E, Romero-Vazquez J, Caunedo-Alvarez A, Pellicer-Bautista F, Herrerias-Gutierrez JM, Fritscher-Ravens A. EUS-guided coil versus cyanoacrylate therapy for the treatment of gastric varices: a multicenter study (with videos). *Gastrointest Endosc* 2013; **78**: 711-721 [PMID: 23891417 DOI: 10.1016/j.gie.2013.05.009]
  - 64 **de Paulo GA**, Ardengh JC, Nakao FS, Ferrari AP. Treatment of esophageal varices: a randomized controlled trial comparing endoscopic sclerotherapy and EUS-guided sclerotherapy of esophageal collateral veins. *Gastrointest Endosc* 2006; **63**: 396-402; quiz 463 [PMID: 16500386 DOI: 10.1016/j.gie.2005.10.039]
  - 65 **Rösch J**, Hanafee WN, Snow H. Transjugular portal venography and radiologic portacaval shunt: an experimental study. *Radiology* 1969; **92**: 1112-1114 [PMID: 5771827 DOI: 10.1148/92.5.1112]
  - 66 **Colombato L**. The role of transjugular intrahepatic portosystemic



- shunt (TIPS) in the management of portal hypertension. *J Clin Gastroenterol* 2007; **41** Suppl 3: S344-S351 [PMID: 17975487 DOI: 10.1097/MCG.0b013e318157e500]
- 67 **Wong F.** The use of TIPS in chronic liver disease. *Ann Hepatol* 2006; **5**: 5-15 [PMID: 16531959]
- 68 **Lai L, Poneros J, Santilli J, Brugge W.** EUS-guided portal vein catheterization and pressure measurement in an animal model: a pilot study of feasibility. *Gastrointest Endosc* 2004; **59**: 280-283 [PMID: 14745408 DOI: 10.1016/S0016-5107(03)02544-6]
- 69 **Giday SA, Ko CW, Clarke JO, Shin EJ, Magno P, Jagannath SB, Buscaglia JM, Kantsevoy SV.** EUS-guided portal vein carbon dioxide angiography: a pilot study in a porcine model. *Gastrointest Endosc* 2007; **66**: 814-819 [PMID: 17905028 DOI: 10.1016/j.gie.2007.05.056]
- 70 **Giday SA, Clarke JO, Buscaglia JM, Shin EJ, Ko CW, Magno P, Kantsevoy SV.** EUS-guided portal vein catheterization: a promising novel approach for portal angiography and portal vein pressure measurements. *Gastrointest Endosc* 2008; **67**: 338-342 [PMID: 18226699 DOI: 10.1016/j.gie.2007.08.037]
- 71 **Buscaglia JM, Dray X, Shin EJ, Magno P, Chmura KM, Surti VC, Dillon TE, Ducharme RW, Donatelli G, Thuluvath PJ, Giday SA, Kantsevoy SV.** A new alternative for a transjugular intrahepatic portosystemic shunt: EUS-guided creation of an intrahepatic portosystemic shunt (with video). *Gastrointest Endosc* 2009; **69**: 941-947 [PMID: 19327481 DOI: 10.1016/j.gie.2008.09.051]
- 72 **Bureau C, Pagan JC, Layrargues GP, Metivier S, Bellot P, Perreault P, Otal P, Abalde JG, Peron JM, Rousseau H, Bosch J, Vinel JP.** Patency of stents covered with polytetrafluoroethylene in patients treated by transjugular intrahepatic portosystemic shunts: long-term results of a randomized multicentre study. *Liver Int* 2007; **27**: 742-747 [PMID: 17617116 DOI: 10.1111/j.1478-3231.2007.01522.x]
- 73 **Clark TW, Agarwal R, Haskal ZJ, Stavropoulos SW.** The effect of initial shunt outflow position on patency of transjugular intrahepatic portosystemic shunts. *J Vasc Interv Radiol* 2004; **15**: 147-152 [PMID: 14963180 DOI: 10.1097/01.RVI.0000109401.52762.56]
- 74 **Bedossa P, Dargère D, Paradis V.** Sampling variability of liver fibrosis in chronic hepatitis C. *Hepatology* 2003; **38**: 1449-1457 [PMID: 14647056 DOI: 10.1016/j.hep.2003.09.022]
- 75 **Cadranel JF, Rufat P, Degos F.** Practices of liver biopsy in France: results of a prospective nationwide survey. For the Group of Epidemiology of the French Association for the Study of the Liver (AFLF). *Hepatology* 2000; **32**: 477-481 [PMID: 10960438 DOI: 10.1053/jhep.2000.16602]
- 76 **Albanis E, Friedman SL.** Diagnosis of hepatic fibrosis in patients with chronic hepatitis C. *Clin Liver Dis* 2006; **10**: 821-833 [PMID: 17164119 DOI: 10.1016/j.cld.2006.08.027]
- 77 **Wells RG.** The role of matrix stiffness in hepatic stellate cell activation and liver fibrosis. *J Clin Gastroenterol* 2005; **39**: S158-S161 [PMID: 15758652]
- 78 **Rimbaş M, Gheonea DI, Săndulescu L, Săftoiu A, Vilman P, Ciurea T.** EUS Elastography in Evaluating Chronic Liver Disease. Why not from Inside? *Curr Health Sci J* 2009; **35**: 225-227 [PMID: 24778821]
- 79 **Hemming AW, Reed AI, Howard RJ, Fujita S, Hochwald SN, Caridi JG, Hawkins IF, Vauthey JN.** Preoperative portal vein embolization for extended hepatectomy. *Ann Surg* 2003; **237**: 686-691; discussion 691-693 [PMID: 12724635 DOI: 10.1097/01.SLA.0000065265.16728.C0]
- 80 **Liu H, Fu Y.** Portal vein embolization before major hepatectomy. *World J Gastroenterol* 2005; **11**: 2051-2054 [PMID: 15810067 DOI: 10.1097/01.mcg.0000155516.02468.0f]
- 81 **Matthes K, Sahani D, Holalkere NS, Mino-Kenudson M, Brugge WR.** Feasibility of endoscopic ultrasound-guided portal vein embolization with Enteryx. *Acta Gastroenterol Belg* 2005; **68**: 412-415 [PMID: 16432991]
- 82 **Winick AB, Waybill PN, Venbrux AC.** Complications of percutaneous transhepatic biliary interventions. *Tech Vasc Interv Radiol* 2001; **4**: 200-206 [PMID: 11748558 DOI: 10.1016/S1089-2516(01)90026-5]
- 83 **Giovannini M, Dotti M, Bories E, Moutardier V, Pesenti C, Danisi C, Delperio JR.** Hepaticogastrostomy by echo-endoscopy as a palliative treatment in a patient with metastatic biliary obstruction. *Endoscopy* 2003; **35**: 1076-1078 [PMID: 14648424 DOI: 10.1055/s-2003-44596]
- 84 **Kahaleh M, Yoshida C, Kane L, Yeaton P.** Interventional EUS cholangiography: A report of five cases. *Gastrointest Endosc* 2004; **60**: 138-142 [PMID: 15229448]
- 85 **Püspök A, Lomoschitz F, Dejaco C, Hejna M, Sautner T, Gangl A.** Endoscopic ultrasound guided therapy of benign and malignant biliary obstruction: a case series. *Am J Gastroenterol* 2005; **100**: 1743-1747 [PMID: 16086710 DOI: 10.1111/j.1572-0241.2005.41806.x]
- 86 **Bories E, Pesenti C, Caillol F, Lopes C, Giovannini M.** Transgastric endoscopic ultrasonography-guided biliary drainage: results of a pilot study. *Endoscopy* 2007; **39**: 287-291 [PMID: 17357952 DOI: 10.1055/s-2007-966212]
- 87 **Panpimanmas S, Ratanachu-ek T.** Endoscopic ultrasound-guided hepaticogastrostomy for hilar cholangiocarcinoma: the first trial in Thailand. *J Med Assoc Thai* 2011; **94** Suppl 2: S129-S134 [PMID: 21717892]
- 88 **Giovannini M, Bories E.** EUS-Guided Biliary Drainage. *Gastroenterol Res Pract* 2012; **2012**: 348719 [PMID: 21860619 DOI: 10.1155/2012/348719]
- 89 **Sarkaria S, Lee HS, Gaidhane M, Kahaleh M.** Advances in endoscopic ultrasound-guided biliary drainage: a comprehensive review. *Gut Liver* 2013; **7**: 129-136 [PMID: 23560147 DOI: 10.5009/gnl.2013.7.2.129]
- 90 **Itoi T, Sofuni A, Itokawa F, Tsuchiya T, Kurihara T, Ishii K, Tsuji S, Ikeuchi N, Umeda J, Moriyasu F, Tsuchida A.** Endoscopic ultrasonography-guided biliary drainage. *J Hepatobiliary Pancreat Sci* 2010; **17**: 611-616 [PMID: 19806298 DOI: 10.1007/s00534-009-0196-1]
- 91 **Kawakubo K, Isayama H, Kato H, Itoi T, Kawakami H, Hanada K, Ishiwatari H, Yasuda I, Kawamoto H, Itokawa F, Kuwatani M, Iiboshi T, Hayashi T, Doi S, Nakai Y.** Multicenter retrospective study of endoscopic ultrasound-guided biliary drainage for malignant biliary obstruction in Japan. *J Hepatobiliary Pancreat Sci* 2014; **21**: 328-334 [PMID: 24026963 DOI: 10.1002/jhbp.27]
- 92 **Ogura T, Masuda D, Imoto A, Takeuchi T, Kamiyama R, Mohamed M, Umegaki E, Higuchi K.** EUS-guided hepaticogastrostomy combined with fine-gauge antegrade stenting: a pilot study. *Endoscopy* 2014; **46**: 416-421 [PMID: 24573771 DOI: 10.1055/s-0034-1365020]
- 93 **Ogura T, Kurisu Y, Masuda D, Imoto A, Hayashi M, Malak M, Umegaki E, Uchiyama K, Higuchi K.** Novel method of endoscopic ultrasound-guided hepaticogastrostomy to prevent stent dysfunction. *J Gastroenterol Hepatol* 2014; **29**: 1815-1821 [PMID: 24720511 DOI: 10.1111/jgh.12598]
- 94 **Ogura T, Masuda D, Imoto A, Umegaki E, Higuchi K.** EUS-guided hepaticogastrostomy for hepatic hilar obstruction. *Endoscopy* 2014; **46** Suppl 1 UCTN: E32-E33 [PMID: 24523169 DOI: 10.1055/s-0033-1359133]
- 95 **Kawakubo K, Isayama H, Sasahira N, Nakai Y, Kogure H, Hamada T, Miyabayashi K, Mizuno S, Sasaki T, Ito Y, Yamamoto N, Hirano K, Tada M, Koike K.** Clinical utility of an endoscopic ultrasound-guided rendezvous technique via various approach routes. *Surg Endosc* 2013; **27**: 3437-3443 [PMID: 23508814 DOI: 10.1007/s00464-013-2896-5]
- 96 **Mallery S, Matlock J, Freeman ML.** EUS-guided rendezvous drainage of obstructed biliary and pancreatic ducts: Report of 6 cases. *Gastrointest Endosc* 2004; **59**: 100-107 [PMID: 14722561]
- 97 **Maranki J, Hernandez AJ, Arslan B, Jaffan AA, Angle JF, Shami VM, Kahaleh M.** Interventional endoscopic ultrasound-guided cholangiography: long-term experience of an emerging alternative to percutaneous transhepatic cholangiography. *Endoscopy* 2009; **41**: 532-538 [PMID: 19533558 DOI: 10.1055/s-0029-1214712]
- 98 **Iwashita T, Lee JG, Shinoura S, Nakai Y, Park DH, Muthusamy VR, Chang KJ.** Endoscopic ultrasound-guided rendezvous for biliary access after failed cannulation. *Endoscopy* 2012; **44**: 60-65

- [PMID: 22127960 DOI: 10.1055/s-0030-1256871]
- 99 **Dhir V**, Bhandari S, Bapat M, Maydeo A. Comparison of EUS-guided rendezvous and precut papillotomy techniques for biliary access (with videos). *Gastrointest Endosc* 2012; **75**: 354-359 [PMID: 22248603 DOI: 10.1016/j.gie.2011.07.075]
  - 100 **Itoi T**, Sofuni A, Tsuchiya T, Ijima M, Iwashita T. Endoscopic ultrasonography-guided transhepatic antegrade stone removal in patients with surgically altered anatomy: case series and technical review (with videos). *J Hepatobiliary Pancreat Sci* 2014; **21**: E86-E93 [PMID: 25231935 DOI: 10.1002/jhbp.165]
  - 101 **Park do H**, Jang JW, Lee SS, Seo DW, Lee SK, Kim MH. EUS-guided transhepatic antegrade balloon dilation for benign bilioenteric anastomotic strictures in a patient with hepaticojejunostomy. *Gastrointest Endosc* 2012; **75**: 692-693 [PMID: 21679943 DOI: 10.1016/j.gie.2011.04.013]
  - 102 **Park do H**, Jeong SU, Lee BU, Lee SS, Seo DW, Lee SK, Kim MH. Prospective evaluation of a treatment algorithm with enhanced guidewire manipulation protocol for EUS-guided biliary drainage after failed ERCP (with video). *Gastrointest Endosc* 2013; **78**: 91-101 [PMID: 23523301 DOI: 10.1016/j.gie.2013.01.042]
  - 103 **Shah JN**, Marson F, Weilert F, Bhat YM, Nguyen-Tang T, Shaw RE, Binmoeller KF. Single-operator, single-session EUS-guided antegrade cholangiopancreatography in failed ERCP or inaccessible papilla. *Gastrointest Endosc* 2012; **75**: 56-64 [PMID: 22018554 DOI: 10.1016/j.gie.2011.08.032]
  - 104 **Park SJ**, Choi JH, Park do H, Choi JH, Lee SS, Seo DW, Lee SK, Kim MH. Expanding indication: EUS-guided hepaticoduodenostomy for isolated right intrahepatic duct obstruction (with video). *Gastrointest Endosc* 2013; **78**: 374-380 [PMID: 23711555 DOI: 10.1016/j.gie.2013.04.183]
  - 105 **McGrath K**, Brody D, Luketich J, Khalid A. Detection of unsuspected left hepatic lobe metastases during EUS staging of cancer of the esophagus and cardia. *Am J Gastroenterol* 2006; **101**: 1742-1746 [PMID: 16790035 DOI: 10.1111/j.1572-0241.2006.00665.x]
  - 106 **Singh P**, Mukhopadhyay P, Bhatt B, Patel T, Kiss A, Gupta R, Bhat S, Erickson RA. Endoscopic ultrasound versus CT scan for detection of the metastases to the liver: results of a prospective comparative study. *J Clin Gastroenterol* 2009; **43**: 367-373 [PMID: 18981929 DOI: 10.1097/MCG.0b013e318167b8cc]

**P- Reviewer:** Kitano M, Mendez-Sanchez N, Picardi A  
**S- Editor:** Qi Y **L- Editor:** A **E- Editor:** Zhang DN





Published by **Baishideng Publishing Group Inc**

8226 Regency Drive, Pleasanton, CA 94588, USA

Telephone: +1-925-223-8242

Fax: +1-925-223-8243

E-mail: [bpgoffice@wjgnet.com](mailto:bpgoffice@wjgnet.com)

Help Desk: <http://www.wjgnet.com/esps/helpdesk.aspx>

<http://www.wjgnet.com>



ISSN 1007-9327



9 771007 932045