

## Overview of embryonal rhabdomyosarcoma of cervix in women over 40-year-old

Malala Razakanaivo, Nam P Nguyen, Juliette Thariat, Vincent Molinie, Anne-Therese Vlastos, Claire Verschraegen, Vincent Vinh-Hung

Malala Razakanaivo, Joseph Ravoahangy Andrianavalona  
University Hospital, Antananarivo 101, Madagascar

Nam P Nguyen, Radiation Oncology, Howard University  
Hospital, Washington, DC 20060, United States

Juliette Thariat, Antoine-Lacassagne Cancer Center, University  
Nice Sophia Antipolis, 06189 Nice Cedex, France

Juliette Thariat, Rare Cancer Network, Lausanne 1011,  
Switzerland

Vincent Molinie, Department of Pathology, University Hospital  
of Martinique, Fort-de-France 97200, Martinique

Anne-Therese Vlastos, Geneva Gynecology and Obstetrics,  
Place des Philosophes, 1205 Geneva, Switzerland

Claire Verschraegen, Division of Hematology Oncology,  
University of Vermont Cancer Center, Burlington, VT 05405,  
United States

Vincent Vinh-Hung, Radiation Oncology, University Hospital of  
Martinique, Fort-de-France 97200, Martinique

Vincent Vinh-Hung, Radiotherapy Department, UZ Brussel,  
Vrije Universiteit Brussel, 1090 Jette, Belgium

Nam P Nguyen, Juliette Thariat, Vincent Vinh-Hung,  
International Geriatric Radiotherapy Group (<http://igrg.org/>),  
Washington, DC 20060, United States

**Author contributions:** Original concept and design were developed by Nguyen NP, Thariat J and Vinh-Hung V; literature search was performed by Razakanaivo M, Nguyen NP, Verschraegen C and Vinh-Hung V; data revisions were carried out by Nguyen NP, Thariat J, Verschraegen C and Vinh-Hung V; statistical analyses were performed by Vinh-Hung V; Razakanaivo M, Molinie V and Vlastos AT contributed to the writing of the manuscript; all authors approved the final version.

**Conflict-of-interest statement:** The authors have no conflicts of interests to report.

**Open-Access:** This article is an open-access article which was selected by an in-house editor and fully peer-reviewed by external reviewers. It is distributed in accordance with the Creative Commons Attribution Non Commercial (CC BY-NC 4.0) license, which permits others to distribute, remix, adapt, build upon this work non-commercially, and license their derivative works on different terms, provided the original work is properly cited and the use is non-commercial. See: <http://creativecommons.org/licenses/by-nc/4.0/>

**Correspondence to:** Vincent Vinh-Hung, MD, PhD, Radiation Oncology, University Hospital of Martinique, Hôpital Clarac, Bd Pasteur, Fort-de-France 97200, Martinique. [anhxang@gmail.com](mailto:anhxang@gmail.com)  
**Telephone:** +596-696-542019  
**Fax:** +596-596-632254

**Received:** June 27, 2015

**Peer-review started:** June 30, 2015

**First decision:** August 16, 2015

**Revised:** November 11, 2015

**Accepted:** December 13, 2015

**Article in press:** December 14, 2015

**Published online:** February 10, 2016

### Abstract

The literature on cervical embryonal rhabdomyosarcoma (RMS) is reviewed here to identify management guidelines for middle-aged women diagnosed with this rare type of gynecologic cancer. Specifically, the PubMed, Web of Science and Google Scholar databases, were searched to find published case series on cervical embryonal RMS reporting on four or more patients, of whom at least one was > 40-year-old. The  $\chi^2$  test was used to assess heterogeneity. Five articles published between 1986 and 2013 were identified, reporting on a total of 47 patients, of whom 22 (46.8%) were older and 25 (53.2%) younger than 40-year-old. Although the two age groups did not differ significantly by stage of disease or radiotherapy treatment, the older age group

received less chemotherapy (55% *vs* 90%,  $P = 0.008$ ) and had more hysterectomy (86% *vs* 43%,  $P = 0.009$ ). Follow-up data was missing for 18/47 (38.3%) patients. Among the 29 patients with follow-up data, survival was shorter in the older group, with 8/12 (67%) alive and 3 with disease at a median follow-up of 2.6 years, as compared with the younger group that had 15/17 (88%) alive and none with disease at a median follow-up of 3.5 years. The longest survivals among the older women were observed in those who received radiotherapy, including one case with a resected lung metastasis. A prospective multi-institutional collaboration and better follow-up are needed to determine the optimal management of cervical embryonal RMS. Long-term survival appears feasible if management is accompanied by chemotherapy and radiotherapy.

**Key words:** Embryonal rhabdomyosarcoma; Botryoid sarcoma; Cervix; Middle-aged adults; Chemotherapy; Radiotherapy; Review

© The Author(s) 2016. Published by Baishideng Publishing Group Inc. All rights reserved.

**Core tip:** The present review of adult cervical embryonal rhabdomyosarcoma case series summarizes 5 studies reporting on 47 female patients, 22 of whom were > 40-year-old. Women over 40 had worse disease-free survival but also received less chemotherapy administration. Although radiotherapy was not often used, the longest survival in the > 40 age group was observed among those who received radiotherapy, including a case with resected lung metastasis. The review argues for multimodality management in this rare disease.

Razakanaivo M, Nguyen NP, Thariat J, Molinie V, Vlastos AT, Verschraegen C, Vinh-Hung V. Overview of embryonal rhabdomyosarcoma of cervix in women over 40-year-old. *World J Obstet Gynecol* 2016; 5(1): 110-117 Available from: URL: <http://www.wjgnet.com/2218-6220/full/v5/i1/110.htm> DOI: <http://dx.doi.org/10.5317/wjog.v5.i1.110>

## INTRODUCTION

Rhabdomyosarcoma (RMS), a mesenchymal tumor with the potential to differentiate into skeletal muscle, is the most common soft tissue sarcoma in children<sup>[1,2]</sup>. It is a complex disease that can originate in any part of the body, from the head or neck to the limbs. The major histologic subtypes are the alveolar rhabdomyosarcoma (ARMS) and the embryonal rhabdomyosarcoma (ERMS). ARMS is frequently characterized by the translocation of t (2; 13) PAX3-FOXO1 and t (1; 13) PAX7-FOXO1, while ERMS typically has a loss of heterozygosity of the short arm of chromosome 11<sup>[1,2]</sup>. ERMS is further divided into two classifications for the sarcoma botryoid variant or spindle cell variant<sup>[2]</sup>. Considerable improvements in the survival of ERMS patients have been attributed to

**Table 1 Intergroup Rhabdomyosarcoma Study Group pretreatment clinical staging system**

Stage	Sites of primary tumor	Tumor size, cm	Regional lymph nodes	Distant metastases
1	Orbit, non-parameningeal head/neck; genito-urinary non-bladder/prostate; biliary tract	Any size	N0 or N1 or Nx	M0
2	All other sites	≤ 5 cm	N0 or Nx	M0
3	All other sites	≤ 5 cm	N1	M0
		> 5 cm	N0 or N1 or Nx	
4	Any site	Any size	N0 or N1 or Nx	M1

N0: Absence of nodal spread; N1: Regional nodes involved; Nx: Unknown nodal status; M0: No metastases; M1: Distant metastases at diagnosis.

intensive chemotherapy<sup>[3]</sup>. While RMS is rare, cervical location is exceedingly rare in adults, but a well-known entity. Thus far, only 10 adult cases of women > 40-year-old have been reported in the literature<sup>[4]</sup>. The present review aims to define the presentation of cervical RMS in adult women. We examined how outcomes of women > 40-year-old compared with younger women diagnosed with ERMS.

## LITERATURE ON ERMS

The PubMed and Web of Science databases were searched for publications on ERMS. The key word combinations used were "rhabdomyosarcoma and embryonal" or "sarcoma and botryoid\*" and "cervical or cervix". The search was expanded manually using Google Scholar. Articles selected were case series reporting on four or more patients with cervical ERMS, among whom at least one was 40-year-old or older. The cutoff age of 40-year-old was chosen because fertility might be less of a concern than in younger women. We also took into consideration a bimodal age distribution around 40 years<sup>[5,6]</sup>. We focused on ERMS because of its preponderance among cervical sarcomas, representing 64.0% of all cervical sarcomas<sup>[7]</sup>.

Two classification systems most commonly used were the pre-treatment TNM-based staging classification (Table 1), and the Intergroup Rhabdomyosarcoma Study Group (IRSG) clinical grouping based on operative pathology (Table 2). Tumor-node-metastasis classification has 4 stages (1-4) varying on the site of primary tumor, tumor size (T), regional lymph node involvement (N) and presence or absence of distant metastases (M). The IRSG classifies tumors in four groups (I-IV). Group I tumors are localized and completely resectable; however, based on whether they are confined to an organ/muscle or infiltrate outside is further classified as groups IA or IB, respectively. Tumors in group II are subdivided into three subgroups (A-C). In these tumors, the microscopic disease remains at margins and/or regional nodes. Group III (A-B) tumors

**Table 2 Intergroup Rhabdomyosarcoma Study Group surgical grouping system**

Group I	Localized disease, completely resected (clear margins, negative regional nodes)
IA	Confined to organ or muscle of origin
IB	Infiltration outside organ or muscle of origin
Group II	Microscopic disease remaining (at margins or in regional nodes)
IIA	Grossly resected tumors with microscopic residual tumor
IIB	Regional disease, completely resected, with nodes involved and/or tumor extension into an adjacent organ
IIC	Regional disease, with involved nodes, grossly resected, but with evidence of microscopic residual tumor
Group III	Incomplete resection or biopsy with gross residual disease remaining
IIIA	After biopsy
IIIB	After major surgical resection
Group IV	Distant metastases present at onset

are characterized by an incomplete resection or biopsy with gross residual disease remaining. Group IV tumors have distant metastases present at onset.

Data extracted from the publications were cross-tabulated by age group, the source of publication, and clinical grouping. For the analyses, we considered a pooled survival analysis using established methods<sup>[8]</sup>. However, upon browsing the publications, we realized that firstly there were no randomized trials, and secondly data were too scarce to allow advanced analyses<sup>[9]</sup>, providing inferential statistical outcomes would be misleading. We restricted the analyses to ad-hoc descriptive statistics, using the  $\chi^2$  test only to indicate heterogeneity of the data. If patients in a group received significantly more treatment than the other group, we would report the *P* value to indicate the heterogeneous treatment attribution. However, if survival outcome differed, we would not test the survival difference. We detailed each retrieved publication as a “vignette”, so as to preserve a direct link with the source. We designed, after the fact, the cross tabulation to go one step beyond the narrative, without overextending to the pretense of a pooled review or a meta-analysis<sup>[10]</sup>.

### Review of ERMS case studies

A total of five eligible publications out of 6180 links from the three internet databases were identified (Figure 1, flowchart according to Moher *et al*<sup>[11]</sup>).

(1) Montag *et al*<sup>[5]</sup>: 4 cases of cervical ERMS; 18-42-year-old. One cervical ERMS patient was 42-year-old; (2) Brand *et al*<sup>[12]</sup>: 5 cases of cervical ERMS; 0-48-year-old. One cervical ERMS patient was 48-year-old; (3) Ferguson *et al*<sup>[13]</sup>: 15 cases of RMS embryonal and non-embryonal, of which 8 were cervical; 17-58-year-old. Five cervical ERMS patients were over 40-year-old; (4) Kriseman *et al*<sup>[14]</sup>: 11 cases; 3-52-year-old. ERMS in 10 cases, undifferentiated RMS in 1 case. Two cervical ERMS patients were > 40-year-old; and (5) Li *et al*<sup>[15]</sup>: 25 cases of ERMS, of which 20 were cervical; 20-89-year-old. Thirteen cervical ERMS patients were > 40-year-old.

Three additional publications also reported adult case series; however, there were no patients > 40-year-old<sup>[16-18]</sup>. Hence, these three publications were not selected for the review.

There were 47 patients with cervical ERMS from the five eligible case studies, with a mean age of 36-year-old at presentation (median, 33 years; range, 1-89 years). Table 3 summarizes patient characteristics according to age group. Table 4 provides the distribution by age and the IRSG grouping.

Montag *et al*<sup>[5]</sup> reported 6 cases of ERMS, diagnostic period unspecified, 4 of which involved the cervix or the cervix and uterus, and 2 of which had involvement of only uterus<sup>[5]</sup>. Five patients had a history of vaginal bleeding starting at 6 wk to 16 mo before the diagnosis. The ages of patients with a cervical origin were 18-, 21-, 26-, and 42-year-old. One patient had a vaginal protrusion of the tumor. The 42-year-old patient had a history of vaginal polyp excision, which had occurred 4 mo earlier. She was treated with a total abdominal hysterectomy (TAH), bilateral salpingo-oophorectomy (BSO), omental biopsy, and pelvic and paraaortic lymph node biopsies. There was no evidence of extra-uterine disease. The patient received external postoperative radiation therapy consisting of 4500 cGy to the whole pelvis and an additional 4000 cGy to the vaginal cuff with radium brachytherapy. Nine months later, the patient developed a metastasis in the right lung. No other site of recurrence could be documented. The patient underwent resection of the upper lobe of the right lung followed by intravenous chemotherapy with nine cycles of doxorubicin and dacarbazine, then nine other cycles combining vincristine, actinomycin-D and cyclophosphamide (VAC), duration unspecified. The patient was alive without evidence of disease 10 years after her initial surgery. The younger patients were treated with radical hysterectomy and bilateral pelvic lymph node dissection (PLND). The 3 younger cervical ERMS patients all received postoperative chemotherapy, and 2 of them also preoperative chemotherapy. They were alive without evidence of disease 17 mo, 7 years, and 8 years after their surgery, respectively. The authors insisted on the importance of initial staging, which included cystoscopy, radiological exams and scans, as the single most important factor affecting prognosis and survival. For non-metastatic locally advanced disease, chemotherapy and radiotherapy have been used to convert inoperable RMS into a resectable disease. The authors argued that surgery followed by adjuvant chemotherapy and, occasionally, radiotherapy for residual disease produced the highest survival rates. An interesting point was the aggressive management of oligometastases in the patient with the longest survival.

Brand *et al*<sup>[12]</sup> reported 4 cases of ERMS of the uterine cervix diagnosed between 1960 and 1986. Patients were 17-mo-old, 2 were 17-year-old, and 1 was 48-year-old. The patients had a history of vaginal bleeding for 1 to 8 mo prior to the diagnosis of ERMS. The patient over 40 was treated with TAH-BSO. She received eight

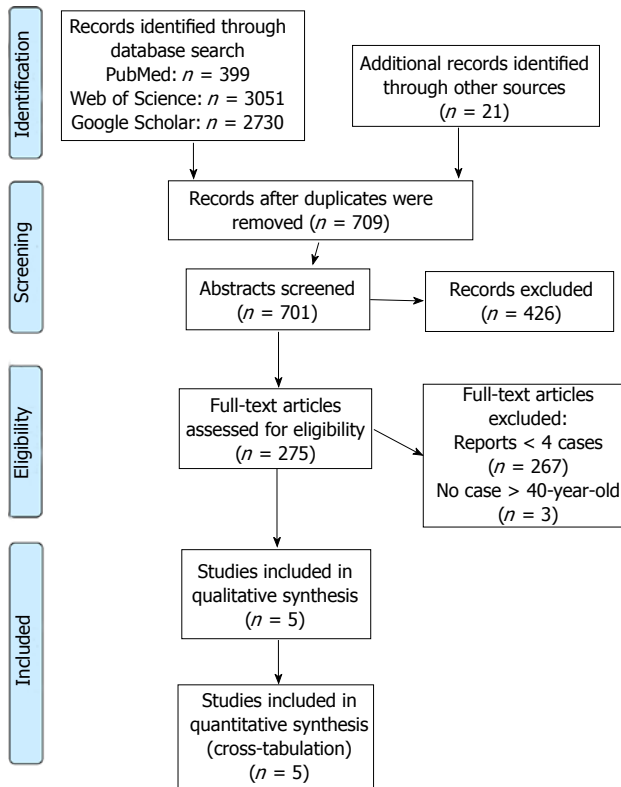


Figure 1 Flow diagram of studies selection.

cycles of cyclophosphamide over a 3-mo period. Vaginal ERMS recurrence was diagnosed 2 mo later, for which she received whole pelvis external radiation (5400 cGy) and intravaginal radium therapy (3500 cGy). She was alive without evidence of malignancy 22 years after the initial treatment. Among the  $\leq 40$ -year-old patients, the 17-mo-old infant presented with pulmonary, bone and brain metastases (Group IV, definition in Table 2). She received vincristine, dactinomycin and doxorubicin over 3 years and was reported to be alive and free of disease 8 years after the diagnosis of ERMS. The two other  $\leq 40$ -year-old patients, who were both 17-year-old, presented with Group IA disease (definition in Table 2, localized disease), and received both TAH-BSO. One received postoperative radiotherapy and was diagnosed with bone metastasis at 1 mo after the radiotherapy; she died with metastatic disease 1 year after the initial diagnosis of ERMS. The other 17-year-old received adjuvant chemotherapy with dactinomycin and vincristine; she was alive and free of disease at 1 year after the initial diagnosis of ERMS. In the series, the outcome of the 48-year-old patient was comparable to that of the younger patients. Brand and colleagues stressed the importance of neo-adjuvant chemotherapy to conserve the function of the bladder, rectum, vagina, and ovaries when feasible. The author considered the role of radiotherapy unclear and did not recommend it for the Group I patients.

Ferguson *et al.*<sup>[13]</sup> reported 8 cases of cervical ERMS treated between January 1963 and December 2003. Five patients were  $> 40$ -year-old at diagnosis (range,

46-58 years). All women older than 40 years presented with early-stage disease. The primary therapy for these women was surgery with TAH/BSO/PLND, except for 1 patient who had no BSO. Four of the women received adjuvant therapy, 2 with radiation alone and 2 in combination with chemotherapy. Three patients were alive without evidence of disease at 7, 27, and 37 mo after the diagnosis. Two patients who did not receive chemotherapy died of the disease. Among the 3 younger patients (age at diagnosis: 17-, 22-, and 32-year-old), 2 had a recurrence of the disease. Time to progression was 7 and 9 mo, and these 2 patients died of disease at 5 and 8 mo after recurrence, respectively. The authors stated that survival in women with gynecologic ERMS was not as favorable as compared to the pediatric population but emphasized that ERMS in adults is responsive to chemotherapy. They argued that adequate initial treatment should be multidisciplinary with surgery, radiation, and combination chemotherapy to offer the best chance of survival.

Kriseman *et al.*<sup>[14]</sup> reported 11 cases of cervical ERMS between 1980 and 2010. Vaginal bleeding or discharge was present in all 11 patients, and 4 patients also had a protruding vaginal mass as a presenting symptom. Two patients had no staging information available. The other 9 had disease classified as IRSG group I, for whom the authors also provided International Federation of Gynecology and Obstetrics (FIGO) staging information intended for carcinoma rather than sarcoma<sup>[19,20]</sup>. All patients received surgery at some point during the treatment. Two patients were  $> 40$ -year-old at diagnosis (49 and 52 years). The 49-year-old patient had FIGO stage IB1 disease (tumor  $\leq 4$  cm). She was treated with TAH-BSO and received adjuvant chemotherapy (cyclophosphamide, doxorubicin, vincristine, and dacarbazine) and radiation beginning 6 mo after the diagnosis (4600 cGy delivered over 31 d). Six years later, this patient was diagnosed with an unresectable high-grade adenocarcinoma of the right parotid which metastasized to the lungs and caused her death. The 52-year-old patient had FIGO stage IB2 disease (tumor  $> 4$  cm). She was treated by cone biopsy and did not receive adjuvant therapy. The patient was in complete remission 19 mo after the end of the treatment. The 9 younger patients presented with stage IB1 disease (2 cases), stage IB2 disease (3 cases), stage IIA disease (tumor involving upper 2/3 of the vagina, without parametrial invasion; 1 case), and stage unknown (2 cases). Eight patients were treated by cone biopsy, and 1 had a TAH. Neo-adjuvant chemotherapy was given in 2/9 cases. Post-operative chemotherapy was given in 6/9 cases. Five patients were alive without evidence of disease at 4, 6, 23, 35, and 121 mo after completion of therapy. One patient was alive with the disease following a local recurrence, 1 died of the disease, 1 died of unknown cause, and 1 died of complications related to neutropenic fever. The authors stressed the importance of multimodal therapy, even at an early stage. They found no differences in



**Table 3** Case-series of cervical embryonal rhabdomyosarcomas reporting on > 4 patients, of whom at least one was > 40-year-old

Author Year Cases	Women ≤ 40-year-old				Women > 40-year-old			
	<i>n</i>	Age, yr	1 <sup>st</sup> treatment ( <i>n</i> )	Follow-up (yr)	<i>n</i>	Age, yr	1 <sup>st</sup> treatment ( <i>n</i> )	Follow-up (yr)
Montag <i>et al</i> <sup>[5]</sup> 1986 <i>n</i> = 4	3	18, 21, 26	TAH (3), BSO (2), LND (2); CT (3)	Alive NED at 1.4 yr, 7 yr, and 8 yr	1	42	TAH-BSO- LND; RT + BT	No local recurrence, but lung metastasis at 9 mo, resection and CT; Alive NED after 10 yr
Brand <i>et al</i> <sup>[12]</sup> 1987 <i>n</i> = 4	3	1.4, 17, 17	TAH (2), BSO (1), LND (1), no surgery (1); CT (2), RT (1)	Died WD at 0.5 yr (case no RT); Alive NED at 1 yr and 8 yr	1	48	TAH-BSO; CT	Vaginal recurrence at 2 mo, pelvic RT + intravaginal brachytherapy; Alive NED after 22 yr
Ferguson <i>et al</i> <sup>[13]</sup> 2007 <i>n</i> = 8	3	17, 22, 32	Unknown (1), TAH (2), BSO (1), LND (2); CT (2), RT (2)	Died WD at 1.8 yr (case CT + RT); Alive NED at 0.2 yr and 10 yr (RT)	5	46, 51, 52, 56, 58	TAH-BSO- LND (4); TAH- LND (1); CT (2); RT (2); BT (2)	Dead WD (2) 1 yr and 1.4 yr after; Alive NED (3) at 0.6 yr, 2 yr, and 3 yr
Kriseman <i>et al</i> <sup>[14]</sup> 2012 <i>n</i> = 11	9	3, 12, 13, 17, 18, 18, 27, 33, 34	No surgery (2), cone biopsy (6), polypectomy (1), TAH-BSO (1), CT (8), RT (1)	No FU (4), Died at date not reported (1) Alive NED (5) at 0.3 yr, 0.5 yr, 2 yr, 3 yr, and 10 yr	2	49  52	TAH-BSO; CT; RT  Cone biopsy; no adjuvant therapy	No recurrence, died after 6 yr from the second primary tumor, adenocarcinoma of parotid; Alive NED after 1.5 yr
Li <i>et al</i> <sup>[15]</sup> 2013 <i>n</i> = 20	7	20, 21, 23, 26, 29, 29, 31	Unknown (2), polypectomy (4), TAH (1) CT (3)	No FU (5); Alive NED (3) at 3.5 yr, 6 yr, and 8 yr	13	54  46 73	TAH  TAH; CT Polypectomy	Alive WD (vaginal recurrence) at 0.4 yr Alive NED at 3 yr Died at 0.4 yr with lung metastasis and a second primary tumor, ductal breast carcinoma No FU data
Summary <i>n</i> = 47	25	Median age 21 yr (range 1-34 yr)	Surgery: TAH 9/21 (42.9%), CT: 18/20 (90.0%), RT: 4/19 (21.1%)	No FU: 8 (32.0%), Alive: 15/17(88.0%), 0 WD, Median FU, 3.5 yr Died: 3/17 (17.6%), at median 1.1 yr	22	Median age 50 yr (range 42-89 yr)	Surgery: TAH 12/14 (85.7%) CT: 6/11 (54.5%) RT: 4/11 (36.4%)	No FU: 10 (45.5%) Alive: 8/12 (66.7%), 3 WD, Median FU 2.6 yr Died: 4 (33.3%), at median 1.2 yr

TAH: Total abdominal hysterectomy; BSO: Bilateral salpingo-oophorectomy; LND: Lymph node dissection; NED: No evidence of disease; WD: With disease; CT: Chemotherapy; RT: External radiotherapy; BT: Brachytherapy; FU: Follow-up.

treatment or survival among women > 19-year-old and younger patients.

Li *et al*<sup>[15]</sup> reported 20 cases of cervical ERMS. Eleven patients were > 40-year-old. A cervical polyp was the most common clinical presentation. The diagnosis was made by biopsy (1 case), polypectomy (8 cases), and hysterectomy (2 cases). Therapeutic modalities were not available for all patients. Of the 3 patients with follow-up, 1 was alive without evidence of disease 3 years later; this case had received chemotherapy. One patient was alive with the disease at 5 mo after treatment. One patient died with pulmonary nodules at 5 mo after the treatment. Seven patients < 40-year-old were diagnosed by biopsy (2 cases) and polypectomy (5 cases). Follow-up data was available for 3 cases. These patients were alive without evidence of disease at 3.5, 6, and 8 years after chemotherapy. Li *et al*<sup>[15]</sup> compared the microscopic diagnosis of cervical ERMS in adults but reported no particular age-related morphological pattern. Their series' age distribution showed a bimodal pattern with a peak at 40-49 years, but the authors did

not comment. The authors discussed the importance of considering ERMS in the differential diagnosis of uterine corpus or cervical spindle cell tumors, regardless of the patient's age.

### Synthetic overview

Both adult and pediatric patients with cervical ERMS presented with vaginal bleeding and sometimes tumor protruding out of the vagina. However, in adults, symptoms can last up to 16 mo<sup>[5]</sup>; in contrast, in pediatric series, the vaginal bleeding and spotting lasted for 1 wk or less<sup>[18]</sup>.

Histologically, ERMS tumors are characterized by myxoid stroma or edematous hypocellular spindle cell proliferation with cellular condensation beneath epithelial surfaces (cambium layer)<sup>[5,12,13,15]</sup>. Pathological diagnosis is based on the demonstration of skeletal muscle differentiation, morphologically, and with the use of immunohistochemistry for the coexpression of desmin and myogenin<sup>[5,13,15]</sup>. Ki-67 expression is usually elevated, and estrogen and progesterone receptors are

absent<sup>[15]</sup>. ERMS differs from ARMS in that the stroma in ERMS is variably loose and shows dense cellularity within a myxoid matrix, whereas ARMS cells tend to cluster into nests that may be separated by fibrous septa<sup>[2]</sup>.

Genetic alterations have yet to be clinically explored in cervical ERMS. In pathology series, there are frequent allelic losses, most notably in the chromosomal region 11p15.5<sup>[2]</sup>. Loss of heterozygosity on the short arm of chromosome 11 suggests inactivation of tumor suppressor genes<sup>[21]</sup>. Diverse gene fusions have been reported in subsets of ERMS<sup>[22,23]</sup>, fusion-positive PAX3/7-FOXO1 in 7 of 31 ERMS, and hyperploidy associated with gains of chromosomes 2, 8 and 12<sup>[24]</sup>. While a discussion of genetic lesions is beyond the purpose of the present review, the lesions may potentially explain heterogeneity of cases and the increased risk for multiple primary cancers that have been reported by several authors<sup>[14,16,18]</sup>. FOXO1 translocation status will be used as a risk stratification criterion in future pediatric RMS studies<sup>[3]</sup>.

Staging did not seem to differ across different age groups; however, diagnostic work-up was missing in half of the cases reviewed (Table 4). The case series spanned across a long time period, from as early as 1960, whereas current imaging procedures differ considerably. Patients who had a negative positron emission tomography (PET) following induction chemotherapy and radiotherapy had a better local relapse-free survival than RMS patients who had a positive PET (94% vs 75%,  $P = 0.02$ )<sup>[25]</sup>. PET might replace conventional staging imaging studies<sup>[3,26,27]</sup>. None of the case series reported the use of PET.

There were substantial differences in the management between the two age groups in the pooled data, though this could not be ascertained within each paper (Table 3). Data on hysterectomy was more often missing in older women than in younger women [36% (8/22 patients) vs 16% (4/25 patients)]. Among documented cases, hysterectomy rates were higher in older women [86% (12/14 patients) vs 43% (9/21 patients)]. In older women, chemotherapy was used less often (55% vs 90%), but radiotherapy more often (36% vs 21%). These differences may be due to the desire to preserve fertility in younger patients.

Chemotherapy and radiotherapy data were missing more frequently for the older than the younger patients (50% vs 22%). Among those with available information, the most commonly used chemotherapy regimens in 20 patients > 40-year-old included VAC (13 patients, 65.0%), VA (2 patients, 10.0%), and vincristine, doxorubicin and cyclophosphamide (VDC) (2 patients, 10.0%). One patient received VDC plus dacarbazine and cyclophosphamide. Two patients received a non-VAC regimen (etoposide alone<sup>[13]</sup> or cisplatin and doxorubicin combination<sup>[14]</sup>). Overall, 85% of the chemotherapy regimens followed a pediatric protocol, regardless of age group<sup>[28-30]</sup>.

The death rate was twice as high in patients >

**Table 4 Intergroup Rhabdomyosarcoma Study Group clinical grouping of the 5 case-series of cervical embryonal rhabdomyosarcomas, overwhelming missing data**

IRSG clinical stage	Women ≤ 40-year-old <i>n</i> = 25 <i>n</i> (%)	Women > 40-year-old <i>n</i> = 22 <i>n</i> (%)
NA	11 (44.0)	13 (59.1)
I	11 (44.0)	9 (40.9)
II	1 (4.0)	0 (0.0)
III	1 (4.0)	0 (0.0)
IV	1 (4.0)	0 (0.0)

IRSG: Intergroup Rhabdomyosarcoma Study Group; NA: Unknown, not available, or could not be inferred from the reports.

40-year-old than in the younger age group. Older patients who survived had more residual disease than the younger patients. The poorer outcome might be explained by lower chemotherapy administration rate (Table 3). The follow-up data was missing across all age groups, but was especially high in the older group (45% vs 32%), precluding reliable comparison. In the most recent publications, the frequency of surgery appeared to decrease, and radiotherapy was infrequently given, even in women over 40 (Table 3). The median time of death or the last follow-up among younger patients who received radiotherapy was 1 year, which raises the question whether or not these patients had been selected because of more advanced disease. The longest survivals were observed among those who received external beam radiotherapy and brachytherapy. The reported survival times in that subset ranged between extremes, from 1.4 and 2 years<sup>[13]</sup> through 6<sup>[14]</sup>, 10<sup>[5]</sup>, to 22 years in a patient who received early salvage radiotherapy and brachytherapy<sup>[12]</sup>.

The limitations of our study have been a small sample size and a retrospective approach; nevertheless, EMRS is sensitive to chemotherapy and radiotherapy. Since ovarian preservation is less of a concern in women who are over 40 years old, radiotherapy could be applied in those who have metastatic pelvic and/or paraaortic lymph nodes or residual disease following surgery. In patients whose tumors are locally unresectable, chemoradiation may be given either preoperatively or to the patient who is not a surgical candidate because of associated co-morbidity. In patients who present with distant metastases, induction chemotherapy and reassessment for loco-regional treatment after chemotherapy may be an option, depending on the response to chemotherapy. In the era of modern radiotherapy techniques such as stereotactic body radiotherapy and image-guided radiotherapy, long-term remission may be feasible even when the patient has distant metastases<sup>[31]</sup>. Because of the rarity of the disease, the feasibility of prospective studies is questionable. An international registry for rare tumors could be used as a depository and a resource on treatment data and long-term follow-up.

## CONCLUSION

ERMS is an exceedingly rare disease among middle-aged women. An international registry could help determine the optimal treatment of patients at various disease stages. Long-term survival is possible with multimodality treatments, as the tumor is chemo- and radio-sensitive. A multidisciplinary team approach is essential for optimal therapy. In the future, genomics might provide new therapeutic opportunities.

## ACKNOWLEDGMENTS

The authors would like to thank Dayleen De Riggs and Kristen L. Young for their help in the preparation of this manuscript.

## REFERENCES

- Hayes-Jordan A, Andrassy R. Rhabdomyosarcoma in children. *Curr Opin Pediatr* 2009; **21**: 373-378 [PMID: 19448544 DOI: 10.1097/MOP.0b013e32832b4171]
- Parham DM, Barr FG. Classification of rhabdomyosarcoma and its molecular basis. *Adv Anat Pathol* 2013; **20**: 387-397 [PMID: 24113309 DOI: 10.1097/PAP.0b013e3283182a92d0d]
- Hawkins DS, Gupta AA, Rudzinski ER. What is new in the biology and treatment of pediatric rhabdomyosarcoma? *Curr Opin Pediatr* 2014; **26**: 50-56 [PMID: 24326270 DOI: 10.1097/MOP.0000000000000041]
- Baiocchi G, Faloppa CC, Osório CA, Kumagai LY, Fukazawa EM, Cunha IW. Embryonal rhabdomyosarcoma of the uterine cervix in a 47-year-old woman. *J Obstet Gynaecol Res* 2011; **37**: 940-946 [PMID: 21410833 DOI: 10.1111/j.1447-0756.2010.01449.x]
- Montag TW, D'ablaing G, Schlaerth JB, Gaddis O, Morrow CP. Embryonal rhabdomyosarcoma of the uterine corpus and cervix. *Gynecol Oncol* 1986; **25**: 171-194 [PMID: 3758828 DOI: 10.1016/0090-8258(86)90098-3]
- Simon JH, Paulino AC, Ritchie JM, Mayr NA, Buatti JM. Presentation, prognostic factors and patterns of failure in adult rhabdomyosarcoma. *Sarcoma* 2003; **7**: 1-7 [PMID: 18521362 DOI: 10.1080/1357714031000114147]
- Fadare O. Uncommon sarcomas of the uterine cervix: a review of selected entities. *Diagn Pathol* 2006; **1**: 30 [PMID: 16981999 DOI: 10.1186/1746-1596-1-30]
- Vinh-Hung V, Verschraegen C. Breast-conserving surgery with or without radiotherapy: pooled-analysis for risks of ipsilateral breast tumor recurrence and mortality. *J Natl Cancer Inst* 2004; **96**: 115-121 [PMID: 14734701 DOI: 10.1093/jnci/djh246]
- Vinh-Hung V, Bourgain C, Vlastos G, Cserni G, De Ridder M, Storme G, Vlastos AT. Prognostic value of histopathology and trends in cervical cancer: a SEER population study. *BMC Cancer* 2007; **7**: 164 [PMID: 17718897 DOI: 10.1186/1471-2407-7-164]
- Murad MH, Montori VM, Ioannidis JP, Jaeschke R, Devereaux PJ, Prasad K, Neumann I, Carrasco-Labra A, Agoritsas T, Hatala R, Meade MO, Weyer P, Cook DJ, Guyatt G. How to read a systematic review and meta-analysis and apply the results to patient care: users' guides to the medical literature. *JAMA* 2014; **312**: 171-179 [PMID: 25005654 DOI: 10.1001/jama.2014.5559]
- Moher D, Liberati A, Tetzlaff J, Altman DG. Preferred reporting items for systematic reviews and meta-analyses: the PRISMA statement. *Int J Surg* 2010; **8**: 336-341 [PMID: 20171303]
- Brand E, Berek JS, Nieberg RK, Hacker NF. Rhabdomyosarcoma of the uterine cervix. Sarcoma botryoides. *Cancer* 1987; **60**: 1552-1560 [PMID: 3621128 DOI: 10.1002/1097-0142(19871001)60]
- Ferguson SE, Gerald W, Barakat RR, Chi DS, Soslow RA. Clinicopathologic features of rhabdomyosarcoma of gynecologic origin in adults. *Am J Surg Pathol* 2007; **31**: 382-389 [PMID: 17325479 DOI: 10.1097/01.pas.0000213352.87885.75]
- Kriseman ML, Wang WL, Sullinger J, Schmeler KM, Ramirez PT, Herzog CE, Frumovitz M. Rhabdomyosarcoma of the cervix in adult women and younger patients. *Gynecol Oncol* 2012; **126**: 351-356 [PMID: 22609112 DOI: 10.1016/j.ygyno.2012.05.008]
- Li RF, Gupta M, McCluggage WG, Ronnett BM. Embryonal rhabdomyosarcoma (botryoid type) of the uterine corpus and cervix in adult women: report of a case series and review of the literature. *Am J Surg Pathol* 2013; **37**: 344-355 [PMID: 23348207 DOI: 10.1097/PAS.0b013e32831826e0271]
- Daya DA, Scully RE. Sarcoma botryoides of the uterine cervix in young women: a clinicopathological study of 13 cases. *Gynecol Oncol* 1988; **29**: 290-304 [PMID: 3278956]
- Guoling Z, Mingzhi C, Baisheng W. Comprehensive treatment for sarcoma botryoides of uterine cervix. *Chin J Cancer Res* 1991; **3**: 68-70 [DOI: 10.1007/BF02671297]
- Dehner LP, Jarzembowski JA, Hill DA. Embryonal rhabdomyosarcoma of the uterine cervix: a report of 14 cases and a discussion of its unusual clinicopathological associations. *Mod Pathol* 2012; **25**: 602-614 [PMID: 22157934 DOI: 10.1038/modpathol.2011.185]
- Sobin LH, Gospodarowicz M, Wittekind C. TNM Classification of Malignant Tumours, 7th ed. Oxford, UK: Wiley-Blackwell, 2009: 206-211
- Mutch DG. The new FIGO staging system for cancers of the vulva, cervix, endometrium and sarcomas. *Gynecol Oncol* 2009; **115**: 325-328 [DOI: 10.1016/j.ygyno.2009.10.050]
- Loh WE, Scrabble HJ, Livanos E, Arboleda MJ, Cavenee WK, Oshimura M, Weissman BE. Human chromosome 11 contains two different growth suppressor genes for embryonal rhabdomyosarcoma. *Proc Natl Acad Sci USA* 1992; **89**: 1755-1759 [PMID: 1347425]
- Calabrese G, Guanciali Franchi P, Stuppia L, Rossi C, Bianchi C, Antonucci A, Palka G. Translocation (8; 11)(q12-13; q21) in embryonal rhabdomyosarcoma. *Cancer Genet Cytogenet* 1992; **58**: 210-211 [PMID: 1551093]
- Sirvent N, Trassard M, Ebran N, Attias R, Pedetour F. Fusion of EWSR1 with the DUX4 facioscapulohumeral muscular dystrophy region resulting from t(4; 22)(q35; q12) in a case of embryonal rhabdomyosarcoma. *Cancer Genet Cytogenet* 2009; **195**: 12-18 [PMID: 19837262 DOI: 10.1016/j.cancergencyto.2009.06.011]
- Nishimura R, Takita J, Sato-Otsubo A, Kato M, Koh K, Hanada R, Tanaka Y, Kato K, Maeda D, Fukayama M, Sanada M, Hayashi Y, Ogawa S. Characterization of genetic lesions in rhabdomyosarcoma using a high-density single nucleotide polymorphism array. *Cancer Sci* 2013; **104**: 856-864 [PMID: 23578105 DOI: 10.1111/cas.12173]
- Dharmarajan KV, Wexler LH, Gavane S, Fox JJ, Schoder H, Tom AK, Price AN, Meyers PA, Wolden SL. Positron emission tomography (PET) evaluation after initial chemotherapy and radiation therapy predicts local control in rhabdomyosarcoma. *Int J Radiat Oncol Biol Phys* 2012; **84**: 996-1002 [PMID: 22560547 DOI: 10.1016/j.ijrobp.2012.01.077]
- Casey DL, Wexler LH, Fox JJ, Dharmarajan KV, Schoder H, Price AN, Wolden SL. Predicting outcome in patients with rhabdomyosarcoma: role of [(18)f]fluorodeoxyglucose positron emission tomography. *Int J Radiat Oncol Biol Phys* 2014; **90**: 1136-1142 [PMID: 25539372 DOI: 10.1016/j.ijrobp.2014.08.005]
- Dong Y, Zhang X, Wang S, Chen S, Ma C. [18F]FDG PET/CT is useful in initial staging, restaging for pediatric rhabdomyosarcoma. *Q J Nucl Med Mol Imaging* 2015 May 21; Epub ahead of print [PMID: 25996974]
- Arndt CA, Hawkins DS, Meyer WH, Sencer SF, Neglia JP, Anderson JR. Comparison of results of a pilot study of alternating vincristine/doxorubicin/cyclophosphamide and etoposide/ ifosfamide with IRS-IV in intermediate risk rhabdomyosarcoma: a report from the Children's Oncology Group. *Pediatr Blood Cancer* 2008; **50**: 33-36 [PMID: 17091486 DOI: 10.1002/pbc.21093]
- Raney RB, Walterhouse DO, Meza JL, Andrassy RJ, Breneman JC, Crist WM, Maurer HM, Meyer WH, Parham DM, Anderson JR. Results of the Intergroup Rhabdomyosarcoma Study Group D9602 protocol, using vincristine and dactinomycin with or without cyclophosphamide and radiation therapy, for newly diagnosed

- patients with low-risk embryonal rhabdomyosarcoma: a report from the Soft Tissue Sarcoma Committee of the Children's Oncology Group. *J Clin Oncol* 2011; **29**: 1312-1318 [PMID: 21357783 DOI: 10.1200/JCO.2010.30.4469]
- 30 **Hawkins DS**, Spunt SL, Skapek SX. Children's Oncology Group's 2013 blueprint for research: Soft tissue sarcomas. *Pediatr Blood Cancer* 2013; **60**: 1001-1008 [PMID: 23255356 DOI: 10.1002/pbc.24435]
- 31 **Navarria P**, Ascolese AM, Tomatis S, Cozzi L, De Rose F, Mancosu P, Alongi F, Clerici E, Lobefalo F, Tozzi A, Reggiori G, Fogliata A, Scorsetti M. Stereotactic body radiotherapy (sbrt) in lung oligometastatic patients: role of local treatments. *Radiat Oncol* 2014; **9**: 91 [PMID: 24694067 DOI: 10.1186/1748-717X-9-91]

**P- Reviewer:** Sonoda K **S- Editor:** Kong JX **L- Editor:** A

**E- Editor:** Wu HL







Published by **Baishideng Publishing Group Inc**

8226 Regency Drive, Pleasanton, CA 94588, USA

Telephone: +1-925-223-8242

Fax: +1-925-223-8243

E-mail: [bpgoffice@wjgnet.com](mailto:bpgoffice@wjgnet.com)

Help Desk: <http://www.wjgnet.com/esps/helpdesk.aspx>

<http://www.wjgnet.com>

