

## Laparoscopic management of a two staged gall bladder torsion

Yadav Kamal Sunder, Sali Priyanka Akhilesh, Garg Raman, Sharma Deborshi, Mehta Hitesh Shantilal

Yadav Kamal Sunder, Sali Priyanka Akhilesh, Garg Raman, Mehta Hitesh Shantilal, G.I. Surgery Department, Lilavati Hospital and Research Centre, Mumbai, Maharashtra 400050, India

Sharma Deborshi, General Surgery Department, Lady Hardinge Medical College, New Delhi, Delhi 110001, India

**Author contributions:** Sunder YK and Akhilesh SP contributed equally to this work; Sunder YK, Akhilesh SP and Raman G designed the research; Sunder YK, Akhilesh SP and Shantilal MH performed the research; Deborshi S analyzed the data; and Akhilesh SP wrote the paper.

**Supported by** Lilavati Hospital and Research Centre.

**Institutional review board statement:** This case report was exempt from the Institutional Review Board standards at Lilavati Hospital and Research Centre.

**Informed consent statement:** The patient involved in this study gave her written informed consent authorizing use and disclosure of her protected health information.

**Conflict-of-interest statement:** All the authors have no conflicts of interests to declare.

**Open-Access:** This article is an open-access article which was selected by an in-house editor and fully peer-reviewed by external reviewers. It is distributed in accordance with the Creative Commons Attribution Non Commercial (CC BY-NC 4.0) license, which permits others to distribute, remix, adapt, build upon this work non-commercially, and license their derivative works on different terms, provided the original work is properly cited and the use is non-commercial. See: <http://creativecommons.org/licenses/by-nc/4.0/>

**Correspondence to:** Yadav Kamal Sunder, MS, G.I. Surgery Department, Lilavati Hospital and Research Centre, A-791, Bandra Reclamation, Bandra West, Mumbai, Maharashtra 400050, India. [dockamalyadav@gmail.com](mailto:dockamalyadav@gmail.com)  
Telephone: +91-99-20375758  
Fax: +91-22-26407655

Received: June 29, 2015  
Peer-review started: July 12, 2015

First decision: August 14, 2015

Revised: August 21, 2015

Accepted: September 25, 2015

Article in press: September 28, 2015

Published online: December 27, 2015

### Abstract

Gall bladder torsion (GBT) is a relatively uncommon entity and rarely diagnosed preoperatively. A constant factor in all occurrences of GBT is a freely mobile gall bladder due to congenital or acquired anomalies. GBT is commonly observed in elderly white females. We report a 77-year-old, Caucasian lady who was originally diagnosed as gall bladder perforation but was eventually found with a two staged torsion of the gall bladder with twisting of the Riedel's lobe (part of tongue like projection of liver segment 4A). This together, has not been reported in literature, to the best of our knowledge. We performed laparoscopic cholecystectomy and she had an uneventful post-operative period. GBT may create a diagnostic dilemma in the context of acute cholecystitis. Timely diagnosis and intervention is necessary, with extra care while operating as the anatomy is generally distorted. The fundus first approach can be useful due to altered anatomy in the region of Calot's triangle. Laparoscopic cholecystectomy has the benefit of early recovery.

**Key words:** Gall bladder torsion; Gangrenous gall bladder; Perforated gall bladder; Two staged torsion of the gall bladder; Laparoscopic cholecystectomy

© **The Author(s) 2015.** Published by Baishideng Publishing Group Inc. All rights reserved.

**Core tip:** Gall bladder torsion is a rare surgical entity that should be considered in a case of suspicious acute cholecystitis not responding to conservative management. Delay in diagnosis and treatment may lead to gall bladder gangrene, gall bladder perforation,

biliary peritonitis or septicaemia. The condition is seldom recognized preoperatively due to its clinical resemblance to acute cholecystitis. We report a 77-year-old, Caucasian lady who was originally diagnosed as gall bladder perforation but was eventually found to have a two staged torsion of the gall bladder with twisting of the Riedel's lobe. This dual entity has so far not been reported in literature.

Sunder YK, Akhilesh SP, Raman G, Deborshi S, Shantilal MH. Laparoscopic management of a two staged gall bladder torsion. *World J Gastrointest Surg* 2015; 7(12): 403-407 Available from: URL: <http://www.wjgnet.com/1948-9366/full/v7/i12/403.htm> DOI: <http://dx.doi.org/10.4240/wjgs.v7.i12.403>

## INTRODUCTION

Gall bladder torsion (GBT) is a process, in which there is a mechanical organo-axial torsion that occurs along the gall bladder's longitudinal axis involving cystic pedicle, with a pre-requisite of freely mobile gall bladder. Wendel<sup>[1]</sup> first described gall bladder torsion in 1898. Thereafter over 300 cases have been reported in literature and only few were operated laparoscopically. However till date, there has been no report in literature regarding a "two-staged torsion" along with a "tornado" like twisting of the Riedel's lobe.

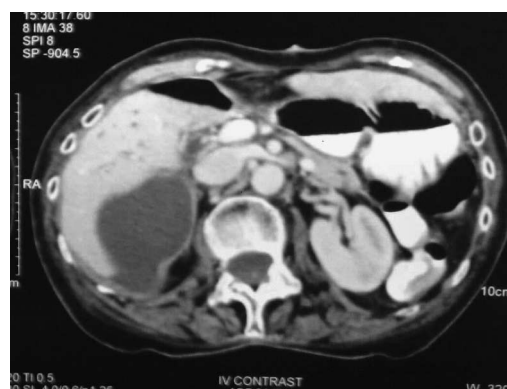GBT commonly occurs in the geriatric population, with 85% of patients above 60 years of age. It is found more frequently in the white race with female to male ratio of 3:1<sup>[2]</sup>. As this entity is rare and its symptoms overlap with those of acute cholecystitis, it is difficult to diagnose preoperatively<sup>[3,4]</sup>. Timely intervention may prevent the morbidity and mortality associated with GBT. We present here a rare case of a two staged gall bladder torsion masquerading as a perforated gall bladder.

## CASE REPORT

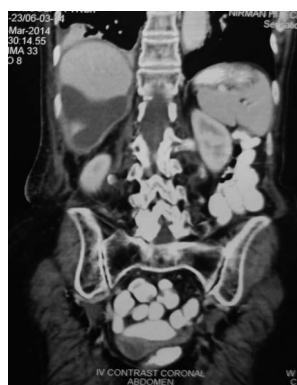
A 77-year-old, thin, Caucasian lady presented with acute pain in the right upper abdomen, radiating to the back for 4 d. There was no history of fever, jaundice or similar complaints in the past. On general examination, she was afebrile with a pulse rate of 96/min. She also had scoliosis. Her abdomen was soft, tenderness and guarding was present in right hypochondrium and Murphy's sign was positive.

There were no signs of peritonitis. Laboratory investigations showed WBC 14000/cu mm and normal liver function tests. The CT scan showed a peripherally enhancing fluid collection along the segment 5 and 6 of the liver (Figures 1 and 2), and no gall bladder was seen in the gall bladder fossa. A diagnosis of gall bladder perforation with a subhepatic collection was made.

The patient was advised laparoscopic cholecy-



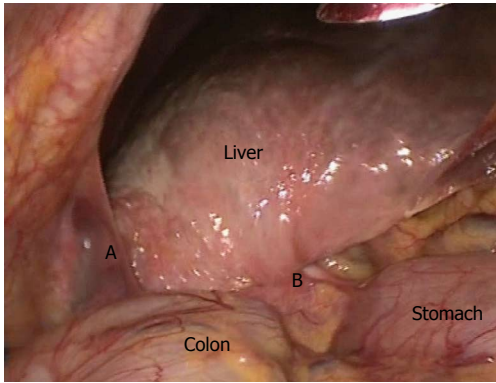
**Figure 1** Axial section showing peripherally enhancing fluid density area seen along the segment 5 and 6 of the liver.



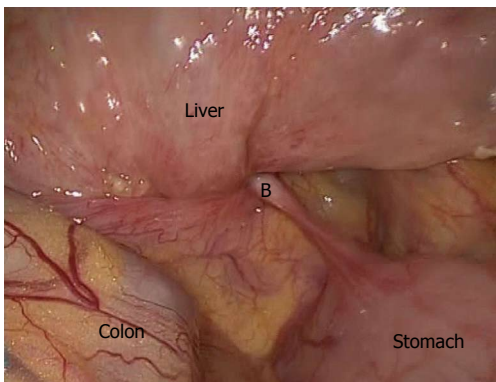
**Figure 2** Coronal section showing peripherally enhancing fluid density area seen along the segment 6 of the liver. The gall bladder is not seen in the gall bladder fossa.

stectomy but she refused surgery. She was managed conservatively with bowel rest, intravenous fluids, injectable antibiotics and analgesics. The patient did not improve and had increased WBC counts. After 4 d, she gave consent for surgery.

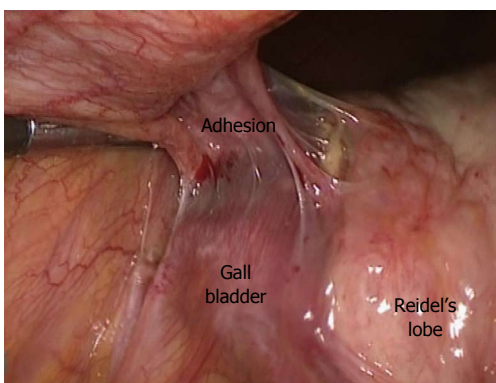
Intraoperatively, we found thick peritoneal folds arising from the pylorus and the hepatic flexure that were pulled into the region of Calot's triangle along with the Riedel's lobe. The gall bladder was adherent to the lateral abdominal wall (Figures 3-5). However, it was still unclear whether these pulled in structures contained the hilar structures or the cystic pedicle. As the anatomy was grossly distorted, we used the fundus first approach to avoid any injury to the hilar structures (Figure 6). After adhesiolysis, the gall bladder was found to be gangrenous till its neck. The gall bladder itself was rotated through 360° in the anticlockwise direction around the fixed cystic pedicle and its neck. There also was a band like adhesion between the neck and the Riedel's lobe (Figure 7). After releasing this band, we noticed a remnant 90° anticlockwise rotation. This was also derotated (Figure 8). The cystic duct was found to be unusually long and twisted (Figures 8 and 9). The common bile duct (CBD) was kinked, pulled anteriorly and was lying close to the anterior edge of the liver. The cholecystectomy was



**Figure 3** Laparoscopic view showing distorted anatomy. A: Adhesions between the gall bladder and the lateral abdominal wall; B: Pulled in peritoneal fold from the pylorus of the stomach and the hepatic flexure.



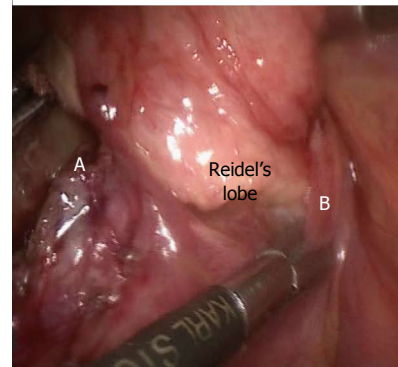
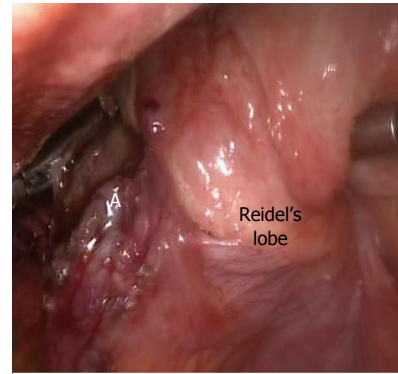
**Figure 4** Zoomed in view of Calot's region. B: Pulled in peritoneal fold from the pylorus of the stomach and the hepatic flexure.



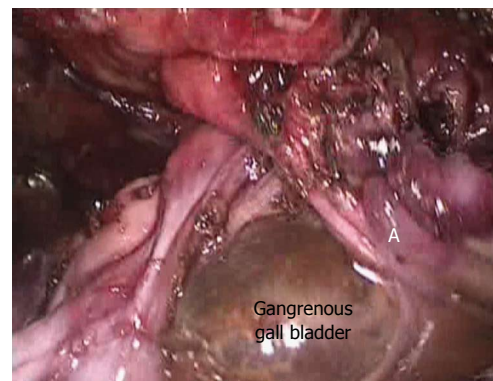
**Figure 5** Adhesions between the gall bladder and the lateral abdominal wall.

thereafter safely completed.

In our case, the gall bladder may have undergone a two staged torsion. The first stage is a 90° anti-clockwise rotation during the initial period of symptoms. This might have been followed by the adhesive band formation between the neck and the anomalous Riedel's lobe. Subsequently, the gall bladder might have undergone the second stage of a 360° anti-clockwise rotation, this time taking the Riedel's lobe and the peritoneal folds (arising from the pylorus and



**Figure 6** Rotated Riedel's lobe. A: Gangrenous fundus of the gall bladder; B: Pulled in peritoneal fold from the pylorus of the stomach and the hepatic flexure.



**Figure 7** Gangrenous gall bladder after adhesiolysis. A: Adhesive band between the neck of the gall bladder and the Riedel's lobe.

the hepatic flexure). The delay in surgery may have led to the adhesions between the gall bladder and its surrounding structures after undergoing torsion.

An intra-operative cholangiogram was done and it was normal. The gall bladder was removed in an endo-bag through umbilical port. It did not contain any calculi. The histopathology report showed features of gangrenous gall bladder. Postoperatively, the patient improved and was discharged after three days.

## DISCUSSION

GBT has been reported in patients ranging from 2 to 100 years old patients<sup>[5,6]</sup>, more frequently in elderly white females. Loss of fat and elasticity



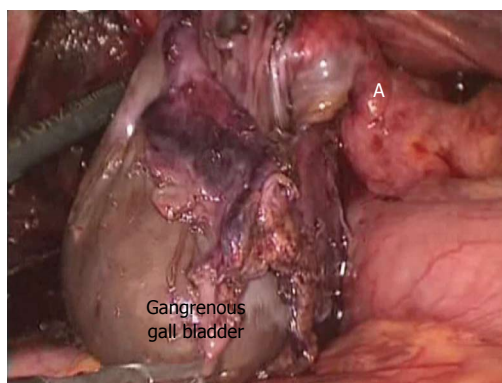


Figure 8 Gall bladder found gangrenous till its neck.

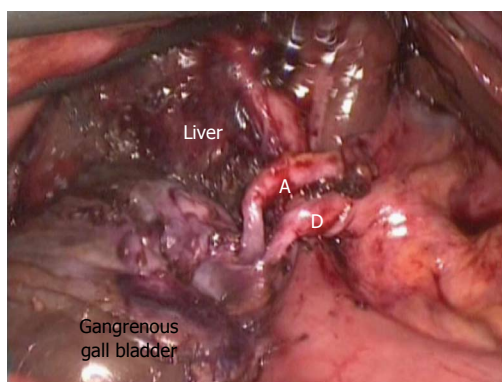


Figure 9 After derotation, the gall bladder in its normal position with the long and twisted cystic artery (A) and cystic duct (D).

may be responsible for its occurrence in the elderly population<sup>[7]</sup>.

Gross classified the congenital floating gall bladder into two types. In type 1, the gall bladder and cystic duct are attached to the inferior surface of the liver *via* mesentery and in type 2, only the cystic duct is attached to the liver<sup>[8]</sup>.

The pre-requisite for torsion is a “floating” gall bladder, where the entire organ is covered with peritoneum and is connected to the porta by a cystic pedicle enveloped in peritoneum. Torsion can also occur when the neck, or, along with the neck, part of gall bladder body is attached to the liver with a long pedicle. Several precipitating factors have been proposed as intense peristalsis of the neighbouring organs, blunt trauma to the abdomen, tortuous atherosclerotic cystic artery and kypho-scoliosis. Gall bladder stones are found only in 20%-33% of patients. Clockwise rotation of the gall bladder can occur due to intense stomach peristalsis or anti-clockwise due to transverse colon peristalsis<sup>[7]</sup>. But, there are no strong evidences to support these factors. Peristalsis is a continuous phenomenon, with up to 5% of the population have floating gall bladder<sup>[2,9]</sup>. In our case, there was a two staged torsion along with twisting of the Riedel's lobe. To cause this type of torsion, an abnormally large force may be required and source of this force needs to be

evaluated, as the above said precipitating factors do not seem to be the culprit.

Surgeons should have a high index of suspicion for GBT in acute cholecystitis patients, who fail to improve with conservative management. These patients should be considered for further careful imaging studies and prompt surgical intervention is required.

However, our patient presented with features of acute cholecystitis and on further imaging (CT scan), it was diagnosed as gall bladder perforation. Eventually, on laparoscopy, we found GBT with partially twisted Riedel's lobe with the gall bladder being loosely adhered to the surrounding structures due to delay in surgical intervention.

GBT is difficult to diagnose pre-operatively because it is rare and the presentation is similar to that of acute cholecystitis<sup>[10,11]</sup>. Very few cases have been diagnosed precisely on pre-operative imaging<sup>[12]</sup>. The classical findings of GBT on ultrasound are a large “floating gall bladder”. On CT scan, presence of the gall bladder outside its normal position, an echogenic conical structure (twisted mesentery) and a prominent cystic artery to the right of gall bladder, GBT should be borne in mind<sup>[4,13,14]</sup>. MRI abdomen may accurately visualize the twisted cystic duct than any other imaging modality<sup>[15]</sup>. In very few cases, CT abdomen showed hugely enlarged gall bladder with its unusual shape and configuration<sup>[14]</sup>. GBT has been treated mostly by open surgical approach in past with few case reports using the laparoscopic approach. Laparoscopy adds the advantage of clearing the diagnostic dilemma and faster recovery.

As the anatomy is not very clear in GBT, one should be careful while dissecting in the region of the Calot's triangle, as chances of CBD injury are high due to distorted anatomy. The fundus first approach can be useful due to distorted anatomy in the region of Calot's triangle. The overall mortality in gall bladder torsion is approximately 5%<sup>[16]</sup>.

Gall bladder torsion is an uncommon surgical entity that should be considered in a case of suspicious acute cholecystitis not improving on conservative management. Delay in diagnosis may lead to gall bladder gangrene, gall bladder perforation, biliary peritonitis, or septicaemia. Such complications may obscure the preoperative diagnosis of GBT. A rare possibility of an accompanying twisted Riedel's lobe alters the anatomy and makes dissection cumbersome. Laparoscopic cholecystectomy is more feasible and safer than open approach.

## COMMENTS

### Case characteristics

A 77-year-old Caucasian lady with right upper quadrant pain since 4 d.

### Clinical diagnosis

Her abdomen was soft with tenderness and guarding in the right hypochondrium and Murphy's sign was positive.

**Differential diagnosis**

Acute cholecystitis, gall bladder perforation.

**Laboratory diagnosis**

WBC count 14000/cu, the other laboratory reports were within normal limits.

**Imaging diagnosis**

The computed tomography scan showed a peripherally enhancing fluid collection along segments 5 and 6 of the liver and no gall bladder was seen in the gall bladder fossa.

**Pathological diagnosis**

Final Histopathological report was suggestive of gangrenous gall bladder.

**Treatment**

Laposcopic cholecystectomy.

**Related reports**

Gall bladder torsion (GBT) is a rare entity, mostly seen in the geriatric population, masquerading as acute cholecystitis. In this case, it presented as gall bladder perforation. A two staged torsion was seen probably due to delayed surgical treatment.

**Term explanation**

In GBT, there is a mechanical organo-axial torsion that occurs along its longitudinal axis involving the cystic pedicle, with a prerequisite of a freely mobile gall bladder.

**Experiences and lessons**

This entity is seldom diagnosed preoperatively. It mimics acute cholecystitis. The dissection in the region of Calot's triangle must be done carefully due to the distorted anatomy.

**Peer-review**

This is uncommon case for laparoscopic cholecystectomy.

**REFERENCES**

- 1 **Wendel AV.** VI. A Case of Floating Gall-Bladder and Kidney complicated by Cholelithiasis, with Perforation of the Gall-Bladder. *Ann Surg* 1898; **27**: 199-202 [PMID: 17860545]
- 2 **Stieber AC,** Bauer JJ. Volvulus of the gallbladder. *Am J Gastroenterol* 1983; **78**: 96-98 [PMID: 6823944]
- 3 **Narchi H,** Thomas M. Acute abdominal pain in a 6-year-old child. *Eur J Pediatr* 1999; **158**: 943-945 [PMID: 10541955]
- 4 **Kitagawa H,** Nakada K, Enami T, Yamaguchi T, Kawaguchi F, Nakada M, Yamate N. Two cases of torsion of the gallbladder diagnosed preoperatively. *J Pediatr Surg* 1997; **32**: 1567-1569 [PMID: 9396527]
- 5 **Schroder DM,** Cusumano DA. Laparoscopic cholecystectomy for gallbladder torsion. *Surg Laparosc Endosc* 1995; **5**: 330-334 [PMID: 7551289]
- 6 **Taha AM,** Welling RE. Acute torsion of the gallbladder in a 100-year-old female patient. *J Natl Med Assoc* 1985; **77**: 404-410 [PMID: 3999156]
- 7 **Saber A.** Gall bladder Volvulus [Internet]. Emedicine.medscape.com. 2015 [cited 2015 Mar 8]. Available from: URL: <http://emedicine.medscape.com/article/195100-overview#a0102>
- 8 **Gross RE.** Congenital anomalies of the gall bladder. A review of 148 cases with report of double gall bladder. *Arch Surg* 1936; **32**: 131-162
- 9 **Christoudias GC.** Gallbladder volvulus with gangrene. Case report and review of the literature. *JSLS* 1997; **1**: 167-170 [PMID: 9876667]
- 10 **Carter R,** Thompson RJ, Brennan LP, Hinshaw DB. Volvulus of the gallbladder. *Surg Gynecol Obstet* 1963; **116**: 105-108 [PMID: 14018964]
- 11 **Wu BG,** Wu CC, Chang YJ. Torsion of the gallbladder. *Surgery* 2008; **143**: 294-295 [PMID: 18260186]
- 12 **Shaikh AA,** Charles A, Domingo S, Schaub G. Gallbladder volvulus: report of two original cases and review of the literature. *Am Surg* 2005; **71**: 87-89 [PMID: 15757065]
- 13 **Yeh HC,** Weiss MF, Gerson CD. Torsion of the gallbladder: the ultrasonographic features. *J Clin Ultrasound* 1989; **17**: 123-125 [PMID: 2492561]
- 14 **Merine D,** Meziane M, Fishman EK. CT diagnosis of gallbladder torsion. *J Comput Assist Tomogr* 1987; **11**: 712-713 [PMID: 3597901]
- 15 **Kimura T,** Yonekura T, Yamauchi K, Kosumi T, Sasaki T, Kamiyama M. Laparoscopic treatment of gallbladder volvulus: a pediatric case report and literature review. *J Laparoendosc Adv Surg Tech A* 2008; **18**: 330-334 [PMID: 18373471 DOI: 10.1089/lap.2007.0057]
- 16 **Mouawad NJ,** Crofts B, Streu R, Desrochers R, Kimball BC. Acute gallbladder torsion - a continued pre-operative diagnostic dilemma. *World J Emerg Surg* 2011; **6**: 13 [PMID: 21489292 DOI: 10.1186/1749-7922-6-13]

**P- Reviewer:** Al-Gayyar MMH, Lee KG

**S- Editor:** Qiu S **L- Editor:** A **E- Editor:** Liu XM





Published by **Baishideng Publishing Group Inc**

8226 Regency Drive, Pleasanton, CA 94588, USA

Telephone: +1-925-223-8242

Fax: +1-925-223-8243

E-mail: [bpgoffice@wjgnet.com](mailto:bpgoffice@wjgnet.com)

Help Desk: <http://www.wjgnet.com/esps/helpdesk.aspx>

<http://www.wjgnet.com>

