

2016 Laparoscopic Surgery: Global view

Review of 500 single incision laparoscopic colorectal surgery cases - Lessons learned

Deborah S Keller, Juan R Flores-Gonzalez, Sergio Ibarra, Eric M Haas

Deborah S Keller, Juan R Flores-Gonzalez, Sergio Ibarra, Eric M Haas, Colorectal Surgical Associates, Houston, TX 77054, United States

Deborah S Keller, Eric M Haas, Division of Colon and Rectal Surgery, Houston Methodist Hospital, Houston, Tx 77030, United States

Eric M Haas, Division of Minimally Invasive Surgery, Department of Surgery, The University of Texas Medical School at Houston, Houston, TX 77054, United States

Author contributions: Keller DS contributed to conception and design of the study, acquisition of data, analysis and interpretation of data; drafting the article, critical analysis; approval of final version; Flores-Gonzalez JR, Ibarra S contributed to acquisition of data, analysis of data, drafting the article; approval of final version; Haas EM contributed to conception and design of the study, analysis and interpretation of data, critical analysis, approval of final version.

Conflict-of-interest statement: There is no conflict of interest associated with any of the authors on this manuscript.

Open-Access: This article is an open-access article which was selected by an in-house editor and fully peer-reviewed by external reviewers. It is distributed in accordance with the Creative Commons Attribution Non Commercial (CC BY-NC 4.0) license, which permits others to distribute, remix, adapt, build upon this work non-commercially, and license their derivative works on different terms, provided the original work is properly cited and the use is non-commercial. See: <http://creativecommons.org/licenses/by-nc/4.0/>

Correspondence to: Deborah S Keller, MS, MD, Colorectal Surgical Associates, LLP LTD, 7900 Fannin Street, 2700, Houston, TX 77054, United States. debby_keller@hotmail.com
Telephone: +1-713-7900600
Fax: +1-713-7900616

Received: July 2, 2015
Peer-review started: July 6, 2015
First decision: August 26, 2015
Revised: September 9, 2015

Accepted: November 19, 2015

Article in press: November 19, 2015

Published online: January 14, 2016

Abstract

Single incision laparoscopic surgery (SILS) is a minimally invasive platform with specific benefits over traditional multiport laparoscopic surgery. The safety and feasibility of SILS has been proven, and the applications continue to grow with experience. After 500 cases at a high-volume, single-institution, we were able to standardize instrumentation and operative steps, as well as develop adaptations in technique to help overcome technical and ergonomic challenges. These technical adaptations have allowed the successful application of SILS to technically difficult patient populations, such as pelvic cases, inflammatory bowel disease cases, and high body mass index patients. This review is a frame of reference for the application and wider integration of the single incision laparoscopic platform in colorectal surgery.

Key words: Laparoscopic colectomy; Minimally invasive colorectal surgery; Single-incision laparoscopic surgery

© The Author(s) 2016. Published by Baishideng Publishing Group Inc. All rights reserved.

Core tip: As the surgery paradigm progresses towards natural orifice transluminal endoscopic surgery, single incision laparoscopic surgery (SILS) is a valuable minimally invasive platform with specific clinical benefits. After experience from 500 SILS cases, we were able to standardize instrumentation and operative steps, and have developed technical adaptations for successful application in difficult patient populations. This review is a frame of reference for the application and wider integration of the single incision laparoscopic

platform in colorectal surgery.

Keller DS, Flores-Gonzalez JR, Ibarra S, Haas EM. Review of 500 single incision laparoscopic colorectal surgery cases - Lessons learned. *World J Gastroenterol* 2016; 22(2): 659-667 Available from: URL: <http://www.wjgnet.com/1007-9327/full/v22/i2/659.htm> DOI: <http://dx.doi.org/10.3748/wjg.v22.i2.659>

INTRODUCTION

Minimally invasive platforms continue to progress towards incisionless, natural orifice transluminal endoscopic surgery (NOTES) to reduce surgical trauma^[1]. NOTES remains in experimental stages, and there is ongoing work is still to refine techniques^[2]. In the meantime, single incision laparoscopic surgery (SILS) is the closest platform available for routine clinical practice. SILS, also referred to as Single Port Access (SPA) and laparoendoscopic single-site surgery (LESS), combines the cosmetic advantage and reduced incision principles of NOTES with the familiarity of performing surgical procedures with standard surgical instruments^[3]. SILS was first reported in 1999 for cholecystectomy^[4], then successfully applied to colorectal surgery in 2008^[3,5]. Since that time, SILS has been proven safe and feasible for both benign and malignant colorectal disease^[6-15]. In fact, SILS has been suggested as a method to improve the outcomes of traditional multiport laparoscopic surgery with reduced tissue trauma, reduced perioperative pain and narcotic use, improved cosmesis, lower rates of port-site related complications, and shorter lengths of stay^[9,14,16-20].

SILS has been reported as the next major advance in the progression of minimally invasive surgical approaches feasible in generalized use^[21,22]. Given the published support and our own outcomes, SILS has been the main minimally invasive platform used in our practice since 2008. Since that time, we have completed more than 700 single incision laparoscopic colorectal resection cases, continuously learning from our experiences, expanding the application of the SILS platform, and redefining our technique^[23-31].

During the initial 500 cases at a high-volume, single-institution, we were able to standardize instrumentation and operative steps, as well as develop adaptations in technique to help overcome technical and ergonomic challenges. The goal is for this review is to be used as a frame of reference for the application and wider integration of the single incision laparoscopic platform in colorectal surgery.

DATABASE REVIEW

After Institutional Review Board approval, a prospective divisional database was reviewed for elective colorectal

resection cases from July 2009 to the present. The initial 500 consecutive cases performed through a single incision laparoscopic approach were identified and included in the analysis. All cases were performed by 1 of 2 board-certified colorectal surgeons; both surgeons were trained in laparoscopy and moderate experienced (at least 150 colorectal resections and approximately 50 laparoscopic colorectal resection) at the start of the study period. Patients were excluded if under 18 years of age, had incomplete medical records, underwent a non-resection or stoma closure procedure, or case performed through a multiport, hand-assisted laparoscopy or open approach. Cases converted to multiport, hand-assisted laparoscopy or open surgeries were included for intention to treat analysis, and the reason for conversion was assessed.

Patient demographic, perioperative procedural, and short-term outcome data was evaluated. Data fields collected included age, gender, body mass index (BMI), ASA class, operative type (emergent/elective), operative procedure, operative time, blood loss, Intensive Care Unit stay required, length of stay, and postoperative complications, readmission, reoperation, and mortality rates. Complications were graded using the validated Clavien-Dindo Classification^[32]. All patients were managed postoperatively with a standardized multimodal Enhanced Recovery Protocol (ERP). Alvimopan was used routinely in the ERP from 2011 onward. In 2013, local wound infiltration with long acting liposomal bupivacaine (EXPAREL®, Pacira Pharmaceuticals, Inc., Parsippany, NJ) were performed at the port site at the completion of each case. In 2014, a post-induction pre-incision Transvs Abdominus Plane block with long acting liposomal bupivacaine was also routinely added to the protocol.

GENERAL TECHNICAL STEPS

For SILS procedures, there are several commercially produced access platforms available, with the most commonly used being the SILS™ Port (Covidien, Mansfield, Massachusetts, United States) and the GelPOINT® platform (Applied Medical, Rancho Santa Margarita, California, United States).

Our operative steps for common SILS colorectal procedures have been previously described and standardized^[25,27-29,31]. Port placement is critical, as proper placement can facilitate dissection, visualization, and the overall technical ease of a single-incision operation. Most procedures access the abdomen through a 2.5 cm skin incision at the umbilicus, allowing the incision to be "hidden" and giving full access to multiple quadrants. The umbilical stump is divided to expose the underlying fascia. The stump is completely detached from the fascia, allowing intraperitoneal access through the natural umbilical hernia defect, which is opened to 4 cm. The fascial incision can be opened further as needed without extending the overlying skin incision.

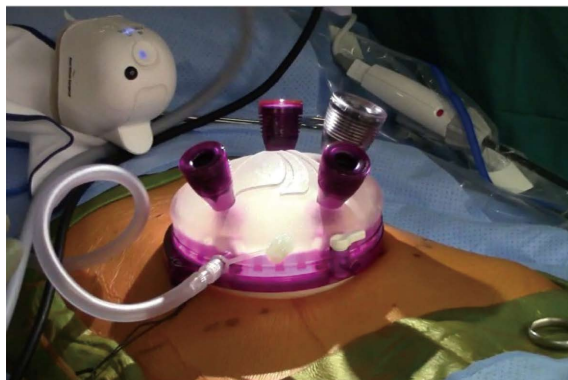

Figure 1 Single incision laparoscopic surgery colorectal set-up.

For pelvic or cases requiring access to multiple quadrants, a Pfannenstiel incision may be favorable. In these cases, a 4 cm skin incision is made, and the underlying fascia is opened to 4 cm. In cases where a stoma is planned, the predetermined ostomy site may also be used for the SILS port, resulting in “scarless” surgery^[7,33-35].

The sleeve of the access device (GelPOINT, Applied Medical, Rancho Santa Margarita, CA) is placed into the abdominal cavity, and a lap sponge is introduced to aid in small bowel retraction and cleaning the camera lens throughout the procedure. The instrumentation is also standardized. Three trocars are placed through the device - 1 for the camera, 1 for the atraumatic bowel grasper, and 1 for the energy device, the cap is secured, and pneumoperitoneum is created. As needed for retraction, an additional atraumatic grasper is placed in the 4th trocar site. A 30° 5-mm camera with a right-angle light cord adaptor is used to allow rotation without interfering with the operator and to reduce external collisions. An experienced camera driver is helpful, as knowing tricks to decrease collisions and optimize visualization without forced movements can reduce the risk of inadvertent injury. The SILS set-up is seen in Figure 1.

A medial-to-lateral approach to bowel mobilization is performed with early identification and isolation of the vascular pedicle. We use a hand-over-fist triangulation technique for developing the retroperitoneal plane. With this technique, the nondominant hand holds an atraumatic grasper to lift the tissue, while the dominant hand holds an energy device to systematically advance the dissection through the retroperitoneal plane^[28]. Once critical structures are identified, the vascular pedicle is divided and the retroperitoneal plane is further developed. When the full mobilization of the retroperitoneal plane has been achieved, a lateral-to-medial mobilization is performed to complete mobilization. In the lateral-to-medial approach, the non-dominant instrument retracts the colon medially while the dominant instrument takes down the lateral peritoneal attachments. When the intended resection segment is fully mobilized, the segment is extracted

through the access device. For right-sided lesions and transverse colectomy, an extracorporeal anastomosis is performed, while for procedures requiring an anastomosis to the rectum, an intracorporeal circular stapled anastomosis is completed under laparoscopic visualization.

Overall experience

Between 2009 and 2014, we performed our initial 500 SILS colorectal resections. In our unselected case series, the mean patient age was 57.6 (SD 15.4) years, and the mean BMI was 26.5 (SD 4.7) kg/m². More than half of the patients (57.6%) had prior abdominal surgery. The main indications for operations were colon cancer ($n = 156$, 31.2%), diverticulitis ($n = 133$, 26.6%), and an unresectable polyp ($n = 114$, 22.8%). The main procedures performed were a right hemicolectomy/ileocolic resection ($n = 197$, 39.4%), an anterior resectosigmoidectomy ($n = 134$, 26.8%), and a Low Anterior Resection ($n = 69$, 13.8%) (Table 1). The mean operative time was 149.9 (SD 62.0) min. The average blood loss was 64.1 (SD 49.8) mL. Eleven patients had an intraoperative complication (enterotomy $n = 4$, bleeding $n = 3$, cystotomy $n = 2$, splenic injury $n = 2$, thermal injury $n = 1$). Conversion from SILS was required in 34 (6.8%) of these cases. The reasons for conversion were adhesions ($n = 13$), obesity/difficult reach ($n = 5$), poor visualization ($n = 5$), dense specimen ($n = 4$), enterotomy ($n = 3$), bleeding ($n = 2$), and anastomotic failure ($n = 2$).

During the 500 case series, Alvimopan was used in 396 patients (79.2%), local wound infiltration with long acting liposomal bupivacaine was used in 104 patients (20.8%), and a post-induction pre-incision Trans vs Abdominus Plane block with local wound infiltration using long acting liposomal bupivacaine was used in 138 patients (27.6%).

Postoperatively, 49 patients had a complication (9.8%). Twelve were Clavien Class 1 (ileus, $n = 7$; dehydration, $n = 5$), 16 were Clavien Class 2 (superficial Site Infection, $n = 6$; bleeding, $n = 5$; and urinary tract infection, fever, pulmonary embolism, abdominal pain, and *C. Difficile* infection, all $n = 1$); 18 were class 3 (anastomotic leak, $n = 9$; intrabdominal abscess, $n = 8$, perforation, $n = 1$), 2 were class 4 (stroke and cardiac issue), and one Class 5 (pulmonary). Twenty-two patients were readmitted (4.4%), and 10 underwent an unplanned reoperation (2.0%) within 30 d of the index operation. The mean hospital length of hospital stay was 3.9 ± 3.1 (median 3, range: 2-31) d. There was one 30-d mortality in a patient with extensive pulmonary metastases who underwent a semi-urgent palliative resection. Postoperative details are seen in Table 2.

Special populations

With experience, SILS has been expanded and applied to specific “difficult” patient populations. Using

Table 1 Diagnosis and procedure for 1st 500 single incision laparoscopic surgery cases *n* (%)

Diagnosis	
Colon cancer	156 (31.2)
Diverticulitis	133 (26.6)
Polyp	114 (22.8)
IBD	47 (9.4)
Constipation	19 (3.8)
Rectal cancer	18 (3.6)
Incontinence/prolapse	4 (0.8)
Endometriosis	2 (0.4)
Other	7 (1.4)
Procedure	
Right hemicolectomy/ileocolic resection	197 (39.4)
Anterior resectosigmoidectomy	134 (26.8)
Low anterior resection	69 (13.8)
Total/subtotal abdominal colectomy	47 (9.4)
Sigmoid/left Hemicolectomy	31 (6.2)
Transverse colectomy	9 (1.8)
Ileal pouch anal anastomosis	9 (1.8)
Small bowel resection	4 (0.8)

IBD: Inflammatory bowel disease.

the knowledge gained from 500 cases, technical adaptations have been developed to successfully use the SILS platform in these cases.

PELVIC PROCEDURES

For pelvic procedures, the reach of the laparoscopic instruments and visualization are an issue. In 2011, after 140 SILS cases, a SILS + 1 approach was developed to address these issues of operating in the pelvis with a minimally invasive approach. In SILS + 1, a 4 cm Pfannenstiel skin incision is made for the access platform and a single port is placed through the umbilicus for the camera. This adaption allows for an expanded view of the pelvis and abdomen and addressed technical limitation of straight SILS, including better access to the splenic flexure and fewer external clashes between the surgeon and the camera holder. SILS + 1 has been described and validated in pelvic colorectal surgery, and demonstrates the versatility of the platform^[27,28].

Outcomes with the SILS + 1 approach for pelvic colorectal cases have been described in a few reports in the existing literature. Kawamata *et al.*^[36] performed a comparison evaluation of SILS + 1 and multiport laparoscopic surgery for anterior resectosigmoidectomy, finding the platform was safe and effective. Case series describing SILS + 1 results in pelvic cases include a 16 patient series of anterior resectosigmoidectomy for rectal cancer patients^[37], a 20 patient tumor specific mesorectal excision in colorectal cancer patients^[38], and single cases of an APR with lateral pelvic lymph node dissection for treating rectal cancer^[39], then for total mesorectal excision (TME) with lateral pelvic lymph node dissection^[40]. In all reports, the authors

Table 2 Outcomes for the 1st 500 single incision laparoscopic surgery cases *n* (%)

Variable	Value
Age (yr), mean ± SD	57.61 ± 15.54
BMI (kg/m ²), mean ± SD	26.47 ± 4.70
ASA score, median (range)	2 (2-4)
Previous abdominal operation	288 (57.6)
Operative time (min), mean ± SD	149.89 ± 61.98
Blood loss (mL), mean ± SD	64.13 ± 49.78
Intraoperative complications	11 (2.2)
Stoma created	66 (13.2)
Intraoperative conversion	34 (6.8)
Postoperative ICU stay	8 (1.6)
Postoperative complications	49 (9.8)
Clavien class 1	12
Clavien class 2	16
Clavien class 3	18
Clavien class 4	2
Clavien class 5	1
Length of stay (d), mean ± SD	3.91 ± 3.06
Readmission	22 (4.4)
Unplanned re-operation	10 (2.0)
Mortality	1 (< 1.0)

found the technique was safe, technically feasible, and did not compromise oncologic safety.

In the present SILS 500 case series, there was a total of 138 SILS + 1 cases performed. The platform was applied for diverticulitis (*n* = 82), resectosigmoid junction cancer (*n* = 21), rectal cancer (*n* = 15), unresectable polyp (*n* = 12), and inflammatory bowel disease (*n* = 6). The procedures performed were an anterior resectosigmoidectomy (*n* = 117), segmental resection (*n* = 9), low anterior resection (*n* = 5), ileal pouch anal anastomosis (*n* = 4), and a total abdominal colectomy (*n* = 3). The mean operating time for these procedures was 181.65 (SD 58.69) min. With the technical adaption, only 4 cases required intraoperative conversion (< 1.0%); the reasons for conversion were bulky tumors (*n* = 2), a complex fistula (*n* = 1), and dense adhesions (*n* = 1). The mean final Pfannenstiel incision length was 4.2 (SD 0.8) cm. Postoperatively, the mean LOS was 3.44 (SD 2.02) d and there were 5 complications (ileus, *n* = 3; intrabdominal abscess, *C. Difficile* infection). Two complications required readmissions (intrabdominal abscess, *C. Difficile* infection), but there were no reoperations and no mortalities in the SILS + 1 sub-group.

In a direct, case-matched comparison of SILS and SILS + 1 in pelvic colorectal cases, we found a significantly shorter operative time (mean 166.6 min vs 178.0 min, *P* = 0.03) and significantly lower conversion rate to multiport or open surgery (*n* = 1, 1.1% vs *n* = 5, 11.4%, *P* = 0.02) using the SILS+1 vs the SILS approach (Table 3)^[41]. Postoperatively, the length of stay, readmission or complication rates were comparable across the cohorts. Thus, the additional port improved visualization and outcomes without any impact on quality outcomes (Figure 2).

Table 3 Single incision laparoscopic surgery *vs* single incision laparoscopic surgery + 1 outcome data *n* (%)

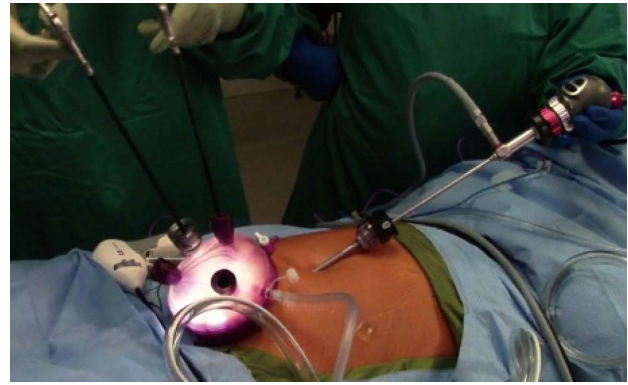
Value	SILS (<i>n</i> = 44)	SILS + 1 (<i>n</i> = 88)	<i>P</i> value
Diagnosis			0.77
Diverticulitis	40 (90.9)	77 (87.5)	
Rectal cancer	4 (9.1)	11 (12.5)	
Gender			1.00
Female	22 (50)	44 (50)	
Male	22 (50)	44 (50)	
Age (yr)	56.14 (12.83)	57.16 (10.98)	0.63
Body mass index (kg/m ²), mean ± SD	26.57 ± 4.36	27.63 ± 4.50	0.42
ASA class, median	2 (range 2-3)	2 (range 2-4)	0.86
Procedure			1.00
Anterior rectosigmoidectomy	38 (86.4)	76 (86.4)	
Low anterior resection	6 (13.6)	12 (13.6)	
Operative time (min), mean ± SD	178.0 ± 70.0	166.6 ± 48.4	0.05 ¹
Conversion rate	5 (11.4)	1 (1.1)	0.02 ¹
Intraoperative complications	1 (2.3)	1 (1.1)	1.00
Length of stay (d), mean ± SD	3.45 ± 1.00	3.56 ± 1.49	0.45
Postoperative complications	2 (4.5)	-	0.11
Readmission (30 d)	1 (2.3)	-	0.33

¹Statistically significant values at an alpha level of 0.05.

ULCERATIVE COLITIS CASES

The SILS platform is valuable in Ulcerative Colitis patients undergoing a total abdominal colectomy or total proctocolectomy with a predetermined ileostomy, as the SILS port can be placed through the right iliac fossa stoma site, and the patient can have an “incisionless surgery”, where there are no incisions or extraction sites other than their stoma. In this patient population, that is predominately young and self-conscious, minimizing incisions is paramount. Using this approach, access is gained through a 2.5 cm circular incision at the planned ileostomy site. The colon is fully mobilized using an inferior to superior approach, and dissection of the colon and division of the mesentery takes place directly by the bowel wall to spare length, minimize manipulation of a thickened edematous mesentery, and protect the vasculature, especially in the ileocolic region, as the vessels need to be spared, as they are the blood supply for the future J pouch.

During our 1st 500 SILS cases, we performed 30 “incisionless” total abdominal colectomies with an end ileostomy as described. The mean age was 44.3 (SD 15.7) years, and mean BMI was 24.5 (SD 4.5) kg/m². Forty percent of patients had a previous abdominal operation. The mean operative time was 216.1 (SD 62.5) min. One patient (3.3%) was converted intraoperatively for poor visualization. There were no intraoperative complications. The mean length of stay was 4.5 (SD 4.2) d. Postoperatively, 6 patients

**Figure 2** Single incision laparoscopic surgery + 1 approach for pelvic colorectal procedures.

had complications (anastomotic leak, *n* = 3; ileus, *n* = 2; intrabdominal abscess, *n* = 1) - all patients with an anastomotic leak were on high-dose steroids pre-operatively. Four patients were readmitted within 30-d of the index operation, and 2 required unplanned reoperation for management of an anastomotic leak.

Several other reports have described this approach. Geisler *et al*^[7] described the technique for an incisionless SILS total proctocolectomy with ileal anal J pouch anastomosis through the ileostomy site for a familial adenomatous polyposis patient. This patient had a scarless abdomen other than ileostomy, and the authors proved the safety and feasibility of this technique. Abarca *et al*^[33] then reported on 17 patients that underwent a SILS ileal J-pouch anal anastomosis surgery with extraction of the specimen through the ileostomy site for resection and extracorporeal pouch construction). These patients had a shorter operative time, shorter length of stay, and lower complication rate than similar patients that had a Pfannenstiel extraction site. Thus, there may be more than cosmetic benefits to the modification of SILS in Ulcerative Colitis patients.

HIGH BMI

Laparoscopy has been proven beneficial in obese patients^[14,42-50]; however, there is little data on single-incision laparoscopic outcomes in the obese. Most of the published literature with the SILS platform regulated it for experienced laparoscopic surgeons and non-obese patients^[7,51-56]. In fact, in describing training colorectal surgeons in SILS, patients initially selected had an average BMI of less than 30 kg/m², with obese patients only incorporated after significant experience^[53]. One study comparing outcomes for SILS and traditional multiport laparoscopic colorectal surgery in the obese found similar conversion rates, operative time, postoperative recovery and length of stay across the platforms^[57].

In our institution, a case-matched cohort study of 80 obese patients obese (BMI ≥ 30 kg/m²) and 80

Table 4 Single incision laparoscopic surgery for obese *vs* non-obese patients *n* (%)

Parameter	Non-obese (<i>n</i> = 80)	Obese (<i>n</i> = 80)	<i>P</i> value
Age (yr), mean ± SD	57.2 ± 12.8	57.0 ± 12.7	0.926
Gender			1.000
Male	41 (51.2)	41 (51.2)	
Female	39 (48.8)	39 (48.8)	
Body mass index (kg/m ²)	22.8 (2.3)	33.4 (3.2)	< 0.001
ASA score, median (range)	II (I - III)	III (I - IV)	0.035*
Diagnosis			1.000
Diverticulitis	29 (36.3)	29 (36.3)	
Colon cancer	23 (28.7)	23 (28.7)	
Polyp	17 (21.3)	17 (21.3)	
Inflammatory bowel disease	7 (8.7)	7 (8.7)	
Constipation	4 (5.0)	4 (5.0)	
Procedure			1.000
Anterior resectosigmoidectomy	39 (48.8)	39 (48.8)	
Right hemicolectomy	29 (36.3)	29 (36.3)	
Total abdominal colectomy	7 (8.8)	7 (8.8)	
Left colectomy	3 (3.8)	3 (3.8)	
Transverse colectomy	2 (2.5)	2 (2.5)	
Operative time (min), mean ± SD	144.4 ± 47.2	176.9 ± 64.0	< 0.001
Blood loss (mL), mean ± SD	51.6 ± 38.0	89.0 ± 139.5	< 0.001
Intraoperative complications	2 (2.5)	1 (1.3)	0.987
Intraoperative conversion	2 (2.5)	4 (5.0)	0.682
Final incision length (cm), mean ± SD	3.5 ± 1.1	4.0 ± 1.5	0.080
Length of stay (d), mean ± SD	3.7 ± 2.1	4.1 ± 2.2	0.332
Postoperative complications	6 (7.5)	10 (12.5)	0.430
Reoperation	2 (2.5)	1 (1.3)	0.987
Readmissions	3 (3.8)	3 (3.8)	1.000

non-obese (BMI < 30 kg/m²) patients undergoing an elective single incision laparoscopic colectomy was performed, where we found similar intraoperative complication (2.5% non-obese *vs* 1.3% obese, *P* = 0.987), conversion (2.5% non-obese *vs* 5.0% obese, *P* = 0.682), postoperative complications (7.5% non-obese *vs* 12.5% obese, *P* = 0.430), length of stay (3.7 d non-obese *vs* 4.1 d obese, *P* = 0.332), readmission (3.8% in both groups, *P* = 1.000) and reoperation rates (2.5% non-obese *vs* 1.3% obese, *P* = 0.987) across groups^[58]. The obese cohort did have significantly longer mean operative times (144.4 min non-obese *vs* 176.9 min obese, *P* < 0.001) and mean blood loss (51.6 mL non-obese *vs* 89.0 mL obese, *P* < 0.001); however, these measures did not impact outcome measures (Table 4). Thus, in the obese, where higher morbidity and conversion rates are common, by accepting longer operative times, SILS can be used to realize the minimally invasive benefits in these technically challenging cases.

INTEGRATION WITH ROBOTIC ASSISTED LAPAROSCOPIC CASES FOR RECTAL CANCER

To facilitate the laparoscopic portion of a robotic low anterior resection for rectal cancer, we developed a novel reduced port set-up. The SILS port is placed through a predetermined right iliac fossa stoma site and a 12 mm port is placed at the umbilicus for the laparoscopic camera. Three 5 mm assistant ports are placed through the SILS port, as well as a 8 mm robotic assist port, reducing the port incisions. For the robotic portion of the case, two 8 mm accessory ports are placed along the left mid-axillary and left lateral sidewall. The patient is positioned, prepped, draped, and all ports are placed. However, the robot is not docked initially. The case begins with a laparoscopic splenic flexure dissection and ligation of the Inferior Mesenteric vessels. Then, the robot is docked for the pelvic portion. Arm 1 is docked to the patient's right and used for dissection, while arms 2 and 3 are docked to the patient's left and used for retraction. The mesorectum is divided beyond the tumor, a circumferential dissection is performed around the rectum, and the rectum is divided. The stapler is fired through the SILS port, eliminating the need for an additional 12 mm port. The specimen is can also be extracted through the SILS port, eliminating the additional Pfannenstiel extraction incision. An extracorporeal resection is performed, the colon is returned to the abdomen, and an end-to-end anastomosis is created. The robot is not undocked during this portion, and readily available to address any issues with the anastomosis. Per surgeon preference, a loop ileostomy can be pulled through the SILS port to protect the low rectal anastomosis, leaving the patient with 8 mm scars and a hidden umbilical scar.

During the study period for the 500 case series, 15 cases were performed using the reduced port robotic assisted low anterior resections technique for rectal cancer (Figure 3). Eleven patients had neoadjuvant chemoradiation. The mean patient age was 60.2 (SD 9.8) years, and 12 were male. The mean BMI was 30.2 (SD 7.55) kg/m². There were no intraoperative complications or conversions. The mean operative time was 306.6 (SD 95.2) min. The mean length of stay was 3.8 (SD 1.6) d. Postoperatively, there were 3 complications- dehydration (*n* = 2) and an abdominal wall abscess. All 3 patients were readmitted. There were no unplanned reoperations or mortality in the series.

CONCLUSION

SILS is a minimally invasive platform with specific benefits over traditional multiport laparoscopic surgery. The safety and feasibility of SILS has been

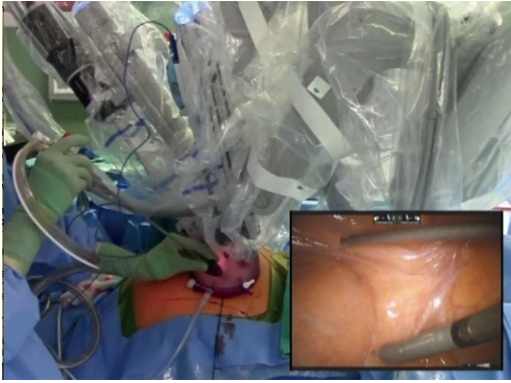


Figure 3 Reduced port robotic assisted laparoscopic surgery.

proven, and the applications continue to grow with experience. After performing 500 cases, we developed best practices to approach common procedures, standardizing the instrumentation and operative steps. With this breadth of experience, we have also applied the SILS platform to special patient populations and developed adaptations to help overcome technical and ergonomic challenges faced with in minimally invasive colorectal surgery.

REFERENCES

- Boni L, Dionigi G, Cassinotti E, Di Giuseppe M, Diurni M, Rauseri S, Cantore F, Dionigi R. Single incision laparoscopic right colectomy. *Surg Endosc* 2010; **24**: 3233-3236 [PMID: 20464415 DOI: 10.1007/s00464-010-1100-4]
- Autorino R, Yakoubi R, White WM, Gettman M, De Sio M, Quattrone C, Di Palma C, Izzo A, Correia-Pinto J, Kaouk JH, Lima E. Natural orifice transluminal endoscopic surgery (NOTES): where are we going? A bibliometric assessment. *BJU Int* 2013; **111**: 11-16 [PMID: 23323699 DOI: 10.1111/j.1464-410X.2012.11494.x]
- Bucher P, Pugin F, Morel P. Single port access laparoscopic right hemicolectomy. *Int J Colorectal Dis* 2008; **23**: 1013-1016 [PMID: 18607608 DOI: 10.1111/j.1463-1318.2009.01825.x]
- Piskun G, Rajpal S. Transumbilical laparoscopic cholecystectomy utilizes no incisions outside the umbilicus. *J Laparoendosc Adv Surg Tech A* 1999; **9**: 361-364 [PMID: 10488834]
- Remzi FH, Kirat HT, Kaouk JH, Geisler DP. Single-port laparoscopy in colorectal surgery. *Colorectal Dis* 2008; **10**: 823-826 [PMID: 18684153 DOI: 10.1111/j.1463-1318.2008.01660.x]
- Adair J, Gromski MA, Lim RB, Nagle D. Single-incision laparoscopic right colectomy: experience with 17 consecutive cases and comparison with multiport laparoscopic right colectomy. *Dis Colon Rectum* 2010; **53**: 1549-1554 [PMID: 20940605 DOI: 10.1007/DCR.0b013e3181e85875]
- Geisler DP, Condon ET, Remzi FH. Single incision laparoscopic total proctocolectomy with ileopouch anal anastomosis. *Colorectal Dis* 2010; **12**: 941-943 [PMID: 19895601 DOI: 10.1111/j.1463-1318.2009.02115.x]
- Law WL, Fan JK, Poon JT. Single-incision laparoscopic colectomy: early experience. *Dis Colon Rectum* 2010; **53**: 284-288 [PMID: 20173474 DOI: 10.1007/DCR.0b013e3181c959ba]
- Papaconstantinou HT, Sharp N, Thomas JS. Single-incision laparoscopic right colectomy: a case-matched comparison with standard laparoscopic and hand-assisted laparoscopic techniques. *J Am Coll Surg* 2011; **213**: 72-80; discussion 80-2 [PMID: 21420878 DOI: 10.1016/j.jamcollsurg.2011.02.010]
- Chen WT, Chang SC, Chiang HC, Lo WY, Jeng LB, Wu C, Ke TW. Single-incision laparoscopic versus conventional laparoscopic right hemicolectomy: a comparison of short-term surgical results. *Surg Endosc* 2011; **25**: 1887-1892 [PMID: 21359907 DOI: 10.1007/s00464-010-1481-4]
- Rijcken E, Mennigen R, Argyris I, Senninger N, Bruewer M. Single-incision laparoscopic surgery for ileocolic resection in Crohn's disease. *Dis Colon Rectum* 2012; **55**: 140-146 [PMID: 22228156 DOI: 10.1097/DCR.0b013e31823d0e0d]
- Champagne BJ, Papaconstantinou HT, Parmar SS, Nagle DA, Young-Fadok TM, Lee EC, Delaney CP. Single-incision versus standard multiport laparoscopic colectomy: a multicenter, case-controlled comparison. *Ann Surg* 2012; **255**: 66-69 [PMID: 22104563 DOI: 10.1097/SLA.0b013e3182378442]
- Huscher CG, Mingoli A, Sgarzini G, Mereu A, Binda B, Brachini G, Trombetta S. Standard laparoscopic versus single-incision laparoscopic colectomy for cancer: early results of a randomized prospective study. *Am J Surg* 2012; **204**: 115-120 [PMID: 22178484 DOI: 10.1016/j.amjsurg.2011.09.005]
- Makino T, Milsom JW, Lee SW. Feasibility and safety of single-incision laparoscopic colectomy: a systematic review. *Ann Surg* 2012; **255**: 667-676 [PMID: 22258065 DOI: 10.1097/SLA.0b013e31823fbac7]
- Moftah M, Nazour F, Cunningham M, Cahill RA. Single port laparoscopic surgery for patients with complex and recurrent Crohn's disease. *J Crohns Colitis* 2014; **8**: 1055-1061 [PMID: 24589026 DOI: 10.1016/j.crohns.2014.02.003]
- Poon JT, Cheung CW, Fan JK, Lo OS, Law WL. Single-incision versus conventional laparoscopic colectomy for colonic neoplasm: a randomized, controlled trial. *Surg Endosc* 2012; **26**: 2729-2734 [PMID: 22538676 DOI: 10.1007/s00464-012-2262-z]
- Vasilakis V, Clark CE, Liasis L, Papaconstantinou HT. Noncosmetic benefits of single-incision laparoscopic sigmoid colectomy for diverticular disease: a case-matched comparison with multiport laparoscopic technique. *J Surg Res* 2013; **180**: 201-207 [PMID: 22626560 DOI: 10.1016/j.jss.2012.04.063]
- Chambers WM, Bicsak M, Lamparelli M, Dixon AR. Single-incision laparoscopic surgery (SILS) in complex colorectal surgery: a technique offering potential and not just cosmesis. *Colorectal Dis* 2011; **13**: 393-398 [PMID: 20002691 DOI: 10.1111/j.1463-1318.2009.02158.x]
- Bulut O, Nielsen CB, Jespersen N. Single-port access laparoscopic surgery for rectal cancer: initial experience with 10 cases. *Dis Colon Rectum* 2011; **54**: 803-809 [PMID: 21654246 DOI: 10.1007/DCR.0b013e3182147b4d]
- Zhou YM, Wu LP, Zhao YF, Xu DH, Li B. Single-incision versus conventional laparoscopy for colorectal disease: a meta-analysis. *Dig Dis Sci* 2012; **57**: 2103-2112 [PMID: 22466079 DOI: 10.1007/s10620-012-2145-0]
- Cianchi F, Staderini F, Badii B. Single-incision laparoscopic colorectal surgery for cancer: state of art. *World J Gastroenterol* 2014; **20**: 6073-6080 [PMID: 24876729 DOI: 10.3748/wjg.v20.i20.6073]
- Curcillo PG, Podolsky ER, King SA. The road to reduced port surgery: from single big incisions to single small incisions, and beyond. *World J Surg* 2011; **35**: 1526-1531 [PMID: 21523502 DOI: 10.1007/s00268-011-1099-2]
- Gandhi DP, Ragupathi M, Patel CB, Ramos-Valadez DI, Pickron TB, Haas EM. Single-incision versus hand-assisted laparoscopic colectomy: a case-matched series. *J Gastrointest Surg* 2010; **14**: 1875-1880 [PMID: 20922576 DOI: 10.1007/s11605-010-1355-z]
- Haas EM, Nieto J, Ragupathi M, Aminian A, Patel CB. Critical appraisal of learning curve for single incision laparoscopic right colectomy. *Surg Endosc* 2013; **27**: 4499-4503 [PMID: 23877765 DOI: 10.1007/s00464-013-3096-z]
- Patel CB, Ramos-Valadez DI, Ragupathi M, Haas EM. Single incision laparoscopic-assisted right hemicolectomy: technique and application (with video). *Surg Laparosc Endosc Percutan Tech* 2010; **20**: e146-e149 [PMID: 20975489 DOI: 10.1097/SLE.0b013e3181ee039f]
- Pedraza R, Aminian A, Nieto J, Faraj C, Pickron TB, Haas EM. Single-incision laparoscopic colectomy for cancer: short-term

- outcomes and comparative analysis. *Minim Invasive Surg* 2013; **2013**: 283438 [PMID: 23766897 DOI: 10.1155/2013/283438]
- 27 **Ragupathi M**, Ramos-Valadez DI, Yaakovian MD, Haas EM. Single-incision laparoscopic colectomy: a novel approach through a Pfannenstiel incision. *Tech Coloproctol* 2011; **15**: 61-65 [PMID: 21287224 DOI: 10.1007/s10151-010-0663-3]
 - 28 **Ragupathi M**, Nieto J, Haas EM. Pearls and pitfalls in SILS colectomy. *Surg Laparosc Endosc Percutan Tech* 2012; **22**: 183-188 [PMID: 22678310 DOI: 10.1097/SLE.0b013e31824e2814]
 - 29 **Ramos-Valadez DI**, Patel CB, Ragupathi M, Bartley Pickron T, Haas EM. Single-incision laparoscopic right hemicolectomy: safety and feasibility in a series of consecutive cases. *Surg Endosc* 2010; **24**: 2613-2616 [PMID: 20364353 DOI: 10.1007/s00464-010-1017-y]
 - 30 **Ramos-Valadez DI**, Patel CB, Ragupathi M, Bokhari MB, Pickron TB, Haas EM. Single-incision laparoscopic colectomy: outcomes of an emerging minimally invasive technique. *Int J Colorectal Dis* 2011; **26**: 761-767 [PMID: 21445554 DOI: 10.1007/s00384-011-1185-9]
 - 31 **Ramos-Valadez DI**, Ragupathi M, Nieto J, Patel CB, Miller S, Pickron TB, Haas EM. Single-incision versus conventional laparoscopic sigmoid colectomy: a case-matched series. *Surg Endosc* 2012; **26**: 96-102 [PMID: 21792717 DOI: 10.1007/s00464-011-1833-8]
 - 32 **Dindo D**, Demartines N, Clavien PA. Classification of surgical complications: a new proposal with evaluation in a cohort of 6336 patients and results of a survey. *Ann Surg* 2004; **240**: 205-213 [PMID: 15273542]
 - 33 **Abarca F**, Cologne KG, Francescatti A, Brand MI, Saclarides TJ. Incisionless laparoscopic total proctocolectomy with ileal J-pouch anal anastomosis. *Am Surg* 2011; **77**: 929-932 [PMID: 21944361]
 - 34 **Atallah SB**, Debeche-Adams T. Incisionless laparoscopic stoma construction using a 12-mm Hassan trocar. *Am Surg* 2012; **78**: E495-E497 [PMID: 23089432]
 - 35 **Lopez NE**, Peterson CY, Ramamoorthy SL, McLemore EC, Sedrak MF, Lowy AM, Horgan S, Talamini MA, Sicklick JK. Single-incision laparoscopic surgery through an ostomy site: a natural approach by an unnatural orifice. *Surg Laparosc Endosc Percutan Tech* 2015; **25**: 74-78 [PMID: 24743670]
 - 36 **Kawamata F**, Homma S, Minagawa N, Kawamura H, Takahashi N, Taketomi A. Comparison of single-incision plus one additional port laparoscopy-assisted anterior resection with conventional laparoscopy-assisted anterior resection for rectal cancer. *World J Surg* 2014; **38**: 2716-2723 [PMID: 24852437 DOI: 10.1007/s00268-014-2642-8]
 - 37 **Hirano Y**, Hattori M, Douden K, Shimizu S, Sato Y, Maeda K, Hashizume Y. Single-incision plus one port laparoscopic anterior resection for rectal cancer as a reduced port surgery. *Scand J Surg* 2012; **101**: 283-286 [PMID: 23238505]
 - 38 **Bae SU**, Baek SJ, Min BS, Baik SH, Kim NK, Hur H. Reduced-port laparoscopic surgery for a tumor-specific mesorectal excision in patients with colorectal cancer: initial experience with 20 consecutive cases. *Ann Coloproctol* 2015; **31**: 16-22 [PMID: 25745622 DOI: 10.3393/ac.2015.31.1.16]
 - 39 **Tokuoka M**, Ide Y, Takeda M, Hashimoto Y, Matsuyama J, Yokoyama S, Morimoto T, Fukushima Y, Nomura T, Kodama K, Sasaki Y. Single-incision plus one-port laparoscopic abdominoperineal resection with bilateral pelvic lymph node dissection for advanced rectal cancer: a case report. *Int Surg* 2015; **100**: 15-20 [PMID: 25594635 DOI: 10.9738/INTSURG-D-14-00232.1]
 - 40 **Tokuoka M**, Ide Y, Takeda M, Hashimoto Y, Matsuyama J, Yokoyama S, Morimoto T, Fukushima Y, Nomura T, Kodama K, Sasaki Y. Single-incision Plus One Port Laparoscopic Total Mesorectal Excision and Bilateral Pelvic Node Dissection for Advanced Rectal Cancer-A Medial Umbilical Ligament Approach. *Int Surg* 2015; **100**: 417-422 [PMID: 25785320 DOI: 10.9738/INTSURG-D-14-00091.1]
 - 41 **Keller DS**, Flores-Gonzalez JR, Sandhu J, Ibarra S, Madhoun N, Haas EM. SILS v SILS+1: a Case-Matched Comparison for Colorectal Surgery. *J Gastrointest Surg* 2015; **19**: 1875-1879 [PMID: 26282851 DOI: 10.1007/s11605-015-2921-1]
 - 42 **Makino T**, Shukla PJ, Rubino F, Milsom JW. The impact of obesity on perioperative outcomes after laparoscopic colorectal resection. *Ann Surg* 2012; **255**: 228-236 [PMID: 22190113 DOI: 10.1097/SLA.0b013e31823dcbf7]
 - 43 **Makino T**, Trencheva K, Shukla PJ, Rubino F, Zhuo C, Pavoors RS, Milsom JW. The influence of obesity on short- and long-term outcomes after laparoscopic surgery for colon cancer: a case-matched study of 152 patients. *Surgery* 2014; **156**: 661-668 [PMID: 24947645 DOI: 10.1016/j.surg.2014.03.023]
 - 44 **Cai Y**, Zhou Y, Li Z, Xiang J, Chen Z. Surgical outcome of laparoscopic colectomy for colorectal cancer in obese patients: A comparative study with open colectomy. *Oncol Lett* 2013; **6**: 1057-1062 [PMID: 24137464 DOI: 10.3892/ol.2013.1508]
 - 45 **Poulsen M**, Ovesen H. Is laparoscopic colorectal cancer surgery in obese patients associated with an increased risk? Short-term results from a single center study of 425 patients. *J Gastrointest Surg* 2012; **16**: 1554-1558 [PMID: 22688417 DOI: 10.1007/s11605-012-1928-0]
 - 46 **Krane MK**, Allaix ME, Zoccali M, Umanskiy K, Rubin MA, Villa A, Hurst RD, Fichera A. Does morbid obesity change outcomes after laparoscopic surgery for inflammatory bowel disease? Review of 626 consecutive cases. *J Am Coll Surg* 2013; **216**: 986-996 [PMID: 23523148 DOI: 10.1016/j.jamcollsurg.2013.01.053]
 - 47 **Delaney CP**, Pokala N, Senagore AJ, Casillas S, Kiran RP, Brady KM, Fazio VW. Is laparoscopic colectomy applicable to patients with body mass index > 30? A case-matched comparative study with open colectomy. *Dis Colon Rectum* 2005; **48**: 975-981 [PMID: 15793638 DOI: 10.1007/s10350-004-0941-0]
 - 48 **Denost Q**, Quintane L, Buscail E, Martenot M, Laurent C, Rullier E. Short- and long-term impact of body mass index on laparoscopic rectal cancer surgery. *Colorectal Dis* 2013; **15**: 463-469 [PMID: 23534683 DOI: 10.1111/codi.12026]
 - 49 **Senagore AJ**, Delaney CP, Madboulay K, Brady KM, Fazio VW. Laparoscopic colectomy in obese and nonobese patients. *J Gastrointest Surg* 2003; **7**: 558-561 [PMID: 12763416]
 - 50 **Zhou Y**, Wu L, Li X, Wu X, Li B. Outcome of laparoscopic colorectal surgery in obese and nonobese patients: a meta-analysis. *Surg Endosc* 2012; **26**: 783-789 [PMID: 22011944 DOI: 10.1007/s00464-011-1952-2]
 - 51 **Bucher P**, Pugin F, Morel P. Transumbilical single incision laparoscopic sigmoidectomy for benign disease. *Colorectal Dis* 2010; **12**: 61-65 [PMID: 19320667 DOI: 10.1007/s00384-008-0519-8]
 - 52 **Geisler D**, Garrett T. Single incision laparoscopic colorectal surgery: a single surgeon experience of 102 consecutive cases. *Tech Coloproctol* 2011; **15**: 397-401 [PMID: 21887555 DOI: 10.1007/s10151-011-0756-7]
 - 53 **Miller S**, Causey MW, Damle A, Maykel J, Steele S. Single-incision laparoscopic colectomy: training the next generation. *Surg Endosc* 2013; **27**: 1784-1790 [PMID: 23389059 DOI: 10.1007/s00464-012-2684-7]
 - 54 **Remzi FH**, Kirat HT, Geisler DP. Laparoscopic single-port colectomy for sigmoid cancer. *Tech Coloproctol* 2010; **14**: 253-255 [PMID: 19953288 DOI: 10.1007/s10151-009-0545-8]
 - 55 **Rieger NA**, Lam FF. Single-incision laparoscopically assisted colectomy using standard laparoscopic instrumentation. *Surg Endosc* 2010; **24**: 888-890 [PMID: 19760335 DOI: 10.1007/s00464-009-0683-0]
 - 56 **Ross H**, Steele S, Whiteford M, Lee S, Albert M, Mutch M, Rivadeneira D, Marcello P. Early multi-institution experience with single-incision laparoscopic colectomy. *Dis Colon Rectum* 2011; **54**: 187-192 [PMID: 21228667 DOI: 10.1007/DCR.0b013e3181f8d972]
 - 57 **Aytac E**, Turina M, Gorgun E, Stocchi L, Remzi FH, Costedio MM. Single-port laparoscopic colorectal resections in obese patients are as safe and effective as conventional laparoscopy. *Surg Endosc* 2014; **28**: 2884-2889 [PMID: 24853841 DOI: 10.1007/

- s00464-014-3542-6]
- 58 **Keller DS**, Ibarra S, Flores-Gonzalez JR, Ponte OM, Madhoun N, Pickron TB, Haas EM. Outcomes for single-incision laparoscopic

colectomy surgery in obese patients: a case-matched study. *Surg Endosc* 2015; Epub ahead of print [PMID: 26092004 DOI: 10.1007/s00464-015-4268-9]

P- Reviewer: Perini MV **S- Editor:** Yu J **L- Editor:** A
E- Editor: Ma S





Published by **Baishideng Publishing Group Inc**

8226 Regency Drive, Pleasanton, CA 94588, USA

Telephone: +1-925-223-8242

Fax: +1-925-223-8243

E-mail: bpgoffice@wjgnet.com

Help Desk: <http://www.wjgnet.com/esps/helpdesk.aspx>

<http://www.wjgnet.com>



ISSN 1007-9327



9 771007 932045