

Corrective osteotomies of the radius: Grafting or not?

Raffaele Mugnai, Luigi Tarallo, Enrico Lancellotti, Francesco Zambianchi, Ettore Di Giovine, Fabio Catani, Roberto Adani

Raffaele Mugnai, Luigi Tarallo, Enrico Lancellotti, Francesco Zambianchi, Ettore Di Giovine, Fabio Catani, Orthopedics and Traumatology Department, Modena Policlinic, University of Modena and Reggio Emilia, 41124 Modena, Italy

Roberto Adani, Department of Hand Surgery and Microsurgery, University Hospital Policlinico di Modena, 41124 Modena, Italy

Author contributions: Mugnai R, Catani F and Adani R designed the research; Lancellotti E and Di Giovine E performed the research; Mugnai R, Tarallo L and Zambianchi F wrote the paper.

Conflict-of-interest statement: The authors declare that they have no conflicts of interest concerning this article.

Data sharing statement: No additional data are available.

Open-Access: This article is an open-access article which was selected by an in-house editor and fully peer-reviewed by external reviewers. It is distributed in accordance with the Creative Commons Attribution Non Commercial (CC BY-NC 4.0) license, which permits others to distribute, remix, adapt, build upon this work non-commercially, and license their derivative works on different terms, provided the original work is properly cited and the use is non-commercial. See: <http://creativecommons.org/licenses/by-nc/4.0/>

Correspondence to: Raffaele Mugnai, MD, Orthopedics and Traumatology Department, Modena Policlinic, University of Modena and Reggio Emilia, via del Pozzo 71, 41124 Modena, Italy. raffaele.mugnai@gmail.com
Telephone: +39-059-4223717
Fax: +39-059-4224313

Received: July 4, 2015

Peer-review started: July 12, 2015

First decision: September 30, 2015

Revised: November 14, 2015

Accepted: December 7, 2015

Article in press: December 8, 2015

Published online: February 18, 2016

Abstract

AIM: To review the current literature regarding corrective

osteotomies to provide the best evidence of the rule of bone grafting.

METHODS: Our MEDLINE literature search included 280 studies using the following key words "Malunited distal radius fracture" and 150 studies using key words "Corrective osteotomy of the distal radius". Inclusion criteria were: Malunited distal radial, extra articular fracture, volar locking plate, use of iliac bone graft (cancellous or corticocancellous), non-use of bone graft. Twelve studies met the inclusion criteria.

RESULTS: Seven of the 12 studies considered, described the use of a graft; the remaining five studies didn't use any graft. Type of malunion was dorsal in most of the studies. The healing time was comparable using the graft or not (mean 12.5 wk), ranging from 7.5 to 16 wk. The mean disabilities of the arm, shoulder and hand score improvement was 23 points both in the studies that used the graft and in those not using the graft.

CONCLUSION: This review demonstrated that corrective osteotomy of extra-articular malunited fractures of the distal radius treated by volar locking plate does not necessarily require bone graft.

Key words: Radial fracture; Osteotomy; Graft; Volar plate; Malunion

© **The Author(s) 2016.** Published by Baishideng Publishing Group Inc. All rights reserved.

Core tip: The aim of this study was to review the current literature regarding corrective osteotomies in malunion of the distal radius to provide the best evidence of the rule of bone graft. The results of this review demonstrated that corrective osteotomy of extra-articular malunited fractures of the distal radius treated by volar locking plate does not necessarily require bone graft. Rate of union and functional outcomes were comparable.

Mugnai R, Tarallo L, Lancellotti E, Zambianchi F, Di Giovine E, Catani F, Adani R. Corrective osteotomies of the radius: Grafting or not? *World J Orthop* 2016; 7(2): 128-135 Available from: URL: <http://www.wjgnet.com/2218-5836/full/v7/i2/128.htm> DOI: <http://dx.doi.org/10.5312/wjo.v7.i2.128>

INTRODUCTION

Distal radius fractures represent the 10%-12% of all fractures^[1-3]. One of the most common complication following distal radial fractures is malunion, especially when treated with close reduction and cast immobilization^[4]. Patients with symptomatic malunions of the distal radius usually present with wrist pain; restricted wrist range of motion (ROM), especially supination; reduced grip strength; unsightly appearance; late neuropathy especially of the median nerve, with compression at the carpal tunnel^[5-7]. Corrective osteotomy aims to restore anatomic configuration and improve function in unsatisfied patients.

Over the last few years, various corrective osteotomy techniques have been characterized^[1,6,8]. Although opening wedge osteotomy through a dorsal approach, using bone graft and non-locking plates has been in the past years the most widely recommended technique for treating distal radius malunion, this procedure requires an extensive dorsal approach and often determines extensor tendons irritation. Recently, with the introduction of fixed-angle plates, interest in performing these osteotomies through a volar approach has increased^[9,10]. According to the opening wedge treatment of a fracture united in a position of abnormality or deformity, a 3-D structural defect is produced by the surgeon in the distal radial metaphysis. The defect will then be filled with 3 different approaches: bone grafting, using a structural or non-structural autogenous corticocancellous bone graft; synthetic material [Norian, bone morphogenetic proteins (BMP), osteogenic protein-1 (OP-1)]; no bone graft^[11,12].

Bone graft

Corticocancellous bone can be derived from the iliac crest, distal femur, proximal tibia, fibula, distal radius and olecranon. Generally, the most used kind of bone graft is the autograft. Defects of a length smaller than 5 to 6 cm are well managed by nonvascularized iliac crest bone grafts, if in presence of well-perfused soft tissues and in absence of any active infection. Therefore they usually represent the first choice treatment of the defect created by the osteotomy. Bone graft helps to maintain the surgical corrections but with possible donor site morbidity: Persistent and chronic pain, serious discharge, nerve injury with meralgia, paresthesia, infection, fractures, pelvic instability, hematoma, cosmetic defects, hernia, ureteral injuries, arterial injuries^[12]. Moreover, sometimes it is not always feasible to shape a structural bone graft based on the dimensions of the defect

precisely^[13]. Studies have demonstrated that osteotomies filled with cancellous or corticocancellous grafts give comparable results^[14]. Anyway, cancellous is recognised to have three advantages over corticocancellous graft: first, it has no need for a specific anatomic configuration, since it can be totally compressed to stuff the defect, it gives the possibility to bypass the long procedure to prepare a structural graft, and lastly, it is not that difficult to applicate plate and screws (no displacement during the fixation) (Figures 1 and 2).

Synthetic graft

Autologous bone grafts can be replaced by bone substitute to elude donor site morbidity. Hydroxyapatite (HA) and calcium-sulphate (CS) are mineral-based substitutes for osteoconductive bone grafts. Osteotomies of malunited distal radial fractures^[15] and surgery of distal radial fractures^[16] has seen the use of HA as a substitute. Even though the time lapse of resorbing graft is of years, it should have the strength necessary to absorb stress until the bone has formed. Although CS has been shown to be highly biocompatible, the resorption rate it is too rapid to be used in fracture treatment. Indeed the CS resorption is faster than the new bone formation; potentially causing hardware failure that can be avoided by maintaining a cortical contact across the osteotomy site^[16,17].

Osteoconductive bone graft substitutes

Extensive research has been conducted on osteoconductive alternatives, associated with growth factors and proteins such as BMPs. Mesenchymal stem cells have been seen to differentiate into chondrocytes and osteoblasts driven by the primitive induction of the BMPs, which are members of the transforming growth factor- β . Preclinical effectiveness investigation on BMPs took to subsequent clinical introduction of the most powerful BMPs, BMP-2 and BMP-7^[18,19]. OP-1, which also goes under the name of recombinant BMP-7, has been known for its osteoinductive properties. Animal and clinical trials showed therapeutic potential in more than a study. Demonstration of the efficacy of this grafts has been documented in spinal fusion, fibular defects, tibial non-union, and most recently also in pelvic girdle non-union^[19,20]. According to Ekrol *et al*^[20], OP-1 substitute has been shown not to elicit the same stability and stress absorption as bone graft across the osteotomy site; furthermore using the combination of a plate with OP-1 resulted in healing of the osteotomy but with a slower rate than autogenous bone graft.

No bone graft

Bone graft seems to be not always necessary when the distal malunion is extra articular and it's treated with a locking plate: The absence of bone graft seems not to adversely affect time to union and functional outcome.

In this case correction should be achieved in the coronal and sagittal planes by having the distal radius

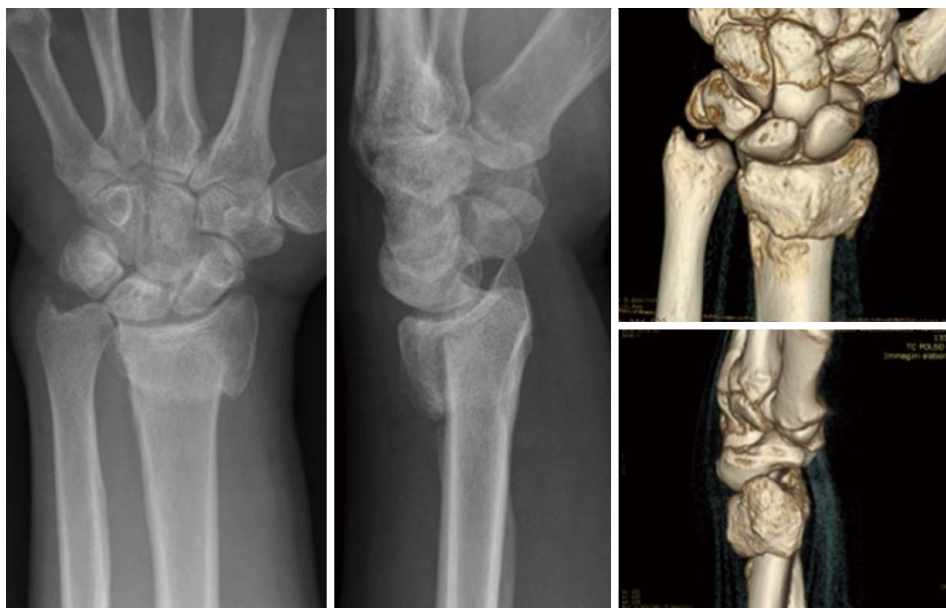


Figure 1 Preoperative X-rays and 3D-computed tomography evaluation showing an extra-articular dorsal malunion in a 36 years old man.

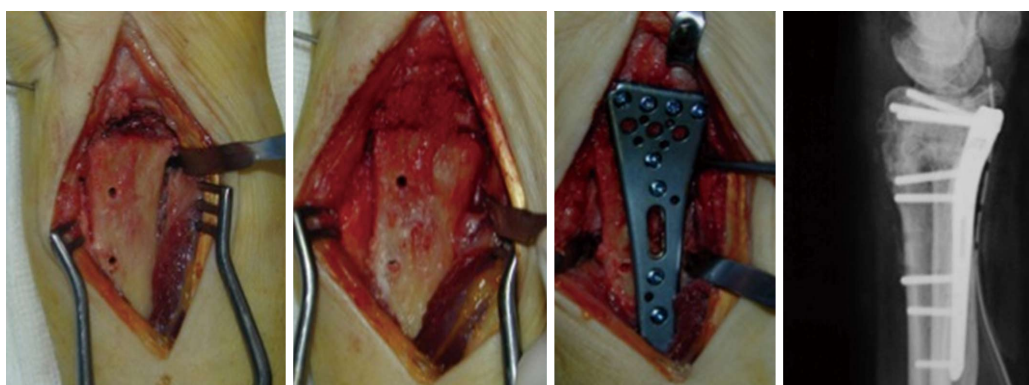


Figure 2 Intraoperative view and post-operative X-rays of the surgical procedure using a volar locking plate and cancellous bone graft.

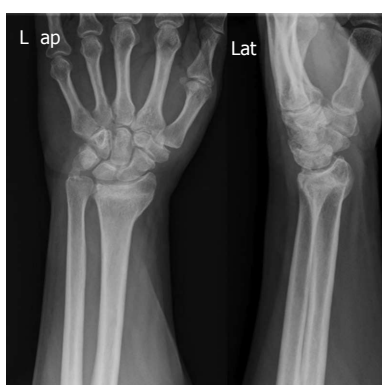

Figure 3 Preoperative X-rays showing an extra-articular dorsal malunion in a 51 years old man.

conform to the tilt of the plate. It can be useful to maintain a volar cortical contact following corrective osteotomy, to ensure the physiological transmission of the force vector through the synthesis, from the distal to the proximal segment of the radius^[21] (Figures 3-5).

MATERIALS AND METHODS

Our MEDLINE literature search included 280 studies using the following key words "Malunited distal radius fracture" and 150 studies using key words "Corrective osteotomy of the distal radius". Inclusion criteria were: Malunited distal radial, extra articular fracture, volar locking plate, use of iliac bone graft (cancellous or corticocancellous), non use of bone graft. Twelve studies met the inclusion criteria. Although important, time of healing and clinical outcome, were not reported in all the studies included in the review.

RESULTS

For each study the number of evaluated patients, surgical technique (graft or not), number of patients enrolled, type of malunion, time of healing and functional recovery regarded as disabilities of the arm, shoulder and hand (DASH) score, pain improvement [visual analogue scale (VAS) and any eventual post-

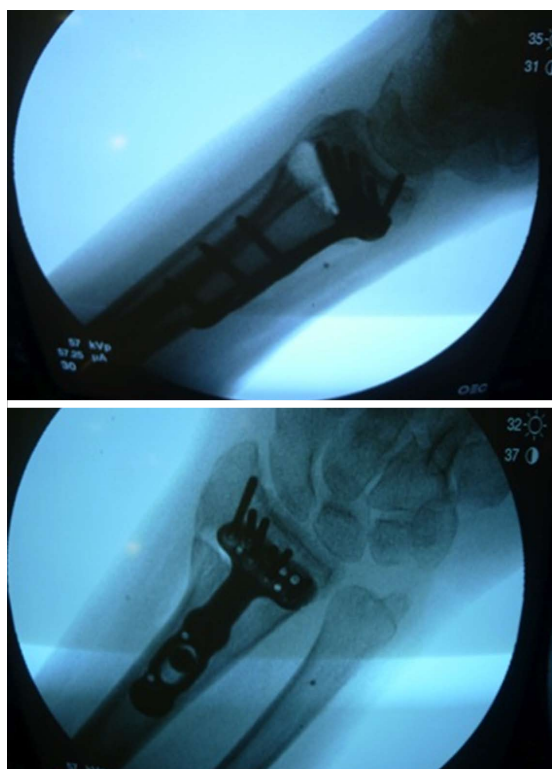


Figure 4 Intraoperative X-rays showing corrective osteotomy of extra-articular dorsally displaced malunion of the distal radius treated by volar locking plate without bone graft, and maintaining volar cortical contact.

surgical complication (Table 1) were reported. In 7 out of the 12 studies included the graft was used: Iliac crest corticocancellous bone graft in 4 studies and iliac crest cancellous bone graft in 3. Moreover Malone *et al*^[22] used crushed cancellous allograft in 1 case and Wada *et al*^[23] tricalcium phosphate. In the remaining five studies grafting was not described. Despite this, the number of patients of all studies treated with graft was inferior to the number of those treated without graft (97 vs 104). Type of malunion was dorsal in most of the studies. The healing time was comparable using the graft or not (mean 12.5 wk), ranging from 7.5^[24] to 16^[25,26] wk. The mean DASH score improvement was 23 points both in the studies describing the use of the graft (range, 11-46)^[22-24,27-29], and in those not using the graft (range, 13-28)^[25,30-32]. Finally, few studies reported postoperative complications^[11,22,23,26,29,32]. Among the majority of the studies neither complications nor significant correction loss were indicated after surgery, even in elderly people. The results of the main evaluated literature are summarized in Table 1.

DISCUSSION

The majority of the examined literature used the bone graft to fix the remaining defect with corticocancellous or cancellous autogenous bone from the iliac crest. Gradl *et al*^[27] employed iliac crest corticocancellous bone graft in all case of malunion. He included in his study 18 patients treated using a palmar approach in 14

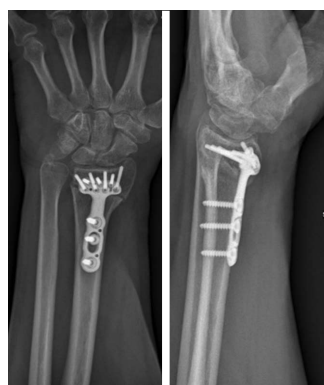

Figure 5 X-rays performed 3 mo post-operatively showing the healing process in progress.

cases and a combined approach (palmar + dorsal) in 4 cases. There were 7 palmar and 11 dorsal malunions, and remaining defects were fixed with corticocancellous autogenous bone graft from the iliac crest in 14 patients, and cancellous bone graft from the radius in one patient. At a mean 7 years of follow-up wrist ROM improved significantly in all cases and the DASH score decreased significantly from 59 to 23 points.

Treatment with transverse opening wedge osteotomy with oblique iliac bone graft of volarly malunited distal radius fractures led to a significant improvement in DASH score as reported by Sato *et al*^[24] in 2009. All patients were analyzed at a mean 25 mo of follow-up. Mean preoperative VAS scale was 45, improving significantly to 3 postoperatively. Range of wrist motion improved in all 28 patients, with supination range improving from 16° preoperatively to 80° postoperatively. Mean DASH score improvement from 55 to 9 postoperatively. X-rays evaluation showed an improvement of the volar tilt from 32° preoperatively to 10° postoperatively, and radial inclination increased from 17° to 21°. Preoperative ulnar variance of 5.9 mm was corrected to -0.1 mm postoperatively. Fifty-two days was the average time for bony union at osteotomy site (young patients, 51 d; older patients, 54 d).

Many authors described complications following the surgical treatment of dorsal malunion: Extensor tenosynovitis and, sometimes, tendon ruptures connected with the use of dorsal plates^[20,33,34]. Keller *et al*^[35] evaluated a series of 49 cases that underwent dorsal plating of the distal radius, reporting, at 32 mo follow-up, an average DASH score of 14.4 with good motion and grip strength. To be noted that 37 of the 49 patients required plate removal and of the 12 patients who did not undergo plate removal, one patient suffered a rupture of the extensor indicis proprius. It's common opinion among the authors that extensor tendon complications are the result of the profile of the dorsal plate^[21,27], but more recent studies claim that this complication can occur even with low-profile plates. Moreover screw placement is important: Gradl *et al*^[27] reported in one case the development of symptomatic tendinitis of the extensor pollicis longus tendon due to dorsal protrusion

Table 1 Results of the main evaluated literature

Ref.	No. of patients	Graft	Type of malunion	Time to healing	Clinical outcome (DASH)	Pain (VAS)	Complications
Gradl <i>et al</i> ^[27]	14	ICCCBG in all cases	Dorsal in 7 cases; volar in 4 cases	Not reported	36	4.2 ± 2.9	None
Malone <i>et al</i> ^[22]	3	ICCCBG in 2 cases; CCA in 1 case	Dorsal in all cases	9 wk	12	3.3	1 post-traumatic fracture
Peterson <i>et al</i> ^[28]	8	ICCCBG in all cases	Dorsal in 6 cases; volar in 2 cases	Not reported	10.8	Not reported	None
Rothenfluh <i>et al</i> ^[29]	14	ICCBG in all cases	Dorsal in all cases	12 wk	17.3	3.59	Secondary dislocation of the distal fragment was observed 21 d after surgery in 1 case
Wada <i>et al</i> ^[23]	16	ICCBG or tricalcium phosphate bone substitute	Dorsal and volar	13 wk	14	Significant improvement	2 delayed unions
Sato <i>et al</i> ^[24]	28	ICCCBG in all cases	Volar in all cases	7.5 wk	46	4.2	None
Miyake <i>et al</i> ^[26]	10	ICCBG in all cases	Dorsal in all cases	16 wk	Not reported	Significant improvement	Early postoperative screw loosening in 2 cases
Farshad <i>et al</i> ^[11]	28	None	Not specified	Not reported	Not reported	Not reported	Plate bending in 6 cases
Mahmoud <i>et al</i> ^[32]	22	None	Dorsal in all cases	10.4 wk	21.6 ± 13.5	3.4 ± 1.5	Intraoperative split in the shaft of the radius in 1 case CRPS in 1 case Residual pain in 2 cases
Opel <i>et al</i> ^[30]	20	None	Not specified	12 wk	13.4	Not reported	None
Ozer <i>et al</i> ^[31]	14	None	Dorsal in all cases	11 wk	28	Not reported	None
Tarallo <i>et al</i> ^[25]	20	None	Dorsal in all cases	16 wk	28.5	0.8	None

VAS: Visual analogue scale; DASH: Disabilities of the arm, shoulder and hand; ICCCBG: Iliac crest cortico cancellous bone graft; CCA: Crushed cancellous allograft; ICCBG: Iliac crest cancellous bone graft; CRPS: Complex regional pain syndrome.

of screw tips after corrective osteotomy with a palmar locking plate and autogenous bone grafting. Malone *et al*^[22] emphasized the role of the volar plate including structural bone grafting: Four corrective osteotomies has been performed using the volar approach for dorsally angulated malunion of distal radius fracture with a volar plate; two patients received autologous iliac crest bone graft, 1 patient received crushed cancellous allograft, and 1 patient had a distal ulna resection for ulnar impaction symptoms and the distal ulna was used as a source for the bone graft. The authors came to the concept that the stiff characteristics of fixed angle volar plates could provide an alternative to the traditional techniques of distal radius osteotomy including structural bone grafting and dorsal plate fixation or external fixation. Comparable results in terms of anatomic restoration of the distal radius, ROM improvement in the radiocarpal joint, and restoration of the anatomic relationships of the distal radioulnar joint were obtained by Rothenfluh *et al*^[29], Wada *et al*^[23], and Peterson *et al*^[28]. All these authors used bone graft from the iliac crest with a comparable DASH scores and no complications. Only Rothenfluh *et al*^[29] reported in one case a secondary dislocation of the distal fragment observed 21 d after volar osteotomy. In his study Rothenfluh *et al*^[29] compared the results of dorsal approach plus structural trapezoidal bone graft stabilized using a thin round-hole mini-fragment plate, with palmar approach plus nonstructural cancellous bone chips and a palmar fixed-angle plate, suggesting comparable results to those achieved with dorsal osteotomy and the interposition of cortico-cancellous bone graft. However, the palmar approach determined a

more favorable effect on wrist flexion, entailing lower complication rates, mainly represented by extensor tendonitis and hardware removal.

Several articles treated corrective osteotomy without bone graft and the first reports concerning this topic dates back to 1930s^[36]. In recent literature, Mahmoud *et al*^[32] described the results of 22 corrective osteotomies of extra-articular dorsally-angulated malunited fractures of the distal radius fixed by a volar locked plate without the use of bone graft. Radiological healing was achieved in all patients at a mean of 10.4 wk (8 to 14). At a mean of 18 (12 to 25) mo of follow-up the DASH score improved from 34.5 points to 12.9; improvements in the VAS score and grip strength were respectively 3.4 points and 17.4 kg; radiological correction of the deformity and ROM improvement were achieved in all cases. Complications occurred in six cases (27%): an intraoperative longitudinal split occurred in the shaft of the radius in one patient, requiring an interfragmentary compression screw; one patient suffered a transient median nerve neuritis; another patient suffered from CRPS, which was healed by physiotherapy; a prominent screw determined tendon impingement and required removal; residual pain on the ulnar side of the wrist due to ulnar impaction was encountered in two patients, requiring ulnar shortening. Tarallo *et al*^[25] treated 20 patients for symptomatic dorsally malunited extra-articular fractures of the distal radius with osteotomy and a volar locking plate without additional bone graft. The authors reported, at a mean 50 mo of follow-up, a significant improvement in pain level, ROM, grip strength, and DASH score.

An important factor to consider is that bone healing is determined by several factors, including cell differentiation, compromise of vascularity, and mechanical stability^[37]. Sheer *et al.*^[37], in a recent study, concluded that although there are few data on metaphyseal bone healing, there are some indications that it adheres to the same biomechanical principles as diaphyseal bone healing, with some differences concerning bone formation, which may follow different paths. The cortical contact between the osteotomy fragments represents an important factor, too. Ozer *et al.*^[31], investigated this aspect underlining the importance to maintain a volar cortical contact following the placement of the volar locking plate in order to obtain a better outcome, especially in extra-articular malunited fractures of the distal radius. They state that in such cases, it would not be necessarily required the use of bone graft.

The use of autogenous bone grafts has been reported to have high complication rates, with associated morbidity of up to 73%, and an additional operative time averaging 20 min^[31]. The most important complication reported by several authors is donor site morbidity, especially at the iliac crest. Minor complications, occurring in 7.1%-39% of patients, include persistent pain at the harvest site, sensory nerve injury, hematoma or seroma, and superficial infection^[38,39]. Concerning the use of a synthetic material, such products come with an inherent advantage of no donor site morbidity; however their use also come with a high cost of production and sometimes a potentially low, but real, risk of disease transmission. Abramo *et al.*^[18] evaluated 25 consecutive patients with a dorsal malunion after a distal radius fracture treated with corrective osteotomy using a dorsal approach. A TriMed buttress pin and a radial pin plate were used, and calcium phosphate mixture (Norian SRS) as bone substitute. At a 1-year follow-up grip strength increased from 62% of the contralateral hand to 82%, with a DASH score improvement of 12 points. Minor complications involving transient tingling and numbness from the radial nerve branches were reported initially in 6 cases, but disappeared by the last follow-up. One major complication occurred: The bone substitute fragmented before osseous union and the plate and screws broke 2 mo postoperatively. The patient was re-operated using conventional bone grafting and fixation with a dorsal AO plate.

Jepeganiam *et al.*^[40] reported on early mechanical failure of injectable calcium sulfate, leading to implant failure in 2 elderly patients who had corrective osteotomies for malunited distal radius fractures. Faster resorption might have specific advantages under certain conditions but might also be disadvantageous if it is required to contribute to mechanical support for many weeks or months. The authors hypothesized that the failures occurred because new bone formation did not occur rapidly enough to replace resorption of the grafted material.

Jepeganiam *et al.*^[40], suggest that graft substitutes with a faster resorption rate should be used with caution

in patients with expected slow bone healing. The major stability of bone graft compared with synthetic material is also emphasized by Ekrol *et al.*^[20]. They compared the OP-1 and autogenous graft for metaphyseal defects after osteotomy of the distal radius, concluding that OP-1 does not confer the same stability as bone graft, reducing the capacity for healing and resulting in osteolysis.

Conclusion

The results of this review demonstrate that corrective osteotomy of extra-articular malunited distal radius fractures treated by volar locking plate does not necessarily require the use of bone graft. Rate of union and functional outcomes are comparable to the use of bone graft. We suggest maintaining a volar cortical contact following corrective osteotomy, to ensure the physiological transmission of the force vector through the synthesis, from the distal segment of the radio to the proximal one.

Bone grafts however, remain a valuable support in this type of surgery, especially to fill gaps when a large defect is created. Synthetic materials come with an inherent advantage of no donor site morbidity but it seems that they do not confer the same stability as bone graft. Their use is limited by faster resorption rate than bone graft, so they should be used with caution in patients with expected slow bone healing rate.

COMMENTS

Background

Different techniques for corrective osteotomy have been described in recent years; although opening wedge osteotomy through a dorsal approach, using bone graft and non-locking plates has been in the past years the most widely recommended technique for treating distal radius malunion, this procedure requires an extensive dorsal approach and often determines extensor tendons irritation. Recently, with the introduction of fixed-angle plates, interest in performing these osteotomies through a volar approach has increased.

Research frontiers

According to the opening wedge treatment of a malunited fracture, the surgeon creates a 3-dimensional structural defect in the distal radial metaphysis, which will be filled with 3 different approaches: Bone grafting, using a structural or non-structural autogenous corticocancellous bone graft; synthetic material (Norian bone morphogenic proteins, osteogenic protein-1); no bone graft.

Innovations and breakthroughs

Current publication is the first systematic review, which summarize published data concerning the use of bone graft in corrective osteotomy of extra-articular malunited fractures of the distal radius treated by volar locking plate. The results of this review demonstrate that corrective osteotomy of extra-articular malunited fractures of the distal radius treated by volar locking plate does not necessarily require the use of bone graft. Rate of union and functional outcomes are comparable to the use of bone graft. However bone graft still represents a valuable solution in this type of surgery, especially to fill the gap when a large osteotomy is performed.

Applications

Given similar rates of union, functional outcomes and complications occurrence, the authors suggest that when a volar cortical contact is maintained following corrective osteotomy the use of bone graft is not necessarily required.

Terminology

Cancellous bone is the meshwork of spongy tissue (trabeculae) of mature adult bone. The most common harvesting site for autogenous cancellous bone graft is the iliac crest, tibial crest, humeral greater tubercle and greater trochanter of femur. Cancellous bone autograft offers the considerable amounts of viable cells that boost the osteogenesis, matrix protein that promotes the osteoinduction and bone matrix that encourage the osteoinduction. Cancellous bone grafts lack biomechanical strength and do not supply structural support. Corticocancellous grafts yield significant mechanical strength and can be used to either replace bone losses or to augment the mechanical stability of the fixation. The most common sites for harvesting corticocancellous bone autograft are ribs, the anterosuperior iliac crest and the posterior iliac crest.

Peer-review

This is a good study.

REFERENCES

- Slagel BE, Luenam S, Pichora DR. Management of post-traumatic malunion of fractures of the distal radius. *Orthop Clin North Am* 2007; **38**: 203-216, vi [PMID: 17560403]
- Lidstrom A. Fractures of the distal end of the radius. A clinical and statistical study of end results. *Acta Orthop Scand Suppl* 1959; **41**: 1-118 [PMID: 14416798]
- Bacorn RW, Kurtzke JF. Colles' fracture; a study of two thousand cases from the New York State Workmen's Compensation Board. *J Bone Joint Surg Am* 1953; **35-A**: 643-658 [PMID: 13069552]
- Amadio PC, Botte MJ. Treatment of malunion of the distal radius. *Hand Clin* 1987; **3**: 541-561 [PMID: 3320065]
- Sharpe F, Stevanovic M. Extra-articular distal radial fracture malunion. *Hand Clin* 2005; **21**: 469-487 [PMID: 16039458]
- Jupiter JB, Fernandez DL. Complications following distal radial fractures. *Instr Course Lect* 2002; **51**: 203-219 [PMID: 12064104]
- Schmitz MA, Finnegan M, Natarajan R, Champine J. Effect of smoking on tibial shaft fracture healing. *Clin Orthop Relat Res* 1999; **(365)**: 184-200 [PMID: 10627703]
- Sennwald G, Fischer M. [Correction of distal radial malunion by forward-sliding osteotomy. 3 case reports]. *Ann Chir Main Memb Supr* 1993; **12**: 124-129 [PMID: 7688234]
- Watson HK, Castle TH. Trapezoidal osteotomy of the distal radius for unacceptable articular angulation after Colles' fracture. *J Hand Surg Am* 1988; **13**: 837-843 [PMID: 3271005]
- Posner MA, Ambrose L. Malunited Colles' fractures: correction with a biplanar closing wedge osteotomy. *J Hand Surg Am* 1991; **16**: 1017-1026 [PMID: 1748745]
- Farshad M, Hess F, Nagy L, Schweizer A. Corrective osteotomy of distal radial deformities: a new method of guided locking fixed screw positioning. *J Hand Surg Eur Vol* 2013; **38**: 29-34 [PMID: 22184783 DOI: 10.1177/1753193411433227]
- Läftman P, Sigurdsson F, Strömberg L. Recovery of diaphyseal bone strength after rigid internal plate fixation. An experimental study in the rabbit. *Acta Orthop Scand* 1980; **51**: 215-222 [PMID: 7435177]
- Younger EM, Chapman MW. Morbidity at bone graft donor sites. *J Orthop Trauma* 1989; **3**: 192-195 [PMID: 2809818]
- Conway JD. Autograft and nonunions: morbidity with intramedullary bone graft versus iliac crest bone graft. *Orthop Clin North Am* 2010; **41**: 75-84; table of contents [PMID: 19931055 DOI: 10.1016/j.ocl.2009.07.006]
- Luchetti R. Corrective osteotomy of malunited distal radius fractures using carbonated hydroxyapatite as an alternative to autogenous bone grafting. *J Hand Surg Am* 2004; **29**: 825-834 [PMID: 15465231]
- Ring D, Roberge C, Morgan T, Jupiter JB. Osteotomy for malunited fractures of the distal radius: a comparison of structural and nonstructural autogenous bone grafts. *J Hand Surg Am* 2002; **27**: 216-222 [PMID: 11901380]
- Peltier LF. The use of plaster of Paris to fill defects in bone. *Clin Orthop* 1961; **21**: 1-31 [PMID: 14485018]
- Abramo A, Tagil M, Geijer M, Kopylov P. Osteotomy of dorsally displaced malunited fractures of the distal radius: no loss of radiographic correction during healing with a minimally invasive fixation technique and an injectable bone substitute. *Acta Orthop* 2008; **79**: 262-268 [PMID: 18484254 DOI: 10.1080/17453670710015085]
- Giannoudis PV, Tzioupis C. Clinical applications of BMP-7: the UK perspective. *Injury* 2005; **36** Suppl 3: S47-S50 [PMID: 16188550]
- Ekrol I, Hajducka C, Court-Brown C, McQueen MM. A comparison of RhBMP-7 (OP-1) and autogenous graft for metaphyseal defects after osteotomy of the distal radius. *Injury* 2008; **39** Suppl 2: S73-S82 [PMID: 18804577 DOI: 10.1016/S0020-1383(08)70018-4]
- Lozano-Calderón S, Moore M, Liebman M, Jupiter JB. Distal radius osteotomy in the elderly patient using angular stable implants and Norian bone cement. *J Hand Surg Am* 2007; **32**: 976-983 [PMID: 17826549]
- Malone KJ, Magnell TD, Freeman DC, Boyer MI, Placzek JD. Surgical correction of dorsally angulated distal radius malunions with fixed angle volar plating: a case series. *J Hand Surg Am* 2006; **31**: 366-372 [PMID: 16516729]
- Wada T, Tatebe M, Ozasa Y, Sato O, Sonoda T, Hirata H, Yamashita T. Clinical outcomes of corrective osteotomy for distal radial malunion: a review of opening and closing-wedge techniques. *J Bone Joint Surg Am* 2011; **93**: 1619-1626 [PMID: 21915577 DOI: 10.2106/JBJS.J.00500]
- Sato K, Nakamura T, Iwamoto T, Toyama Y, Ikegami H, Takayama S. Corrective osteotomy for volarly malunited distal radius fracture. *J Hand Surg Am* 2009; **34**: 27-33, 33.e1 [PMID: 19121727 DOI: 10.1016/j.jhsa.2008.09.018]
- Tarallo L, Mugnai R, Adani R, Catani F. Malunited extra-articular distal radius fractures: corrective osteotomies using volar locking plate. *J Orthop Traumatol* 2014; **15**: 285-290 [PMID: 25017024 DOI: 10.1007/s10195-014-0307-x]
- Miyake J, Murase T, Moritomo H, Sugamoto K, Yoshikawa H. Distal radius osteotomy with volar locking plates based on computer simulation. *Clin Orthop Relat Res* 2011; **469**: 1766-1773 [PMID: 21203873 DOI: 10.1007/s11999-010-1748-z]
- Gradi G, Jupiter J, Pillukat T, Knobe M, Prommersberger KJ. Corrective osteotomy of the distal radius following failed internal fixation. *Arch Orthop Trauma Surg* 2013; **133**: 1173-1179 [PMID: 23708289 DOI: 10.1007/s00402-013-1779-5]
- Peterson B, Gajendran V, Szabo RM. Corrective osteotomy for deformity of the distal radius using a volar locking plate. *Hand (N Y)* 2008; **3**: 61-68 [PMID: 18780123 DOI: 10.1007/s11552-007-9066-y]
- Rothenfluh E, Schweizer A, Nagy L. Opening wedge osteotomy for distal radius malunion: dorsal or palmar approach? *J Wrist Surg* 2013; **2**: 49-54 [PMID: 24436789 DOI: 10.1055/s-0032-1326725]
- Opel S, Konan S, Sorene E. Corrective distal radius osteotomy following fracture malunion using a fixed-angle volar locking plate. *J Hand Surg Eur Vol* 2014; **39**: 431-435 [PMID: 24051477 DOI: 10.1177/1753193413497636]
- Ozer K, Kiliç A, Sabel A, Ipaktchi K. The role of bone allografts in the treatment of angular malunions of the distal radius. *J Hand Surg Am* 2011; **36**: 1804-1809 [PMID: 22036280 DOI: 10.1016/j.jhsa.2011.08.011]
- Mahmoud M, El Shafie S, Kamal M. Correction of dorsally-malunited extra-articular distal radial fractures using volar locked plates without bone grafting. *J Bone Joint Surg Br* 2012; **94**: 1090-1096 [PMID: 22844051 DOI: 10.1302/0301-620X.94B8.28646]
- Schnur DP, Chang B. Extensor tendon rupture after internal fixation of a distal radius fracture using a dorsally placed AO/ASIF titanium pi plate. Arbeitsgemeinschaft für Osteosynthesefragen/ Association for the Study of Internal Fixation. *Ann Plast Surg* 2000; **44**: 564-566 [PMID: 10805309]
- Simic PM, Robison J, Gardner MJ, Gelberman RH, Weiland AJ, Boyer MI. Treatment of distal radius fractures with a low-profile dorsal plating system: an outcomes assessment. *J Hand Surg Am*

- 2006; **31**: 382-386 [PMID: 16516731]
- 35 **Keller M**, Steiger R. [Open reduction and internal fixation of distal radius extension fractures in women over 60 years of age with the dorsal radius plate (pi-plate)]. *Handchir Mikrochir Plast Chir* 2006; **38**: 82-89 [PMID: 16680663]
- 36 **Meyerding HW**, Overton LM. Malunited fracture of the lower end of the radius (Colles' fracture) treated by osteotomy. *Minnesota Medicine* 1935; **18**: 84-89
- 37 **Scheer JH**, Adolfsson LE. Non-union in 3 of 15 osteotomies of the distal radius without bone graft. *Acta Orthop* 2015; **86**: 316-320 [PMID: 25619425 DOI: 10.3109/17453674.2015.1007415]
- 38 **Westrich GH**, Geller DS, O'Malley MJ, Deland JT, Helfet DL. Anterior iliac crest bone graft harvesting using the corticocancellous reamer system. *J Orthop Trauma* 2001; **15**: 500-506 [PMID: 11602833]
- 39 **Dimitriou R**, Mataliotakis GI, Angoules AG, Kanakaris NK, Giannoudis PV. Complications following autologous bone graft harvesting from the iliac crest and using the RIA: a systematic review. *Injury* 2011; **42** Suppl 2: S3-15 [PMID: 21704997 DOI: 10.1016/j.injury.2011.06.015]
- 40 **Jepegnanam TS**, von Schroeder HP. Rapid resorption of calcium sulfate and hardware failure following corrective radius osteotomy: 2 case reports. *J Hand Surg Am* 2012; **37**: 477-480 [PMID: 22305728 DOI: 10.1016/j.jhsa.2011.12.020]

P- Reviewer: Anand A, Ertem K **S- Editor:** Ji FF

L- Editor: A **E- Editor:** Liu SQ





Published by **Baishideng Publishing Group Inc**

8226 Regency Drive, Pleasanton, CA 94588, USA

Telephone: +1-925-223-8242

Fax: +1-925-223-8243

E-mail: bpgoffice@wjgnet.com

Help Desk: <http://www.wjgnet.com/esps/helpdesk.aspx>

<http://www.wjgnet.com>

