

Old title:

Significant improvements after modified Quad and triangle tilt as revision surgeries in obstetric brachial plexus injury patients, who had other traditional surgical procedures at other institutions

Nath RK and Somasundaram C.

New title:

Outcomes of modified Quad and triangle tilt as revision surgeries in obstetric brachial plexus injury patients.

Our response highlighted in red.

This is an informative paper, generally well-written and of interest to readers of the WJO. I suggest a few minor revisions, as specified below:

We thank the reviewer for his/her corrections and suggestions to our manuscript.

1. Abstract, Methods: Please re-word the sentence commencing with ‘Of the 20 patients...’ to fix the grammar- **corrected it.**
2. Background, Paragraph 2: Please write the definition of the acronym SHEAR in full – **Scapular Hypoplasia, Elevation and Rotation- added it to our revised manuscript.**
3. Background, Paragraph 3: Can the authors please be a bit more explicit in this paragraph on how their study differs to previously-published work in this area. From what they have stated, this study is different as the patients have had previous treatment elsewhere. Please clarify and re-word. **re-written**
4. Patients and Methods, Paragraph 1: ‘Table 1 and 2’ should be ‘Tables 1 and 2.’ Please change ‘2’ to ‘Two’ at the start of the sentence. **corrected it.**
5. Patients and Methods, Clinical Assessment: Could the authors please provide a short explanation of what the modified Mallet clinical assessment is, perhaps with some accompanying references? This will make the paper more understandable to the wider orthopaedic audience. **added 2 more referenes**
6. Patients and Methods, Statistical Analysis: This should be ‘A student’s t-test...’ (not ‘The’). **corrected it.**
7. Discussion: What is MRC? **medial rotation contracture – added it to our revised manuscript.**

Abstract:

Purpose:

To compare results from our revision surgical treatment experiences in children with obstetric brachial plexus injury (OBPI) to outcomes of other traditional surgical treatments at other institutions.

Methods:

We conducted a retrospective study in our medical records consisting of OBPI patients, who came to our clinic with a history of prior operative procedures at other hospitals. We identified 20 OBPI children (10 girls and 10 boys), aged between 2.0 and 11.8 years (mean age 6.5 years), who had other traditional surgical treatments at other institutions.

Of the 20 patients, 18 undergone bony surgical procedure, the triangle tilt, 2 had only modified Quad. Among 18 patients, 8 had only triangle tilt and 10 had also moadQuad as revision surgeries with us. Mean modified Mallet and radiological scores were measured and compared. All measurements were done at least one-year post surgery.

Results:

Pre- revision surgery mean modified Mallet score was 12.0 ± 1.5 . This functional score was greatly improved to 18 ± 2.3 ($P < 0.0001$) at least one-year after modified Quad and or triangle tilt revision surgeries. Further, their radiological scores such as posterior subluxation and glenoid version were improved significantly to 31.9 ± 13.6 ($P < 0.001$), -16.3 ± 11 ($P < 0.0002$) respectively, at least one-year after triangle tilt surgery. Their mean pre- triangle tilt (yet after other surgeon's surgeries) PHHA, glenoid version and SHEAR were 14.6 ± 21.7 , -31.6 ± 19.3 and 16.1 ± 14.7 respectively.

Conclusion:

We demonstrate here, the triangle tilt and modified Quad as successful revision surgeries in 20 OBPI patients, who had other conventional surgical treatments at other clinics before presenting to us for further treatment.

Background:

Inadequate recovery of neurological function in obstetric brachial plexus injuries (OBPI) results in muscle weakness and imbalances around the shoulder [1-4]. Long-standing muscular imbalance leads to progressive glenohumeral dysplasia and joint incongruity [5-7]. Many traditional surgical interventions such as posterior glenohumeral capsulorrhaphy, biceps tendon lengthening, humeral osteotomy, anterior capsule release, nerve transfer/graft, botox, muscle and or tendon transfer and release have been reported to improve limb functions in this group of patients [8-13].

We and other investigators have demonstrated that soft tissue procedures such as muscle release and tendon transfers [14-21] lead to better shoulder abduction and flexion through releasing the existing contractures. Derotational osteotomy of the humerus [13–16] improves the resting position of the arm, but neglects the glenohumeral and SHEAR (Scapular Hypoplasia, Elevation and Rotation) deformities. Surgical treatments such as humeral osteotomy are likely to fail or have significant rates of recurrence, as they do not address these two osseous deformities.

We have published extensively the effectiveness of triangle tilt surgery in correcting glenohumeral joint incongruity and thereby improving upper extremity functions in OBPI patients, who had treatments primarily with us [22-31]. Here, we show both functional and anatomical improvements significantly after triangle tilt and or mod

Quad as revision surgeries in 20 OBPI patients, who had other traditional surgical treatments at outside clinics before visiting our clinic for further treatment.

Patients and Methods:

We conducted a retrospective study in our medical records consisting of OBPI patients, who came to our clinic with a history of prior operative procedures at other hospitals. We identified 20 OBPI children (10 girls and 10 boys), aged between 2.0 and 11.8 years (mean age 6.5 years), who had other traditional surgical treatments at other institutions and had modified Quad and or triangle tilt as revision surgeries with us. Of 20 OBPI patients in our present study group, 8 patients undergone only the bony procedure, triangle tilt and 10 had both triangle tilt and modQuad (Tables 1 and 2). Therefore, these 18 patients (Table 2) have anatomical and radiological scores (PHHA, SHEAR and glenoid version), in addition to functional modifies Mallet scale (Table 1). Two 2 patients, number 19 and 20 in Table 1, underwent only modQuad surgery, as they did not have shoulder subluxation. Therefore, these 2 patients did not need to undergo triangle tilt surgery, which addresses shoulder subluxation. Mean modified Mallet and radiological scores were measured and compared. All measurements were done at least one-year post surgery.

The nerve involvement was C5-6 (n= 5), C5-7 (n= 8), and total (n = 7). Prior surgical procedures that the patients had at other clinics are included nerve transfer/graft, neurolysis, brachial plexus exploration, botox, muscle/tendon transfer and release, humeral osteotomy and anterior capsule release. We compared statistically the results obtained from other procedures performed in other institutes to outcomes of our procedures at least with a follow up of one-year. In addition, their radiological scores

such as posterior subluxation, and glenoid version were measured from CT scans and MRI in both groups and compared.

Clinical assessment

Patients were evaluated with a physical exam and through the modified Mallet clinical assessment[32, 33] with video recordings of patients performing external rotation, hands to mouth, hands to neck, hands to spine, and supination pre- and post-operatively. For each functional Mallet parameter, patients were scored on a scale of 1–5 with 5 as normal function and 1 denoting lack of any movement.

Radiological evaluation

CT or MRI images were used to measure the posterior humeral head subluxation , glenoid version [34][32], and SHEAR deformity [35][33], which evaluate the bony deformities of the patients' shoulder joint before and after triangle tilt surgery.

Operative technique

Triangle tilt [22-31] and modified Quad procedures [16] [36, 37][34, 35] have been shown to have successful outcomes in OBPI patients.

Statistical analysis

The ~~A~~ Student's t test statistic was applied to compare the mean Mallet scores and bony parameters between the both groups using the 'Analyse it' plugin (Leeds, UK) for Microsoft Excel 2003. A value of $p < 0.05$ was considered to be statistically significant.

Results:

Pre- revision surgery mean modified Mallet score was 12.0 ± 1.5 (Table 1, Figure 1 upper panels). This functional score was greatly improved to 18 ± 2.3 ($P < 0.0001$) at least one-year after modified Quad and or triangle tilt revision surgeries (Table 1, Figure

1 lower panels). Further, their radiological scores such as PHHA and glenoid version were improved significantly to 31.9 ± 13.6 ($P < 0.001$) and -16.3 ± 11 ($P < 0.0002$) respectively at least one-year after triangle tilt surgery (Table 2 and Figures 2 a and b, lower panels), when compared to their radiological outcomes of other procedures before having triangle tilt with us (mean PHHA, glenoid version and SHEAR were 14.6 ± 21.7 , -31.6 ± 19.3 and 16.1 ± 14.7 respectively; Table 2, Figures 2 a and b, upper panels). Normal values are PHHA 50, glenoid version and SHEAR 0.

Discussion:

All 20 patients in our present study had poor shoulder abduction and flexion because of C5 injury. They all had one or multiple surgical treatments with other surgeons before visiting our clinic (Table 1). These conventional treatments fail to address the SHEAR deformity [35][33] associated with most OBPI. For example, the recurrence of medial rotation contracture (MRC) after humeral osteotomy is common because of the SHEAR and the impingement of the distal acromioclavicular triangle against the humeral head. Without addressing the joint incongruency and SHEAR deformity, procedures such as humeral osteotomy are likely to fail or have significant rates of recurrence. Open reduction or arthroscopic anterior capsulectomy alone or with tendon transfers may improve passive external rotation and active range of motion, but results in external rotation deformity with significant internal rotation contracture [8, 18–20]. Another example, Steindler flexoroplasty, which is used to improve active flexion of the elbow. One patient in our study group had Steindler flexoroplasty at other clinic before presenting to us. This treatment obviously did not improve overall upper extremity functions. Therefore, these patients had poor functions after having such traditional

treatments at other clinics (Table 1, Figure 1 upper panels), (Table 2, Figure 2 a and b, upper panels).

Modified Quad procedure addresses poor shoulder abduction and flexion due to C5 injury in all permanent OBPI patients, but does not realign the deformed glenohumeral joint (GHJ) and does not correct SHEAR deformity. Therefore, triangle tilt surgery was performed on these patients. This procedure has been shown to effectively addresses these bony deformities, and improves the anatomy and overall functions of the shoulder [22-31, 38]. The functional benefits of mod Quad [16], and triangle tilt surgeries have been extensively discussed in our previous publications [22-31,38]. After undergone these surgical procedures with us, these patients had better results both functionally and anatomically, which is statistically significant, when compared to the outcomes of other traditional surgical treatments at outside clinics.

There was statistically significant improvement anatomically, after having triangle tilt compared to the radiological outcomes of other procedures.

Conclusion:

We demonstrate here, the triangle tilt and modified Quad as successful revision surgeries in 20 OBPI patients, who had other conventional surgical treatments at other clinics. before presenting to us for further treatment.

Conflicts of interest:

The authors report that there are no conflicts of interest.

Funding:

None.

Ethical approval statement:

Written informed consent was obtained from all patients for publication and accompanying images. A copy of the written consent is available for review on request.

References:

1. Birch R: **Late sequelae at the shoulder in obstetrical palsy in children.** In *Surgical techniques in orthopaedics and traumatology: Shoulder. Volume 3.* Edited by Randelli M, Karlsson J. Paris: Elsevier; 2001: 55-200-E-210: *Surgical Techniques in Orthopaedics and Traumatology*].
2. Kon DS, Darakjian AB, Pearl ML, Kosco AE: **Glenohumeral deformity in children with internal rotation contractures secondary to brachial plexus birth palsy: intraoperative arthrographic classification.** *Radiology* 2004, **231**:791-795.
3. van der Sluijs JA, van Ouwerkerk WJ, de Gast A, Wuisman PI, Nollet F, Manoliu RA: **Deformities of the shoulder in infants younger than 12 months with an obstetric lesion of the brachial plexus.** *J Bone Joint Surg (Br)* 2001, **83**:551-555.
4. Nath RK, Mackinnon SE, Jensen JN, Parks WC: **Spatial pattern of type I collagen expression in injured peripheral nerve.** *J Neurosurg* 1997, **86**:866-870.
5. Birch R: **Invited editorial: Obstetric brachial plexus palsy.** *J Hand Surg (Br)* 2002, **27 B**:3-8.
6. Waters PM: **Obstetric Brachial Plexus Injuries: Evaluation and Management.** *J Am Acad Orthop Surg* 1997, **5**:205-214.
7. Birch R, Bonney G, Wynn Parry CB: **Birth lesions of the brachial plexus.** In *Surgical disorders of the peripheral nerves.* Edited by Birch R, Bonney G, Wynn Parry CB. New York, NY: Churchill Livingstone; 1998: 209-233
8. Shenaq SM, Kim JY, Armenta AH, Nath RK, Cheng E, Jedrysiak A: **The Surgical Treatment of Obstetric Brachial Plexus Palsy.** *Plast Reconstr Surg* 2004, **113**:54E-67E.
9. Nath RK, Somasundaram C, Mahmooduddin F: **Comparing functional outcome of triangle tilt surgery performed before versus after two years of age.** *Open Orthop J* 2011, **5**:59-62.
10. Hoffer MM, Phipps GJ: **Closed reduction and tendon transfer for treatment of dislocation of the glenohumeral joint secondary to brachial plexus birth palsy.** *J Bone Joint Surg (Am)* 1998, **80**:997-1001.
11. Pearl ML, Edgerton BW, Kon DS, Darakjian AB, Kosco AE, Kazimiroff PB, Burchette RJ: **Comparison of arthroscopic findings with magnetic resonance imaging and arthrography in children with glenohumeral deformities secondary to brachial plexus birth palsy.** *J Bone Joint Surg (Am)* 2003, **85-A**:890-898.
12. Pedowitz DI, Gibson B, Williams GR, Kozin SH: **Arthroscopic treatment of posterior glenohumeral joint subluxation resulting from brachial plexus birth palsy.** *J Shoulder Elbow Surg* 2007, **16**:6-13.

13. Kambhampati SB, Birch R, Cobiella C, Chen L: **Posterior subluxation and dislocation of the shoulder in obstetric brachial plexus palsy.** *J Bone Joint Surg (Br)* 2006, **88**:213-219.
14. Al-Qattan MM: **Latissimus dorsi transfer for external rotation weakness of the shoulder in obstetric brachial plexus palsy.** *J Hand Surg (Br)* 2003, **28**:487-490.
15. El-Gammal TA, Saleh WR, El-Sayed A, Kotb MM, Imam HM, Fathi NA: **Tendon transfer around the shoulder in obstetric brachial plexus paralysis: clinical and computed tomographic study.** *J Pediatr Orthop* 2006, **26**:641-646.
16. Nath RK, Paizi M: **Improvement in abduction of the shoulder after reconstructive soft-tissue procedures in obstetric brachial plexus palsy.** *J Bone Joint Surg (Br)* 2007, **89**:620-626.
17. Pagnotta A, Haerle M, Gilbert A: **Long-term results on abduction and external rotation of the shoulder after latissimus dorsi transfer for sequelae of obstetric palsy.** *Clin Orthop Relat Res* 2004:199-205.
18. Safoury Y: **Muscle transfer for shoulder reconstruction in obstetrical brachial plexus lesions.** *Handchir Mikrochir Plast Chir* 2005, **37**:332-336.
19. van der Sluijs JA, van Ouwerkerk WJ, de Gast A, Nollet F, Winters H, Wuisman PI: **Treatment of internal rotation contracture of the shoulder in obstetric brachial plexus lesions by subscapular tendon lengthening and open reduction: early results and complications.** *J Pediatr Orthop B* 2004, **13**:218-224.
20. Waters PM, Bae DS: **The early effects of tendon transfers and open capsulorrhaphy on glenohumeral deformity in brachial plexus birth palsy.** *J Bone Joint Surg (Am)* 2008, **90**:2171-2179.
21. Waters PM, Bae DS: **Effect of tendon transfers and extra-articular soft-tissue balancing on glenohumeral development in brachial plexus birth palsy.** *J Bone Joint Surg (Am)* 2005, **87**:320-325.
22. Nath RK, Avila MB, Karicherla P: **Triangle tilt surgery as salvage procedure for failed shoulder surgery in obstetric brachial plexus injury.** *Pediatr Surg Int* 2010, [Epub ahead of print].
23. Nath RK, Amrani A, Melcher SE, Eichhorn MG: **Triangle tilt surgery in an older pediatric patient with obstetric brachial plexus injury.** *ePlasty* 2009, **9**:e26.
24. Nath RK, Amrani A, Melcher SE, Wentz MJ, Paizi M: **Surgical normalization of the shoulder joint in obstetric brachial plexus injury.** *Ann Plast Surg*, **65**:411-417.
25. Nath RK, Avila MB, Karicherla P, Somasundaram C: **Assessment of triangle tilt surgery in children with obstetric brachial plexus injury using the pediatric outcomes data collection instrument.** *Open Orthop J* 2011, **5**:385-388.
26. Nath RK, Liu X, Melcher SE, Fan J: **Long-term outcomes of triangle tilt surgery for obstetric brachial plexus injury.** *Pediatr Surg Int* 2010, **26**:393-399.
27. Nath RK, Mahmooduddin F: **Triangle tilt surgery: effect on coracohumeral distance and external rotation of the glenohumeral joint.** *Eplasty* 2010, **10**:e67.

28. Nath RK, Melcher SE, Lyons AB, Paizi M: **Surgical correction of the medial rotation contracture in obstetric brachial plexus palsy.** *J Bone Joint Surg (Br)* 2007, **89**:1638-1644.
29. Nath RK, Melcher SE, Paizi M: **Surgical correction of unsuccessful derotational humeral osteotomy in obstetric brachial plexus palsy: Evidence of the significance of scapular deformity in the pathophysiology of the medial rotation contracture.** *J Brachial Plex Peripher Nerve Inj* 2006, **1**:9.
30. Nath RK, Somasundaram C, Mahmooduddin F: **Triangle tilt and steel osteotomy: similar approaches to common problems.** *Open Orthop J* 2011, **5**:124-133.
31. Nath RK, Somasundaram C, Melcher SE, Bala M, Wentz MJ: **Arm rotated medially with supination - the ARMS variant: description of its surgical correction.** *BMC Musculoskelet Disord* 2009, **10**:32.
32. Mallet J: **[Obstetrical paralysis of the brachial plexus. II. Therapeutics. Treatment of sequelae. e. Results of different therapeutic techniques and therapeutic indications].** *Rev Chir Orthop Reparatrice Appar Mot* 1972, **58 Suppl 1**:192-196.
33. Nath RK: *Obstetric brachial plexus injuries-Erb's palsy: The Nath method of diagnosis and treatment.* College Station, TX: VirtualBookworm.com Publishing; 2007.
34. Friedman RJ, Hawthorne KB, Genez BM: **The use of computerized tomography in the measurement of glenoid version.** *J Bone Joint Surg (Am)* 1992, **74**:1032-1037.
35. Nath RK, Paizi M: **Scapular deformity in obstetric brachial plexus palsy: a new finding** *Surg Radiol Anat* 2007, **29**:133-140.
36. Nath RK, Somasundaram C: **Successful outcome of modified quad surgical procedure in preteen and teen patients with brachial plexus birth palsy.** *Eplasty* 2012, **12**:e54.
37. Nath RK, Kumar N, Somasundaram C: **Modified Quad surgery significantly improves the median nerve conduction and functional outcomes in obstetric brachial plexus nerve injury.** *Ann Surg Innov Res* 2013, **7**:5.
38. Nath RK, Amrani A, Melcher SE, Wentz MJ, Paizi M: **Surgical normalization of the shoulder joint in obstetric brachial plexus injury.** *Ann Plast Surg* 2010, **65**:411-417.

MQ- modified Quad, HO- Humeral osteotomy.

Table 2: Comparing anatomical improvements of triangle tilt to other surgeon surgeries in OBPI.

Patients	Other surgeons & previous Surgeries	PreTT- PHHA	PostTT- PHHA	PreTT- Version	PostTT- Version	PreTT- SHEAR	PostTT- SHEAR
1	Subscap release& lat dorsi rerouting	8	33	-47	-14		
2	Neurolysis, MQ, HO	16	14	-41	-35	24	10
3	MQ	-12	19	-65	-33	40	39
4	Nerve graft, FO, BTL, MQ	32	37	-21	-10	3	1
5	Botox, MQ	33	45	-18	-15	15	3
6	Nerve graft	47	48	-10	-1	5	14
7	Neurolysis, Nerve graft	-7	22	-62	-12	8	22
8	Neuroma excision, nerve graft	34	35	-20	-11	0	0
9	Nerve transfer	33	29	-16	-21	15	12
10	Coracoacromial release/resection	-12	17	-51	-35	30	15
11	Neurolysis, nerve graft	13	4	-20	-15	7	4
12	Wrist Caps, HO	39	50	0	0	9	0
13	Sural nerve graft	38	51	-10	-4	0	1
14	Botox, MQ	-8	44	-38	-22	11	2
15	Neurolysis, MQ	-14	35	-33	-10	25	30
16	Muscle release	0	19	-45	-27	32	8
17	Anterior Capsule Release	-11	34	-53	-22	48	41
18	Tendon transfer & neurolysis	33	39	-18	-7	1	1
Mean		14.6 ±	31.9 ±	-31.6 ±	-16.3 ±	16.1 ±	11.9 ±
STD		21.7	13.6	19.3	11.0	14.7	13.5
P value			0.001		0.0002		0.087

Normal values are PHHA 50, glenoid version and SHEAR 0.

TT- Triangle Tilt, MQ- modified Quad, HO- Humeral Osteotomy, FO- Forearm Osteotomy, BTL- Biceps Tendon Lengthening, PHHA- Percentage of the Humeral Head Anterior.

Figure legends:

Figure 1: Modified Mallet functions performed by an OBPI child, who had surgeries at other clinics before presenting to us (upper panels) and the same child, at least one-year after having modified Quad and triangle tilt as revision surgeries at our clinic (lower panels).

Figure 2a and b: Comparison of CT images of OBPI children, who had surgeries at other clinics before presenting to us (upper panels) and the CT images of the same children at least one-year after having triangle tilt as revision surgery at our clinic (lower panels).

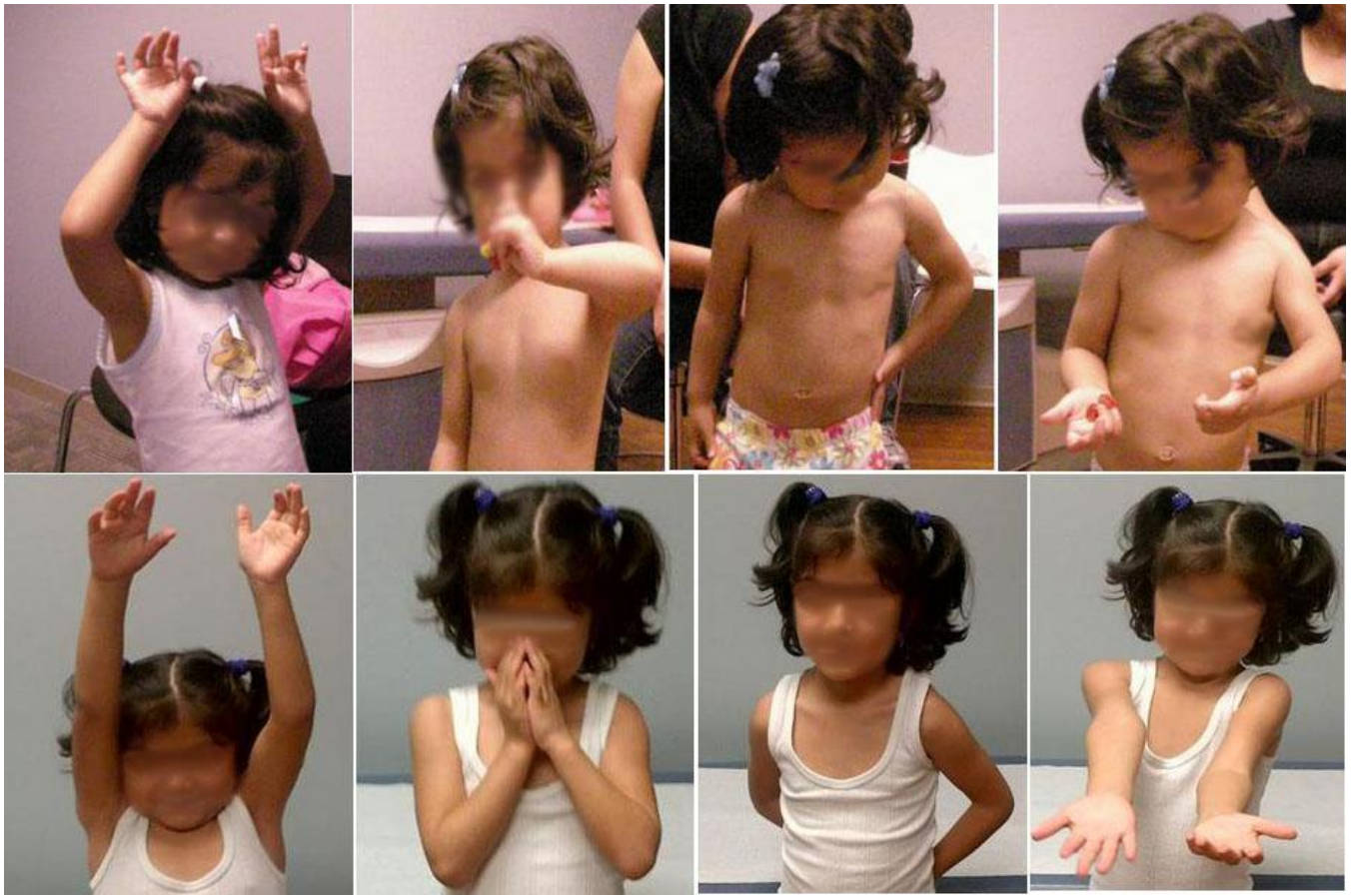

Figure 1.

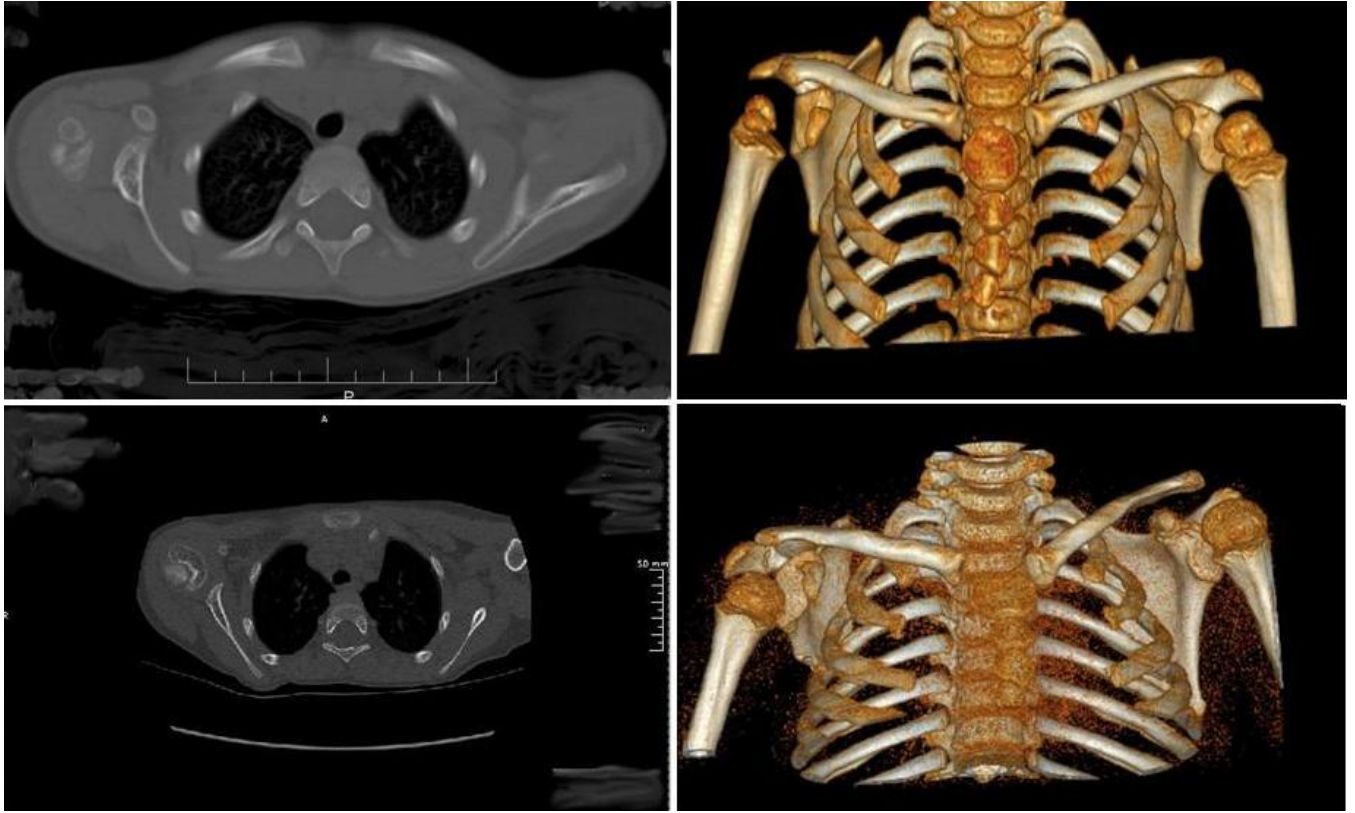


Figure 2a.

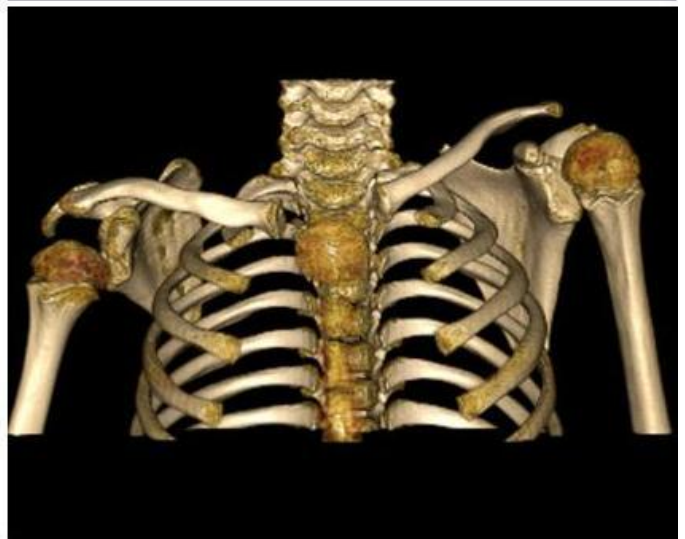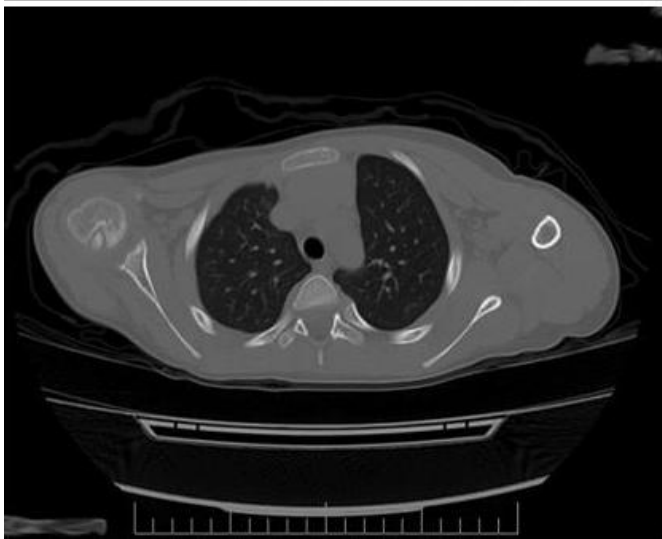
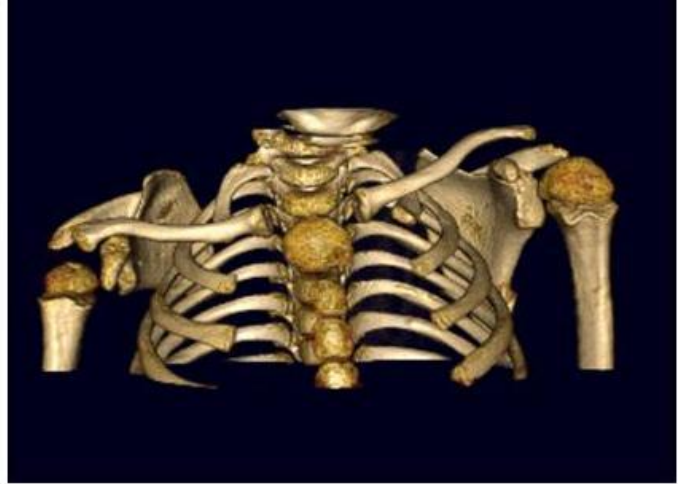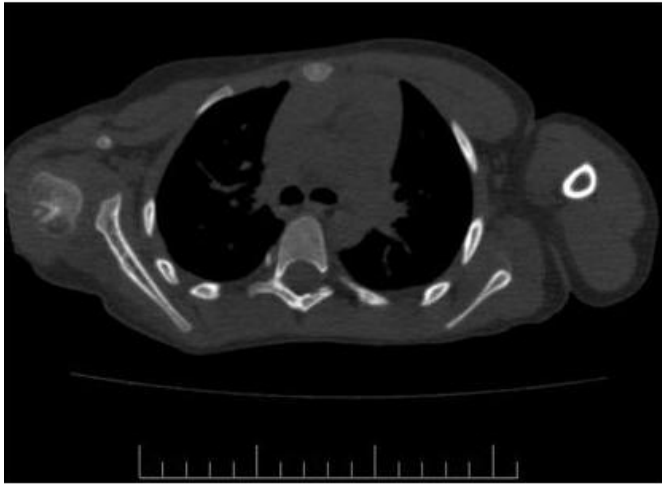


Figure 2b.