

## Portal biliopathy

Mohammad S Khuroo, Ajaz A Rather, Naira S Khuroo, Mehnaaz S Khuroo

Mohammad S Khuroo, Sher-I-Kashmir Institute of Medical Sciences, Srinagar Kashmir 190010, India

Mohammad S Khuroo, Digestive Diseases Centre, Dr. Khuroo's medical Clinic, Srinagar, Kashmir 190010, India

Ajaz A Rather, Department of Surgery, SKIMS Medical College and Hospital, Bemina, Srinagar, Kashmir 190010, India

Naira S Khuroo, Consultant Radiology, Digestive Diseases Centre, Dr. Khuroo's Medical Clinic, Srinagar, Kashmir 190010, India

Mehnaaz S Khuroo, Department of Pathology, Govt. Medical College, Srinagar, Kashmir 190001, India

**Author contributions:** All authors contributed equally; Rather AA, Khuroo NS and Khuroo MS made literature search; Khuroo NS conducted the radiological studies and critically reviewed the images; Khuroo MS and Khuroo NS wrote the paper; all authors read the paper and made necessary corrections.

**Supported by** Dr. Khuroo's Medical Trust, a nonprofit organization which supports academic activities, disseminates medical education and helps poor patients for medical treatment.

**Conflict-of-interest statement:** The authors report no conflict of interest.

**Open-Access:** This article is an open-access article which was selected by an in-house editor and fully peer-reviewed by external reviewers. It is distributed in accordance with the Creative Commons Attribution Non Commercial (CC BY-NC 4.0) license, which permits others to distribute, remix, adapt, build upon this work non-commercially, and license their derivative works on different terms, provided the original work is properly cited and the use is non-commercial. See: <http://creativecommons.org/licenses/by-nc/4.0/>

**Manuscript source:** Invited manuscript

**Correspondence to:** Mohammad S Khuroo, Director, Digestive Diseases Centre, Dr. Khuroo's Medical Clinic, Sector 1, SK Colony, Qamarwari, Srinagar, Kashmir 190010, India. [khuroo@yahoo.com](mailto:khuroo@yahoo.com)  
Telephone: +91-194-2492398

**Fax:** +91-194-2491190

**Received:** March 28, 2016

**Peer-review started:** March 29, 2016

**First decision:** May 12, 2016

**Revised:** June 22, 2016

**Accepted:** August 1, 2016

**Article in press:** August 1, 2016

**Published online:** September 21, 2016

## Abstract

Portal biliopathy refers to cholangiographic abnormalities which occur in patients with portal cavernoma. These changes occur as a result of pressure on bile ducts from bridging tortuous paracholedochal, epicholedochal and cholecystic veins. Bile duct ischemia may occur due prolonged venous pressure effect or result from insufficient blood supply. In addition, encasement of ducts may occur due fibrotic cavernoma. Majority of patients are asymptomatic. Portal biliopathy is a progressive disease and patients who have long standing disease and more severe bile duct abnormalities present with recurrent episodes of biliary pain, cholangitis and cholestasis. Serum chemistry, ultrasound with color Doppler imaging, magnetic resonance imaging with magnetic resonance cholangiopancreatography and magnetic resonance portovenography are modalities of choice for evaluation of portal biliopathy. Endoscopic retrograde cholangiography being an invasive procedure is indicated for endotherapy only. Management of portal biliopathy is done in a stepwise manner. First, endotherapy is done for dilation of biliary strictures, placement of biliary stents to facilitate drainage and removal of bile duct calculi. Next portal venous pressure is reduced by formation of surgical porto-systemic shunt or transjugular intrahepatic portosystemic shunt. This causes significant resolution of biliary changes. Patients who persist with biliary symptoms and bile duct changes may benefit from surgical biliary drainage procedures (hepaticojejunostomy or choledochoduodenostomy).

**Key words:** Biliary disease; Extrahepatic portal venous obstruction; Portal cavernoma; Bile duct strictures; Bile duct calculi

© **The Author(s) 2016.** Published by Baishideng Publishing Group Inc. All rights reserved.

**Core tip:** Extrahepatic portal vein obstruction is often encountered in children in India. It is caused by long standing thrombosis of portal vein and leads to cavernous transformation of the bridging venous collaterals. Cholangiographic abnormalities occur in majority of such patients, however, the entity stays asymptomatic in early stages. Biliopathy is a progressive disease and patients surviving to adulthood develop more severe biliary abnormalities and present with clinical disease. Now, portal biliopathy is an important clinical entity faced by hepatologists in India. Since the disease was described in early 90's, there have been important developments in definition, pathogenesis, diagnostic modalities and therapeutic interventions of portal biliopathy.

Khuroo MS, Rather AA, Khuroo NS, Khuroo MS. Portal biliopathy. *World J Gastroenterol* 2016; 22(35): 7973-7982 Available from: URL: <http://www.wjgnet.com/1007-9327/full/v22/i35/7973.htm> DOI: <http://dx.doi.org/10.3748/wjg.v22.i35.7973>

## INTRODUCTION

Portal biliopathy refers to cholangiographic abnormalities which occur in patients with portal cavernoma<sup>[1-3]</sup>. Biliary abnormalities do occur in patients with cirrhosis and idiopathic portal hypertension. These are primarily in the intrahepatic bile ducts and are caused by hepatic nodularity and fibrosis rather than portal cavernoma<sup>[4]</sup>. Some investigators have suggested that such cholangiographic abnormalities should also be defined as portal biliopathy. However, there is a general consensus that portal biliopathy should be restricted to those cholangiographic abnormalities which are caused by portal cavernoma. Other biliary diseases which may superficially resemble portal biliopathy and need to be excluded include choledocholithiasis, primary sclerosing cholangitis, biliary parasitosis, AIDS cholangiopathy, oriental-cholangio-hepatitis and cholangiocarcinoma *etc.*<sup>[1]</sup>.

### Historical background

Portal biliopathy as a clinical entity was established by 3 reports published in early 90's. In 1989, we were confronted with biliary disease in two patients of portal cavernoma<sup>[5]</sup>. Both patients exsanguinated and died at elective gall bladder surgery. We searched the literature around that time and could not find well-documented reports of biliary disease with extrahepatic

portal venous obstruction (EHPVO). From December 1989 to November 1991, we<sup>[3]</sup> prospectively studied 21 consecutive such patients for evidence of biliary tract disease. Cholangiographic abnormalities were detected in 17 (80.9%) patients. Three adult patients had clinically manifest biliary disease. The pathogenesis of these changes and their relationship with portal cavernoma was critically evaluated. Another study reported on bile duct changes in 20 patients with portal cavernoma<sup>[6]</sup>. Sarin *et al.*<sup>[7]</sup> observed similar changes in 80% patients with EHPVO. Since then, several investigators have reported on case series of patients with portal biliopathy (Table 1)<sup>[8-22]</sup>. Portal biliopathy has been described by a multitude of names in literature. Dilawari and Chawla<sup>[6]</sup> described these cholangiographic abnormalities as "pseudosclerosing cholangitis". Bayraktar<sup>[8]</sup> described these abnormalities resembling "pseudocholangiocarcinoma sign". Dhiman *et al.*<sup>[16]</sup> named it portal hypertensive biliopathy, while others have used terms extrahepatic portal biliopathy<sup>[23]</sup>, vascular biliopathy<sup>[24]</sup>, portal ductopathy, portal cholangiopathy<sup>[25]</sup> and portal cavernoma cholangiopathy<sup>[1]</sup> to describe this entity. However, authors believe that portal biliopathy suggested by Sarin *et al.*<sup>[7]</sup> is appropriate term to reflect the cholangiographic abnormalities in this entity.

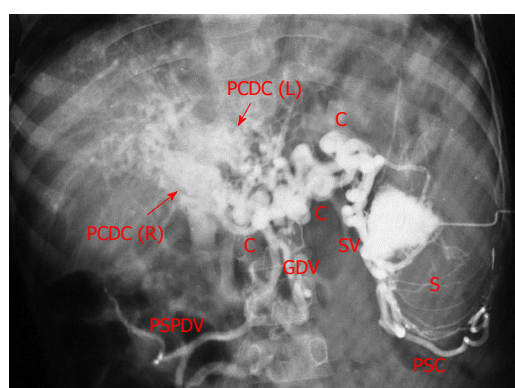
## BILIARY ANATOMY

Biliary tract has intrahepatic and extrahepatic components. The anatomy of the intrahepatic bile duct follows that of the portal system and segmentation of the liver. The Couinaud classification divides liver in to eight (I to VIII) segments. Right liver lobe, consisting of segments V, VI, VII and VIII is drained by the right hepatic duct. The left hepatic lobe consisting of Segments II, III and IV is drained by left hepatic duct. Caudate lobe (segment 1) receives small ducts from right and left lobes. The right and left hepatic ducts join in the hilum to form common hepatic duct, which continues as common bile duct from the point cystic duct joins it laterally. Common bile duct is 6.0-8.0 cm long and has four segments namely supraduodenal, retroduodenal, retropancreatic and intraduodenal<sup>[26,27]</sup>.

Biliary tree including ampulla of Vater receive blood supply from branches of the coeliac trunk<sup>[27]</sup>. The common bile duct is palisaded by 3 o'clock (left) and 9 o'clock (right) marginal arteries, which derive blood supply from right hepatic artery, left hepatic artery, cystic artery and posterior superior pancreaticoduodenal artery. The marginal arteries through intricate network of vessels form two plexuses, one around the bile duct (paracholedochal plexus) and another on the surface of bile duct (epicholedochal plexus). Several branches perforate the bile duct wall (intramural plexus) and reach under the bile duct epithelium (subepithelial plexus). The marginal arteries intercommunicate at hilum forming hilar plexus. The

**Table 1** Reported studies of portal biliopathy

Ref.	Year of publication	City Country	Number of patients	Age (mean)	Male: Female	Biliary changes	Symptomatic disease
Khuroo <i>et al</i> <sup>[3]</sup>	1993	Kashmir India	21	14.0	13:8	81%	38%
Dilawari <i>et al</i> <sup>[6]</sup>	1992	Chandigarh India	20	22.0	16:4	100%	5%
Sarin <i>et al</i> <sup>[7]</sup>	1992	Delhi India	20	-	16:4	90%	15%
Bayraktar <i>et al</i> <sup>[8]</sup>	1995	Ankara Turkey	44	31.5	24:20	94%	30%
Malkan <i>et al</i> <sup>[9]</sup>	1999	Mumbai India	20	23.0	12:08	85%	10%
Nagi <i>et al</i> <sup>[10]</sup>	2000	Chandigarh India	43	-	25:18	100%	19%
Condat <i>et al</i> <sup>[11]</sup>	2003	Paris France	25	49.5	15:1	84%	28%
Sezgin <i>et al</i> <sup>[12]</sup>	2003	Mersin Turkey	36	-		94%	10%
Khare <i>et al</i> <sup>[13]</sup>	2005	Lucknow India	13	-	9:4	100%	100%
Belhadjbrik <i>et al</i> <sup>[14]</sup>	2006	Tunis Tunisia	17	-		100%	82%
Chevallier <i>et al</i> <sup>[15]</sup>	2006	Nice Cedex 3 France	10	-		90%	40%
Dhiman <i>et al</i> <sup>[16]</sup>	2007	Chandigarh India	53	24.5	36:17	100%	24.5%
Vibert <i>et al</i> <sup>[17]</sup>	2007	Villejuif France	64	-		100%	30%
Oo <i>et al</i> <sup>[18]</sup>	2009	Birmingham UK	13	-		100%	100%
Llop <i>et al</i> <sup>[19]</sup>	2011	Barcelona Spain	67	47.0	41:26	78%	21%
Agarwal <i>et al</i> <sup>[20]</sup>	2011	New Delhi India	39	29.6	27:11	100%	100%
Aguirre <i>et al</i> <sup>[21]</sup>	2012	Bogota Columbia	18	-		100%	100%
Aguilar-Olivas <i>et al</i> <sup>[22]</sup>	2014	DF Mexico	4	-		100%	100%



**Figure 1** Splenoportovenography in a patient with extrahepatic portal venous obstruction and portal cavernoma. Contrast within splenic pulp (S) is drained by multiple splenic vein channels (SV) into large peripancreatic collaterals (C). There are two broad parallel conglomerate of veins in the porta hepatis (arrows) formed by right and left paracholedochal collaterals [PCDC (R) and PCDC (L) respectively], forming the portal cavernoma. Main portal vein is not seen (thrombosed). Retrograde filling of perisplenic collaterals (PSC), gastroduodenal vein (GDV) and posterior-superior pancreaticoduodenal vein (PSPDV) is seen.

right and left hepatic arteries are connected with each other by communicating arcade. The intrahepatic bile ducts are accompanied by corresponding arteries and form peribiliary plexus. These arteries communicate with venules through arteriportal channels.

The venous drainage of bile duct is accomplished by epicholedochal venous plexus of Saint and paracholedochal plexus of Petren. These drain in to 3 o'clock and 9 o'clock marginal veins. An additional 6 o'clock marginal vein may be present posterior to bile duct. The marginal veins drain in to gastric veins, posterior superior pancreaticoduodenal vein and gastroduodenal trunk<sup>[26]</sup>.

## PORTAL CAVERNOMA

Portal cavernoma is formed by serpiginous, tortuous

and dilated 3 o'clock and 9 o'clock marginal veins and venous of plexus of Petren, that bridge thrombosed portal vein. The portal vein, following thrombosis may be atretic or re-canalized. In addition, the epicholedochal plexus of Saint on the surface of bile ducts and cholecystic veins surrounding and within gallbladder wall also dilate and become tortuous (Figure 1)<sup>[28]</sup>. Portal cavernoma formation may take from a week to a year. Over time, the portal cavernoma may turn in to a "solid tumor-like cavernoma" compromising of fibrous hilar mass containing multiple collateral veins<sup>[1,3]</sup>.

Portal cavernoma in developing countries occurs in children and results from portal vein thrombosis secondary to neonatal umbilical sepsis and dehydration. In adults, portal vein thrombosis with resultant portal cavernoma is caused by a number of conditions including hypercoagulable states, myeloproliferative disorders, Bechet's syndrome, pancreatitis and pylephlebitis. No underlying cause is detectable in around 30% patients. Portal cavernoma formation is rare in portal vein thrombosis with underlying cirrhosis and portal hypertension, as stasis in portal venous system in such patients prevents formation of collaterals.

The diagnosis of portal cavernoma is easily made at grey scale and color Doppler sonography<sup>[29]</sup>. Portal vein is not visualized or may be atretic or recanalized. Liver hilum reveals multiple dilated serpiginous channels. Flow pattern within the tortuous channels on color and duplex Doppler show portal venous type of flow with absent respiratory or cardiac variation. Patients with solid tumor cavernoma depict an echogenic irregular mass of varying size with dilated tortuous channels passing through the mass. Hepatic arteries demonstrate increased flow to compensate for reduced portal flow. Multiphase computed tomography (CT) and magnetic resonance imaging (MRI) reveal thrombosed portal vein which may be atretic or recanalized with

dilated tortuous channels, enhancing during portal venous phase and not during arterial phase. This helps to exclude arteriovenous malformation. In solid tumor cavernoma, CT and MRI show an echogenic mass with numerous venous channels. In some patients, linear areas of calcification within the previously thrombosed portal vein may be seen, indicating chronic venous thrombosis.

## **PATHOGENESIS**

The pathogenesis of cholangiographic abnormalities in EHPVO and portal cavernoma are multifactorial<sup>[3]</sup>. Broadly the cholangiographic abnormalities have reversible and fixed component (Figure 2). Reversible component includes those changes which are likely to resolve following portal venous decompression [shunt surgery or transjugular intrahepatic portosystemic shunt (TIPS)]. These include shallow bile duct impressions and indentations causing wall irregularity, smooth strictures with upstream dilatation and luminal filling defects. These changes are as a result of dilatation of veins of the plexus of Saint, causing bile duct impingement. Bile duct strictures with upstream dilatation may be as a result of compression by dilated tortuous collaterals<sup>[30,31]</sup>. In addition, bile duct filling defects occur due to dilatation of perforators and subepithelial veins in the ducts. This hypothesis is based on findings at MRCP and MR portography which demonstrate signal void-defects of dilated veins around the bile duct lumen<sup>[32]</sup>. Rarely, bile duct wall shows localized thickening and luminal narrowing as a result of dilated tortuous choledochal vessels. Further shunt surgery or TIPS results in partial or complete resolution of cholangiographic abnormalities. In some cases, these changes of biliopathy may persist after portal decompression. This is related to persistence of portosystemic collaterals and does not necessarily imply ischemia as a cause of bile duct changes. Left hepatic duct is involved more often and shows more severe changes as umbilical vein enters left portal vein, leading to formation of prominent collaterals.

Fixed component cholangiographic abnormalities include those changes which do not regress after portal decompression. These include rigid stricture, angulation, and ductal ectasia. Rigid strictures are usually due to ischemia, which occurs as the time of portal vein thrombosis. As bile duct are supplied by hepatic arteries, ischemic necrosis may result from concomitant hepatic artery thrombosis. In addition, portal vein thrombosis per se may cause bile duct ischemia due to damage to the microvascular bile duct flow. Strictures can also form as a result of prolonged compression by dilated tortuous collaterals. Angulation and rigid strictures result from encasement of bile ducts by solid tumor-like cavernoma<sup>[1,3]</sup>. Gallstones formation results from several pathogenic mechanisms which include: (1) bile stasis due to strictures; (2) increased lithogenicity of bile; (3) reduced contractility

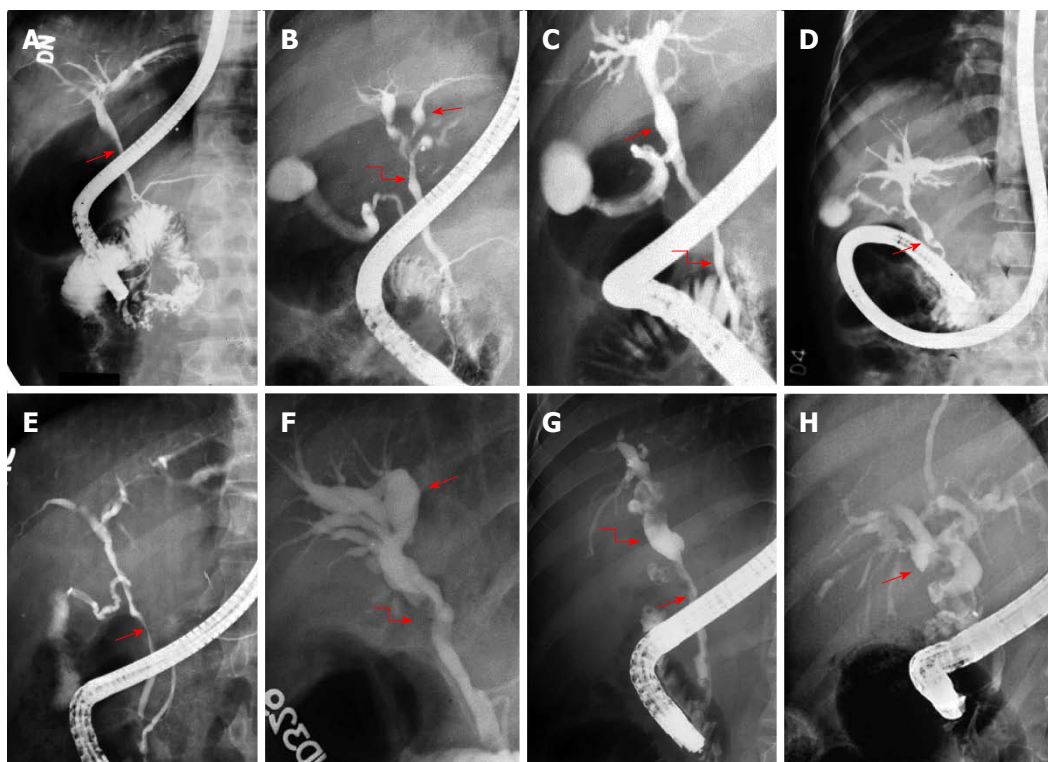
of gallbladder due to collateral in the gallbladder wall; and (4) decreased bile flow due to liver atrophy, resulting from reduced portal venous flow<sup>[33]</sup>.

## **CLINICAL DISEASE**

Majority of patients with portal biliopathy have no biliary symptoms (asymptomatic stage). Such patients have early cholangiographic abnormalities which include duct irregularity; serration, undulation, scalloping of the duct wall; and smooth extrinsic nodular, spiral or stenotic impressions on the ducts and filling defects in the bile and hepatic ducts. This asymptomatic phase of portal biliopathy may last for years and patients develop clinical biliary disease only if they survive to adulthood. Patients with clinical disease are older and have longer duration of portal hypertension. There is sparse data on the other factors like extent of thrombosis and the presence of portosystemic shunts affecting the occurrence of symptomatic biliopathy. During the asymptomatic phase, patients often show elevated serum alkaline phosphatase, the significance of which vis-à-vis biliary disease is difficult to interpret in children. The first detectable clinical disease starts with isolated elevated serum bilirubin and/or detectable icterus<sup>[34]</sup>. The occurrence of jaundice usually points to presence of slow onset subtle biliary obstruction or hemolysis related to large spleen and is often detected incidentally while evaluating the patients for other symptoms of portal hypertension. Patients with symptomatic biliary disease have advanced cholangiographic abnormalities which include ectasia of the ducts; angulation, displacement and strictures of the bile and hepatic ducts and aneurysmal dilatation of the intrahepatic biliary tree. The patients present with episodes of biliary pain or cholangitis and/or biliary obstruction. Biliary pain may be related to gallstones or bile duct stones or to cholangitis. Biliary obstruction presents with cholestasis with or without episodes of cholangitis<sup>[34-37]</sup>. There is considerable variation in clinical presentation of biliary obstruction. However, most of patients have recurrent and progressive disease and often need to be hospitalized repeatedly to control symptoms<sup>[34,38]</sup>. Portal biliopathy late in the clinical course cause marked bile duct abnormalities which include long (> 2 cm) or multifocal strictures, strictures associated with choledochal or intrahepatic calculi and biliopancreatic complications. Therapeutic options in such patients are limited due to extensive venous thrombosis and advanced liver disease.

## **NATURAL COURSE**

Data on the natural course of biliopathy following portal vein thrombosis and portal cavernoma are scarce<sup>[18,19,39]</sup>. Only one study has reported on follow up in 22 patients of portal vein thrombosis and 45 patients with established portal cavernoma<sup>[19]</sup>. At initial assessment, majority of patients in either group



**Figure 2** Endoscopic retrograde cholangiograms in 8 patients of portal biliopathy depicting spectrum of cholangiographic abnormalities of portal biliopathy. A: Extrinsic impression on common bile duct (arrow); B: Ectasia of left hepatic duct (arrow) and caliber irregularity of common hepatic duct (curved arrow); C: Ectasia of common hepatic duct (arrow) and caliber irregularity of common bile duct (curved arrow); D: Angulation (arrow) of common bile duct; E: Large smooth impression (arrow) on common bile duct; F: Angulation common hepatic duct (curved arrow) and gross ectasia of intrahepatic ducts (arrow); G: Long smooth stricture of common bile duct (arrow) with upstream dilatation (curved arrow); H: dilated bile ducts with multiple filling defects (arrow). Adapted and modified from Khuroo *et al*<sup>[3]</sup>.

had developed evidence of biliopathy. Symptomatic disease was limited to patients with severe biliary abnormalities. Over a follow up period extending up to 4 years, disease was non-progressive. Authors believed the disease to be a one-time event after acute portal vein thrombosis. However, patients with symptomatic biliopathy have established long-term disease extending for over 8 to 14 years. This suggests that natural course of portal biliopathy is progressive and long term portal hypertension and significant biliary abnormalities leading to symptomatic biliopathy<sup>[1]</sup>.

## DIAGNOSIS

### Ultrasonography

Ultrasound with color Doppler is an excellent imaging modality in evaluation of portal cavernoma<sup>[29]</sup> (Figure 3). Gray scale and color Doppler imaging show atretic or recanalized portal vein with a mass of multiple serpentine channels, seen in the porta hepatis. These collaterals demonstrate portal venous type flow<sup>[40]</sup>. An increased flow in hepatic artery may be seen, representing a compensatory mechanism to the reduced portal flow. Color Doppler has advantage of showing varices around and in the wall of gallbladder. Bile duct wall may show collaterals within the thickened bile ducts. Ultrasound can detect bile duct dilatation with associated cholelithiasis and choledocholithiasis.

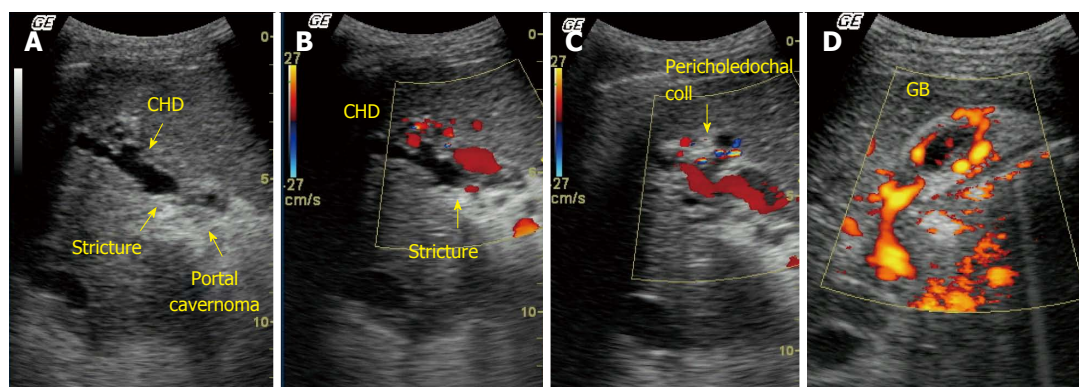
In addition, hepatic parenchyma can be well seen on ultrasound with associated portosystemic collaterals and splenomegaly. However, ultrasound has limitation in visualization of common bile duct especially in retroduodenal segment and cannot differentiate between extrinsic pressure from collaterals and ischemic stricturing.

### Computed tomography or magnetic resonance imaging

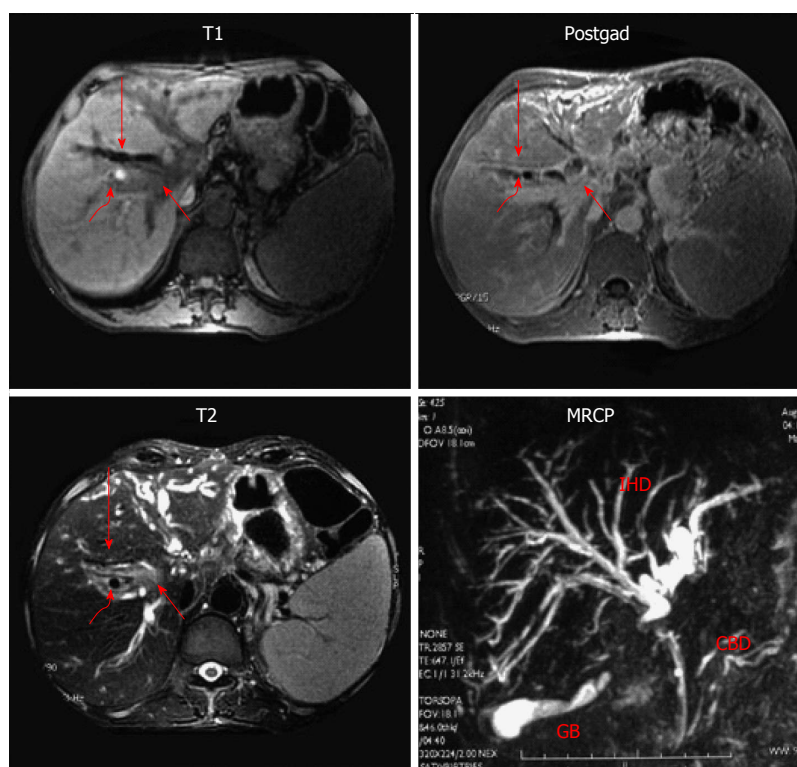
Contrast enhanced computed tomography (CECT) or magnetic resonance imaging (MRI) have advantage over ultrasound in delineating the anatomy of portal venous system (portovenography), help to find cause of portal venous thrombosis like pancreatitis and exclude biliary malignancy<sup>[21]</sup>. MRI is a better imaging tool in this setting as it does not expose incumbent to radiation and delineates better biliary anatomy. MRI can differentiate epicholedochal collaterals, which appear as signal void-defects from paracholedochal collaterals which appear as low signal channels on T2-weighted images<sup>[41]</sup>. Typical biliary findings of biliopathy are well seen on MR cholangiography<sup>[15,42]</sup>. Hence MRI is the modality of choice for mapping of the biliary and vascular abnormalities<sup>[43]</sup> (Figure 4).

### Endoscopic ultrasound

Role of endoscopic ultrasound (EUS) in the diagnosis of portal biliopathy is evolving<sup>[44-47]</sup>. Portal cavernoma



**Figure 3** Ultrasound with Doppler in a patient with extrahepatic portal venous obstruction and portal biliopathy. A: Gray scale image shows an echogenic mass in hilum (portal cavernoma). Common hepatic duct (CHD) shows dilatation and luminal irregularity with a stricture at the level of the cavernoma; B: Color Doppler image showed multiple pericholedochal collaterals around the strictured bile duct (arrow); C: Color Doppler image shows pericholedochal collaterals and recanalized irregular portal vein; D: Power Doppler images of gall bladder. Gall bladder wall is thickened with multiple collaterals within the gall bladder wall.



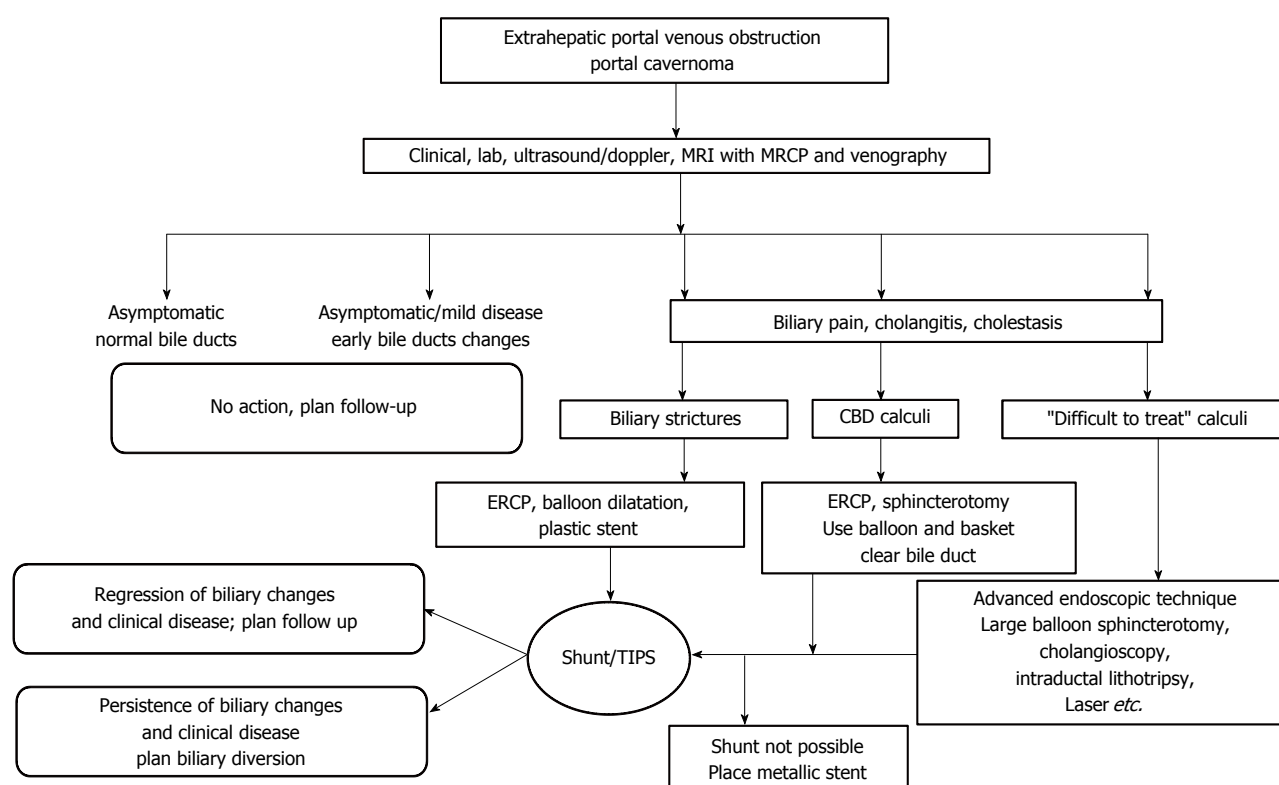
**Figure 4** Magnetic resonance imaging with Magnetic retrograde cholangiogram in a patient with portal biliopathy. T1 weighted, T2 weighted and post-gadolinium (postgad) images. Mass lesion (short arrow) is seen at the level of porta hepatis with dilated bile ducts (long arrow) and signal void (curved arrow), depicting collateral channels compressing bile ducts, MRCP. Common bile duct (CBD) shows luminal irregularity. There is a localized irregular stricture in common hepatic duct with upstream gross dilatation of intrahepatic ducts (IHD).

and its anatomy can be well defined. These collaterals appear as multiple vascular channels in and/or around the extrahepatic biliary tract. Paracholedochal, epicholedochal, intracholedochal and subepithelial varices can be well seen and differentiated<sup>[48]</sup>. Visualization of choledochal and subepithelial venous plexuses is important as biliary endotherapy may increase risk of hemobilia.

#### Endoscopic retrograde cholangiography

Endoscopic retrograde cholangiography (ERC) is the

gold standard for defining the biliary changes of portal biliopathy (Figure 2). In fact, ERC has been employed to define bile duct changes, study their distribution in the biliary tract and assess the severity and grading of abnormalities. ERC is being replaced by ultrasound and MRCP. ERC is invasive, has risk of complications and cannot be employed on repeated occasions for follow up examinations. In contrast ultrasound and MRCP are non-invasive, give comparable images of biliary tract and have advantages to further visualize portal venous system.



**Figure 5** Management algorithm in patients of extrahepatic portal venous obstruction and portal biliopathy. See text under "Management" for details. TIPS: Transjugular intrahepatic portosystemic shunt.

Cholangiographic abnormalities on ERC known to occur in portal biliopathy include: (1) shallow extrinsic impressions/indentations of the bile and hepatic ducts; (2) deep extrinsic impressions/indentations of the bile and hepatic ducts; (3) irregularity in ductal contour; (4) strictures with upstream dilatation; (5) filling defects which may be round, oval, or elongated and are caused by stones, intra-luminal varices, or blood clots; (6) bile duct angulation causing an angle of  $\leq 145^\circ$  between lower and upper ductal alignment; and (7) ectasia which cause dilated segment of biliary tree without any evident downstream obstruction. The cholangiographic abnormalities may occur in bile ducts alone, hepatic ducts alone, bile ducts with unilateral hepatic ducts and bile ducts bilateral hepatic ducts.

## MANAGEMENT

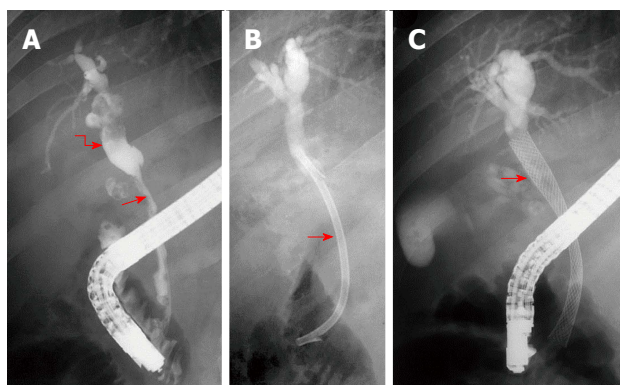
### Asymptomatic patients

Asymptomatic patients with portal biliopathy do not need any active treatment. Such patients have early cholangiographic abnormalities. As these changes are progressive in nature, it is worthwhile to have serial assessment of type, extent and severity of these changes on a long term follow up. Ultrasound with color Doppler is ideal imaging tool to evaluate portal cavernoma and biliary tract for strictures and stones. Patients with mild abnormalities in liver tests without clinical disease should be included in asymptomatic disease and need no active intervention.

### Endotherapy

Treatment of symptomatic biliopathy can be approached in a stepwise fashion. Initial treatment is aimed at managing biliary strictures and stones. Next portal decompression should be done to reverse biliary abnormalities. Lastly biliary obstruction should be relieved by biliary diversion at surgery<sup>[17,22,49,50]</sup> (Figure 5). Patients presenting with cholestasis and/or cholangitis should be primarily managed by biliary endotherapy<sup>[2,51]</sup>. Common bile stones are managed by endoscopic sphincterotomy with stone extraction<sup>[33]</sup>. Patients with cholangitis or cholestasis need endoscopic biliary drainage with plastic stents or nasobiliary drainage<sup>[52]</sup>. Biliary strictures can be treated by balloon dilatation and stent placement<sup>[53]</sup>.

Advanced biliary endoscopic procedures can be employed in patients with difficult biliary calculi. Such patients need large balloon sphincteroplasty, cholangioscopy with intraductal lithotripsy using laser and electrohydraulic probes. As of now, even intractable biliary calculi in biliopathy are amenable to endoscopic therapy. Many patients need repeated plastic stents and is a problem for patients who come from far flung regions and cannot reach tertiary care centers regularly. Such patients are candidates for placement of self-expanding metal stent (Figure 6)<sup>[54]</sup>. Placement of metallic stents in a benign disease may cause difficulty in retrieval of stents if needed and intraoperative difficulty in case these patients require surgical management for persistent biliary



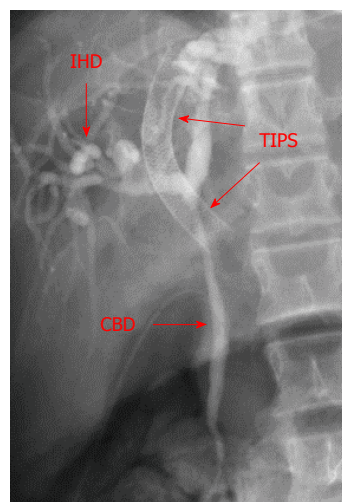
**Figure 6** Endoscopic retrograde cholangiogram and metallic biliary stenting in a patient with portal biliopathy. A: Long smooth stricture common bile duct (arrow) with upstream dilatation of intrahepatic ducts (curved arrow); B: A 12 Fr plastic stent (arrow) is placed across the stricture. Patient needed repeated stent replacement in the follow up and was considered for shunt surgery. Shunt surgery was not possible due to unavailability of a shuntable portal vein; C: Self-expanding nitinol biliary stent (arrow) placed across the stricture. Patient stays asymptomatic over long-term follow up.

symptoms<sup>[18,55]</sup>. Endoscopic sphincterotomy along with use of Dormia basket and balloon extraction of stones in portal biliopathy has been shown to be safe<sup>[56]</sup>. Intraductal and subepithelial collaterals are risk factors for hemobilia. Such varices can be demonstrated on EUS and it may be worth doing this procedure once biliary endotherapy is envisaged. Hemobilia, if occurs, is usually mild and needs conservative treatment and settles in most cases<sup>[55,57]</sup>.

Biliary surgery namely surgical removal of CBD calculi or bilio-enteric anastomosis without prior portal decompression carries higher mortality and should be avoided. Laparoscopic cholecystectomy for gallstones in two patients with pericholecystic collaterals and non-obstructive biliopathy has been performed safely with careful operative strategy and diligent hemostasis<sup>[58]</sup>. The use of concomitant ursodeoxycholic acid (UDCA) is recommended as it has been reported to be beneficial by some authors<sup>[59]</sup>.

### Shunt surgery

With advances in endotherapy, patients with biliopathy are increasingly being managed with multiple stents for prolonged periods of time. Such patients should be evaluated for surgical porto-systemic shunts or TIPS<sup>[24,25,60-63]</sup> (Figure 7). One of the strong arguments in favor of operative management has been the fact that surgery is a onetime procedure, does not require repeated hospital visits, which is particularly relevant for the majority of EHPVO patients who come from areas where specialized medical help with access to endotherapy may not be available. Shunt procedures cause regression in collaterals and as a result cause improvement in the cholangiographic abnormalities of portal biliopathy and significant clinical improvement. Follow up studies have shown that around two-thirds of patients remain asymptomatic and complete



**Figure 7** Transjugular intrahepatic porto-systemic shunt in a patient with extrahepatic portal venous obstruction and portal biliopathy. Common bile duct shows a long smooth stricture (CBD) with upstream dilatation of intrahepatic ducts (IHD). Transjugular intrahepatic porto-systemic shunt (TIPS) (arrows) was placed to decompress the portal venous circulation. Follow-up showed significant improvement in cholangiographic appearances.

reversal of cholangiographic abnormalities.

Even if the regression of cholangiographic changes is incomplete, majority of the patients remain asymptomatic probably due to slowing-down of progression of biliopathy after shunt. Around one third of patients continue to have cholangiographic abnormalities and may suffer from repeat biliary symptoms. TIPS, though effective in portal decompression has issues of wider accessibility and high occlusion rate at one year<sup>[64]</sup>. In patients with extensive thrombosis and non-shuntable vein or blocked shunt, patients must be managed with continued endoscopic stents. Such patients may be candidates for placement of self-expanding metal stents.

### Biliary drainage

The third phase is to manage patients who continue to be symptomatic with cholangiographic changes despite portal decompression. Some patients may develop symptoms due to blocked portosystemic shunt. Biliary drainage procedures like hepaticojejunostomy or choledochoduodenostomy are performed with good clinical results<sup>[20,65]</sup>. Liver transplantation is indicated in patients with secondary biliary cirrhosis and end stage liver disease<sup>[66,67]</sup>.

## REFERENCES

- 1 **Dhiman RK**, Saraswat VA, Valla DC, Chawla Y, Behera A, Varma V, Agarwal S, Duseja A, Puri P, Kalra N, Rameshbabu CS, Bhatia V, Sharma M, Kumar M, Gupta S, Taneja S, Kaman L, Zargar SA, Nundy S, Singh SP, Acharya SK, Dilawari JB. Portal cavernoma cholangiopathy: consensus statement of a working party of the Indian national association for study of the liver. *J Clin Exp Hepatol* 2014; 4: S2-S14 [PMID: 25755591 DOI: 10.1016/j.jceh.2014.02.003]

- 2 **Saraswat VA**, Rai P, Kumar T, Mohindra S, Dhiman RK. Endoscopic management of portal cavernoma cholangiopathy: practice, principles and strategy. *J Clin Exp Hepatol* 2014; **4**: S67-S76 [PMID: 25755598 DOI: 10.1016/j.jceh.2013.08.011]
- 3 **Khuroo MS**, Yattoo GN, Zargar SA, Javid G, Dar MY, Khan BA, Boda MI. Biliary abnormalities associated with extrahepatic portal venous obstruction. *Hepatology* 1993; **17**: 807-813 [PMID: 8491448]
- 4 **Chandra R**, Kapoor D, Tharakan A, Chaudhary A, Sarin SK. Portal biliopathy. *J Gastroenterol Hepatol* 2001; **16**: 1086-1092 [PMID: 11686833]
- 5 **Khuroo MS**. Landmarks in research-The Untold Stories: Portal Biliopathy-the biliary disease in extrahepatic portal hypertension. Available from: URL: <https://www.researchgate.net/publication/297916019>
- 6 **Dilawari JB**, Chawla YK. Pseudosclerosing cholangitis in extrahepatic portal venous obstruction. *Gut* 1992; **33**: 272-276 [PMID: 1541425]
- 7 **Sarin SK**, Bhatia V, Makwane U. Portal biliopathy in extra hepatic portal vein obstruction. *Ind J Gastroenterol* 1992; **2**: A82
- 8 **Bayraktar Y**, Balkanci F, Ozenc A, Arslan S, Koseoglu T, Ozdemir A, Uzunalioglu B, Telatar H, Gurakar A, Van Thiel DH. The "pseudo-cholangiocarcinoma sign" in patients with cavernous transformation of the portal vein and its effect on the serum alkaline phosphatase and bilirubin levels. *Am J Gastroenterol* 1995; **90**: 2015-2019 [PMID: 7485013]
- 9 **Malkan GH**, Bhatia SJ, Bashir K, Khemani R, Abraham P, Gandhi MS, Radhakrishnan R. Cholangiopathy associated with portal hypertension: diagnostic evaluation and clinical implications. *Gastrointest Endosc* 1999; **49**: 344-348 [PMID: 10049418]
- 10 **Nagi B**, Kochhar R, Bhasin D, Singh K. Cholangiopathy in extrahepatic portal venous obstruction. Radiological appearances. *Acta Radiol* 2000; **41**: 612-615 [PMID: 11092484]
- 11 **Condat B**, Vilgrain V, Asselah T, O'Toole D, Rufat P, Zappa M, Moreau R, Valla D. Portal cavernoma-associated cholangiopathy: a clinical and MR cholangiography coupled with MR portography imaging study. *Hepatology* 2003; **37**: 1302-1308 [PMID: 12774008 DOI: 10.1053/jhep.2003.50232]
- 12 **Sezgin O**, Oğuz D, Altıntaş E, Sarıtaş U, Sahin B. Endoscopic management of biliary obstruction caused by cavernous transformation of the portal vein. *Gastrointest Endosc* 2003; **58**: 602-608 [PMID: 14520303]
- 13 **Khare R**, Sikora SS, Srikanth G, Choudhuri G, Saraswat VA, Kumar A, Saxena R, Kapoor VK. Extrahepatic portal venous obstruction and obstructive jaundice: approach to management. *J Gastroenterol Hepatol* 2005; **20**: 56-61 [PMID: 15610447 DOI: 10.1111/j.1440-1746.2004.03528.x]
- 14 **Belhadjbrik N**, Kchaou-Ouakaa A, Kharat J, Elloumi H, Gargouri D, Kochlef A, Ghorbel A. [Biliary abnormalities associated to portal Cavernoma. About 17 cases]. *Tunis Med* 2006; **84**: 291-295 [PMID: 16915779]
- 15 **Chevallier P**, Denys A, Novellas S, Schmidt S, Schnyder P, Bruneton JN. Magnetic resonance cholangiography features of biliary abnormalities due to cavernous transformation of the portal vein. *Clin Imaging* 2006; **30**: 190-194 [PMID: 16632155 DOI: 10.1016/j.clinimag.2005.12.028]
- 16 **Dhiman RK**, Behera A, Chawla YK, Dilawari JB, Suri S. Portal hypertensive biliopathy. *Gut* 2007; **56**: 1001-1008 [PMID: 17170017 DOI: 10.1136/gut.2006.103606]
- 17 **Vibert E**, Azoulay D, Aloia T, Pascal G, Veilhan LA, Adam R, Samuel D, Castaing D. Therapeutic strategies in symptomatic portal biliopathy. *Ann Surg* 2007; **246**: 97-104 [PMID: 17592297 DOI: 10.1097/SLA.0b013e318070cada]
- 18 **Oo YH**, Olliff S, Haydon G, Thorburn D. Symptomatic portal biliopathy: a single centre experience from the UK. *Eur J Gastroenterol Hepatol* 2009; **21**: 206-213 [PMID: 19212209 DOI: 10.1097/MEG.0b013e318060ee8]
- 19 **Llop E**, de Juan C, Seijo S, García-Criado A, Abalde JG, Bosch J, García-Pagán JC. Portal cholangiopathy: radiological classification and natural history. *Gut* 2011; **60**: 853-860 [PMID: 21270119 DOI: 10.1136/gut.2010.230201]
- 20 **Agarwal AK**, Sharma D, Singh S, Agarwal S, Girish SP. Portal biliopathy: a study of 39 surgically treated patients. *HPB (Oxford)* 2011; **13**: 33-39 [PMID: 21159101 DOI: 10.1111/j.1477-2574.2010.00232.x]
- 21 **Aguirre DA**, Farhadi FA, Rattansingh A, Jhaveri KS. Portal biliopathy: imaging manifestations on multidetector computed tomography and magnetic resonance imaging. *Clin Imaging* 2012; **36**: 126-134 [PMID: 22370133 DOI: 10.1016/j.clinimag.2011.07.001]
- 22 **Aguilar-Olivos NE**, de León-Monterroso JL, Avila-Escobedo L, López-Méndez E. [Therapeutic options for portal hypertensive biliopathy: case series and literature review]. *Cir Cir* 2014; **82**: 680-685 [PMID: 25393868]
- 23 **Walser EM**, Runyan BR, Heckman MG, Bridges MD, Willingham DL, Paz-Fumagalli R, Nguyen JH. Extrahepatic portal biliopathy: proposed etiology on the basis of anatomic and clinical features. *Radiology* 2011; **258**: 146-153 [PMID: 21045178 DOI: 10.1148/radiol.10090923]
- 24 **Rosenthal MD**, White GH, Stephen MS, Gallagher JJ, Sandroussi C. Vascular biliopathy as a cause of common bile duct obstruction successfully treated by mesocaval shunt and endoscopic retrograde cholangiopancreatography biliary stent placement. *Vascular* 2008; **16**: 356-358 [PMID: 19344595]
- 25 **Varma V**, Behera A, Kaman L, Chattopadhyay S, Nundy S. Surgical management of portal cavernoma cholangiopathy. *J Clin Exp Hepatol* 2014; **4**: S77-S84 [PMID: 25755599 DOI: 10.1016/j.jceh.2013.07.005]
- 26 **Ramesh Babu CS**, Sharma M. Biliary tract anatomy and its relationship with venous drainage. *J Clin Exp Hepatol* 2014; **4**: S18-S26 [PMID: 25755590 DOI: 10.1016/j.jceh.2013.05.002]
- 27 **Northover JM**, Terblanche J. A new look at the arterial supply of the bile duct in man and its surgical implications. *Br J Surg* 1979; **66**: 379-384
- 28 **Sharma M**, Rameshbabu CS. Collateral pathways in portal hypertension. *J Clin Exp Hepatol* 2012; **2**: 338-352 [PMID: 25755456 DOI: 10.1016/j.jceh.2012.08.001]
- 29 **Nunoi H**, Hirooka M, Ochi H, Koizumi Y, Tokumoto Y, Abe M, Tada F, Ikeda Y, Matsuura B, Tanaka H, Tsuda T, Mochizuki T, Hiasa Y, Onji M. Portal biliopathy diagnosed using color Doppler and contrast-enhanced ultrasound. *Intern Med* 2013; **52**: 1055-1059 [PMID: 23676590]
- 30 **Puri P**. Pathogenesis of Portal Cavernoma Cholangiopathy: Is it Compression by Collaterals or Ischemic Injury to Bile Ducts During Portal Vein Thrombosis? *J Clin Exp Hepatol* 2014; **4**: S27-S33 [PMID: 25755592 DOI: 10.1016/j.jceh.2013.05.015]
- 31 **Choudhary NS**, Puri R, Sud R. Paracholedochal varices causing biliopathy in a case of portal vein thrombosis. *Endosc Ultrasound* 2015; **4**: 76-77 [PMID: 25789291 DOI: 10.4103/2303-9027.151372]
- 32 **Liu Y**, Hou B, Chen R, Jin H, Zhong X, Ye W, Liang C. Biliary collateral veins and associated biliary abnormalities of portal hypertensive biliopathy in patients with cavernous transformation of portal vein. *Clin Imaging* 2015; **39**: 841-844 [PMID: 26004045 DOI: 10.1016/j.clinimag.2015.04.018]
- 33 **Bhatia V**, Jain AK, Sarin SK. Choledocholithiasis associated with portal biliopathy in patients with extrahepatic portal vein obstruction: management with endoscopic sphincterotomy. *Gastrointest Endosc* 1995; **42**: 178-181 [PMID: 7590059]
- 34 **Duseja A**. Portal cavernoma cholangiopathy-clinical characteristics. *J Clin Exp Hepatol* 2014; **4**: S34-S36 [PMID: 25755593 DOI: 10.1016/j.jceh.2013.05.014]
- 35 **Takamatsu M**, Furutake M, Hisa T, Ueda M. Obstructive jaundice caused by a portal cavernoma. *Jpn J Radiol* 2010; **28**: 754-758 [PMID: 21191741 DOI: 10.1007/s11604-010-0480-7]
- 36 **Le Roy B**, Gelli M, Serji B, Memeo R, Vibert E. Portal biliopathy as a complication of extrahepatic portal hypertension: etiology, presentation and management. *J Visc Surg* 2015; **152**: 161-166 [PMID: 26025414 DOI: 10.1016/j.jvisurg.2015.04.003]
- 37 **Guerrero Hernández I**, Weimersheimer Sandoval M, López

- Méndez E, Hernández Calleros J, Tapia AR, Uribe M. Biliary stricture caused by portal biliopathy: case report and literature review. *Ann Hepatol* 2005; **4**: 286-288 [PMID: 16432497]
- 38 Schlansky B, Kaufman JA, Bakis G, Naugler WE. Portal Biliopathy Causing Recurrent Biliary Obstruction and Hemobilia. *ACG Case Rep J* 2013; **1**: 44-46 [PMID: 26157818 DOI: 10.14309/crj.2013.16]
- 39 Kumar M, Saraswat VA. Natural history of portal cavernoma cholangiopathy. *J Clin Exp Hepatol* 2014; **4**: S62-S66 [PMID: 25755597 DOI: 10.1016/j.jceh.2013.08.003]
- 40 Gulati G, Pawa S, Chowdhary V, Kumar N, Mittal SK. Colour Doppler flow imaging findings in portal biliopathy. *Trop Gastroenterol* 2003; **24**: 116-119 [PMID: 14978982]
- 41 Ozkavukcu E, Erden A, Erden I. Imaging features of portal biliopathy: frequency of involvement patterns with emphasis on MRCP. *Eur J Radiol* 2009; **71**: 129-134 [PMID: 18448295 DOI: 10.1016/j.ejrad.2008.03.007]
- 42 Shin SM, Kim S, Lee JW, Kim CW, Lee TH, Lee SH, Kim GH. Biliary abnormalities associated with portal biliopathy: evaluation on MR cholangiography. *AJR Am J Roentgenol* 2007; **188**: W341-W347 [PMID: 17377002 DOI: 10.2214/AJR.05.1649]
- 43 Baskan O, Erol C, Sahingoz Y. Portal biliopathy, magnetic resonance imaging and magnetic resonance cholangiopancreatography findings: a case series. *Gastroenterol Rep (Oxf)* 2016; **4**: 68-72 [PMID: 25216728 DOI: 10.1093/gastro/gou062]
- 44 Umphress JL, Pecha RE, Urayama S. Biliary stricture caused by portal biliopathy: diagnosis by EUS with Doppler US. *Gastrointest Endosc* 2004; **60**: 1021-1024 [PMID: 15605028]
- 45 Takagi T, Irisawa A, Shibukawa G, Hikichi T, Obara K, Ohira H. Intraductal ultrasonographic anatomy of biliary varices in patients with portal hypertension. *Endosc Ultrasound* 2015; **4**: 44-51 [PMID: 25789284 DOI: 10.4103/2303-9027.151346]
- 46 Ramchandani M, Nageshwar Reddy D, Lakhtakia S, Gupta R, Tandan M, Rao GV. Role of single-operator per-oral cholangioscopy and intraductal US in assessment of portal biliopathy (with videos). *Gastrointest Endosc* 2014; **79**: 1015-1019 [PMID: 24713306 DOI: 10.1016/j.gie.2014.01.042]
- 47 Mangla V, Singla V, Pal S. Portal biliopathy: diagnosis by endosonography. *Clin Gastroenterol Hepatol* 2012; **10**: A34 [PMID: 21888882 DOI: 10.1016/j.cgh.2011.08.023]
- 48 Sharma M, Pathak A. Perforators of common bile duct wall in portal hypertensive biliopathy (with videos). *Gastrointest Endosc* 2009; **70**: 1041-1043 [PMID: 19631938 DOI: 10.1016/j.gie.2009.03.040]
- 49 Chawla Y, Dhiman RK. Portal biliopathy: emerging management problems. *Trop Gastroenterol* 2003; **24**: 165-166 [PMID: 15164525]
- 50 Cellich PP, Crawford M, Kaffes AJ, Sandroussi C. Portal biliopathy: multidisciplinary management and outcomes of treatment. *ANZ J Surg* 2013; **85**: 561-566 [PMID: 24237891 DOI: 10.1111/ans.12436]
- 51 Yattoo GN, Khuroo MS. Endoscopic management of obstructive jaundice due to portal cavernoma. *Endoscopy* 1996; **28**: 521 [PMID: 8886642 DOI: 10.1055/s-2007-1005535]
- 52 Tyagi P, Puri AS, Sharma BC. Balloon sweep in portal biliopathy. *Gastrointest Endosc* 2010; **71**: 885-886; author reply 886 [PMID: 20363438 DOI: 10.1016/j.gie.2009.08.014]
- 53 Mutignani M, Shah SK, Bruni A, Perri V, Costamagna G. Endoscopic treatment of extrahepatic bile duct strictures in patients with portal biliopathy carries a high risk of haemobilia: report of 3 cases. *Dig Liver Dis* 2002; **34**: 587-591 [PMID: 12502216]
- 54 Goenka MK, Harwani Y, Rai V, Goenka U. Fully covered self-expandable metal biliary stent for hemobilia caused by portal biliopathy. *Gastrointest Endosc* 2014; **80**: 1175 [PMID: 24818548 DOI: 10.1016/j.gie.2014.03.029]
- 55 Layec S, D'Halluin PN, Pagenault M, Bretagne JF. Massive hemobilia during extraction of a covered self-expandable metal stent in a patient with portal hypertensive biliopathy. *Gastrointest Endosc* 2009; **70**: 555-556; discussion 556 [PMID: 19595317 DOI: 10.1016/j.gie.2009.04.051]
- 56 Sharma M, Ponnusamy RP. Is balloon sweeping detrimental in portal biliopathy? A report of 3 cases. *Gastrointest Endosc* 2009; **70**: 171-173 [PMID: 19409559 DOI: 10.1016/j.gie.2008.11.002]
- 57 Sharma M, Babu CS, Dhiman RK, Chawla Y. Induced hypotension in the management of acute hemobilia during therapeutic ERCP in a patient with portal biliopathy (with videos). *Gastrointest Endosc* 2010; **72**: 1317-1319 [PMID: 20561622 DOI: 10.1016/j.gie.2010.04.020]
- 58 Bhatia P, John S, Kalhan S, Khetan M. Primary laparoscopic cholecystectomy in patients with portal cavernoma and non-obstructive portal biliopathy: Two case reports. *J Minim Access Surg* 2014; **10**: 161-162 [PMID: 25013336 DOI: 10.4103/0972-9941.134885]
- 59 Koshy A. "Medical treatment of portal biliopathy". *J Clin Gastroenterol* 2006; **40**: 453-454 [PMID: 16721234]
- 60 Siddiqui MN. Bile duct obstruction due to portal biliopathy in extrahepatic portal hypertension: surgical management. *Br J Surg* 1999; **86**: 138 [PMID: 10027383 DOI: 10.1046/j.1365-2168.1999.0985k.x]
- 61 Senzolo M, Tibbals J, Cholongitas E, Triantos CK, Burroughs AK, Patch D. Transjugular intrahepatic portosystemic shunt for portal vein thrombosis with and without cavernous transformation. *Aliment Pharmacol Ther* 2006; **23**: 767-775 [PMID: 16556179 DOI: 10.1111/j.1365-2036.2006.02820.x]
- 62 Gupta V, Chandra A. Portal biliopathy: is splenectomy with devascularization really effective? *HPB (Oxford)* 2013; **15**: 559 [PMID: 23750497 DOI: 10.1111/j.1477-2574.2012.00606.x]
- 63 Chaudhary A, Dhar P, Sarin SK, Sachdev A, Agarwal AK, Vij JC, Broor SL. Bile duct obstruction due to portal biliopathy in extrahepatic portal hypertension: surgical management. *Br J Surg* 1998; **85**: 326-329 [PMID: 9529484 DOI: 10.1046/j.1365-2168.1998.00591.x]
- 64 Khuroo MS, Al-Suhabani H, Al-Sebayel M, Al-Ashgar H, Dahab S, Khan MQ, Khalaf HA. Budd-Chiari syndrome: long-term effect on outcome with transjugular intrahepatic portosystemic shunt. *J Gastroenterol Hepatol* 2005; **20**: 1494-1502 [PMID: 16174064 DOI: 10.1111/j.1440-1746.2005.03878.x]
- 65 D'Souza MA, Desai D, Joshi A, Abraham P, Shah SR. Bile duct stricture due to caused by portal biliopathy: Treatment with one-stage portal-systemic shunt and biliary bypass. *Indian J Gastroenterol* 2009; **28**: 35-37 [PMID: 19529903 DOI: 10.1007/s12664-009-0010-7]
- 66 Gupta S, Singhal A, Goyal N, Vij V, Wadhawan M. Portal biliopathy treated with living-donor liver transplant: index case. *Exp Clin Transplant* 2011; **9**: 145-149 [PMID: 21453234]
- 67 Filipponi F, Urbani L, Catalano G, Iaria G, Biancifiore G, Cioni R, Campatelli A, Mosca F, Campani D, Romagnoli P. Portal biliopathy treated by liver transplantation. *Transplantation* 2004; **77**: 326-327 [PMID: 14743009 DOI: 10.1097/01.TP.0000101795.29250.10]

P- Reviewer: Gupta V, Nundy S, Tarazov PG S- Editor: Yu J

L- Editor: A E- Editor: Wang CH





Published by **Baishideng Publishing Group Inc**

8226 Regency Drive, Pleasanton, CA 94588, USA

Telephone: +1-925-223-8242

Fax: +1-925-223-8243

E-mail: [bpgoffice@wjgnet.com](mailto:bpgoffice@wjgnet.com)

Help Desk: <http://www.wjgnet.com/esps/helpdesk.aspx>

<http://www.wjgnet.com>



ISSN 1007-9327

