

Langerhans cell histiocytosis masquerading as acute appendicitis: Case report and review

Mohammad M Karimzada, Michele N Matthews, Samuel W French, Daniel DeUgarte, Dennis Y Kim

Mohammad M Karimzada, Daniel DeUgarte, Dennis Y Kim, Department of Surgery, Harbor-UCLA Medical Center, Torrance, CA 90502, United States

Michele N Matthews, Samuel W French, Department of Pathology, Harbor-UCLA Medical Center, Torrance, CA 90053, United States

Author contributions: Karimzada MM, Matthews MN, French SW, DeUgarte D and Kim DY designed the case study and review; Matthews MN and French SW performed microscopic and immunohistochemical evaluations of surgical specimens; DeUgarte D provided descriptive impressions of differential diagnosis and intraoperative findings; Karimzada MM and Matthews MN wrote the paper; final revision approved by Kim DY.

Institutional review board statement: Case study was prepared at Harbor-UCLA Medical Center in affiliation with the Institutional Review Board at the LA BioMed Research Institute in Torrance, CA.

Informed consent statement: Patient consented to use of medical information pertaining to this case for teaching and research purposes.

Conflict-of-interest statement: The authors have no conflicts of interest to disclose regarding this case report and review.

Open-Access: This article is an open-access article which was selected by an in-house editor and fully peer-reviewed by external reviewers. It is distributed in accordance with the Creative Commons Attribution Non Commercial (CC BY-NC 4.0) license, which permits others to distribute, remix, adapt, build upon this work non-commercially, and license their derivative works on different terms, provided the original work is properly cited and the use is non-commercial. See: <http://creativecommons.org/licenses/by-nc/4.0/>

Manuscript source: Invited manuscript

Correspondence to: Dennis Y Kim, Assistant Professor of Surgery, Department of Surgery, Harbor-UCLA Medical Center, 1000 West Carson Street, Torrance, CA 90502, United States. dekim@dhs.lacounty.gov

Telephone: +1-310-2222700

Fax: +1-310-5331841

Received: April 29, 2016

Peer-review started: May 3, 2016

First decision: May 17, 2016

Revised: December 6, 2016

Accepted: December 27, 2016

Article in press: December 28, 2016

Published online: March 16, 2017

Abstract

Langerhans cell histiocytosis (LCH) is a rare syndrome characterized by unifocal, multifocal unisystem, or disseminated/multi-system disease that commonly involves the bone, skin, lymph nodes, pituitary, or sometimes lung (almost exclusively in smokers) causing a variety of symptoms from rashes and bone lesions to diabetes insipidus or pulmonary infiltrates. We present a previously unreported case of gastrointestinal LCH as well as a novel characteristic lesion affecting the colon of a young woman who presented with signs and symptoms mimicking acute on chronic appendicitis. Immunohistochemical analysis of appendectomy specimen and nodular specimens on colonoscopy demonstrated S-100, CD1a, and langerin reactivity. The patient underwent systemic chemotherapy with cytarabine and demonstrated excellent response to therapy.

Key words: Langerhans cell histiocytosis; Adult histiocytosis; Appendicitis; Gastrointestinal histiocytosis; Right lower quadrant pain

© **The Author(s) 2017.** Published by Baishideng Publishing Group Inc. All rights reserved.

Core tip: Langerhans cell histiocytosis (LCH) of the adult gastrointestinal tract can affect the appendix and present as mild inflammatory findings on exploratory

laparoscopy, or white-yellowish nodularities and polyps on lower endoscopy. Immunohistochemical staining of surgical specimens for CD1a, S-100, and langerin should be considered in gastrointestinal lesions that demonstrate histology concerning for histiocytosis in an attempt to decrease morbidity related to undiagnosed LCH.

Karimzada MM, Matthews MN, French SW, DeUgarte D, Kim DY. Langerhans cell histiocytosis masquerading as acute appendicitis: Case report and review. *World J Gastrointest Endosc* 2017; 9(3): 139-144 Available from: URL: <http://www.wjgnet.com/1948-5190/full/v9/i3/139.htm> DOI: <http://dx.doi.org/10.4253/wjge.v9.i3.139>

INTRODUCTION

Langerhans cell histiocytosis (LCH) is a rare syndrome characterized by unifocal, multifocal unisystem, or disseminated/multi-system disease that commonly involves the bone, skin, lymph nodes, pituitary, and sometimes lungs (almost exclusively in smokers) causing a variety of symptoms from rashes and bone lesions to diabetes insipidus or pulmonary infiltrates. The liver, spleen, or bone marrow may also be involved and are considered "risk organs" that signify a less favorable prognosis^[1,2]. The gastrointestinal tract is rarely involved, and when it is present, it usually affects pediatric patients with severe multisystem disease^[3]. LCH typically affects children under 10 years of age with European ancestry. Peak incidence is under 2 years of age with a 2:1 predilection for males^[1,2].

There are case reports of patients presenting up to the eighth decade of life and some evidence to suggest a higher incidence in patients of Hispanic descent when compared to whites^[1,3-5]. An incidence of 1 out of 200000 is commonly cited for the pediatric population compared to 1-2 per 1 million in the adult population. Diagnosis is typically confirmed by CD1a and S-100 reactivity on immunohistochemical staining of biopsied lesions and diagnosis is typically confirmed by the finding of Birbeck granules on electron microscopy or langerin reactivity on histology^[1]. Treatment consists of supportive care, surgery, chemotherapy (especially in multisystem involvement), radiotherapy, and sometimes hormone replacement therapy in cases of pituitary dysfunction. Recent research supports the notion that LCH is more align with a neoplastic process rather than a reactive one, with a proportion of lesions presenting with *BRAF* or *MAP2K1* mutations. Such mutations may be of some value for risk stratification and prognostication, and immunotherapy with *BRAF* inhibitors have shown some promise in treatment^[1,6]. Five-year mortality runs up to 20% with a greater risk of mortality in younger patients^[2-4].

CASE REPORT

A 20-year-old G1P1 Hispanic female in previously good

health with a history of pyelonephritis during pregnancy and eczema presented with 3 d of sharp, intermittent right lower quadrant pain that radiates towards the midline with movement. She vomited non-bloody, non-bilious emesis three times the day before presentation after eating and presented to our emergency department after having acute appendicitis ruled out at an outside hospital three days prior. Her pain responds to ibuprofen. She denies fevers, chills, diarrhea, urinary urgency or hesitancy, vaginal discharge or bleeding, or trauma. She engages in monogamous unprotected sex with a male partner and endorses mild dysuria. She denies alcohol, tobacco, or other drug use. She experienced a similar episode of pain a couple months prior to presentation. Her only medications are intramuscular depo provera for birth control and ibuprofen for her abdominal pain. She is afebrile with vitals within normal limits and body mass index of 19. Abdominal examination revealed present bowel sounds, mild tenderness to the right of midline near the right lower quadrant without guarding, McBurney's point tenderness or Murphy's sign. The remainder of the exam, including a pelvic exam, was unremarkable. Abdominal and pelvic causes of pain including acute appendicitis, nephrolithiasis, pregnancy, tuboovarian abscess, ovarian torsion, small bowel obstruction, functional intestinal obstruction, urinary tract infection, sexually transmitted infection, muscle strain were considered. Transvaginal and limited abdominal ultrasound performed at the outside hospital demonstrated small bilateral follicular cysts and no evidence of appendicitis or other tuboovarian processes. Urine studies were negative for bacteriuria, leukocyte esterase, nitrite, and both gonococcal and chlamydial RNA. Urine cultures acquired at that time were eventually negative for growth. Urine beta-hCG was negative. Wet mount unremarkable. Abdominal X-ray was unremarkable with nonspecific bowel gas pattern. At this point her signs/symptoms and lab testing were unremarkable for acute pathology other than perhaps abdominal pain secondary to follicular cysts. She was discharged in ambulatory, stable condition with instructions to present to pediatric acute follow-up clinic in 2-3 d and pain control with ibuprofen.

The next day she presented to the pediatric acute follow up clinic with severe and constant right lower quadrant pain that was no longer responsive to ibuprofen, and is exacerbated with any ambulation or lifting her child. She is afebrile with normal vitals. Abdominal exam is remarkable for right lower quadrant tenderness to palpation, guarding, and Rovsing's sign with no rebound tenderness. The patient also clarifies that her right lower quadrant pain has been intermittent and ongoing for the last four months. Hemoglobin (13.1 mg/dL), white blood count (7100/ μ L), platelets (260000/ μ L), fibrinogen (303 mg/dL) were within normal with a blood differential notable for peripheral eosinophilia (18% eosinophils with 1300/ μ L absolute count). Inflammatory markers C-reactive protein (< 0.02 mg/dL) and erythrocyte sedimentation rate (8 mm/h) were normal. Amylase

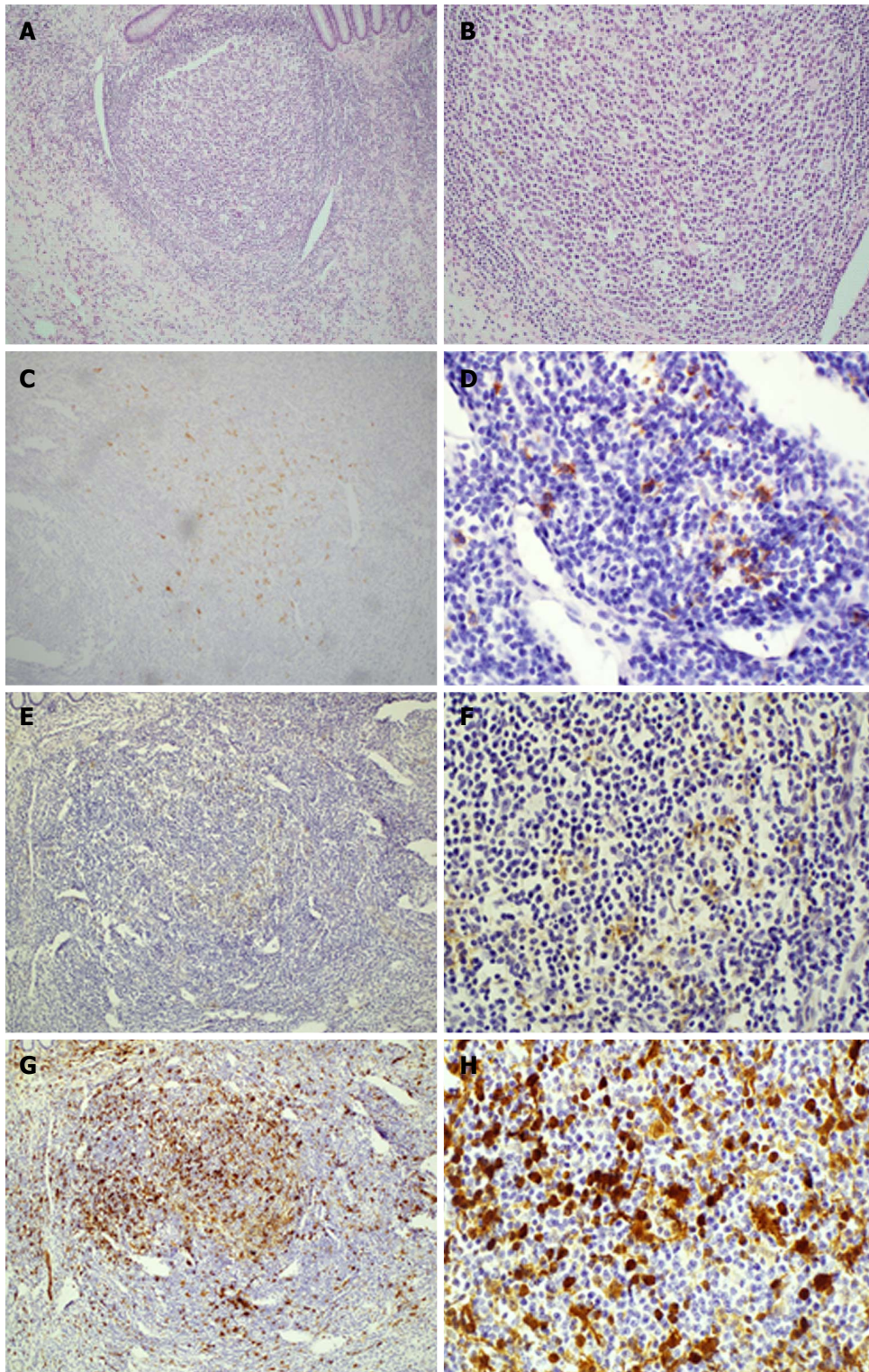


Figure 1 Histology and immunohistochemical stains of appendix confirming diagnosis of Langerhans cell histiocytosis. The appendix shows an overgrowth of histiocytes in the lymphoid aggregates at 10 × (A) and 40 × (B) magnifications of H and E stains; while the electron microscopy images did not show Birbeck bodies due to previous fixation, the Langerin stain (CD207) demonstrates their presence in the areas of concern at 10 × (C) and 40 × (D) magnification. CD1a stains at 10 × (E) and 40 × (F); S-100 stains at 10 × (G) and 40 × (H).

(82 U/L) and lipase (24 U/L) were within normal limits and pelvic as well as right upper quadrant ultrasounds both unremarkable for acute pathology. CT scan of the abdomen and pelvis is unremarkable, particularly demonstrating an air-filled appendix within normal limits

and no fat stranding. She is admitted to the pediatrics ward and a gynecology consult determined that a gynecological problem is unlikely. Pediatric surgery was consulted and a diagnostic laparoscopy found normal liver, intestines, uterus, bilateral ovaries and fallopian tubes.

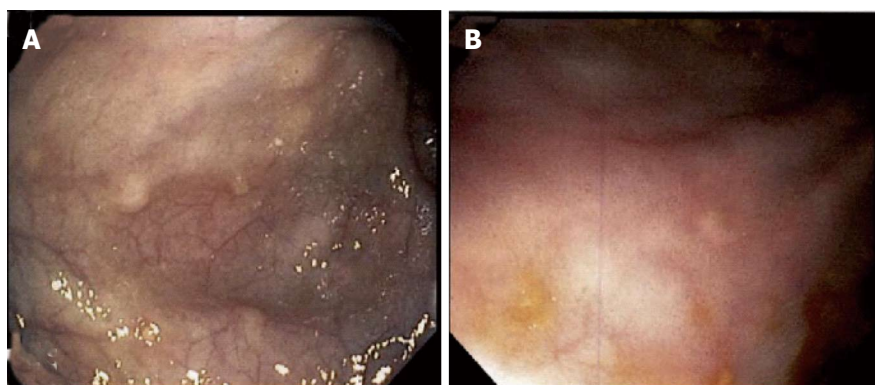


Figure 2 Gross appearance of colonic lesions on endoscopy. Wide (A) and close-up (B) views of approximately 5 mm whitish-yellowish polypoid lesions found throughout the colon. Biopsy and immunohistochemical staining demonstrated CD1a, S-100, and langerin reactivity confirming langerhans cell histiocytosis-related lesions (see Figure 3).

There were anomalous adhesions of the cecum to the anterior abdominal wall and the appendix was mildly injected with some area of thickening and induration suspicious for chronic appendicitis, and thus resected.

Her immediate post-op period was unremarkable and she was discharged with appropriate incisional tenderness on post-op day two. She presented to the emergency department on post-op day five complaining of right lower quadrant pain similar to that prior to surgery. She was readmitted and further imaging and workup including pelvic ultrasound as well as MRI of the brain and spine, and failed to show a cause of her pain. Her pain was managed with non-steroidal anti-inflammatory drugs, intravenous morphine, and Norco while in hospital. Surgical pathology of her appendix was grossly unremarkable, without ulceration or inflammation, yet demonstrated histiocytes in lymphoid aggregates on H and E stain and suspicious for LCH. This was confirmed with S-100, CD1a, and CD207 reactivity (Figure 1). Upper and lower endoscopy demonstrated whitish-yellowish polypoid nodules less than 5 mm in size at the luminal surface of the cecum, transverse, and descending colon (Figure 2). Microscopic evaluation demonstrated similar morphology to the appendix H and E, and immunohistochemical analysis demonstrated S-100, CD1a, CD207 (langerin) reactivity of these nodules (Figure 3) whereas biopsy samples of the esophagus, stomach, duodenum, and rectum failed to show histiocytosis. Bone marrow aspirates, bone scan, and MRI brain were negative for bone marrow, skeletal, and pituitary involvement, respectively.

DISCUSSION

Given the extensive involvement of her colon, she was diagnosed with unisystem, multifocal LCH that solely involves the colon. A port-a-cath was placed and the patient was started on cytarabine chemotherapy at 100 mg/m² per day for 5 d. The patient was to undergo 12 cycles, each one month apart, over the course of 12 mo.

At the time of writing this report, the patient is status post six cycles of cytarabine with marked clinical

improvement. Follow-up upper and lower endoscopies with biopsy after her third cycle of chemotherapy demonstrated decreased disease burden with residual foci of histiocytosis present in colon biopsies (particularly the ascending colon) and her abdominal pain completely resolved sometime after her fourth cycle of chemotherapy.

In general, gastrointestinal involvement is rare in both child and adult forms of LCH and there are few case reports in the literature documenting gastrointestinal disease in adult patients with LCH. Gastrointestinal involvement in childhood onset LCH typically occurs in systemic LCH and thus forewarns of a poor prognosis. In contrast, adult patients who are diagnosed with unisystem disease such as in this case are thought to have an excellent prognosis upwards of 90% survival at five years^[6]. Adult patients who present with enteric-related signs and symptoms seem to have a predilection towards oral lesions such as palatal ulcers, and there is a small case series that demonstrates 12 patients with incidentally found LCH lesions on endoscopy that predominantly affected the colon (with 2 cases of cecal involvement) and described as polyps or ulcerative lesions^[3,4,6,7]. There seem to be even fewer case reports of small bowel involvement^[8,9]. There are none that report an acute presentation of right lower quadrant pain that presents with features similar to acute appendicitis^[3,4,10].

The patient presented with a story concerning for acute on chronic appendicitis. Exploratory laparotomy was performed under this suspicion, and although the appendix was a focus of disease, the gross findings of mild inflammation could have possibly been dismissed as normal variation of anatomy. Additionally, she is a young Hispanic woman in contrast to the stereotypical infant/toddler male of European descent. It is worth mentioning that there is some evidence to suggest this notion may have to be dismissed in favor of one that denotes Hispanics and those who live in crowded counties or areas with a low education level may be at higher risk of LCH^[1,3,5,11].

Only after tissue analysis demonstrated histological

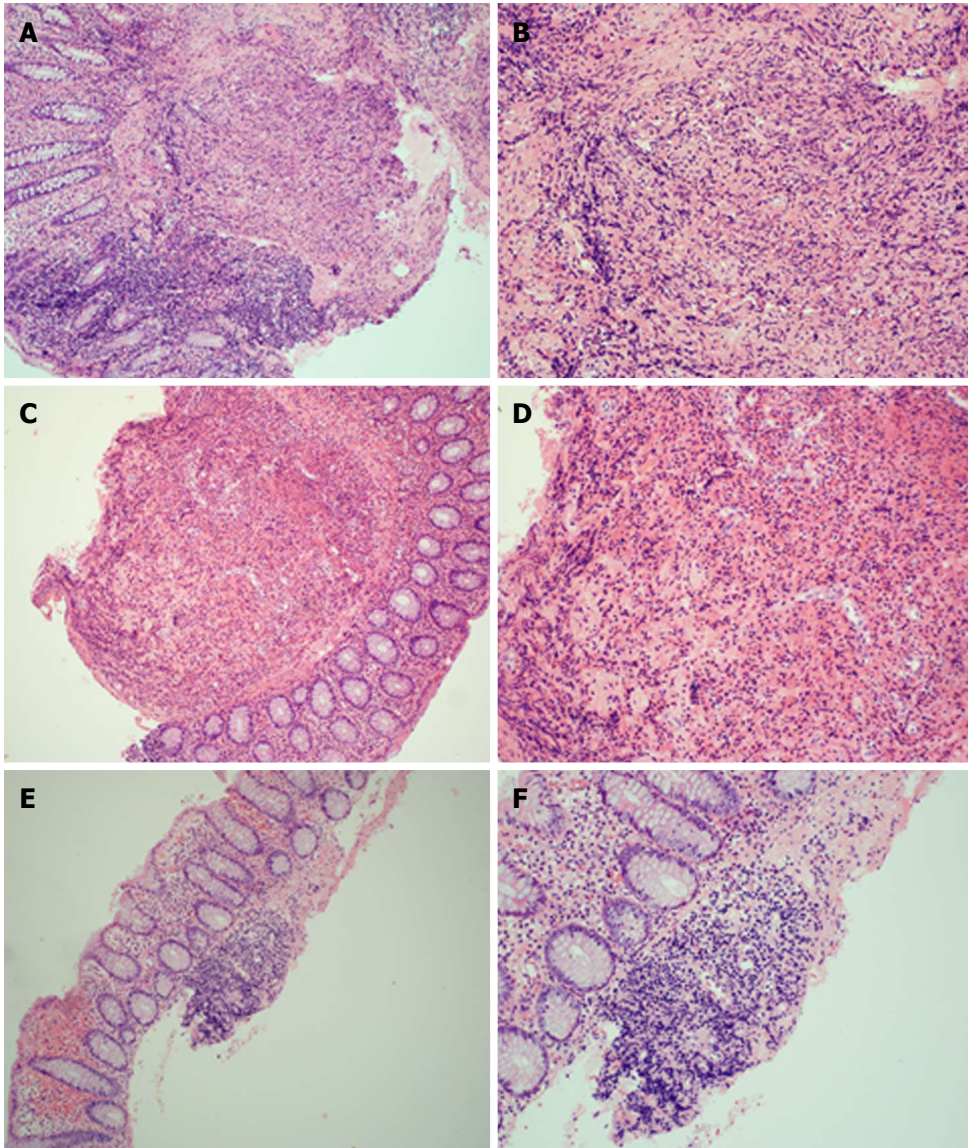


Figure 3 Histology of colonic samples consistent with Langerhans cell histiocytosis. Grossly, the colon biopsies were each received as small fragments of tissue, where no tissue defects could be determined due to the size of the specimens received. Microscopically, the cecum (A and B, 10 × and 20 ×, respectively), descending colon (C and D, 10 × and 40 ×, respectively), and transverse colon (E and F, 10 × and 20 ×, respectively) each show nodules that are similar in morphology to the appendix and (although not shown here) share the same staining patterns (CD1a, S-100, and langerin reactivity). Again, electron microscopy was unsuccessful in highlighting the Birbeck bodies due to formalin fixation.

findings suspicious for LCH, was the diagnosis entertained, and further testing performed. It is typical for surgeons to routinely send appendectomy specimens for analysis, and some studies have stressed the importance of routine histological examination of appendectomy specimens in order to identify uncommon etiologies of appendiceal disease such as neoplasms or various infectious processes, however there is some evidence to suggest otherwise^[3,4]. In this case, had a surgical specimen not been taken, the time to diagnosis would have likely been prolonged, leading to further patient discomfort, lack of appropriate treatment, and possible loss to follow up due to a combination of these two.

Her persistent right lower quadrant pain was not relieved by the appendectomy, but spontaneously

resolved after a considerable amount of chemotherapy. Lacking evidence of musculoskeletal, neurological, or other abdominopelvic pathology, it may be reasonable to suggest that her pain was caused by the histiocytosis of her colon that seems to have affected the entirety of her colon.

Gastrointestinal histiocytosis in the adult may present with an appendicitis-like syndrome that may be harbinger of more extensive colonic involvement. Additionally, whitish-yellowish polypoid lesions on endoscopy should involve a differential diagnosis of gastrointestinal histiocytosis. In total, a combination of surgical specimens and endoscopy are crucial in diagnosing and evaluating the extent of gastrointestinal involvement of LCH in adults.

COMMENTS

Case characteristics

Three days of sharp, intermittent right lower quadrant pain exacerbated by movement accompanied by non-bloody, non-bilious vomiting.

Clinical diagnosis

Multifocal gastrointestinal adult langerhans cell histiocytosis (LCH).

Differential diagnosis

Causes of right lower quadrant pain accompanied by nausea in reproductive age women include acute appendicitis, nephrolithiasis, pregnancy, tuboovarian abscess, ovarian torsion, small bowel obstruction, functional intestinal obstruction, urinary tract infection, sexually transmitted infection, muscle strain.

Laboratory diagnosis

Labs notable for peripheral eosinophilia.

Imaging diagnosis

Unremarkable brain, skeletal, abdominal, and pelvic imaging except for subcentimeter polyps found throughout colon on lower endoscopy.

Pathological diagnosis

LCH of the appendix and colon confirmed by S-100, CD1a, and CD207 reactivity.

Treatment

Twelve cycles of cytarabine therapy at 100 mg/m² per day for five days with cycles one month apart.

Related reports

Adult LCH is a rare entity, and there are few reports of bowel involvement that are either asymptomatic and found incidentally on endoscopy or a single report of small bowel hemorrhage secondary to the disease; importantly, there are no reports that presented like this case.

Experiences and lessons

Surgical biopsy is an invaluable practice that can identify uncommon etiologies of appendicitis and may be of great value in guiding any further treatment; in the same vein, a practitioner must entertain common and rare diagnoses for a complete differential.

Peer-review

The authors have done a very good job of writing up this fascinating case.

REFERENCES

- 1 **Harmon CM**, Brown N. Langerhans Cell Histiocytosis: A Clinicopathologic Review and Molecular Pathogenetic Update. *Arch Pathol Lab Med* 2015; **139**: 1211-1214 [PMID: 26414464 DOI: 10.5858/arpa.2015-0199-RA]
- 2 **Lipton JM**. Langerhans Cell Histiocytosis. Merck Manual database online. [accessed 2016 Apr 18]. Whitehouse Station, NJ: Merck Sharp & Dohme Corp, 2013
- 3 **Akbulut S**, Tas M, Sogutcu N, Arikanoğlu Z, Basbug M, Ulku A, Semur H, Yagmur Y. Unusual histopathological findings in appendectomy specimens: a retrospective analysis and literature review. *World J Gastroenterol* 2011; **17**: 1961-1970 [PMID: 21528073 DOI: 10.3748/wjg.v17.i15.1961]
- 4 **Swank HA**, Eshuis EJ, Ubbink DT, Bemelman WA. Is routine histopathological examination of appendectomy specimens useful? A systematic review of the literature. *Colorectal Dis* 2011; **13**: 1214-1221 [PMID: 20958910 DOI: 10.1111/j.1463-1318.2010.02457.x]
- 5 **Roeb E**, Etschmann B, Gattenlöhner S. Is it always Crohn's disease in a patient with perianal fistulae and skip lesions in the colon? *Gastroenterology* 2012; **143**: e7-e8 [PMID: 22640732 DOI: 10.1053/j.gastro.2011.12.013]
- 6 **Aricò M**, Girschikofsky M, Gènéreau T, Klersy C, McClain K, Grois N, Emile JF, Lukina E, De Juli E, Danesino C. Langerhans cell histiocytosis in adults. Report from the International Registry of the Histiocyte Society. *Eur J Cancer* 2003; **39**: 2341-2348 [PMID: 14556926 DOI: 10.1016/S0959-8049(03)00672-5]
- 7 **Singhi AD**, Montgomery EA. Gastrointestinal tract langerhans cell histiocytosis: A clinicopathologic study of 12 patients. *Am J Surg Pathol* 2011; **35**: 305-310 [PMID: 21263252 DOI: 10.1097/PAS.0b013e31820654e4]
- 8 **Pops MA**, Campbell T. Gastrointestinal bleeding from ileal ulcerations in histiocytosis X. *Arch Intern Med* 1968; **122**: 271-272 [PMID: 5302326 DOI: 10.1001/archinte.1968.00300080079015]
- 9 **Lee-Elliott C**, Alexander J, Gould A, Talbot R, Snook JA. Langerhan's cell histiocytosis complicating small bowel Crohn's disease. *Gut* 1996; **38**: 296-298 [PMID: 8801215 DOI: 10.1136/gut.38.2.296]
- 10 **Yashoda-Devi B**, Rakesh N, Agarwal M. Langerhans cell histiocytosis with oral manifestations: a rare and unusual case report. *J Clin Exp Dent* 2012; **4**: e252-e255 [PMID: 24558565 DOI: 10.4317/jced.50728]
- 11 **Ribeiro KB**, Degar B, Antoneli CB, Rollins B, Rodriguez-Galindo C. Ethnicity, race, and socioeconomic status influence incidence of Langerhans cell histiocytosis. *Pediatr Blood Cancer* 2015; **62**: 982-987 [PMID: 25586293 DOI: 10.1002/pbc.25404]

P- Reviewer: Imashuku S, Mentos O, Parker W **S- Editor:** Qiu S
L- Editor: Ji FF **E- Editor:** Wu HL





Published by **Baishideng Publishing Group Inc**

8226 Regency Drive, Pleasanton, CA 94588, USA

Telephone: +1-925-223-8242

Fax: +1-925-223-8243

E-mail: bpgoffice@wjgnet.com

Help Desk: <http://www.wjgnet.com/esps/helpdesk.aspx>

<http://www.wjgnet.com>

