

Desmopression is an effective adjunct treatment for reversing excessive hyponatremia overcorrection

Kamel A Gharaibeh, Matthew J Craig, Christian A Koch, Anna A Lerant, Tibor Fülöp, Éva Csongrádi

Kamel A Gharaibeh, Matthew J Craig, Christian A Koch, Tibor Fülöp, Éva Csongrádi, Department of Internal Medicine, University of Mississippi Medical Center, Jackson, MS 39216-4505, United States

Anna A Lerant, Department of Anesthesiology, University of Mississippi Medical Center, Jackson, MS 39216-4505, United States

Éva Csongrádi, Department of Medicine, University of Debrecen Medical and Health Science Centre, University of Debrecen, 4032 Debrecen, Hungary

Author contributions: Fülöp T was the attending physician and initiated the concept of the paper; Gharaibeh KA and Craig MJ acquired data and drafted the manuscript; Lerant AA analyzed the data and revised the manuscript; Koch CA and Csongrádi É interpreted the data and critically revised the manuscript; all authors reviewed and approved the final manuscript.

Correspondence to: Kamel A Gharaibeh, MD, Department of Internal Medicine, University of Mississippi Medical Center, 2500 North State Street, Jackson, MS 39216-4505, United States. kgharaibeh@umc.edu

Telephone: +1-601-5002931 Fax: +1-601-5002931

Received: March 11, 2013 Revised: April 19, 2013

Accepted: May 18, 2013

Published online: August 16, 2013

Abstract

We report a case of a 50-year-old malnourished African American male with hiccups, nausea and vomiting who was brought to the Emergency Department after repeated seizures at home. Laboratory evaluations revealed sodium (Na^+) 107 mmol/L, unmeasurably low potassium, chloride < 60 mmol/L, bicarbonate of 38 mmol/L and serum osmolality 217 mOsm/kg. Seizures were controlled with 3% saline IV. Once nausea was controlled with *iv* antiemetics, he developed large volume free water diuresis with 6 L of dilute urine in 8 h (urine osmolality 40-60 mOsm/kg) and serum sodium rapidly rose to 126 mmol/L in 12 h. Both intravenous desmopressin and 5% dextrose in water was given to achieve a concentrated urine and to temporarily reverse the

acute rise of sodium, respectively. Serum Na^+ was gradually re-corrected in 2-3 mmol/L daily increments from 118 mmol/L until 130 mmol/L. Hypokalemia was slowly corrected with resultant auto-correction of metabolic alkalosis. The patient discharged home with no neurologic sequelae on the 11th hospital day. In euvoletic hyponatremic patients controlling nausea may contribute to unpredictable free water diuresis. The addition of an antidiuretic hormone analog, such as desmopressin can limit urine output and prevent an unpredictable rise of the serum sodium.

© 2013 Baishideng. All rights reserved.

Key words: Hyponatremia; Hypokalemia; Overcorrection; Polyuria; Antidiuretic hormone; Vasopressin; Desmopressin; Osmotic demyelination syndrome; Central pontine myelinolysis

Core tip: In euvoletic hyponatremic patients, controlling the underlying reason of excessive vasopressin secretion may lead to sudden, large-volume free water diuresis and rise of serum sodium exceeding 12 mmol/L per day. Polyuria after presentation with symptomatic hyponatremia is a serious warning sign and should not be ignored. These patients need frequent electrolyte monitoring and, in case of excessive rise of serum sodium, pure water replacement with 5% dextrose in water to achieve a targeted reduction in serum sodium levels. Early addition of an antidiuretic hormone analog, such as desmopressin, can limit urine output and improve patient outcome.

Gharaibeh KA, Craig MJ, Koch CA, Lerant AA, Fülöp T, Csongrádi É. Desmopression is an effective adjunct treatment for reversing excessive hyponatremia overcorrection. *World J Clin Cases* 2013; 1(5): 155-158 Available from: URL: <http://www.wjgnet.com/2307-8960/full/v1/i5/155.htm> DOI: <http://dx.doi.org/10.12998/wjcc.v1.i5.155>

INTRODUCTION

Acute hyponatremia can cause death if cerebral edema and seizures are not treated promptly^[1]. Conversely, osmotic demyelination syndrome (ODS) will occur with rapid correction of severe chronic hyponatremia (serum sodium concentration 120 mmol/L or less) that has been present for more than 2 or 3 d, the time required for the cerebral adaptation to occur^[2]. Excessive correction of chronic hyponatremia triggers a cascade of injury in the brain beginning with breakdown of the blood-brain barrier and culminating in the programmed death of oligodendrocytes, the cells that form myelin sheaths in the central nervous system^[3]. Known risk factors for ODS are hyponatremia (both in duration and severity), rapid correction of hyponatremia with more than 12 mmol/L in less than 24 h, hypokalemia on presentation^[4-6], low BUN with malnourished state, alcoholism, liver disease and seizures on presentation^[7,8].

CASE REPORT

A 50-year-old African American male with history of hypertension and chronic intractable hiccups was brought to the emergency department (ED) by family members after three episodes of seizures at home, with the last episode few hours prior to admission and lasting for 10 min. The patient has been having hiccups for several years, which worsened acutely over 3 wk prior to admission. In order to control his hiccups, he has been drinking large amount of water and a proprietary carbonated beverage (Sprite®), as well. He reported nausea and daily vomiting and avoided solid food for the last two weeks prior to admission. He observed that his hiccups have improved temporarily with vomiting and the persisting and crescendo hiccups frustrated him enough to induce voluntary vomiting repeatedly.

On admission, his vital signs included a temperature of 36.4 °C, blood pressure of 168/73 mmHg with a heart rate of 81 beats/min, respiratory rate 18/min and body weight of 72.7 kg. General physical examination revealed an alert malnourished African-American male, oriented to person, place, and time with no focal neurological findings. Physical exam was unremarkable with no detectable peripheral edema. In the ED, the patient's serum electrolyte concentrations were: sodium of 107 mmol/L, potassium less than 1.5 mmol/L, chloride less than 60 mmol/L, bicarbonate of 38 mmol/L with a pH of 7.60. Blood urea nitrogen (BUN) measured 4 mg/dL, creatinine 0.7 mg/dL and serum osmolality 217 mOsm/kg. Liver function tests were within normal limits. EKG noted prolonged QT intervals (616 ms) and non-specific ST-T abnormalities. No arrhythmia was observed. Emergent treatment included 150 mL 3% saline IV bolus to control seizures, intravenous chlorpromazine (Thorazine®) and baclofen to control hiccups, nausea and vomiting and 1 L of normal saline with 40 mmol/L of potassium-chloride over 5 h. Six hours after the ED presentation, he was admitted to

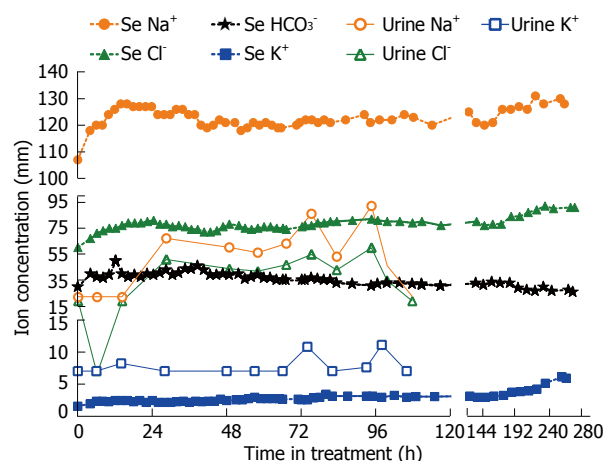


Figure 1 Serum and urine electrolyte concentrations over time. The patient spent 0-120 h in the intensive care unit.

the medical intensive care unit (ICU) for close monitoring.

Shortly after admission to the ICU, the patient developed large volume free water diuresis with 6 L of dilute urine over 8 h (initial U_{osm} 60 mOsm/kg; repeat 4 h later 40 mOsm/kg). The patient's serum sodium rapidly rose to 126 mmol/L within 12 h and he became drowsy. At that point of time, the decision was made to start desmopressin at 1 mcg *iv* twice a day to minimize dilute urine output, increased to 2 mcg *iv* twice daily the next day. We also administered 5% dextrose in water (D5W) to replace free water over 10 h, calculated to decrease serum sodium to 120 mmol/L. The patient's serum sodium concentration dropped to 118 mmol/L in 12 h after starting desmopressin and his urine output decreased to ≤ 2 L/d for the next several days. Thereafter, serum sodium was corrected gradually in 2-3 mmol/L daily increments until 130 mmol/L was reached with continued water restriction (Figure 1). After that point, serum potassium was slowly corrected with *per os* potassium supplements, with the resultant and expected auto-correction of metabolic alkalosis, once serum potassium normalized. The patient was released from the medical ICU on day 5 to the medical ward and discharged home on day 11th day with a weight of 71.4 kg. The patient fully recovered without any neurological sequelae and was discharged home with appropriate instructions, including limiting his fluid intake and avoiding self-induced nausea and vomiting.

DISCUSSION

Based on the co-morbid features during admission (hypokalemia, seizures, low BUN, rapid rise of sodium), our patient was at a very high risk of developing ODS^[9,10]. In our patient, nausea and vomiting contributed to the development of both hyponatremia^[11] and metabolic alkalosis^[12]. The presenting clinical picture for our patient on arrival was similar to the syndrome of inappropriate anti-diuretic hormone secretion (SIAD)^[13,14]. In his case, however, the causes for excessive release of vasopressin (or anti-diuretic hormone) were reversible ones: nausea

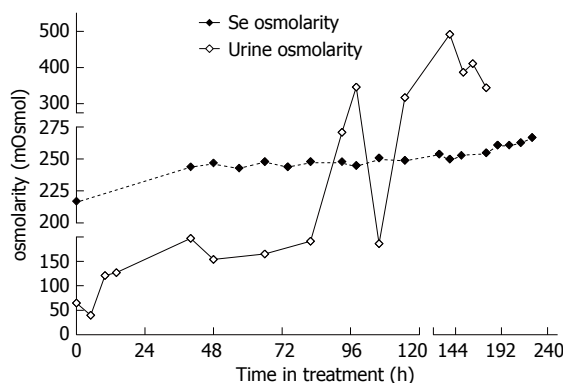


Figure 2 Serum and urine osmolality over time. The patient spent 0-120 h in the intensive care unit.

and hiccups. Nonetheless, once his nausea was resolved, alternative stimuli to maintain the vasopressin level (*e.g.*, hypovolemia) were absent. The patient excreted the free water accumulated prior to admission in the form of dilute urine, leading to the observed large rise of serum sodium. We could not correct metabolic alkalosis with *in vivo* acid infusions, as neither ammonium chloride nor hydrochloric acid^[15] were available either in our institution or from any of the surrounding healthcare facilities. We specifically monitored serum osmolality to reflect on all osmotically active substances (sodium, potassium and BUN; Figure 2) and avoided sudden correction of hypokalemia, which could have resulted in increased global osmolality^[3,10]. Immediate correction of hypokalemia is associated with ODS^[6,16,17], perhaps due to rise in intracellular potassium.

This case illustrates that administration of desmopressin can be a successful strategy both to ameliorate sodium overcorrection and to avoid inadvertent overcorrection of hyponatremia, if significant free water diuresis emerges during recovery from hyponatremia. Inadvertent overcorrection of hyponatremia is, in fact, common^[18] and should be viewed as a medical emergency^[19]. The administration of hypertonic saline sometimes increases serum sodium more than expected because of unanticipated water diuresis that may develop during the course of therapy. This was the case in our patient, who had additional risk factors for concentration impairment in the kidneys. This prompted us, along with free water administration, to use desmopressin to minimize urine output and alleviate overcorrection of hyponatremia (Figure 3). Avoiding overcorrection with oral intake is difficult since hyposmolality suppresses thirst and patients may reject water that is offered to them. Oral intake is not an option in patients with altered mental status. Finally, attempting to match urinary water losses with intravenous or orally administered electrolyte-free water requires intensive monitoring of fluid balance that is often impractical. Such a strategy has been reported in the medical literature^[20], including in a series of 20 patients, where pre-emptive administration of desmopressin prevented excessive water diuresis and fewer patients required 5% dextrose in water (D₅W) administration for therapeutic re-lowering of the sodium^[21].

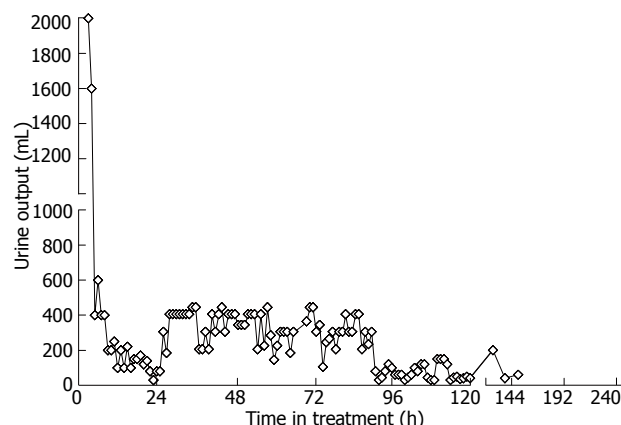


Figure 3 Urine output over time. The patient spent 0-120 h in the intensive care unit.

For these reasons, administration of vasopressin or synthetic vasopressin analog, such as desmopressin may be a more attractive strategy. Our paper strengthens and confirms the limited published experience to date with the use of desmopressin to prevent or reverse overcorrection of hyponatremia, in face of co-existing complex electrolyte disturbances^[22].

In conclusion, controlling nausea or any other reversible causes of excessive vasopressin release may lead to unpredictable free water diuresis in euvoletic hyponatremic patients. Polyuria after symptomatic hyponatremia on presentation is a serious warning sign. Early addition of an antidiuretic hormone analog, such as desmopressin, can limit urine output and prevent unpredictable free water losses with sudden rise in serum sodium, simplifying the managements of these complex and high-risk scenarios.

REFERENCES

- 1 Verbalis JG. Brain volume regulation in response to changes in osmolality. *Neuroscience* 2010; **168**: 862-870 [PMID: 20417691 DOI: 10.1016/j.neuroscience.2010.03.042]
- 2 Hoorn EJ, Zietse R. Hyponatremia and mortality: moving beyond associations. *Am J Kidney Dis* 2013; **62**: 139-149 [PMID: 23291150 DOI: 10.1053/j.ajkd.2012.09.019]
- 3 Norenberg MD. Central pontine myelinolysis: historical and mechanistic considerations. *Metab Brain Dis* 2010; **25**: 97-106 [PMID: 20182780 DOI: 10.1007/s11011-010-9175-0]
- 4 Lohr JW. Osmotic demyelination syndrome following correction of hyponatremia: association with hypokalemia. *Am J Med* 1994; **96**: 408-413 [PMID: 8192171]
- 5 Berl T, Rastegar A. A patient with severe hyponatremia and hypokalemia: osmotic demyelination following potassium repletion. *Am J Kidney Dis* 2010; **55**: 742-748 [PMID: 20338465 DOI: 10.1053/j.ajkd.2009.12.024]
- 6 Patel SV, Parish DC, Patel RM, Grimsley EW. Resolution of MRI findings in central pontine myelinolysis associated with hypokalemia. *Am J Med Sci* 2007; **334**: 490-492 [PMID: 18091372]
- 7 Sterns RH. Severe symptomatic hyponatremia: treatment and outcome. A study of 64 cases. *Ann Intern Med* 1987; **107**: 656-664 [PMID: 3662278]
- 8 Sterns RH, Cappuccino JD, Silver SM, Cohen EP. Neurologic sequelae after treatment of severe hyponatremia: a multicenter perspective. *J Am Soc Nephrol* 1994; **4**: 1522-1530

- [PMID: 8025225]
- 9 **Funayama M**, Hisamatsu T, Koreki A. Central pontine demyelolysis following water intoxication in schizophrenia. *Schizophr Res* 2011; **125**: 300-301 [PMID: 20705434 DOI: 10.1016/j.schres.2010.07.009]
 - 10 **King JD**, Rosner MH. Osmotic demyelination syndrome. *Am J Med Sci* 2010; **339**: 561-567 [PMID: 20453633 DOI: 10.1097/MAJ.0b013e3181d3cd78]
 - 11 **Fried LF**, Palevsky PM. Hyponatremia and hypernatremia. *Med Clin North Am* 1997; **81**: 585-609 [PMID: 9167647]
 - 12 **Seldin DW**, Rector FC. Symposium on acid-base homeostasis. The generation and maintenance of metabolic alkalosis. *Kidney Int* 1972; **1**: 306-321 [PMID: 4600132]
 - 13 **Kwun KB**, Boucherit T, Wong J, Richards Y, Bryan-Brown CW. Treatment of metabolic alkalosis with intravenous infusion of concentrated hydrochloric acid. *Am J Surg* 1983; **146**: 328-330 [PMID: 6614322]
 - 14 **Ellison DH**, Berl T. Clinical practice. The syndrome of inappropriate antidiuresis. *N Engl J Med* 2007; **356**: 2064-2072 [PMID: 17507705]
 - 15 **Esposito P**, Piotti G, Bianzina S, Malul Y, Dal Canton A. The syndrome of inappropriate antidiuresis: pathophysiology, clinical management and new therapeutic options. *Nephron Clin Pract* 2011; **119**: c62-c73; discussion c73 [PMID: 21677440 DOI: 10.1159/000324653]
 - 16 **Heng AE**, Vacher P, Aublet-Cuvellier B, Garcier JM, Sapin V, Deteix P, Souweine B. Centropontine myelinolysis after correction of hyponatremia: role of associated hypokalemia. *Clin Nephrol* 2007; **67**: 345-351 [PMID: 17598369]
 - 17 **Davenport C**, Liew A, Vic Lau P, Smith D, Thompson CJ, Kearns G, Agha A. Central pontine myelinolysis secondary to hypokalaemic nephrogenic diabetes insipidus. *Ann Clin Biochem* 2010; **47**: 86-89 [PMID: 19940203 DOI: 10.1258/acb.2009.009094]
 - 18 **Mohmand HK**, Issa D, Ahmad Z, Cappuccio JD, Kouides RW, Sterns RH. Hypertonic saline for hyponatremia: risk of inadvertent overcorrection. *Clin J Am Soc Nephrol* 2007; **2**: 1110-1117 [PMID: 17913972]
 - 19 **Sterns RH**, Hix JK. Overcorrection of hyponatremia is a medical emergency. *Kidney Int* 2009; **76**: 587-589 [PMID: 19721422 DOI: 10.1038/ki.2009.251]
 - 20 **Soupart A**, Ngassa M, Decaux G. Therapeutic relowering of the serum sodium in a patient after excessive correction of hyponatremia. *Clin Nephrol* 1999; **51**: 383-386 [PMID: 10404700]
 - 21 **Perianayagam A**, Sterns RH, Silver SM, Grieff M, Mayo R, Hix J, Kouides R. DDAVP is effective in preventing and reversing inadvertent overcorrection of hyponatremia. *Clin J Am Soc Nephrol* 2008; **3**: 331-336 [PMID: 18235152 DOI: 10.2215/CJN.03190807]
 - 22 **Sood L**, Sterns RH, Hix JK, Silver SM, Chen L. Hypertonic saline and desmopressin: a simple strategy for safe correction of severe hyponatremia. *Am J Kidney Dis* 2013; **61**: 571-578 [PMID: 23266328]

P- Reviewer Pasquale E S- Editor Zhai HH L- Editor A
E- Editor Ma S





Published by **Baishideng Publishing Group Co., Limited**

Flat C, 23/F., Lucky Plaza, 315-321 Lockhart Road,

Wan Chai, Hong Kong, China

Fax: +852-65557188

Telephone: +852-31779906

E-mail: bpgoffice@wjgnet.com

<http://www.wjgnet.com>

