

Pediatric living donor liver transplantation for congenital hepatic fibrosis using a mother's graft with von Meyenburg complex: A case report

Naoya Yamada, Yukihiro Sanada, Takumi Katano, Masahisa Tashiro, Yuta Hirata, Noriki Okada, Yoshiyuki Ihara, Atsushi Miki, Hideki Sasanuma, Taizen Urahashi, Yasunaru Sakuma, Koichi Mizuta

Naoya Yamada, Yukihiro Sanada, Takumi Katano, Masahisa Tashiro, Yuta Hirata, Noriki Okada, Yoshiyuki Ihara, Taizen Urahashi, Koichi Mizuta, Department of Transplant Surgery, Jichi Medical University, Shimotsuke-shi, Tochigi 329-0498, Japan

Atsushi Miki, Hideki Sasanuma, Yasunaru Sakuma, Department of Surgery, Jichi Medical University, Shimotsuke-shi, Tochigi 329-0498, Japan

Author contributions: Yamada N drafted the manuscript; Sanada Y, Katano T, Tashiro M, Hirata Y, Okada N, Ihara Y, Miki A, Sasanuma H, Urahashi T, Sakuma Y, and Mizuta K researched the literature, coordinated the management of the case, discussed the scientific issues regarding the management and helped to draft the manuscript; all authors read and approved the final manuscript.

Conflict-of-interest statement: The authors have no competing to disclose.

Institutional review board statement: This study was reviewed and approved by the Ethics Committees of Jichi Medical University, Tochigi, Japan (15-106).

Informed consent statement: The patient involved in this study gave her informed consent authorizing use and disclosure of her protected health information.

Open-Access: This article is an open-access article which was selected by an in-house editor and fully peer-reviewed by external reviewers. It is distributed in accordance with the Creative Commons Attribution Non Commercial (CC BY-NC 4.0) license, which permits others to distribute, remix, adapt, build upon this work non-commercially, and license their derivative works on different terms, provided the original work is properly cited and the use is non-commercial. See: <http://creativecommons.org/licenses/by-nc/4.0/>

Manuscript source: Unsolicited manuscript

Correspondence to: Naoya Yamada, MD, Department of

Transplant Surgery, Jichi Medical University, 3311-1 Yakushiji, Shimotsuke-shi, Tochigi 329-0498, Japan. yn708@jichi.ac.jp
Telephone: +81-285-587069
Fax: +81-285-587069

Received: May 28, 2016
Peer-review started: May 30, 2016
First decision: July 29, 2016
Revised: August 30, 2016
Accepted: September 28, 2016
Article in press: September 28, 2016
Published online: November 28, 2016

Abstract

This is the first report of living donor liver transplantation (LDLT) for congenital hepatic fibrosis (CHF) using a mother's graft with von Meyenburg complex. A 6-year-old girl with CHF, who suffered from recurrent gastrointestinal bleeding, was referred to our hospital for liver transplantation. Her 38-year-old mother was investigated as a living donor and multiple biliary hamartoma were seen on her computed tomography and magnetic resonance imaging scan. The mother's liver function tests were normal and she did not have any organ abnormality, including polycystic kidney disease. LDLT using the left lateral segment (LLS) graft from the donor was performed. The donor LLS graft weighed 250 g; the graft recipient weight ratio was 1.19%. The operation and post-operative course of the donor were uneventful and she was discharged on post-operative day (POD) 8. The graft liver function was good, and the recipient was discharged on POD 31. LDLT using a graft with von Meyenburg complex is safe and useful. Long-term follow-up is needed with respect to graft liver function and screening malignant tumors.

Key words: Congenital hepatic fibrosis; Von Meyenburg complex; Living donor liver transplantation; Pediatric liver transplantation

© **The Author(s) 2016.** Published by Baishideng Publishing Group Inc. All rights reserved.

Core tip: Multiple biliary hamartoma is a rare, benign lesion known as von Meyenburg complex. This is the first report of living donor liver transplantation (LDLT) using a liver graft with von Meyenburg complex. A 6-year-old girl with congenital hepatic fibrosis, who suffered from recurrent gastrointestinal bleeding, was transplanted her mother's liver graft with von Meyenburg complex. Successful LDLT was performed, and the liver and renal function after LDLT were good also in recipient and donor. LDLT using a graft with von Meyenburg complex is safe and useful for a further expansion of living donor pool. Long-term follow-up is needed with respect to graft liver function and screening malignant tumors.

Yamada N, Sanada Y, Katano T, Tashiro M, Hirata Y, Okada N, Ihara Y, Miki A, Sasanuma H, Urahashi T, Sakuma Y, Mizuta K. Pediatric living donor liver transplantation for congenital hepatic fibrosis using a mother's graft with von Meyenburg complex: A case report. *World J Gastroenterol* 2016; 22(44): 9865-9870 Available from: URL: <http://www.wjgnet.com/1007-9327/full/v22/i44/9865.htm> DOI: <http://dx.doi.org/10.3748/wjg.v22.i44.9865>

INTRODUCTION

Multiple biliary hamartoma is a rare, benign lesion known as von Meyenburg complex^[1]. The frequency is unknown, but Lin *et al*^[2] have reported that it was seen in 0.35% of patients undergoing liver biopsy. Multiple biliary hamartoma is a benign tumor and does not affect liver function. However, there exist only two case reports of liver transplantation (LT) with a donor having von Meyenburg complex, both of which were orthotopic liver transplantation LT^[3,4]. Due to the lack of information, graft liver function with von Meyenburg complex and the risk of malignancy in the graft liver are unknown.

To the best of our knowledge, there have been no reports of living donor liver transplantation (LDLT) from a donor with von Meyenburg complex. We herein report a case of pediatric LDLT for congenital hepatic fibrosis (CHF) with a graft taken from the mother having von Meyenburg complex, and considered the possibility of a liver with von Meyenburg complex for a further expansion of living donor pool.

Interestingly, the recipient (the donor's daughter) had CHF, which is considered to be associated with von Meyenburg complex. Both of these conditions are considered as type of hepatobiliary fibropolycystic disease^[5]. The case especially focuses on the pre-

operative imaging findings and liver function of the donor and the recipient.

CASE REPORT

A 6-year-old female patient with CHF was referred to our hospital for LT. She developed sudden hematemesis due to esophagogastric varices and had been diagnosed with CHF based on histological findings from a liver biopsy that was done when she was 4 years old. She had been suffering from recurrent gastrointestinal bleeding for 2 years and was considered competent for LT (Figure 1A, Table 1).

The only living donor candidate was the patient's 38-year-old mother. The mother had undergone clinical examinations required for evaluation as a potential donor. Her magnetic resonance imaging (MRI) scan showed multiple 3-5 mm nodules with high intensity in T2 weighted imaging (Figure 2A). The nodules were dominant in the right lobe of her liver, although they were seen in the left lobe to some extent. Her computed tomography (CT) scan also revealed multiple low-density areas that were 3-5 mm in diameter, and had higher density in CT scan than the water level (Figure 2B). Therefore, rather than multiple liver cyst, multiple biliary hamartoma, also known as von Meyenburg complex was suspected. Her standard liver function tests were normal (T-Bil; 0.33 mg/dL, AST; 12 U/L, ALT; 11 U/L), and she did not have cystic disease of any other organ, especially polycystic kidney disease. Although her daughter developed repetitive severe gastrointestinal bleeding, no other living donor was available, and therefore the mother was selected as the living donor.

During LDLT, hepatectomy of the donor's left-lateral segment (LLS) was performed. Multiple cystic lesions were observed in the mother's liver during surgery, more so in the right lobe of the liver. The LLS graft from the donor weighed 250 g, and it was estimated to be 22.7% of the donor's total liver volume of the donor. The operation time and amount bleeding were 4 h 24 min and 430 mL, respectively. The operation and post-operative course of the donor were uneventful and she was discharged on post-operative day (POD) 8.

During the recipient's surgery, the graft liver was transplanted after total hepatectomy. Her native liver showed fibrotic changes in the portal area, with proliferation of the pseudocholangiolar ducts, and it was consistent with CHF (Figure 1B-D). The graft-recipient weight ratio and graft volume/standard liver volume were 1.19% and 43.2%, respectively. The vascular reconstructions were anastomosed from the donor's left hepatic vein to the recipient's middle and left hepatic vein, the donor's left portal vein to the recipient's main portal vein, and the donor's left hepatic artery to the recipient's right hepatic artery. After reperfusion of the graft liver, we observed multiple small lesions suspected to be biliary hamartoma (Figure 3A). Time zero biopsy of the graft liver revealed the

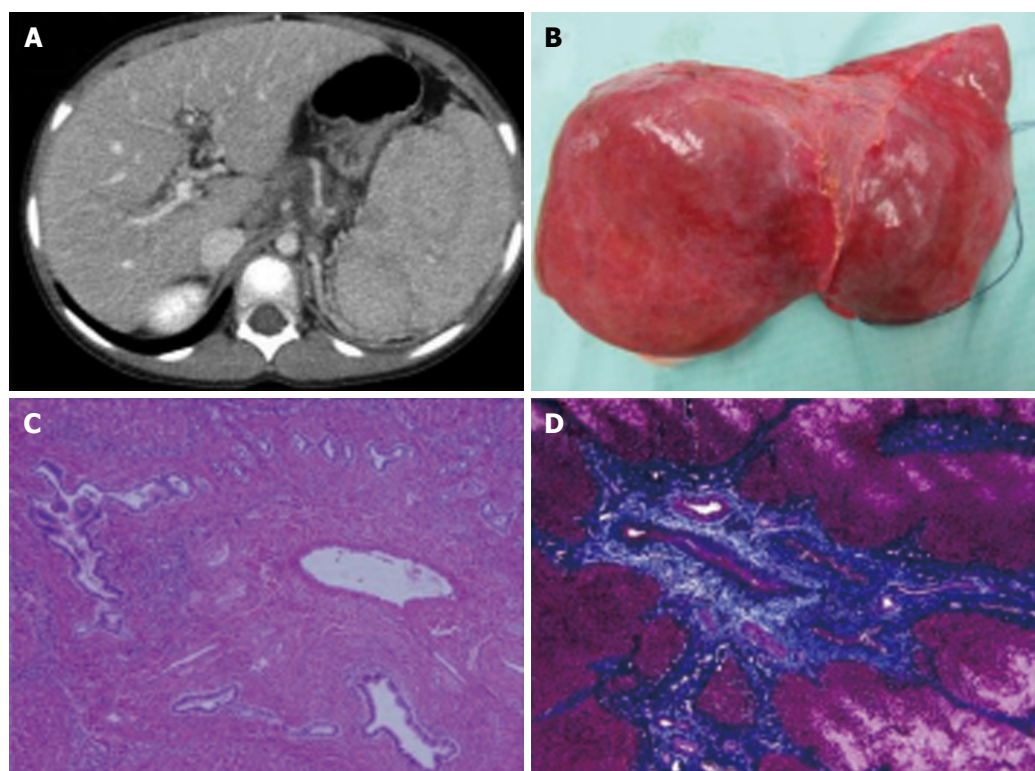


Figure 1 Computed tomography scan (A), macroscopic finding (B) and histology findings (C, D) of the recipient. A, B: Reveals splenomegaly due to portal hypertension (A), macroscopic finding of the recipient's native liver (B). Her native liver shows fibrotic changes in the portal area with proliferation of the pseudocholangiolar ducts, which is consistent with congenital hepatic fibrosis (C, D). C: Hematoxylin-eosin staining; D: Azan staining. Magnification $\times 100$.

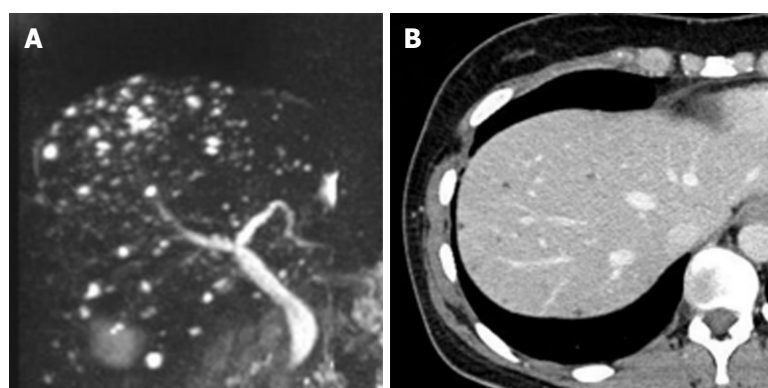


Figure 2 Magnetic resonance imaging and computed tomography scan of the donor. Magnetic resonance imaging scan of the donor shows 3-5 mm multiple nodules with high intensity in T2 weighted image (A). Her computed tomography scan also reveals multiple low-density area of 3-5 mm in diameter. Multiple biliary hamartoma, also known as von Meyenburg complex, was suspected.

slight fibrosis around portal area, with a Metavir fibrosis score F0 (Figure 3B). The operation time and estimated bleeding volume were 10 h 20 min and 380 mL, respectively. Tacrolimus and Methylprednisolone were used as postoperative immunosuppressive therapy. After LDLT, the recipient developed catheter-related bloodstream infection on POD 7 and obstruction of external biliary drainage tube on the POD 22, which was accompanied by slight temporary elevation of alanine transaminase (Figure 4). However, the graft liver function was good, and gastrointestinal bleeding did not occur after LDLT. She was therefore discharged

on POD 31. Her routine CT scan on POD 28 revealed some small nodules suspected to biliary hamartoma (Figure 3C). One year have passed after LDLT, and her graft liver and renal function were normal. Her oncogenic surveillance was also with no abnormal findings.

DISCUSSION

Kerr *et al*^[6] first reported in 1961 that CHF is a hereditary autosomal recessive fibropolycystic disease of the liver. It is caused by ductal plate malformations

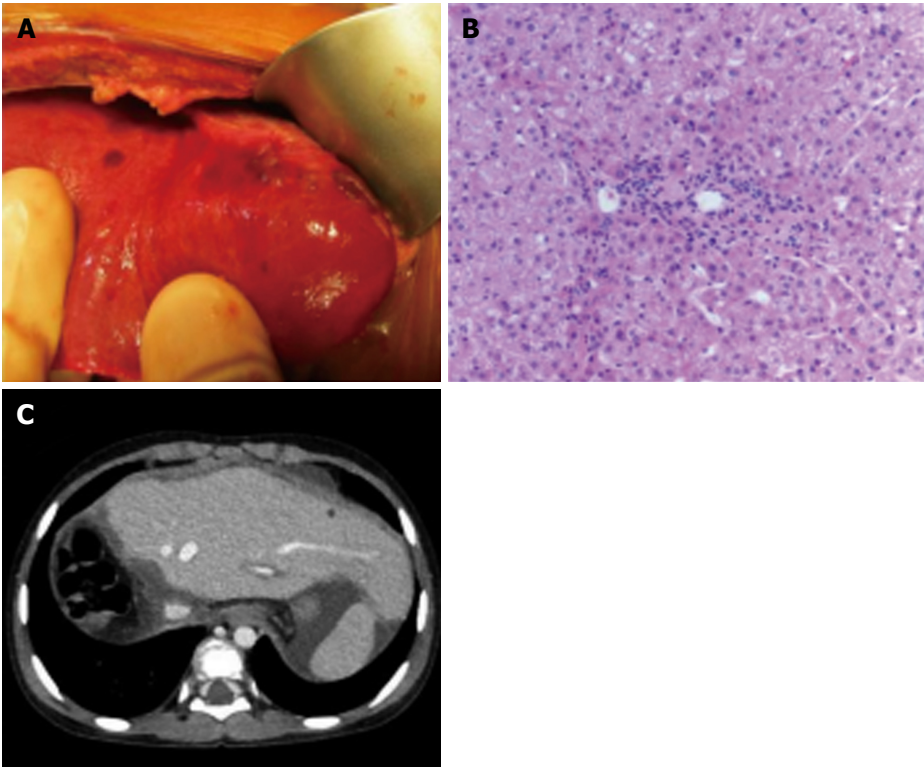


Figure 3 Clinical findings during the recipient's surgery. During living donor liver transplantation, we identified the small lesions of the graft liver suspected as biliary hamartoma after reperfusion (A). Time zero biopsy of the graft liver revealed slight fibrosis around the portal area; metavir fibrosis score F0 (B) (magnification $\times 100$). Computed tomography scan on postoperative day 28 (C).

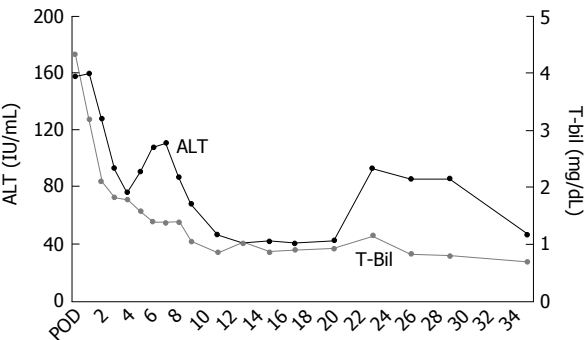


Figure 4 Clinical course of the recipient after living donor liver transplantation. Her graft liver function was good and she was discharged on postoperative day 31. ALT: Alanine transaminase; T-Bil: Total bilirubin.

and is sometimes accompanied by polycystic kidney disease^[7,8]. The typical pathological findings of a liver with CHF are progressive fibrosis around the portal veins and cystic changes of the peripheral small-sized bile ducts in the thick fibrotic band. Survival depends mainly on complications of portal hypertension, such as variceal bleeding and hypersplenism, and some cases are complicated with cholangiocarcinoma or hepatocellular carcinoma in the long term. There are some patients with CHF who progress to liver failure or severe gastrointestinal bleeding, and require LT.

Hepatobiliary fibropolycystic disease, including Caroli disease, von Meyenburg complex (multiple biliary

Table 1 Preoperative blood examination of the recipient

Items	Results	Units
WBC	3.6×10^4	/ μ L
RBC	372	/ μ L
Hb	7.9×10^4	g/dL
Ht	26.4	%
Plt	6.9	/ μ L
TP	6.4	g/dL
Alb	4.2	g/dL
BUN	10	mg/dL
Cre	0.24	mg/dL
T-Bil	0.67	mg/dL
AST	43	U/L
ALT	39	U/L
LDH	258	U/L
γ -GTP	41	U/L

WBC: White blood cell count; RBC: Red blood cell count; Hb: Hemoglobin; Ht: Hematocrit; Plt: Platelet count; TP: Total protein; Alb: Albumin; BUN: Blood urea nitrogen; Cre: Creatinine; T-Bil: Total bilirubin; AST: Aspartate aminotransferase; ALT: Alanine aminotransferase; LDH: Lactate dehydrogenase; γ -GTP: γ -glutamyltransferase.

hamartoma), CHF, and polycystic liver disease are considered to arise from the same etiology, with different levels of the biliary tract being affected. von Meyenburg complex is now considered to not be a pure liver disease, but rather a multi-organ disorder involving the brain, portal vein, kidneys, and bile ducts; some genetic linked disorders have been identified^[9-11].

Interestingly, this is the first case report wherein a parent has von Meyenburg complex and the child has CHF, but neither had multi-organ disorder.

Only two case reports exist of LT from patients with von Meyenburg complex; both of these cases are orthotopic LT. They were diagnosed at procurement of LT, and the recipient's graft liver function was good after LT. Our case is likely the first case report of LDLT from a donor having von Meyenburg complex. We could not obtain the histopathological diagnosis of the biliary hamartoma; however, the MRI and CT findings of von Meyenburg complex are characteristic and reportedly enable a highly accurate diagnosis^[12,13]. Although some lesions of von Meyenburg complex were seen in the donor's left lobe, they were dominant in the right lobe, and preoperative laboratory liver function tests in the donor were normal. There was no other living donor available, due to which the LLS graft with some lesions of von Meyenburg complex had to be retrieved. Although time zero biopsy of the graft revealed slight fibrosis in the portal area, the graft function and clinical course of the recipient were good. To our experience and according to previous reports, graft liver with von Meyenburg complex shows no problem regarding graft function in the early post-LT phase.

The von Meyenburg complex usually consists of benign tumors, but there have been several case reports of cholangiocarcinoma or hepatocellular carcinoma arising from the liver with the multiple biliary hamartoma^[14-17]. To date, the frequency of cholangiocarcinoma arising from a liver with von Meyenburg complex is unknown; whether these cholangiocarcinomas were derived from the biliary hamartoma is also unknown. However, under the circumstances, oncologic surveillance of the graft liver in the recipient should be performed over time. In addition, hepatobiliary fibropolycystic disease, including CHF, is sometimes accompanied by polycystic kidney disease, which can result in renal failure^[18]. When following up the LT recipient for CHF in the outpatient clinic, physicians should check renal function as well as for the appearance of cysts in the kidney.

In our institute, we perform the routine blood test (including standard liver function test and renal function test) and echo check per 3 mo for first 5 years and per 6 mo after that. We also examine the CT scan at 1 mo, 6 mo, and 1 year after LT. From 1 year to 5 years after LT, CT scan were performed annually; thereafter they were examined every 2 years^[18]. We will perform same follow up for the recipient. In addition, we will add the tumor marker test (carcinoembryonic antigen, carbohydrate antigen 19-9), when blood examination will be performed.

In conclusion, we successfully treated a patient with CHF by performing LDLT using the mother's graft that had von Meyenburg complex. Long-term follow-up regarding graft liver function, screening for malignant tumors, checking renal function, and watching for the appearance of polycystic kidney disease is needed.

COMMENTS

Case characteristics

A 6-year-old girl with congenital hepatic fibrosis (CHF), who suffered from recurrent gastrointestinal bleeding, was transplanted her mother's liver graft with von Meyenburg complex.

Clinical diagnosis

The recipient was suffered from hematemesis. The donor had no symptoms; the von Meyenburg complex was detected after donor's examination.

Differential diagnosis

Hepatobiliary fibropolycystic disease, including Caroli disease, von Meyenburg complex (multiple biliary hamartoma), CHF, and polycystic liver disease.

Laboratory diagnosis

The donor with von Meyenburg complex was normal liver function.

Imaging diagnosis

The donor's magnetic resonance imaging scan showed multiple 3-5 mm nodules with high intensity in T2 weighted imaging.

Pathological diagnosis

The recipient was diagnosed CHF.

Treatment

Living donor liver transplantation (LDLT).

Related reports

There exist only two case reports of liver transplantation with a donor having von Meyenburg complex, both of which were orthotopic liver transplantation.

Term explanation

Multiple biliary hamartoma is a rare, benign lesion known as von Meyenburg complex, which is included in the hepatobiliary fibropolycystic disease.

Experiences and lessons

LDLT using a graft with von Meyenburg complex is safe and useful for a further expansion of living donor pool. Long-term follow-up is needed with respect to graft liver function and screening malignant tumors.

Peer-review

This paper is informative and is suitable for publishing.

REFERENCES

- 1 **Mortelé B**, Mortelé K, Seynaeve P, Vandeveld D, Kunnen M, Ros PR. Hepatic bile duct hamartomas (von Meyenburg Complexes): MR and MR cholangiography findings. *J Comput Assist Tomogr* 2002; **26**: 438-443 [PMID: 12016376]
- 2 **Lin S**, Weng Z, Xu J, Wang MF, Zhu YY, Jiang JJ. A study of multiple biliary hamartomas based on 1697 liver biopsies. *Eur J Gastroenterol Hepatol* 2013; **25**: 948-952 [PMID: 23510964 DOI: 10.1097/MEG.0b013e32835fb9ee]
- 3 **Saidi RF**, Yoon V, Jabbour N, Shah SA, Bozorgzadeh A. Liver transplantation from a donor with multiple biliary hamartomata. *Int J Organ Transplant Med* 2013; **4**: 35-37 [PMID: 25013652]
- 4 **Perkins JD**. Are we reporting the same thing? *Liver Transpl* 2007; **13**: 465-466 [PMID: 17396292]
- 5 **Summerfield JA**, Nagafuchi Y, Sherlock S, Cadafalch J, Scheuer PJ. Hepatobiliary fibropolycystic diseases. A clinical and histological review of 51 patients. *J Hepatol* 1986; **2**: 141-156 [PMID: 3958471]
- 6 **Kerr DN**, Harrison CV, Sherlock S, Walker RM. Congenital hepatic fibrosis. *Q J Med* 1961; **30**: 91-117 [PMID: 13752660]

- 7 **Landing BH**, Wells TR, Lipsey AI, Oyemade OA. Morphometric studies of cystic and tubulointerstitial kidney diseases with hepatic fibrosis in children. *Pediatr Pathol* 1990; **10**: 959-972 [PMID: 2082340]
- 8 **Desmet VJ**. What is congenital hepatic fibrosis? *Histopathology* 1992; **20**: 465-477 [PMID: 1607148]
- 9 **Yönem O**, Ozkayar N, Balkanci F, Harmanci O, Sökmensüer C, Ersoy O, Bayraktar Y. Is congenital hepatic fibrosis a pure liver disease? *Am J Gastroenterol* 2006; **101**: 1253-1259 [PMID: 16771946]
- 10 **Gunay-Aygun M**, Font-Montgomery E, Lukose L, Tuchman Gerstein M, Piwnica-Worms K, Choyke P, Daryanani KT, Turkbey B, Fischer R, Bernardini I, Sincan M, Zhao X, Sandler NG, Roque A, Douek DC, Graf J, Huizing M, Bryant JC, Mohan P, Gahl WA, Heller T. Characteristics of congenital hepatic fibrosis in a large cohort of patients with autosomal recessive polycystic kidney disease. *Gastroenterology* 2013; **144**: 112-121.e2 [PMID: 23041322]
- 11 **Cnossen WR**, Drenth JP. Polycystic liver disease: an overview of pathogenesis, clinical manifestations and management. *Orphanet J Rare Dis* 2014; **9**: 69 [PMID: 24886261]
- 12 **Madhusudhan KS**, Das CJ. von Meyenburg's complex in a patient with primary malignancy: role of MRI. *Indian J Surg* 2009; **71**: 98-100 [PMID: 23133125]
- 13 **Zheng RQ**, Zhang B, Kudo M, Onda H, Inoue T. Imaging findings of biliary hamartomas. *World J Gastroenterol* 2005; **11**: 6354-6359 [PMID: 16419165]
- 14 **Röcken C**, Pross M, Brucks U, Ridwelski K, Roessner A. Cholangiocarcinoma occurring in a liver with multiple bile duct hamartomas (von Meyenburg complexes). *Arch Pathol Lab Med* 2000; **124**: 1704-1706 [PMID: 11079031]
- 15 **Dekker A**, Ten Kate FJ, Terpstra OT. Cholangiocarcinoma associated with multiple bile-duct hamartomas of the liver. *Dig Dis Sci* 1989; **34**: 952-958 [PMID: 2470558]
- 16 **Burns CD**, Kuhns JG, Wieman TJ. Cholangiocarcinoma in association with multiple biliary microhamartomas. *Arch Pathol Lab Med* 1990; **114**: 1287-1289 [PMID: 2174673]
- 17 **Jain D**, Nayak NC, Saigal S. Hepatocellular carcinoma arising in association with von-Meyenburg's complexes: an incidental finding or precursor lesions? A clinicopathologic study of 4 cases. *Ann Diagn Pathol* 2010; **14**: 317-320 [PMID: 20850692]
- 18 **Hirata Y**, Sanada Y, Urahashi T, Ihara Y, Yamada N, Okada N, Tashiro M, Katano T, Otomo S, Ushijima K, Mizuta K. Relationship Between Graft Liver Function and the Change of Graft Liver and Spleen Volumes After Technical Variant Liver Transplantation. *Transplant Proc* 2016; **48**: 1105-1109 [PMID: 27320567]

P- Reviewer: Arni D, Ma JQ **S- Editor:** Yu J **L- Editor:** A
E- Editor: Zhang FF





Published by **Baishideng Publishing Group Inc**

8226 Regency Drive, Pleasanton, CA 94588, USA

Telephone: +1-925-223-8242

Fax: +1-925-223-8243

E-mail: bpgoffice@wjgnet.com

Help Desk: <http://www.wjgnet.com/esps/helpdesk.aspx>

<http://www.wjgnet.com>



ISSN 1007-9327

