

"Contrast nephropathy" in renal transplantation: Is it real?

Fedaey Mohammed Abbas, Bridson M Julie, Ajay Sharma, Ahmed Halawa

Fedaey Mohammed Abbas, Nephrology Department, Jaber El Ahmed Military Hospital, Safat 13005, Kuwait

Fedaey Mohammed Abbas, Bridson M Julie, Ajay Sharma, Ahmed Halawa, Faculty of Health and Science, University of Liverpool, Institute of Learning and Teaching, School of Medicine, Liverpool L69 3GB, United Kingdom

Ajay Sharma, Royal Liverpool University Hospital, Liverpool L7 8XP, United Kingdom

Ahmed Halawa, Sheffield Teaching Hospitals, Sheffield S5 7AU, United Kingdom

Author contributions: Abbas FM designed the study, data collection, writing the manuscript; Julie BM and Sharma A reviewed and edited the manuscript; Halawa A contributed to providing the topic for the manuscript, designing the study, supervising the data collection and reviewing and editing the manuscript.

Conflict-of-interest statement: There are no conflicts of interest to the manuscript.

Open-Access: This article is an open-access article which was selected by an in-house editor and fully peer-reviewed by external reviewers. It is distributed in accordance with the Creative Commons Attribution Non Commercial (CC BY-NC 4.0) license, which permits others to distribute, remix, adapt, build upon this work non-commercially, and license their derivative works on different terms, provided the original work is properly cited and the use is non-commercial. See: <http://creativecommons.org/licenses/by-nc/4.0/>

Manuscript source: Invited manuscript

Correspondence to: Ahmed Halawa, Consultant Transplant Surgeon, Sheffield Teaching Hospital, Herries Road, Sheffield S5 7AU, United Kingdom. ahmed.halawa@sth.nhs.uk
 Telephone: +44-77-87542128
 Fax: +44-11-42714604

Received: July 18, 2016
 Peer-review started: July 21, 2016
 First decision: September 5, 2016
 Revised: October 3, 2016

Accepted: October 22, 2016
 Article in press: October 24, 2016
 Published online: December 24, 2016

Abstract

The risk of contrast-induced nephropathy (CIN) in renal transplant recipients is increased in diabetics, patients with impaired basal kidney function, patients in shock, patients presenting with acute emergency and in old age recipients. Approximately one-third of all hospitalized patients with acute kidney injury is attributed to CIN. In the United States, it is the third leading cause of hospital-acquired renal failure. Therefore, efforts should be directed to minimize CIN-related morbidity and mortality as well as to shorten hospital stay. While the role of peri-procedural prophylactic hydration with saline is unequivocal; the use of acetyl cysteine is not based on robust evidence. The utility of theophylline, aminophylline, calcium channel blockers, natriuretic peptide, and diuretics does not have proven role in attenuating CIN incidence. We aim to analyze the evidence for using various protocols in published literature to limit CIN-associated morbidity and mortality, particularly during surveillance of the renal allograft survival.

Key words: Contrast; Renal; Transplantation; Nephropathy

© **The Author(s) 2016.** Published by Baishideng Publishing Group Inc. All rights reserved.

Core tip: The renal transplant is usually a solitary kidney with diverse hemodynamic changes and exposed to the immunosuppressive agents for a long period. Any superadded stress such as contrast-induced nephropathy (CIN), will definitely affect allograft function. We provide in this article a comprehensive review of the current evidence on the true incidence, the mechanism of damage induced by CIN and available preventive measures to counteract the possible effect induced by CIN.

Abbas FM, Julie BM, Sharma A, Halawa A. "Contrast nephropathy" in renal transplantation: Is it real? *World J Transplant* 2016; 6(4): 682-688 Available from: URL: <http://www.wjgnet.com/2220-3230/full/v6/i4/682.htm> DOI: <http://dx.doi.org/10.5500/wjt.v6.i4.682>

INTRODUCTION

Perioperative transplant complications are reported to involve about 15%-20% of the kidney transplant recipients. Diagnostic ultrasound (US) is the most common and first line imaging modality^[1], since it is safe, noninvasive, gives a rapid diagnosis and also a portable tool for many surgical emergencies requiring bedside imaging^[2-5]. The utility of ultrasonography in management of hydronephrosis, renal masses, renal artery stenosis (RAS) and pyelonephritis in renal allograft is well documented^[1].

Computed tomography (CT) scanning and CT-guided interventions play a vital role in investigating post-operative complications. Magnetic resonance imaging (MRI) and magnetic resonance angiography (MRA) can be used safely where there is renal dysfunction, since the "Gadolinium-based" contrast media can be safely used with minimal nephrotoxic effects. Post-transplant complications such as vessel thrombosis can also be assessed using these modalities. Allograft "morphology and function" can be effectively assessed by using intravenous Gadopentetate Dimeglumine (DTPA) to the MRA technique^[6].

However, the patients with pacemakers, aneurysmal clips, or evident claustrophobia cannot be safely exposed to MRI studies. Gadolinium-based media have been linked to the development of nephrogenic systemic fibrosis (NSF). Another drawback of MRI, is the "layering" of the excreted gadolinium in the urinary bladder causing multiple image artifacts. Alternatively, CT is better for the evaluation of the kidney and urinary bladder for renal stones and ureter and bladder abnormalities. To summarize, MRI is usually dedicated to the evaluation of transplant recipient, whereas CT and CT angiogram are reserved for potential donors^[6].

MECHANISM OF CONTRAST-INDUCED NEPHROPATHY

Vasoconstriction induced by the contrast media (CM) can be explained by the direct action of contrast media on vascular smooth muscle and from metabolites such as adenosine and endothelin. Moreover, the osmotic criteria of contrast media, especially in the tubular lumen, affects water reabsorption, leading to a magnifying interstitial pressure. This will be augmented by the increased salt and water load to the distal tubules, will decrease GFR and lead to local compression of the vasa recta. All these factors will aggravate medullary hypoxemia and renal vasoconstriction in an already volume depleted patient.

Finally, contrast media could increase resistance to blood flow by increasing its viscosity and by deranging red blood cells (RBCs) deformability. These manifest as local ischemia leading to activation of reactive oxygen species that result in damage to renal tubules^[7].

Up till now, we are sure why renal failure patients are sensitive to contrast utilization. Whether their primary disease is a contributing factor or not, this has to be elucidated by additional future research.

CONTRAST NEPHROPATHY IN RENAL TRANSPLANTATION

Intravenous contrast (Table 1)

Only a relatively handful of studies have looked into the contrast-induced nephropathy (CIN) in the renal transplant recipients. Light *et al*^[8], 1975 studied thirty-four renal transplant recipients received drip infusion urograms post-transplantation. Twenty-two patients exhibited a change in renal function within 1-4 d of the urogram that was indistinguishable from allograft rejection that is a tender swollen kidney, a rise in serum creatinine, oliguria, diminished urinary sodium, weight gain and hypertension. Two patients developed acute tubular necrosis (ATN) and required hemodialysis, but renal function in the remaining 20 patients improved after therapy for "graft rejection" with intravenous methylprednisolone sodium succinate. Kidneys from older-age donors that were functioning sub-optimally at transplant and kidneys, which exhibited subsequent clinical allograft rejection, were more at risk for CIN. These suggested occult vascular lesions might have been present in the allograft, which was exacerbated when exposed to the irritant vascular effects of contrast media, producing a mild, reversible toxic nephritis. However, several renal grafts with normal function and also those, which never exhibited rejection activity, were also adversely affected by exposure to contrast media. Therefore these agents should be used cautiously, if at all, in the early post-transplant period^[8]. CIN was more common and more severe in those with impaired kidney function. This study also found that kidneys from older donors were at higher risk for CIN. In this study, contrast was used before stable creatinine was achieved, these kidney transplant recipients were not on a CNI, and there is no mention of use of any prophylaxis to prevent CIN. More than half of these patients were thought to have acute rejection and were treated as such without consistent biopsy documentation^[8].

The incidence of acute kidney injury (AKI) induced by CIN resulting from direct exposure to contrast media in kidney transplants recipients still controversial. The main insult is the ensuing vasoconstriction of the afferent glomerular arterioles and reduction in renal blood flow and glomerular filtration rate. Renal vasoconstriction, as well as direct tubular epithelial toxicity, is the two major mechanisms by which contrast causes AKI as explained by Haider *et al*^[9] in 2015. Immediately after contrast

Table 1 Trials concerned with contrast nephropathy

No.	Trial	Year	No. of KTRs	Need for HDX	CIN	Comments
1	Light <i>et al</i> ^[8]	1975	34	Two	22	20 patients improved after therapy for "graft rejection"
2	Moreau <i>et al</i> ^[12]	1975	231	None	Nil	No increase in risk of CIN in KTRs if contrast studies were performed with normal renal function
3	Peters <i>et al</i> ^[11]	1983	93	None	Very high (84.3%)	No increased risk was found > 120 d post-transplant
4	Ahuja <i>et al</i> ^[10]	2000	35	None	> 21%	Patients received high osmolality contrast, and 94% were on CyA therapy
5	Charnow <i>et al</i> ^[16]	2015	76	None	> 13.2%	CIN did not affect allograft function and survival, according to the researchers
6	Haider <i>et al</i> ^[9]	2015	124	None	5.60%	The largest retrospective study evaluating incidence of CIN in KTRs. CNIs were being used in 95% patients at the time of contrast administration
7	Bostock <i>et al</i> ^[15]	2016	40	One	12.50%	Renal dysfunction is 3 times more frequent in KTR treated with EVAR, though overall survival did not differ between groups. Decreased pre-operative eGFR and higher iodine/eGFR ratio are associated with post-operative renal dysfunction
8	Fananapazir <i>et al</i> ^[14]	2016	104	None	7% and 3%	Incidence of CIN = 7% (7/104) based on a rise of ≥ 0.3 mg/dL and 3% (3/104) based on a rise of ≥ 0.5 mg/dL. With a strict definition (≥ 0.5 mg/dL) had a pre-CT eGFR < 60 mL/min per 1.73 m ² . No patients required DX or had allograft loss 30 d after contrast use

CIN: Contrast-induced nephropathy; HDX: Hemodialysis; KTRs: Kidney transplant recipients; CNIs: Calcineurin inhibitors; EVAR: Endovascular aortic aneurysm repair; eGFR: Estimated glomerular filtration rate.

use, there is a transient increase in renal blood flow followed by a prolonged reduction in flow resulting in renal ischemia. So, there is "clustering" of two risk factors here, as both calcineurin inhibitors and IV contrast cause renal ischemia by the dual mechanism: (1) by increasing the release of the vasoconstrictors such as endothelin; and (2) by blocking the release of vasodilators including prostaglandins and nitric oxide^[10].

Ahuja *et al*^[10] (2000) also studied 35 kidney transplantation recipients (KTRs) as regard the effect of "volume expansion" as well as the effect of cyclosporine therapy; which documented the presence of CIN in a percentage exceeding 21%, with incidence of CIN was about 15% in patients received volume expansion and exceeds 42% in those who did not. None of these patients had AKI requiring dialysis. In this study, two main insults were reported, first: They received "high osmolality" contrast, and second: 94% were on cyclosporine therapy. The baseline serum creatinine in patients with and without CIN was 1.54 ± 0.17 mg/dL and 1.97 ± 0.20 mg/dL, respectively, $P = 0.15$, but the volume of contrast was not reported here. Another study- demonstrated by Peters *et al*^[11] in 1983-reported a very high incidence of CIN (84.3%) in the early post-transplant period, but no increased risk was found > 120 d post-transplant.

Moreau *et al*^[12] (1975) demonstrated clear evidence that there was no increase in the risk of CIN in kidney transplant recipients if contrast studies were performed against a background of normal renal function. Data observed from these studies showed that older donor kidney, early post-transplant period, impaired baseline kidney function, and lack of prophylactic volume expansion, appear to be important risk factors for increasing the incidence of CIN in kidney transplant recipients (Figure 1). In fact, a direct comparison between these studies regarding the incidence

of CIN among is challenging, as the definition of AKI used was not uniform. There were differences in baseline serum creatinine; use of hyper-, hypo-, or iso-osmolar contrast; volume of contrast given; and the proportion of patients with known risk factors for CIN, including: Diabetes Mellitus, congestive heart failure, and concomitant use of CNI, in these studies which make it difficult to conclude the actual incidence of CIN in kidney transplant recipients.

To date, Haider *et al*^[9] (2015) study is considered the largest retrospective study evaluating the incidence of CIN in kidney transplantation. The incidence of CIN in this study was low (5.6%), much lower than reported by Ahuja *et al*^[10] (2000). Two fundamental factors were implicated in this low incidence of CIN in this landmark study first: the relatively elevated baseline eGFR (> 70 mL/min per 1.73 m²) and second: The use of "hypo-osmolar" contrast applied in this procedure^[9].

Another possible explanation for the low incidence of CIN in this study is that Diabetes Mellitus and hypertension in these patients may not have damaged the renal allograft to the extent to potentiate CIN. Another important factor is the age of the kidney rather than the age of recipient may affect the susceptibility for CIN. Furthermore, among all procedures utilizing iodine-based contrast, coronary angiography with the percutaneous intervention was responsible for 49% of cases of CIN^[13]. However in Haider *et al*^[9] (2015) work, only 4.8% of patients have had cardiac catheterization (none of them had CIN), and this might also have leading to low incidence of CIN-AKI in this group of patients. Their inability to identify association with known risk factors for CIN may be explained by the very small number of patients complicated by CIN events.

On the other hand, Fananapazir *et al*^[14], 2016, declared in the most recent trial that CIN incidence was very low,

Incidence of CIN after kidney transplant

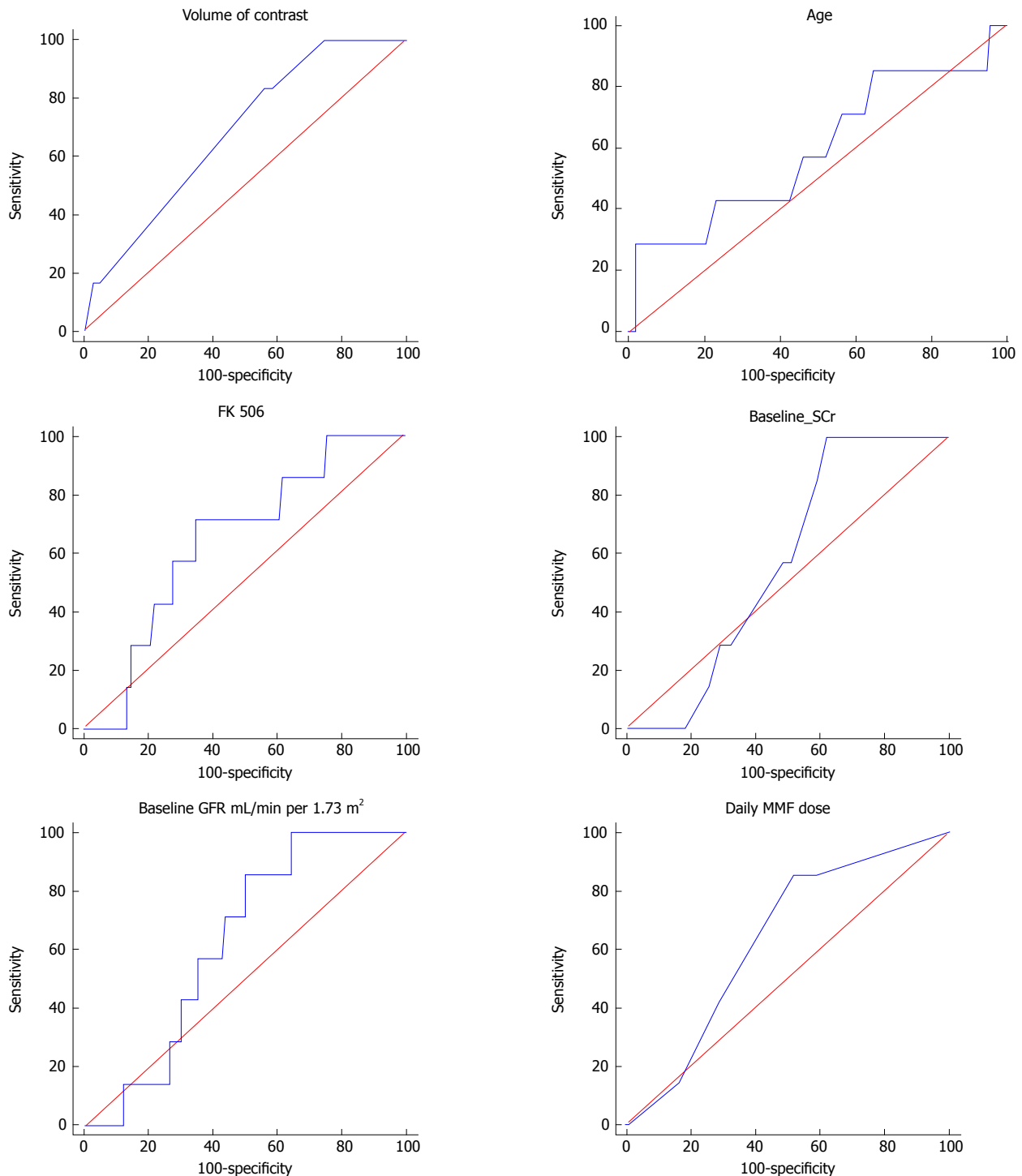


Figure 1 Receiver operating characteristics curves for age, FK506 levels, daily Cellcept dose, baseline Cr., eGFR, and volume of IV contrast. Area under the curve (AUC) for age, FK506 levels, daily Cellcept dose, baseline creatinine, eGFR, and volume of IV contrast were 0.60, 0.64, 0.63, 0.57, 0.63, and 0.68, respectively^[9]. Adapted from Haider *et al.*^[9], Incidence of Contrast-induced Nephropathy in Kidney Transplant Recipients. *Transplantation Proceedings* 2015; **47**: 2379-2383 (with permission). GFR: Glomerular filtration rate.

i.e., 7% and 3% according to an elevation of SCr of > 0.3 and 0.5 respectively, after a low osmolality contrast administration. There was with no need for emergent dialysis or an allograft loss 30 d post-operative^[14].

Moreover, Bostock *et al.*^[15] in 2016, also demonstrated that CIN following endovascular aortic aneurysm repair

(EVAR) in kidney transplant recipients could have de-ranging sequelae. The Vascular Quality Initiative (VQI) database was interrogated to select all kidney transplant recipients who underwent EVAR between 01/2003 and 12/2014. Their primary outcome was renal dysfunction, defined as AKI (rise in serum creatinine concentration

> 0.5 mg/dL above the baseline or new post-operative hemodialysis requirement). Within the EVAR VQI dataset, 40 subjects were kidney transplant recipients (40/17, 213, 0.2%). Renal dysfunction occurred in 5/40 patients in the kidney transplant recipients group in comparison to 779/17173 patients in the non-transplanted group (12.5% vs 4.5%, $P < 0.01$). Emergency EVAR was indicated in 2 (5%) patients who required hemodialysis after surgery and died later. One-year survival after EVAR was similar in both groups (92.9% vs 93.1%, $P = 0.73$). Kidney transplant recipients who developed renal dysfunction had significantly lower pre-operative eGFR's (29.5 vs 54.7, $P = 0.007$) and a significantly higher iodine/eGFR ratio (0.78 vs 0.39, $P = 0.02$) despite receiving a similar volume of contrast (70.0 vs 68.8, $P = 0.97$). Renal impairment was three times more frequent in kidney transplant recipients treated with EVAR, despite the overall survival did not differ between groups. Diminished pre-operative eGFR and a higher iodine/eGFR ratio were associated with post-operative renal dysfunction^[15]. Charnow *et al*^[16] 2015, showed an incidence about 13% of CIN in allograft recipients undergoing CT or cardiac catheterization with contrast media. CIN was relatively common in kidney transplant recipients undergoing (CT) or cardiac catheterization with contrast media. Charnow *et al*^[16] (2015) at the University of Cincinnati in Ohio studied 76 contrast exposures (45 CT scans and 31 catheterizations) in 50 kidney transplant recipients (50% male) with a mean age of 53.3 years and means. Cr level of 1.46 mg/dL. The investigators reported CIN - defined as a rise in s. Cr by > 0.3 mg/dL or 25% from baseline within 4 d. after the procedure - in 10 of 76 procedures (13.2%). Results demonstrated: 6 (13.3%) of the 45 CT scans and 4 (12.9%) of the 31 catheterizations resulted in CIN^[16].

Abu Jawdeh's group (2015)^[16] also examined the risk factors for CIN. In a multivariate model, exposure to N-acetylcysteine (NAC) and a lower hemoglobin level was significantly associated with an increased risk of CIN, but not with CNI use. They assumed that NAC might have been used in high-risk subjects for CIN, a bias that could explain the increased risk of CIN associated with NAC use. At the last follow-up, CIN did not affect allograft function and survival, according to the investigator^[16].

CIN is accompanied by a significant rise in mortality and morbidity; Abu Jawdeh suggested that extrapolation of knowledge about CIN affecting the native kidneys and applying this to allografts might not necessarily reflect the best practice. Allografts are solitary kidneys that exposed to significant hemodynamic alterations and also under the effect of lifelong immuno-suppressive agents. Both these factors might affect susceptibility to contrast-induced renal injury. They also suggested that CIN is potentially modifiable if risk factors are well identified and the proper preventive precautions are performed. The 13.3% incidence of CIN identified in this study is consistent with previous studies looking at native kidneys^[16]. Due to the retrospective nature of

this study and the small sample size, this study should be interpreted with caution.

Finally, it appears that the strict "definition of CIN" in various studies was not universal. While Charnow *et al*^[16] defined CIN as a rise in s. Cr by > 0.3 mg/dL or 25% rise from baseline within four days of contrast exposure, Bostock *et al*^[15] defined CIN as an AKI with elevation of SCr > 0.5 mg/dL from baseline, or new post-operative hemodialysis (HD) requirement%. Haider *et al*^[9] (2015) defined CIN as either an absolute rise in serum creatinine of ≥ 0.5 mg/dL or a $\geq 25\%$ drop in estimated glomerular filtration rate (eGFR) after contrast administration. On the other hand Fananapazir *et al*^[14] (2016) applied two definitions for CIN in the most recent study, they found CIN in 7% based on a rise of ≥ 0.3 mg/dL and 3% based on a rise of ≥ 0.5 mg/dL. Patients with the more strict definition (≥ 0.5 mg/dL) had a pre-contrast eGFR < 60 mL/min per 1.73 m².

"Ultrasound with contrast": Contrast enhanced ultrasound (CEUS) is a promising radiological technique with increased popularity. It has a superiority over the color Doppler ultrasound in evaluation of kidney microvasculature studies. A wide variety of diagnoses can be applied including differentiation of cystic from solid lesion, solid mass assessment, pseudotumor and RAS. Moreover, CEUS can help in elucidating the hemodynamic changes associated with chronic allograft nephropathy (CAN)^[17].

US contrasts are gas microbubbles of nearly the same size of RBCs, which enclosed in a protein, lipid or polymer shell^[18]. They last intravascular only for few minutes (time of CEUS examination), after that, the gas exhaled through the lungs and the shell metabolized by the liver^[19], so renal excretion is not a possibility. As these contrast agents is not excreted through the kidney, allograft integrity cannot be deranged. So, their use in KTRs with impaired renal function is completely safe. Furthermore, CEUS is the sole available technique for dynamic evaluation of kidney perfusion, particularly so, when the use of contrast media is mandatory in CT and MR studies in patients with renal dysfunction. CEUS has a wide safety margin in comparison with other radiological modalities^[20,21].

Prevention of CIN-induced AKI in the renal transplant recipient: There are no specific measures dedicated to prevent CIN-induced AKI in the renal allograft, but rather universal recommendations. The optimal recommendations for CIN prevention are still uncertain.

The following precautions are suggested with increased risk of CIN (S. creatinine ≥ 1.5 mg/dL (132 micromols/L) or an eGFR < 60 mL/1.73 m²), especially in diabetics: (1) Avoid volume depletion and NSAID^[22,23]; (2) Avoid use of high osmolar agents (1400-1800 mosmol/kg)^[24,25]; (3) Try to use US and MRI without gadolinium contrast, or CT scanning without contrast media when possible; (4) Choose iodixanol or nonionic low-osmolar

agents, *e.g.*, iopamidol or ioversol rather than iohexol^[25]; (5) Apply lower doses of contrast and avoid repetitive, closely spaced studies (< 48 h apart)^[12,13,15,16,25]; (6) In an absence of contraindications to volume expansion, start isotonic intravenous fluids before and continued several hours after contrast use. Optimal type and timing are not well documented. "Isotonic bicarbonate" is preferred to isotonic saline as a "volume expander"^[23,26-29]. "Isotonic bicarbonate" regimen: A bolus of 3 mL/kg for one hour prior to the procedure, and continued at a rate of 1 mL/kg per hour for "6" h after the procedure^[23,26-29]. Suggested regimen for isotonic saline: Isotonic saline (1 mL/kg per hour), starting at least 2-6 h before, and continued for 6-12 h after the procedure. Duration of intravenous fluid should be directly proportional to the degree of renal dysfunction (*i.e.*, longer duration for severe renal impairment); (7) Based upon potential benefit, low toxicity, and cost, Acetylcysteine (AC) can be given: 1200 mg orally twice/day, the day before and the day of the procedure. Intravenous AC is NOT recommended due to lack of evidence of benefit and potential risk of anaphylactoid reactions^[30,31]; and (8) Prophylactic use of "mannitol" or other diuretics is NOT recommended^[32,33]. Prophylactic HF/HDX after contrast exposure is NOT advised on stage 3 and 4 CKD^[34].

Oral contrasts

Two documented contrast media are already in use for oral imaging procedures: First: Barium sulphate, a commonly used oral contrast agent (for GI studies); Second: Gastrografin, which is a substitute agent for the barium in special situations. Generally, barium, as well as gastrografin, is safe, passing through the gastrointestinal tract easily like food and drink^[35].

Barium sulphate is by far the most common contrast material used orally. It can also be utilized rectally. Multiple forms are available, including powder, liquid, paste and tablets. They are generally safe. Only mild unpleasant taste can be observed. If given by enema, abdominal fullness, change in bowel habits and whitish discoloration may be observed for only a few days^[36].

Nephrostogram

A nephrostogram is a radiological tool performed to check the nephrostomy catheter and to rule out any abnormalities in the kidney and ureters, for example, obstructive uropathy. It is performed by disconnecting the catheter from its drainage bag and injecting the iodinated contrast through its lumen, monitored with fluoroscopy and static X-ray imaging. Nephrostogram is a very safe technique with few documented complications. Only mild pain with the possibility of the introduction of infection can occur. Unfortunately, this procedure has no known alternative technique^[37].

CONCLUSION

The risk of CIN affecting renal allograft function is

significant especially in diabetics, old age and in volume depleted subjects. This risk can be greatly mitigated through optimizing the hydration status in peri-procedure period, by avoiding nephrotoxic medications, by careful use of safe and widely spaced contrast media with the possible minimal amount of contrast media and possibly by prophylactic peri-procedural administration of isotonic bicarbonate. Some of the questions remain unanswered that require randomized controlled trials involving larger number of renal transplant recipients in order to maximize safety of the renal allograft.

REFERENCES

- Noce A, Iaria G, Durante O, Sforza D, Canale MP, Di Villahermosa SM, Castagnola V, Tisone G, Di Daniele N. Bilateral native kidney neoplasia detected by ultrasound in functioning renal allograft recipient. *Arch Ital Urol Androl* 2012; **84**: 253-255 [PMID: 23427757]
- Quintela J, Aguirrezabalaga J, Alonso A, Fernandez C, Corbal G, Gomez M. Portal and systemic venous drainage in pancreas and kidney-pancreas transplantation: early surgical complications and outcomes. *Transplant Proc* 2009; **41**: 2460-2462 [PMID: 19715951 DOI: 10.1016/j.transproceed.2009.06.046]
- Grottemeyer D, Voiculescu A, Iskandar F, Voshege M, Blondin D, Balzer KM, Rump LC, Sandmann W. Renal cysts in living donor kidney transplantation: long-term follow-up in 25 patients. *Transplant Proc* 2009; **41**: 4047-4051 [PMID: 20005339 DOI: 10.1016/j.transproceed.2009.09.077]
- Sinha R, Saad A, Marks SD. Prevalence and complications of chronic kidney disease in paediatric renal transplantation: a K/DOQI perspective. *Nephrol Dial Transplant* 2010; **25**: 1313-1320 [PMID: 19926719 DOI: 10.1093/ndt/gfp600]
- Smith KM, Windsperger A, Alane S, Humar A, Kashtan C, Shukla AR. Risk factors and treatment success for ureteral obstruction after pediatric renal transplantation. *J Urol* 2010; **183**: 317-322 [PMID: 19914663 DOI: 10.1016/j.juro.2009.09.003]
- Goyen M, Debatin JF. Gadopentetate dimeglumine-enhanced three-dimensional MR-angiography: dosing, safety, and efficacy. *J Magn Reson Imaging* 2004; **19**: 261-273 [PMID: 14994293 DOI: 10.1002/jmri.20005]
- Bansal R, Batuman V, Kaplan AA, Aglieco F. Contrast-Induced Nephropathy. *Med Pup*, Jan 18, 2016. Available from: URL: <http://emedicine.medscape.com/article/246751-overview>
- Light JA, Perloff LJ, Etheredge EE, Hill G, Spees EK. Adverse effects of meglumine diatrizoate on renal function in the early post-transplant period. *Transplantation* 1975; **20**: 404-409 [PMID: 1108314 DOI: 10.1097/00007890-197511000-00008]
- Haider M, Yessayan L, Venkat KK, Goggins M, Patel A, Karthikeyan V. Incidence of contrast-induced nephropathy in kidney transplant recipients. *Transplant Proc* 2015; **47**: 379-383 [PMID: 25769577 DOI: 10.1016/j.transproceed.2015.01.008]
- Ahuja TS, Niaz N, Agraharkar M. Contrast-induced nephrotoxicity in renal allograft recipients. *Clin Nephrol* 2000; **54**: 11-14 [PMID: 10939751]
- Peters C, Delmonico FL, Cosimi AB, Rubin RH, Tolkoff-Rubin N, Baker G, Russell PS. Risks versus benefits of contrast medium exposure in renal allograft recipients. *Surg Gynecol Obstet* 1983; **156**: 467-472 [PMID: 6340225]
- Moreau JF, Kreis H, Barbanel CI, Michel JR. [Effects of iodine contrast medias on the function of transplanted kidneys]. *Nouv Presse Med* 1975; **4**: 2643-2646 [PMID: 1105419]
- Nash K, Hafeez A, Hou S. Hospital-acquired renal insufficiency. *Am J Kidney Dis* 2002; **39**: 930-936 [PMID: 11979336 DOI: 10.1053/ajkd.2002.32766]
- Fananapazir G, Troppmann C, Corwin MT, Nikpour AM, Naderi S, Lamba R. Incidences of acute kidney injury, dialysis, and graft loss following intravenous administration of low-osmolality iodinated

- contrast in patients with kidney transplants. *Abdom Radiol* (NY) 2016; 41: 2182-2186 [PMID: 27377897 DOI: 10.1007/s00261-016-0827-3]
- 15 **Bostock IC**, Zarkowsky DS, Hicks CW, Stone DH, Eslami MH, Malas MB, Goodney PP. Outcomes of Endovascular Aortic Aneurysm Repair in Kidney Transplant Recipients: Results From a National Quality Initiative. *Am J Transplant* 2016; **16**: 2395-2400 [PMID: 26813253 DOI: 10.1111/ajt.13733]
- 16 **Charnow JA**, Jawdeh BGA. Contrast-Induced Nephropathy in Kidney transplantation patients Characterized. USA: Renal & Urology News, 2015
- 17 **Schwenger V**, Korosoglou G, Hinkel UP, Morath C, Hansen A, Sommerer C, Dikow R, Hardt S, Schmidt J, Kücherer H, Katus HA, Zeier M. Real-time contrast-enhanced sonography of renal transplant recipients predicts chronic allograft nephropathy. *Am J Transplant* 2006; **6**: 609-615 [PMID: 16468973 DOI: 10.1111/j.1600-6143.2005.01224.x]
- 18 **Morin SH**, Lim AK, Cobbold JF, Taylor-Robinson SD. Use of second generation contrast-enhanced ultrasound in the assessment of focal liver lesions. *World J Gastroenterol* 2007; **13**: 5963-5970 [PMID: 18023084 DOI: 10.3748/wjg.13.5963]
- 19 **Cosgrove D**, Blomley M. Liver tumors: evaluation with contrast-enhanced ultrasound. *Abdom Imaging* 2004; **29**: 446-454 [PMID: 14716451 DOI: 10.1007/s00261-003-0126-7]
- 20 **Wilson SR**, Burns PN. Microbubble-enhanced US in body imaging: what role? *Radiology* 2010; **257**: 24-39 [PMID: 20851938 DOI: 10.1148/radiol.10091210]
- 21 **Piscaglia F**, Bolondi L. The safety of Sonovue in abdominal applications: retrospective analysis of 23188 investigations. *Ultrasound Med Biol* 2006; **32**: 1369-1375 [PMID: 16965977 DOI: 10.1016/j.ultrasmedbio.2006.05.031]
- 22 **Pannu N**, Wiebe N, Tonelli M. Prophylaxis strategies for contrast-induced nephropathy. *JAMA* 2006; **295**: 2765-2779 [PMID: 16788132 DOI: 10.1001/jama.295.23.2765]
- 23 **Marenzi G**, Assanelli E, Campodonico J, Lauri G, Marana I, De Metrio M, Moltrasio M, Grazi M, Rubino M, Veglia F, Fabbicocchi F, Bartorelli AL. Contrast volume during primary percutaneous coronary intervention and subsequent contrast-induced nephropathy and mortality. *Ann Intern Med* 2009; **150**: 170-177 [PMID: 19189906 DOI: 10.7326/0003-4819-150-3-200902030-00006]
- 24 **Kian K**, Wyatt C, Schon D, Packer J, Vassalotti J, Mishler R. Safety of low-dose radiocontrast for interventional AV fistula salvage in stage 4 chronic kidney disease patients. *Kidney Int* 2006; **69**: 1444-1449 [PMID: 16508655 DOI: 10.1038/sj.ki.5000276]
- 25 **Lautin EM**, Freeman NJ, Schoenfeld AH, Bakal CW, Haramati N, Friedman AC, Lautin JL, Braha S, Kadish EG. Radiocontrast-associated renal dysfunction: a comparison of lower-osmolality and conventional high-osmolality contrast media. *AJR Am J Roentgenol* 1991; **157**: 59-65 [PMID: 2048540 DOI: 10.2214/ajr.157.1.2048540]
- 26 **Rudnick MR**, Goldfarb S, Wexler L, Ludbrook PA, Murphy MJ, Halpern EF, Hill JA, Winniford M, Cohen MB, VanFossen DB. Nephrotoxicity of ionic and nonionic contrast media in 1196 patients: a randomized trial. The Iohexol Cooperative Study. *Kidney Int* 1995; **47**: 254-261 [PMID: 7731155 DOI: 10.1038/ki.1995.32]
- 27 **Cigarroa RG**, Lange RA, Williams RH, Hillis LD. Dosing of contrast material to prevent contrast nephropathy in patients with renal disease. *Am J Med* 1989; **86**: 649-652 [PMID: 2729314 DOI: 10.1016/0002-9343(89)90437-3]
- 28 **Manske CL**, Sprafka JM, Strony JT, Wang Y. Contrast nephropathy in azotemic diabetic patients undergoing coronary angiography. *Am J Med* 1990; **89**: 615-620 [PMID: 2239981 DOI: 10.1016/0002-9343(90)90180-L]
- 29 **McCullough PA**, Wolyn R, Rocher LL, Levin RN, O'Neill WW. Acute renal failure after coronary intervention: incidence, risk factors, and relationship to mortality. *Am J Med* 1997; **103**: 368-375 [PMID: 9375704 DOI: 10.1016/S0002-9343(97)00150-2]
- 30 **Merten GJ**, Burgess WP, Gray LV, Holleman JH, Roush TS, Kowalchuk GJ, Bersin RM, Van Moore A, Simonton CA, Rittase RA, Norton HJ, Kennedy TP. Prevention of contrast-induced nephropathy with sodium bicarbonate: a randomized controlled trial. *JAMA* 2004; **291**: 2328-2334 [PMID: 15150204 DOI: 10.1001/jama.291.19.2328]
- 31 **Briguori C**, Airolidi F, D'Andrea D, Bonizzi E, Morici N, Focaccio A, Michev I, Montorfano M, Carlino M, Cosgrave J, Ricciardelli B, Colombo A. Renal Insufficiency Following Contrast Media Administration Trial (REMEDIAT): a randomized comparison of 3 preventive strategies. *Circulation* 2007; **115**: 1211-1217 [PMID: 17309916 DOI: 10.1016/j.jvs.2007.10.028]
- 32 **Recio-Mayoral A**, Chaparro M, Prado B, Cózar R, Méndez I, Banerjee D, Kaski JC, Cubero J, Cruz JM. The reno-protective effect of hydration with sodium bicarbonate plus N-acetylcysteine in patients undergoing emergency percutaneous coronary intervention: the RENO Study. *J Am Coll Cardiol* 2007; **49**: 1283-1288 [PMID: 17394959 DOI: 10.1016/j.jacc.2006.11.034]
- 33 **Ozcan EE**, Guneri S, Akdeniz B, Akyildiz IZ, Senaslan O, Baris N, Aslan O, Badak O. Sodium bicarbonate, N-acetylcysteine, and saline for prevention of radiocontrast-induced nephropathy. A comparison of 3 regimens for protecting contrast-induced nephropathy in patients undergoing coronary procedures. A single-center prospective controlled trial. *Am Heart J* 2007; **154**: 539-544 [PMID: 17719303 DOI: 10.1016/j.ahj.2007.05.012]
- 34 **Hoste EA**, De Waele JJ, Gevaert SA, Uchino S, Kellum JA. Sodium bicarbonate for prevention of contrast-induced acute kidney injury: a systematic review and meta-analysis. *Nephrol Dial Transplant* 2010; **25**: 747-758 [PMID: 19703838 DOI: 10.1093/ndt/gfp389]
- 35 Information about intravenous and oral contrast used in CT. Available from: URL: <http://www.imaginis.com/ct-scan/information-about-intravenous-and-oral-contrast-used-in-ct-1>
- 36 Radiologyinfo.org for patients. Available from: URL: <http://www.radiologyinfo.org>
- 37 **Stockport NHS**. Available from: URL: <http://www.stockport.nhs.uk/>

P- Reviewer: Hu XP, Sheashaa HA, Tanaka A **S- Editor:** Ji FF

L- Editor: A **E- Editor:** Lu YJ





Published by **Baishideng Publishing Group Inc**

8226 Regency Drive, Pleasanton, CA 94588, USA

Telephone: +1-925-223-8242

Fax: +1-925-223-8243

E-mail: bpgoffice@wjgnet.com

Help Desk: <http://www.wjgnet.com/esps/helpdesk.aspx>

<http://www.wjgnet.com>

