

World Journal of *Gastrointestinal Endoscopy*

World J Gastrointest Endosc 2017 April 16; 9(4): 149-203



EDITORIAL

- 149 Laparoscopic surgery for complex and recurrent Crohn's disease
Sevim Y, Akyol C, Aytac E, Baca B, Bulut O, Remzi FH

MINIREVIEWS

- 153 Non-functioning pancreatic neuroendocrine tumors: Surgery or observation?
Bar-Moshe Y, Mazeh H, Grozinsky-Glasberg S

ORIGINAL ARTICLE

Case Control Study

- 162 Comparative study of outcomes following laparoscopic Roux-en-Y gastric bypass and sleeve gastrectomy in morbidly obese patients: A case control study
Garg H, Priyadarshini P, Aggarwal S, Agarwal S, Chaudhary R

Retrospective Cohort Study

- 171 Does serotonin reuptake inhibitor therapy increase the risk of post-sphincterotomy bleeding in patients undergoing endoscopic retrograde cholangio-pancreatography?
Yadav D, Vargo J, Lopez R, Chahal P

Retrospective Study

- 177 Does deep sedation with propofol affect adenoma detection rates in average risk screening colonoscopy exams?
Thirumurthi S, Raju GS, Pande M, Ruiz J, Carlson R, Hagan KB, Lee JH, Ross WA

- 183 Endoscopic balloon catheter dilatation *via* retrograde or static technique is safe and effective for cricopharyngeal dysfunction
Chandrasekhara V, Koh J, Lattimer L, Dunbar KB, Ravich WJ, Clarke JO

- 189 Analysis of the risk factors for severity in post endoscopic retrograde cholangiopancreatography pancreatitis: The indication of prophylactic treatments
Matsubara H, Urano F, Kinoshita Y, Okamura S, Kawashima H, Goto H, Hirooka Y

Observational Study

- 196 Endoscopic assessment and management of sporadic duodenal adenomas: The results of single centre multidisciplinary management
Rajkomar K, Kweon M, Khan I, Frankish P, Rodgers M, Koea JB

Contents

World Journal of Gastrointestinal Endoscopy
Volume 9 Number 4 April 16, 2017

ABOUT COVER

Editorial Board Member of *World Journal of Gastrointestinal Endoscopy*, Andreas Sieg, MD, PhD, Assistant Professor, Department of Gastroenterology, Practice of Gastroenterology, 69115 Heidelberg, Germany

AIM AND SCOPE

World Journal of Gastrointestinal Endoscopy (*World J Gastrointest Endosc*, *WJGE*, online ISSN 1948-5190, DOI: 10.4253) is a peer-reviewed open access (OA) academic journal that aims to guide clinical practice and improve diagnostic and therapeutic skills of clinicians.

WJGE covers topics concerning gastroscopy, intestinal endoscopy, colonoscopy, capsule endoscopy, laparoscopy, interventional diagnosis and therapy, as well as advances in technology. Emphasis is placed on the clinical practice of treating gastrointestinal diseases with or under endoscopy.

We encourage authors to submit their manuscripts to *WJGE*. We will give priority to manuscripts that are supported by major national and international foundations and those that are of great clinical significance.

INDEXING/ABSTRACTING

World Journal of Gastrointestinal Endoscopy is now indexed in Emerging Sources Citation Index (Web of Science), PubMed, and PubMed Central.

FLYLEAF

I-III Editorial Board

EDITORS FOR THIS ISSUE

Responsible Assistant Editor: *Xiang Li*
Responsible Electronic Editor: *Huan-Liang Wu*
Proofing Editor-in-Chief: *Lian-Sheng Ma*

Responsible Science Editor: *Jin-Xin Kong*
Proofing Editorial Office Director: *Xiu-Xia Song*

NAME OF JOURNAL
World Journal of Gastrointestinal Endoscopy

ISSN
ISSN 1948-5190 (online)

LAUNCH DATE
October 15, 2009

FREQUENCY
Monthly

EDITORS-IN-CHIEF
Atsushi Imagawa, PhD, Director, Doctor, Department of Gastroenterology, Mitoyo General Hospital, Kan-onji, Kagawa 769-1695, Japan

Juan Manuel Herrerias Gutierrez, PhD, Academic Fellow, Chief Doctor, Professor, Unidad de Gestión Clínica de Aparato Digestivo, Hospital Universitario Virgen Macarena, Sevilla 41009, Sevilla, Spain

EDITORIAL BOARD MEMBERS
All editorial board members resources online at <http://www.wjgnet.com>

www.wjgnet.com/1948-5190/editorialboard.htm

EDITORIAL OFFICE
Xiu-Xia Song, Director
World Journal of Gastrointestinal Endoscopy
Baishideng Publishing Group Inc
8226 Regency Drive, Pleasanton, CA 94588, USA
Telephone: +1-925-2238242
Fax: +1-925-2238243
E-mail: editorialoffice@wjgnet.com
Help Desk: <http://www.f6publishing.com/helpdesk>
<http://www.wjgnet.com>

PUBLISHER
Baishideng Publishing Group Inc
8226 Regency Drive,
Pleasanton, CA 94588, USA
Telephone: +1-925-2238242
Fax: +1-925-2238243
E-mail: bpgoffice@wjgnet.com
Help Desk: <http://www.f6publishing.com/helpdesk>
<http://www.wjgnet.com>

PUBLICATION DATE
April 16, 2017

COPYRIGHT
© 2017 Baishideng Publishing Group Inc. Articles published by this Open-Access journal are distributed under the terms of the Creative Commons Attribution Non-commercial License, which permits use, distribution, and reproduction in any medium, provided the original work is properly cited, the use is non commercial and is otherwise in compliance with the license.

SPECIAL STATEMENT
All articles published in journals owned by the Baishideng Publishing Group (BPG) represent the views and opinions of their authors, and not the views, opinions or policies of the BPG, except where otherwise explicitly indicated.

INSTRUCTIONS TO AUTHORS
<http://www.wjgnet.com/bpg/gerinfo/204>

ONLINE SUBMISSION
<http://www.f6publishing.com>

Observational Study

Endoscopic assessment and management of sporadic duodenal adenomas: The results of single centre multidisciplinary management

Kheman Rajkomar, Michelle Kweon, Imran Khan, Paul Frankish, Michael Rodgers, Jonathan B Koea

Kheman Rajkomar, Michelle Kweon, Michael Rodgers, Jonathan B Koea, the Department of Surgery, North Shore Hospital, Private Bag 93503, Takapuna, Auckland, New Zealand

Imran Khan, Paul Frankish, the Department of Gastroenterology, North Shore Hospital, Private Bag 93503, Takapuna, Auckland, New Zealand

Author contributions: All authors were involved in the design, analysis and interpretation of the study results as well as manuscript preparation and review; Rajkomar K and Khan I were also involved in data acquisition.

Institutional review board statement: This investigation was reviewed and approved by the Awhina Health and Knowledge Centre, North Shore Hospital, Auckland, New Zealand.

Informed consent statement: All study participants provided written informed consent prior to study enrolment.

Conflict-of-interest statement: None to declare.

Data sharing statement: No additional data are available.

Open-Access: This article is an open-access article which was selected by an in-house editor and fully peer-reviewed by external reviewers. It is distributed in accordance with the Creative Commons Attribution Non Commercial (CC BY-NC 4.0) license, which permits others to distribute, remix, adapt, build upon this work non-commercially, and license their derivative works on different terms, provided the original work is properly cited and the use is non-commercial. See: <http://creativecommons.org/licenses/by-nc/4.0/>

Manuscript source: Invited manuscript

Correspondence to: Dr. Jonathan B Koea, Chief of Upper gastrointestinal Unit, the Department of Surgery, North Shore Hospital, Private Bag 93503, Takapuna, Auckland, New Zealand. jonathan.koea@waitemataadhb.govt.nz
Telephone: +64-9-4868900
Fax: +64-9-4884621

Received: July 23, 2016

Peer-review started: July 26, 2016

First decision: September 29, 2016

Revised: January 22, 2017

Accepted: February 28, 2017

Article in press: March 1, 2017

Published online: April 16, 2017

Abstract

AIM

To review the role of multidisciplinary management in treating sporadic duodenal adenomas (SDA).

METHODS

SDA managed at North Shore Hospital between 2009-2014 were entered into a prospective database. Pathology, endoscopic and surgical management as well as follow up were reviewed.

RESULTS

Twenty-eight patients (14 male: Median age 68 years) presented with SDA [18 were classified as non ampullary location (NA), 10 as ampullary location (A)]. All SDA were diagnosed on upper gastrointestinal endoscopy and were imaged with a contrast enhanced CT scan of the chest, abdomen and pelvis. Of the NA adenomas 14 were located in the second part, 2 in the first part and 2 in the third part of the duodenum. Two patients declined treatment, 3 patients underwent surgical resection (2 transduodenal resections and 1 pancreaticoduodenectomy), and 23 patients were treated with endoscopic mucosal resection (EMR). The only complication with endoscopic resection was mild pancreatitis post procedure. Patients were followed with gastroduodenoscopy for a median of 22 mo (range: 2-69 mo). There were 8 recurrences treated with EMR with one

patient proceeding to pancreaticoduodenectomy because of high grade dysplasia in the resected specimen and 2 NA recurrences were managed with surgical resection (distal gastrectomy for a lesion in the first part of the duodenum and a transduodenal resection of a lesion in the third part of the duodenum).

CONCLUSION

SDA can be treated endoscopically with minimal morbidity and piecemeal resection results in eradication in nearly three quarters of patients. Recurrent SDA can be treated with endoscopic resection with surgical resection indicated when the lesions are large (> 4 cm in diameter) or demonstrate severe dysplasia or invasive cancer.

Key words: Duodenal adenoma; Endoscopic resection; Surgical resection; Pancreaticoduodenectomy; Endoscopic surveillance; Dysplasia

© The Author(s) 2017. Published by Baishideng Publishing Group Inc. All rights reserved.

Core tip: Sporadic duodenal adenomas can be treated endoscopically with minimal morbidity and even piecemeal resection results in eradication in nearly three quarters of patients. Optimal surveillance strategies include re-endoscopy 6 mo after the initial resection is a satisfactory starting point. Recurrent sporadic adenomas can be treated with endoscopic re-resection with surgical resection indicated when the lesions are large (> 3 cm in diameter) or demonstrate severe dysplasia or invasive cancer.

Rajkomar K, Kweon M, Khan I, Frankish P, Rodgers M, Koea JB. Endoscopic assessment and management of sporadic duodenal adenomas: The results of single centre multidisciplinary management. *World J Gastrointest Endosc* 2017; 9(4): 196-203 Available from: URL: <http://www.wjgnet.com/1948-5190/full/v9/i4/196.htm> DOI: <http://dx.doi.org/10.4253/wjge.v9.i4.196>

INTRODUCTION

Sporadic duodenal adenomas (SDA) are rare lesions with a prevalence of 0.3%-1.5%^[1]. Due to this rarity, the natural history of SDA is not well understood although it is known to follow an adenoma to carcinoma sequence similar to colorectal cancer^[2]. The reported rate of malignant transformation of SDA ranges from 25% to 85% and this provides a rationale for preventative intervention and surveillance^[2-4]. The majority of sporadic adenomas are sessile and occur in the second part of the duodenum^[5,6] and can be divided into those with an ampullary location (A) or non ampullary location (NA)^[1,2].

Currently there is no consensus on the optimal management of SDA and, in particular, the choice of surgical or endoscopic resection remains controversial since surgical resection involves either

local resection by the transduodenal approach or by pancreaticoduodenectomy with the risk of significant morbidity and mortality. In contrast endoscopic mucosal resection (EMR) was first described in 1992 and has become increasingly favoured as the first line treatment modality^[6-8].

This investigation describes the multidisciplinary management strategy for SDA as used at a single unit and involves contributions from surgery, endoscopy and gastroenterology. The specific aims of this study were to: (1) define the role of EMR of SDA; (2) define the role of whole vs piece meal endoscopic resection; (3) define an optimal surveillance strategy following endoscopic resection; and (4) define the optimal treatment for recurrence SDA following endoscopic resection.

MATERIALS AND METHODS

Consecutive cases of duodenal adenoma diagnosed at North Shore Hospital (NSH) between 2009 and 2014 were reviewed. The pathology findings from all patients was entered into a prospective database. Demographic, diagnostic, biopsy, treatment and follow up information was then reviewed as well as details pertaining to local recurrence rate and salvage treatments.

This project was logged with the Awhina Research and Knowledge Centre at NSH and ethics approval was obtained from the Regional Ethics Committee.

RESULTS

Thirty-four patients were diagnosed with duodenal adenomas between 2009 and 2014 of which six patients were excluded because of an underlying diagnosis of familial adenomatous polyposis. Data from 28 patients was analysed for the investigation of whom 18 were classified as NA and 10 as A.

Demographics, presentation and investigation

A summary of patient demographics, polyp morphology and investigations utilized in the management of the reported patients with SDA are presented in Table 1. All patients were New Zealand European with no Maori or Pacific Island patients presenting with SDA. Five patients (50%) with ampullary lesions presented with adenoma specific symptoms (iron deficiency anaemia 3, obstructive jaundice 2), while five (28%) of the NA patients presented with iron deficiency anaemia. The remaining patients with ampullary lesions underwent investigation for non-specific abdominal pain or following an incidental finding on ERCP for choledocolithiasis. In patients with NA upper gastrointestinal endoscopy was also undertaken for non-specific pain (4 patients), peptic ulcer disease or reflux (4 patients), and one patient each for globus, dysphagia, incidental finding during ERCP and investigation of Crohn's disease and incidentally noted raised carcino-embryonic antigen. All SDA were diagnosed on upper gastrointestinal endoscopy and were biopsied (Table 1). All patients

Table 1 Summary of patient demographics, adenoma morphology and investigations utilized *n* (%)

	Non-ampullary (<i>n</i> = 18)	Ampullary (<i>n</i> = 10)
Demographics		
Median age, yr (range)	69 (47-88)	67 (48-80)
Male: female	9:9	5:5
Morphology		
Pedunculated	3 (17)	1 (10)
Sessile	15 (83)	9 (90)
Median size, mm (range)	15 (9-24)	20 (10-35)
Number ≥ 20 mm	7 (39)	6 (60)
Investigations		
Biopsy	7 (39)	8 (80)
EUS	3 (17)	0
ERCP	0	10 (100)

ERCP: Endoscopic retrograde cholangiopancreatography; EUS: Endoscopic ultrasound.

were imaged with a contrast enhanced CT scan of the abdomen to define signs of invasion or metastases. Of the non-ampullary adenomas 14 were located in the second part of the duodenum, two in the first part and two in the third part of the duodenum. Endoscopic ultrasound (EUS) was used selectively to locoregionally stage lesions that were large, ulcerated or had high grade dysplasia on biopsy (5 of 8 ampullary adenomas and 8 of 15 non-ampullary adenomas). EUS permitted detailed assessment of lesional size and depth and location of further biopsy specimens^[4,5,7].

Treatment

Patient management is summarised in Figure 1 and Table 2. All endoscopically treated patients had an EMR. All endoscopic procedures were undertaken in a specialist endoscopy suite with conscious sedation administered intravenously followed by recovery and same day discharge. Endoscopic resection was undertaken after submucosal injection of saline, epinephrine or methylene blue depending on the endoscopist's preference. The median number of endoresections per patient was 1 and was higher for ampullary (median 2.5) than non-ampullary adenomas (median 1). Endoscopic *en bloc* resection was aimed for in all cases but, due to the size of the lesions, 11 NA and 6 A underwent piecemeal resection (Table 2). The only complication of endoscopic resection was one episode of mild pancreatitis post-procedure which was self-limiting.

Once removed specimens were orientated and sent for pathological examination. Overall biopsies were concordant with final pathology in 4 of 7 NA and 7 of 8 A (Table 2).

Two non-ampullary adenomas underwent surgical resection: Two patients underwent transduodenal resection of lesions in the second and third parts of the duodenum and one patient with a large ampullary adenoma, was treated with a pancreaticoduodenectomy. In addition, two elderly patients declined any treatment.

Table 2 Summary of treatment, biopsy and final pathology and recurrence

	Non-ampullary (<i>n</i> = 18)	Ampullary (<i>n</i> = 10)
Endoscopic treatment	15	8
Stenting		
Biliary	0	2
Pancreatic	0	5
Specimen removal		
Piecemeal	11	6
<i>En bloc</i>	4	2
Complications	0	1
Surgical resection	2	1
No treatment	1	1
Histology		
	1 no dysplasia 13 low grade dysplasia 3 high grade dysplasia	7 low grade dysplasia 1 high grade dysplasia 1 adenocarcinoma
Concordance with biopsy	4/7	7/8
Recurrence	5	5

Surveillance

All patients had follow up gastroscopies although five patients declined follow up and one patient had undergone a pancreaticoduodenectomy (*n* = 1). The average time taken for the first endoscopic surveillance post resection was 7.9 mo for NA and 5.9 mo for A. The median follow up period was 22 mo (range 2-69 mo).

Recurrence

Details on recurrence rate in the 20 cases actively followed up are presented in Table 3 in addition to salvage therapy employed. EMR was used to treat 8 recurrences. Endoscopic ultrasound was used in two ampullary recurrences to rule out transmural invasion. One of eight patients treated with endoscopic resection was shown to be a high grade dysplastic lesion and was subsequently treated with a pancreaticoduodenectomy (final pathology T₁N₀ adenocarcinoma). Two non-ampullary recurrences were managed with surgical resection (distal gastrectomy for a lesion in the first part of the duodenum and a transduodenal resection of a lesion in the third part of the duodenum).

DISCUSSION

This investigation was undertaken to review multidisciplinary management of SDA and confirms that the majority of SDA are not symptomatic and are found incidentally^[6-9]. Endoscopically SDA tend to be large, sessile and located in the second part of the duodenum^[6,10-13] and this series also confirms that most SDA harbour dysplasia^[14-19]. Kim *et al.*^[13] found that all of their 17 non ampullary adenomas were dysplastic while a larger series from Japan^[14] demonstrated that dysplasia was presented in all 233 non-ampullary adenomas assessed. The rate of low grade dysplasia

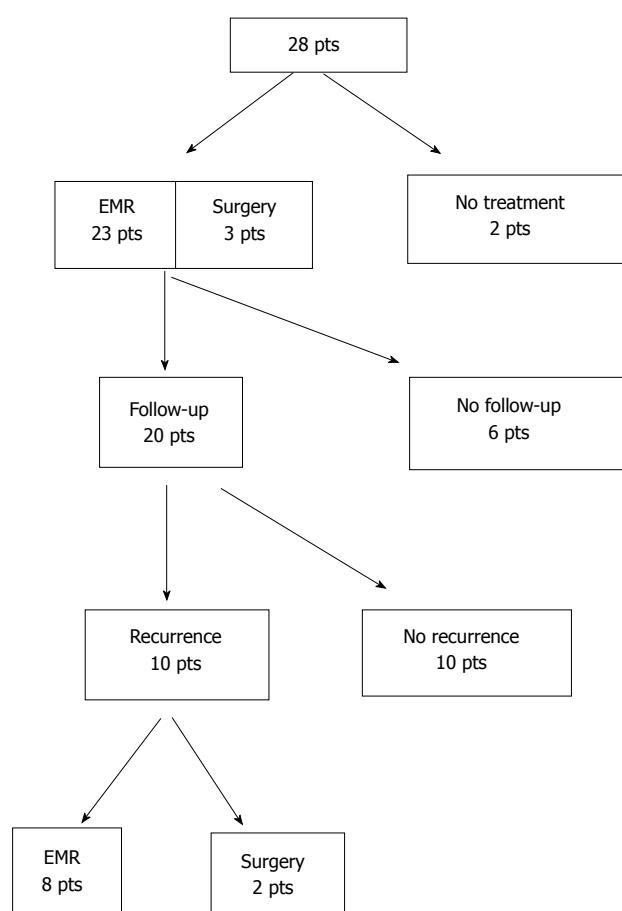


Figure 1 Summary of treatment of ampullary and non-ampullary adenomas. EMR: Endoscopic mucosal resection.

in non-ampullary adenomas in our series was 73.3%, which was within range (52%-84%) of recently published series^[13-15,19], while the rate of low grade dysplasia in our ampullary adenomas (78%) was higher than 53%-66% previously reported^[16-18]. The processes responsible for the high rates of dysplasia in SDA are not clear however Rubio^[19] suggested that the duodenum of those patients may exhibit gastric duodenal metaplasia and bile acids and pancreatic juices may provide a milieu that encourages the metaplasia to proceed onto the adenoma-carcinoma sequence. It is possible that SDA progress to dysplasia faster than other adenomas in the gastrointestinal tract^[19].

Strategy for investigations

The variable investigations performed during patient workup is a reflection of the lack of guidelines available in managing this rare entity.

Role of biopsy: There are no clear guidelines regarding the absolute need to biopsy all lesions and therefore the decision is often left to the discretion of the endoscopist. However a pre resection biopsy for SDAs may compromise a subsequent safe "lift off" technique of EMR and may increase the risk of perforation especially in the setting of a thin duodenal wall or a large duodenal

Table 3 Comparison of characteristics of recurrences (*n* = 10) vs no recurrence (*n* = 10)

	Recurrence (<i>n</i> = 10)	No recurrence (<i>n</i> = 10)
Non-ampullary/ ampullary	5:5	7:3
Median size (mm)	20 mm	10 mm
Treatment		
Endoscopic resection	10	8
Surgical resection	0	2
Specimen retrieval		
Piecemeal	8	6
<i>En bloc</i>	2	4
Margin positivity	9 (90%)	6 (60%)
Salvage therapy		
Endoscopic resection	8	
Surgical resection	2	

tumour. Moreover morphological changes after biopsy may give the false impression of submucosal infiltration of a superficial lesion^[20,21]. The American Society for Gastrointestinal Endoscopy (ASGE) guidelines suggests that all suspicious lesions should be biopsied^[22]. Although biopsy concordance with final pathology is commonly around 75%, as in this investigation^[23-25], and the non-concordant biopsies usually fail to sample a small focus of malignancy within the SDA particularly ampullary adenomas^[26]. Elek suggests taking large, multiple biopsies (up to 6) or doing papillectomies to improve the diagnostic yield^[27].

Role of EUS: We pursued a selective policy of EUS prior to resection to define invasion or pancreatic ductal involvement in large SDA that were suspicious (large size, ulceration or the presence of high grade dysplasia on biopsy)^[8,27-29]. However SDA size is a variable determinant of high grade dysplasia or malignant change with authors quoting a size > 10 mm^[30], > 20 mm^[8,27,28,31], and > 30 mm^[29]. ASGE guidelines suggest the use of EUS in lesions > 2 cm in non-ampullary and > 1 cm in ampullary adenoma^[22]. Currently the role of intraductal ultrasound is not well defined. Menzel *et al*^[32] suggested it was more useful than EUS in tumour diagnosis but a recent prospective study suggested that it could overstage tumours^[33].

Role of ERCP: This is the least controversial investigational tool for ampullary adenomas and was performed in all our patients since it provides an accurate means of assessing ductal involvement^[34-36].

Treatment

Most of the SDAs were resected endoscopically, which is in line with contemporary management^[37].

Role for EMR: The factors affecting the suitability for a lesion to undergo endoscopic resection include size, presence of malignant signs, extension along the wall

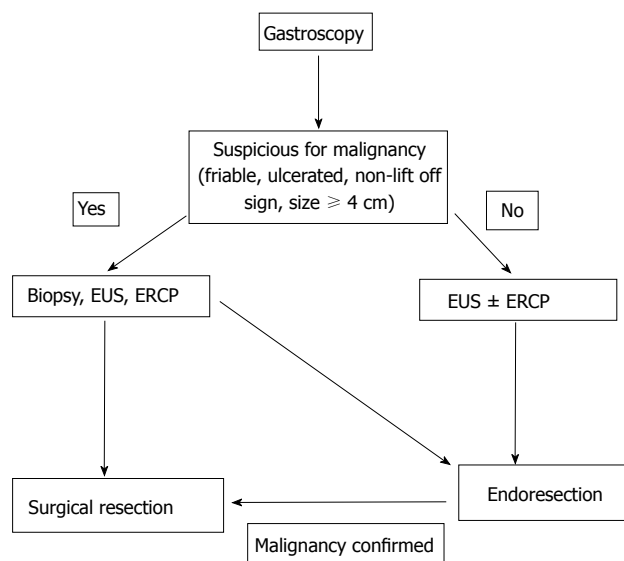


Figure 2 Management of ampullary adenomas. ERCP: Endoscopic retrograde cholangiopancreatography; EUS: Endoscopic ultrasound.

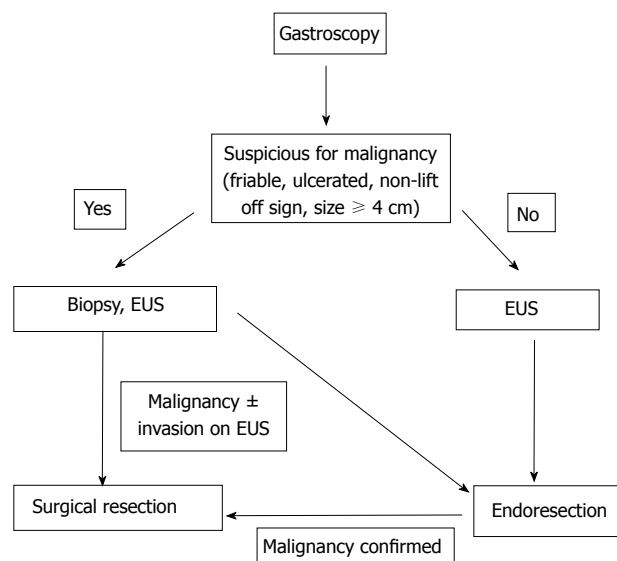


Figure 3 Management of non-ampullary adenomas. EUS: Endoscopic ultrasound.

of the duodenum and extension into biliary/pancreatic ducts^[37]. There is no consensus regarding the absolute size that would make a lesion suitable for endoscopic resection although a maximum size of 4-5 cm for an endoscopic ampullectomy has been suggested, due to the increased risk of malignancy. Large adenomas can be challenging to resect *en bloc* although Irani had a success rate of 84%, with a mean lesion size of 2.4 cm^[38].

There has been a significant shift with respect to size criteria for non ampullary lesions. In 2003 Perez *et al*^[8] suggested that lesions more than 2 cm ought to be resected surgically. In 2009 Alexander *et al*^[7] showed that lesions with mean size of 27.6 mm could be resected endoscopically. Apart from size, the physical appearance of the lesion is important. If the depressed segment is < 10 mm and non-depressed segment < 50 mm then it will be suitable for endoscopic resection and the non-lift sign is a strong sign of malignancy^[39].

Role for endoscopic submucosal dissection: In our institution we have favoured EMR as a method of endoscopic resection. In general it has a success rate of 79%-100% with ability to deal with any lesion in only one session in 80%. The complication rate been quoted as 0.6% for perforation and up to 9% for non-fatal bleeding. Endoscopic submucosal dissection has recently been trialled in duodenal adenomas and electrosurgical dissection with an endoscopic knife achieves a better *en bloc* resection of the lesion^[11]. However the complication rate is higher with perforation rates of 31%, 15% for post-procedural bleeding and a longer procedural duration.

En bloc vs piecemeal resection: We have more commonly resorted to piecemeal resection for both types of adenoma. Ideally *en bloc* resection would

allow an oncologically better resection of the tumour but this can be challenging for lesions > 2 cm^[7,40]. Piecemeal resection allows tumours of larger size to be resected endoscopically with reduced risk of perforation, reduces resection time and uses less electrocautery. Unfortunately it does predispose to repeated subsequent resections^[22] as there is increased risk of recurrence^[7] especially when the lesion is > 20 mm^[7,22].

Role of pancreatic stenting following ampullectomy: Pancreatic duct stenting has been shown to reduce the risk of post procedural pancreatitis in a prospective randomised trial^[41], although the study only included 19 patients. A meta-analysis of five studies involving 481 patients showed that patients in the no stent group had a 3-fold increased risk of post-ERCP pancreatitis^[42]. Our pancreatic stenting rate is only 62.5%, without however any trend towards significant pancreatitis post resection. There is no strong evidence regarding prophylactic biliary stenting, although it has a role should biliary drainage post procedure be a concern^[33].

Complications

We reported a 4.3% complication rate. This was a single patient with self-limiting mild pancreatitis after a papillectomy. The rate of specific complications associated with endoscopic resections include pancreatitis (8%-15%), perforation (up to 4%), cholangitis (up to 2%), papillary stenosis (0%-8%)^[22]. A recent prospective study showed a risk of minor bleeding of 18% and 6.5% for major bleeding^[43]. The low rate of bleeding at our institution could be due to meticulous hemostasis being achieved once resection is completed.

Surveillance and recurrence

In our series of cases, recurrences in ampullary

adenomas occurred earlier and more often than in non ampullary SDA. The inherent risk of recurrence after endoscopic resection has been investigated separately in both subgroups of adenomas. Two series on ampullary adenomas showed a recurrence rate of 19% on follow-up^[43,44] while a published case series of endoscopic resection of non-ampullary adenomas showed an average recurrence rate of 19.9%^[31]. However subset analysis shows that the recurrence rate of 37% can go up to 63% if lesion of > 2 cm diameter are analysed separately^[6]. Currently there is no accepted standardized follow up regime. Most commonly it is suggested that patients should have annual endoscopic follow up for first 2 years after complete resection^[6], while Apel *et al*^[10] suggests 3 monthly endoscopy for 1 year, increasing to 6 monthly for 2 years followed by annual endoscopy.

Best salvage therapy

A treatment plan for recurrences should be devised by all units offering endoscopic therapy of duodenal adenomas as recurrences are common, especially if there has been more than one endoresection, the lesion was large or the resection was incomplete. Unfortunately there is no consensus on the optimal salvage therapy. As more experience is being gathered with endoresection it is increasingly becoming an attractive tool to treat recurrences, often coupled with ablative therapy such as argon beam coagulation (APC). Alexander *et al*^[7] noted 5 recurrences after treating 23 patients with NA by EMR, with median size of 20 mm. Those were cleared with a further session of APC ± EMR with a mean follow up of 13 mo. Similarly a series of 54 patients with non-ampullary adenomas (mean size 15 mm)^[45] had 16 recurrences of which 15 were eradicated with a further session of EMR ± APC. However, the median follow up period was only 10.8 mo.

Very few series have assessed ablation therapy in isolation. Lienert *et al*^[46] assessed 16 cases of NA treated with APC ± polypectomy where 3 of the 4 recurrences were successfully treated with ablative therapy. Apel *et al*^[10] had assessed 18 cases of non-ampullary adenoma, with a median size of 27.5 mm, treated with a combination of serial sessions of polypectomy and APC (33 sessions) carried out over 3 wk to achieve a 55% success rate although 6 cases could not be eradicated despite multimodal endoscopic therapy.

Recently Schneider *et al*^[47] addressed the role of surgery to treat recurrences after failed endoscopic treatment of ampullary adenomas. Forty-four cases were referred for transduodenal surgical ampullectomy following a median of 3 endoscopic treatments before referral. The surgical cure rate was 84% with a post-operative morbidity of 24%, the majority being mild (Clavien-Dindo grade I/II). This was comparable to morbidity associated with endoresection (8%-27%).

Proposed management algorithm

Based on this information a management algorithm for sporadic non-ampullary and ampullary adenomas is

summarised in Figures 2 and 3 respectively. However, management does depend on the experience of the endoscopist (e.g., with respect to size of polyp), the availability of investigative tools (e.g., EUS) and the fitness of the patient to tolerate the treatment offered.

In conclusion, this investigation has confirmed that SDA can be treated endoscopically with minimal morbidity and that piecemeal resection results in eradication in nearly three quarters of patients. Optimal surveillance strategies following resection are not clearly established but re-endoscopy 6 mo after the initial resection is a satisfactory starting point. Recurrent SDA can be treated with endoscopic reresection with surgical resection indicated when the lesions are large (> 3 cm in diameter) or demonstrate severe dysplasia or invasive cancer.

ACKNOWLEDGMENTS

The medical and nursing staff of wards 4, 6 and 8 and the Department of Gastroenterology at North Shore Hospital are gratefully acknowledged.

COMMENTS

Background

The optimal treatment strategy for sporadic duodenal adenomas (SDA) is not yet established although it is clear that this involves contributions from both advanced endoscopy and upper gastrointestinal surgery.

Research frontiers

Developing algorithms to accurately predict the optimal treatment (endoscopic or surgical resection) based on morphology and pathology of both primary and recurrent SDA will assist in their multidisciplinary management.

Innovations and breakthrough

Most SDA can be treated endoscopically with even piecemeal resection resulting in eradication in three quarters of patients. Surgical resection can be reserved for lesions > 4 cm in diameter or with malignant change.

Applications

With multidisciplinary review, endoscopic resection can be the primary treatment modality for SDA.

Terminology

SDA is a management challenge due to their anatomical position and the often comorbid status of patients.

Peer-review

This manuscript is interesting due to the paucity of precise international guidelines regarding the topic.

REFERENCES

- 1 Jepsen JM, Persson M, Jakobsen NO, Christiansen T, Skoubo-Kristensen E, Funch-Jensen P, Kruse A, Thommesen P. Prospective study of prevalence and endoscopic and histopathologic characteristics of duodenal polyps in patients submitted to upper endoscopy. *Scand J Gastroenterol* 1994; **29**: 483-487 [PMID: 8079103 DOI: 10.3109/00365529409092458]
- 2 Seifert E, Schulte F, Stolte M. Adenoma and carcinoma of the duodenum and papilla of Vater: a clinicopathologic study. *Am J*

- Gastroenterol* 1992; **87**: 37-42 [PMID: 1728122]
- 3 **Spigelman AD**, Talbot IC, Penna C, Nugent KP, Phillips RK, Costello C, DeCosse JJ. Evidence for adenoma-carcinoma sequence in the duodenum of patients with familial adenomatous polyposis. The Leeds Castle Polyposis Group (Upper Gastrointestinal Committee). *J Clin Pathol* 1994; **47**: 709-710 [PMID: 7962621 DOI: 10.1136/jcp.47.8.709]
- 4 **Hirota WK**, Zuckerman MJ, Adler DG, Davila RE, Egan J, Leighton JA, Qureshi WA, Rajan E, Fanelli R, Wheeler-Harbaugh J, Baron TH, Faigel DO. ASGE guideline: the role of endoscopy in the surveillance of premalignant conditions of the upper GI tract. *Gastrointest Endosc* 2006; **63**: 570-580 [PMID: 16564854 DOI: 10.1016/j.gie.2006.02.004]
- 5 **El Hajj II**, Coté GA. Endoscopic diagnosis and management of ampullary lesions. *Gastrointest Endosc Clin N Am* 2013; **23**: 95-109 [PMID: 23168121 DOI: 10.1016/j.giec.2012.10.004]
- 6 **Abbass R**, Rigaux J, Al-Kawas FH. Nonampullary duodenal polyps: characteristics and endoscopic management. *Gastrointest Endosc* 2010; **71**: 754-759 [PMID: 20363416 DOI: 10.1016/j.gie.2009.11.043]
- 7 **Alexander S**, Bourke MJ, Williams SJ, Bailey A, Co J. EMR of large, sessile, sporadic nonampullary duodenal adenomas: technical aspects and long-term outcome (with videos). *Gastrointest Endosc* 2009; **69**: 66-73 [PMID: 18725157 DOI: 10.1016/j.gie.2008.04.061]
- 8 **Perez A**, Saltzman JR, Carr-Locke DL, Brooks DC, Osteen RT, Zinner MJ, Ashley SW, Whang EE. Benign nonampullary duodenal neoplasms. *J Gastrointest Surg* 2003; **7**: 536-541 [PMID: 12763412 DOI: 10.1016/S1091-255X(02)00146-4]
- 9 **Takahashi T**, Ando T, Kabeshima Y, Kawakubo H, Shito M, Sugiura H, Omori T. Borderline cases between benignancy and malignancy of the duodenum diagnosed successfully by endoscopic submucosal dissection. *Scand J Gastroenterol* 2009; **44**: 1377-1383 [PMID: 19821793 DOI: 10.3109/00365520903287551]
- 10 **Apel D**, Jakobs R, Spiethoff A, Riemann JF. Follow-up after endoscopic snare resection of duodenal adenomas. *Endoscopy* 2005; **37**: 444-448 [PMID: 15844023 DOI: 10.1055/s-2005-861287]
- 11 **Honda T**, Yamamoto H, Osawa H, Yoshizawa M, Nakano H, Sunada K, Hanatsuka K, Sugano K. Endoscopic submucosal dissection for superficial duodenal neoplasms. *Dig Endosc* 2009; **21**: 270-274 [PMID: 19961529 DOI: 10.1111/j.1443-1661.2009.00908.x]
- 12 **Lépilliez V**, Chemaly M, Ponchon T, Napoleon B, Saurin JC. Endoscopic resection of sporadic duodenal adenomas: an efficient technique with a substantial risk of delayed bleeding. *Endoscopy* 2008; **40**: 806-810 [PMID: 18828076 DOI: 10.1055/s-2008-1077619]
- 13 **Kim HK**, Chung WC, Lee BI, Cho YS. Efficacy and long-term outcome of endoscopic treatment of sporadic nonampullary duodenal adenoma. *Gut Liver* 2010; **4**: 373-377 [PMID: 20981216 DOI: 10.5009/gnl.2010.4.3.373]
- 14 **Goda K**, Kikuchi D, Yamamoto Y, Takimoto K, Kakushima N, Morita Y, Doyama H, Gotoda T, Maehata Y, Abe N. Endoscopic diagnosis of superficial non-ampullary duodenal epithelial tumors in Japan: Multicenter case series. *Dig Endosc* 2014; **26** Suppl 2: 23-29 [PMID: 24750144 DOI: 10.1111/den.12277]
- 15 **Kedia P**, Brensinger C, Ginsberg G. Endoscopic predictors of successful endoluminal eradication in sporadic duodenal adenomas and its acute complications. *Gastrointest Endosc* 2010; **72**: 1297-1301 [PMID: 20970793 DOI: 10.1016/j.gie.2010.07.039]
- 16 **Boix J**, Lorenzo-Zúñiga V, Moreno de Vega V, Domènech E, Gassull MA. Endoscopic resection of ampullary tumors: 12-year review of 21 cases. *Surg Endosc* 2009; **23**: 45-49 [PMID: 18398649 DOI: 10.1007/s00464-008-9866-3]
- 17 **Jeanniard-Malet O**, Caillol F, Pesenti C, Bories E, Monges G, Giovannini M. Short-term results of 42 endoscopic ampullectomies: a single-center experience. *Scand J Gastroenterol* 2011; **46**: 1014-1019 [PMID: 21492053 DOI: 10.3109/00365521.2011.571711]
- 18 **Laleman W**, Verreth A, Topal B, Aerts R, Komuta M, Roskams T, Van der Merwe S, Cassiman D, Nevens F, Verslype C, Van Steenberghe W. Endoscopic resection of ampullary lesions: a single-center 8-year retrospective cohort study of 91 patients with long-term follow-up. *Surg Endosc* 2013; **27**: 3865-3876 [PMID: 23708714 DOI: 10.1007/s00464-013-2996-2]
- 19 **Rubio CA**. Gastric duodenal metaplasia in duodenal adenomas. *J Clin Pathol* 2007; **60**: 661-663 [PMID: 16837629 DOI: 10.1136/jcp.2006.039388]
- 20 **Uno Y**, Munakata A. The non-lifting sign of invasive colon cancer. *Gastrointest Endosc* 1994; **40**: 485-489 [PMID: 7926542 DOI: 10.1016/S0016-5107(94)70216-0]
- 21 **Han KS**, Sohn DK, Choi DH, Hong CW, Chang HJ, Lim SB, Choi HS, Jeong SY, Park JG. Prolongation of the period between biopsy and EMR can influence the nonlifting sign in endoscopically resectable colorectal cancers. *Gastrointest Endosc* 2008; **67**: 97-102 [PMID: 18155430 DOI: 10.1016/j.gie.2007.05.057]
- 22 **Chathadi KV**, Khashab MA, Acosta RD, Chandrasekhara V, Eloubeidi MA, Faulx AL, Fonkalsrud L, Lightdale JR, Saltzman JR, Shaikat A, Wang A, Cash BD, DeWitt JM. The role of endoscopy in ampullary and duodenal adenomas. *Gastrointest Endosc* 2015; **82**: 773-781 [PMID: 26260385]
- 23 **Elek G**, Györi S, Tóth B, Pap A. Histological evaluation of preoperative biopsies from ampulla vateri. *Pathol Oncol Res* 2003; **9**: 32-41 [PMID: 12704445 DOI: 10.1007/BF03033712]
- 24 **Bellizzi AM**, Kahaleh M, Stelow EB. The assessment of specimens procured by endoscopic ampullectomy. *Am J Clin Pathol* 2009; **132**: 506-513 [PMID: 19762527 DOI: 10.1309/AJCPJWJ8WA2IHBG]
- 25 **Rodríguez C**, Borda F, Elizalde I, Jiménez Pérez FJ, Carral D. How accurate is preoperative diagnosis by endoscopic biopsies in ampullary tumours? *Rev Esp Enferm Dig* 2002; **94**: 585-592 [PMID: 12647408]
- 26 **Pandolfi M**, Martino M, Gabbriellini A. Endoscopic treatment of ampullary adenomas. *JOP* 2008; **9**: 1-8 [PMID: 18182736]
- 27 **Ahmad NA**, Kochman ML, Long WB, Furth EE, Ginsberg GG. Efficacy, safety, and clinical outcomes of endoscopic mucosal resection: a study of 101 cases. *Gastrointest Endosc* 2002; **55**: 390-396 [PMID: 11868015 DOI: 10.1067/mge.2002.121881]
- 28 **Min YW**, Min BH, Kim ER, Lee JH, Rhee PL, Rhee JC, Kim JJ. Efficacy and safety of endoscopic treatment for nonampullary sporadic duodenal adenomas. *Dig Dis Sci* 2013; **58**: 2926-2932 [PMID: 23695872 DOI: 10.1007/s10620-013-2708-8]
- 29 **Lim GJ**, Devereaux BM. EUS in the assessment of ampullary lesions prior to endoscopic resection. *Tech Gastrointest Endosc* 2010; **12**: 49-52 [DOI: 10.1016/j.tgie.2010.01.008]
- 30 **Baillie J**. Endoscopic ampullectomy. *Am J Gastroenterol* 2005; **100**: 2379-2381 [PMID: 16279887 DOI: 10.1111/j.1572-0241.2005.00332.x]
- 31 **Basford PJ**, Bhandari P. Endoscopic management of nonampullary duodenal polyps. *Therap Adv Gastroenterol* 2012; **5**: 127-138 [PMID: 22423261 DOI: 10.1177/1756283X11429590]
- 32 **Menzel J**, Hoepffner N, Sulkowski U, Reimer P, Heinecke A, Poremba C, Domschke W. Polypoid tumors of the major duodenal papilla: preoperative staging with intraductal US, EUS, and CT—a prospective, histopathologically controlled study. *Gastrointest Endosc* 1999; **49**: 349-357 [PMID: 10049419 DOI: 10.1016/S0016-5107(99)70012-X]
- 33 **Ito K**, Fujita N, Noda Y, Kobayashi G, Horaguchi J, Takasawa O, Obana T. Preoperative evaluation of ampullary neoplasm with EUS and transpapillary intraductal US: a prospective and histopathologically controlled study. *Gastrointest Endosc* 2007; **66**: 740-747 [PMID: 17905017 DOI: 10.1016/j.gie.2007.03.1081]
- 34 **Norton ID**, Gostout CJ, Baron TH, Geller A, Petersen BT, Wiersma MJ. Safety and outcome of endoscopic snare excision of the major duodenal papilla. *Gastrointest Endosc* 2002; **56**: 239-243 [PMID: 12145603 DOI: 10.1016/S0016-5107(02)70184-3]
- 35 **Catalano MF**, Linder JD, Chak A, Sivak MV, Rajman I, Geenen JE, Howell DA. Endoscopic management of adenoma of the major duodenal papilla. *Gastrointest Endosc* 2004; **59**: 225-232 [PMID: 14745396 DOI: 10.1016/S0016-5107(03)02366-6]
- 36 **Norton ID**, Geller A, Petersen BT, Sorbi D, Gostout CJ. Endoscopic surveillance and ablative therapy for perampullary adenomas. *Am J Gastroenterol* 2001; **96**: 101-106 [PMID: 11197237 DOI: 10.1111/j.1572-0241.2001.03358.x]
- 37 **Moon JH**, Choi HJ, Lee YN. Current status of endoscopic

- papillectomy for ampullary tumors. *Gut Liver* 2014; **8**: 598-604 [PMID: 25368746 DOI: 10.5009/gnl14099]
- 38 **Irani S**, Arai A, Ayub K, Biehl T, Brandabur JJ, Dorer R, Gluck M, Jiranek G, Patterson D, Schembre D, Traverso LW, Kozarek RA. Papillectomy for ampullary neoplasm: results of a single referral center over a 10-year period. *Gastrointest Endosc* 2009; **70**: 923-932 [PMID: 19608181 DOI: 10.1016/j.gie.2009.04.015]
 - 39 **Kahaleh M**, Shami VM, Brock A, Conaway MR, Yoshida C, Moskaluk CA, Adams RB, Tokar J, Yeaton P. Factors predictive of malignancy and endoscopic resectability in ampullary neoplasia. *Am J Gastroenterol* 2004; **99**: 2335-2339 [PMID: 15571579 DOI: 10.1111/j.1572-0241.2004.40391.x]
 - 40 **Desilets DJ**, Dy RM, Ku PM, Hanson BL, Elton E, Mattia A, Howell DA. Endoscopic management of tumors of the major duodenal papilla: Refined techniques to improve outcome and avoid complications. *Gastrointest Endosc* 2001; **54**: 202-208 [PMID: 11474391 DOI: 10.1067/mge.2001.116564]
 - 41 **Harewood GC**, Pochron NL, Gostout CJ. Prospective, randomized, controlled trial of prophylactic pancreatic stent placement for endoscopic snare excision of the duodenal ampulla. *Gastrointest Endosc* 2005; **62**: 367-370 [PMID: 16111953 DOI: 10.1016/j.gie.2005.04.020]
 - 42 **Singh P**, Das A, Isenberg G, Wong RC, Sivak MV, Agrawal D, Chak A. Does prophylactic pancreatic stent placement reduce the risk of post-ERCP acute pancreatitis? A meta-analysis of controlled trials. *Gastrointest Endosc* 2004; **60**: 544-550 [PMID: 15472676 DOI: 10.1016/S0016-5107(04)02013-9]
 - 43 **Aschmoneit-Messer I**, Richl J, Pohl J, Ell C, May A. Prospective study of acute complication rates and associated risk factors in endoscopic therapy for duodenal adenomas. *Surg Endosc* 2015; **29**: 1823-1830 [PMID: 25380706 DOI: 10.1007/s00464-014-3871-5]
 - 44 **Zádorová Z**, Dvofák M, Hajer J. Endoscopic therapy of benign tumors of the papilla of Vater. *Endoscopy* 2001; **33**: 345-347 [PMID: 11315897 DOI: 10.1055/s-2001-13693]
 - 45 **Navaneethan U**, Lourdasamy D, Mehta D, Lourdasamy V, Venkatesh PG, Sanaka MR. Endoscopic resection of large sporadic non-ampullary duodenal polyps: efficacy and long-term recurrence. *Surg Endosc* 2014; **28**: 2616-2622 [PMID: 24695983 DOI: 10.1007/s00464-014-3512-z]
 - 46 **Lienert A**, Bagshaw PF. Treatment of duodenal adenomas with endoscopic argon plasma coagulation. *ANZ J Surg* 2007; **77**: 371-373 [PMID: 17497979 DOI: 10.1111/j.1445-2197.2007.04063.x]
 - 47 **Schneider L**, Contin P, Fritz S, Strobel O, Büchler MW, Hackert T. Surgical ampullectomy: an underestimated operation in the era of endoscopy. *HPB (Oxford)* 2016; **18**: 65-71 [PMID: 26776853 DOI: 10.1016/j.hpb.2015.07.004]

P- Reviewer: de Angelis GL **S- Editor:** Gong ZM **L- Editor:** A
E- Editor: Wu HL





Published by **Baishideng Publishing Group Inc**

8226 Regency Drive, Pleasanton, CA 94588, USA

Telephone: +1-925-223-8242

Fax: +1-925-223-8243

E-mail: bpgoffice@wjgnet.com

Help Desk: <http://www.f6publishing.com/helpdesk>

<http://www.f6publishing.com>

