

Therapeutic approaches for portal biliopathy: A systematic review

Irene Franceschet, Alberto Zanetto, Alberto Ferrarese, Patrizia Burra, Marco Senzolo

Irene Franceschet, Alberto Zanetto, Alberto Ferrarese, Patrizia Burra, Marco Senzolo, Gastroenterology Unit, Department of Surgery, Oncology and Gastroenterology, University Hospital of Padua, 35128 Padua, Italy

Alberto Zanetto, Alberto Ferrarese, Patrizia Burra, Marco Senzolo, Multivisceral Transplant Unit, Department of Surgery, Oncology and Gastroenterology, University Hospital of Padua, 35128 Padua, Italy

Author contributions: Franceschet I and Senzolo M designed and drafted the manuscript; Franceschet I, Zanetto A and Ferrarese A contributed to the literature search; Burra P and Senzolo M revised the final manuscript.

Conflict-of-interest statement: Authors declare no conflict of interests for this article.

Open-Access: This article is an open-access article which was selected by an in-house editor and fully peer-reviewed by external reviewers. It is distributed in accordance with the Creative Commons Attribution Non Commercial (CC BY-NC 4.0) license, which permits others to distribute, remix, adapt, build upon this work non-commercially, and license their derivative works on different terms, provided the original work is properly cited and the use is non-commercial. See: <http://creativecommons.org/licenses/by-nc/4.0/>

Manuscript source: Invited manuscript

Correspondence to: Marco Senzolo, MD, PhD, Multivisceral Transplant Unit, Department of Surgery, Oncology and Gastroenterology, University Hospital of Padua, Via Giustiniani 2, 35128 Padua, Italy. marcosenzolo@hotmail.com
Telephone: +39-4-98218726
Fax: +39-4-98760820

Received: August 26, 2016

Peer-review started: August 29, 2016

First decision: September 20, 2016

Revised: October 12, 2016

Accepted: November 14, 2016

Article in press: November 16, 2016

Published online: December 7, 2016

Abstract

Portal biliopathy (PB) is defined as the presence of biliary abnormalities in patients with non-cirrhotic/non-neoplastic extrahepatic portal vein obstruction (EHPVO) and portal cavernoma (PC). The pathogenesis of PB is due to *ab extrinseco* compression of bile ducts by PC and/or to ischemic damage secondary to an altered biliary vascularization in EHPVO and PC. Although asymptomatic biliary abnormalities can be frequently seen by magnetic resonance cholangiopancreatography in patients with PC (77%-100%), only a part of these (5%-38%) are symptomatic. Clinical presentation includes jaundice, cholangitis, cholecystitis, abdominal pain, and cholelithiasis. In this subset of patients is required a specific treatment. Different therapeutic approaches aimed to diminish portal hypertension and treat biliary strictures are available. In order to decompress PC, surgical porto-systemic shunt or transjugular intrahepatic porto-systemic shunt can be performed, and treatment on the biliary stenosis includes endoscopic (Endoscopic retrograde cholangiopancreatography with endoscopic sphincterotomy, balloon dilation, stone extraction, stent placement) and surgical (bilioenteric anastomosis, cholecystectomy) approaches. Definitive treatment of PB often requires multiple and combined interventions both on vascular and biliary system. Liver transplantation can be considered in patients with secondary biliary cirrhosis, recurrent cholangitis or unsuccessful control of portal hypertension.

Key words: Portal biliopathy; Portal cavernoma; Magnetic resonance cholangiopancreatography; Endoscopic retrograde cholangiopancreatography; Porto-systemic shunt

© **The Author(s) 2016.** Published by Baishideng Publishing Group Inc. All rights reserved.

Core tip: Portal biliopathy in patients with portal vein thrombosis and portal cavernoma can be symptomatic in about 5%-38% of patients. Therapy includes endoscopic and surgical approaches aimed to improve both portal hypertension and biliary alterations and clinical manifestation. Usually, multiple and combined treatments are required to resolve portal biliopathy.

Franceschet I, Zanetto A, Ferrarese A, Burra P, Senzolo M. Therapeutic approaches for portal biliopathy: A systematic review. *World J Gastroenterol* 2016; 22(45): 9909-9920 Available from: URL: <http://www.wjgnet.com/1007-9327/full/v22/i45/9909.htm> DOI: <http://dx.doi.org/10.3748/wjg.v22.i45.9909>

INTRODUCTION

Portal biliopathy (PB) is a clinical condition defined as the presence of abnormalities in the biliary tree (including biliary tree and gallbladder) in patients with non-cirrhotic/non-neoplastic extrahepatic portal vein obstruction (EHPVO) and portal cavernoma (PC)^[1]. In literature, this disease has been named as "portal hypertensive biliopathy"^[2], "portal cavernoma-associated cholangiopathy"^[3], "portal cavernomacholangiopathy"^[4], "cholangiopathy associated with portal hypertension"^[5], "pseudosclerosing cholangitis"^[6] and "pseudocholangiocarcinoma"^[7] due to the fact that PB biliary alterations can mimic sclerosing cholangitis or cholangiocarcinoma, respectively.

The spectrum of biliary abnormalities shown at magnetic resonance cholangiopancreatography (MRCP) includes intra- and extra-hepatic biliary stenosis (single or multiple), with or without consensual above dilation; bile duct wall irregularity or thickening; bile duct angulation, varicose veins located at the ductular walls and gallbladder^[3,8].

The aim of this paper is to analyse PB clinical approaches based on classification and characteristics of portal biliopathy through a systematic review of the literature.

For this purpose, a systematic search on MEDLINE was conducted spanning April 1990 to April 2016. Studies were identified using the following terms: "portal biliopathy" OR "portal cholangiopathy" OR "pseudosclerosing cholangitis" OR "pseudocholangiocarcinoma" AND "treatment". In addition, all study references were consulted to identify any other relevant studies. Only studies on humans were considered, and only papers wrote in English were used for the analysis. Inclusion criteria were as follows: patients with PB secondary to non-neoplastic non-cirrhotic portal vein thrombosis (PVT) reporting endoscopic and surgical treatment of PB, both case series and case reports. Exclusion criteria were: review articles, guidelines or comment to other papers; iatrogenic PVT articles; papers about treatment of PB therapy complications or PB medical

therapy; papers about PVT treatment.

A total of 118 articles were initially retrieved. Of these, 69 were excluded according to inclusion/exclusion criteria and the remaining 49 papers were included in this review (Figure 1).

PATHOGENESIS

The development of PB in PC is due to two main mechanisms: a mechanical compression *ab extrinseco* of bile ducts (mainly hepatic biliary duct and common bile duct) by both the PC and the numerous compensatory collateral vein circles that arise after EHPVO formation, and an ischemic damage secondary to the altered vascularization due to EHPVO and PC.

Normally, venous drain of biliary tree is serviced by epicholedochal venous plexus of Saint and the paracholedochal plexus of Petren, whom normally diameter does not exceed 1 mm. In chronic portal vein obstruction these plexus are dilated in response to portal hypertension leading to thickening of biliary duct walls and compression, often with a characteristic radiological/endoscopic image of virtual lumen^[9-11]. In particular, dilation of plexus of Saint causes fine irregularities in biliary walls while dilation of plexus of Petren causes extrinsic compression.

The ischemic damage seems to be related to deficient portal blood supply of the biliary tree secondary to EHPVO and PC and to thrombosis of small bile duct venules, resulting in strictures formation and fibrous^[9]. The prevalence of biliary strictures due to a mechanical compression is about 55% among patients with PB, on the contrary in 45% of cases there was no relationship between stenosis localization and severity and cavernoma/collateral vein compression, suggesting the preponderance of ischemic damage in these cases^[12]. However, both mechanisms can contribute at the same time in PB pathogenesis.

The bile stasis secondary to biliary strictures and hypothetic changes in bile compositions (increased pigment load due to hypersplenism, abnormal enterohepatic circulation of bile acids due to portal hypertension) can contribute to stones formation^[13].

DIAGNOSIS AND CLASSIFICATION

The diagnosis of PB is based on radiological imaging, in particular on cholangiography. MRCP is a non-invasive imaging test that can give a definite outline of biliary ductal abnormalities, and for these reasons it represents the modality of choice for PB diagnosis and evaluation. As previously mentioned, the main alterations evidenced at MRCP are bile duct stenosis, angulations and dilations, both intra and extra-hepatic, parietal irregularities, bile duct angulations, choledochal varices, lithiasis^[3,9]. Condat *et al*^[3] purposed the use of MRCP coupled with magnetic resonance (MR) portography in the initial evaluation of PB, to assess both biliary abnormalities and portal anatomy, which

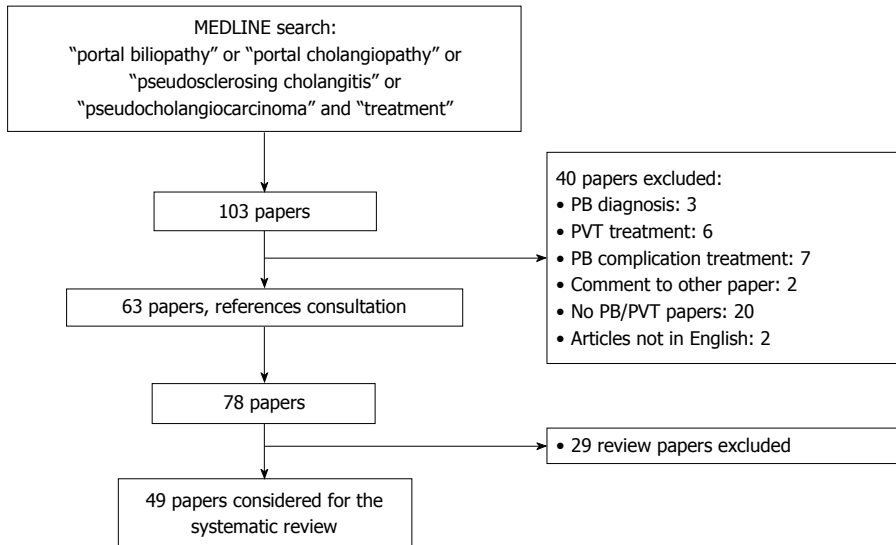


Figure 1 Flow-chart of literature search. PB: Portal biliopathy; PVT: Portal vein thrombosis.

helps in choice of the best therapeutic approach.

Initially, endoscopic retrograde cholangiopancreatography (ERCP) has been for many years the modality of choice to obtain cholangiographic images. Nowadays it has been replaced by MRCP in biliary diagnostic: ERCP is an invasive tool with possible complications, and it has only a therapeutic rather than diagnostic role. ERCP abnormalities are the same demonstrated at MRCP, however some old studies that used ERCP for PB diagnosis described a more frequent and severe left hepatic duct involvement (40%-100%) respect right hepatic duct (40%-57%)^[6,14].

Endoscopic ultrasound (EUS) has a complementary role and can evaluate biliary stenosis and dilations, stones, and in particular it is able demonstrate dilated peri-choledochal venous collateral vessels^[15].

Abdominal ultrasound (US) has not a primary role in PB diagnosis but can be complementary to other techniques to evaluate presence and characteristics of PC, presence of gallbladder varices, signs of portal hypertension, gallstones, biliary tree dilation.

In the literature many classification have been published. Firstly, Chandra and Sarin^[10] identified four PB types according with the biliary abnormalities localization at ERCP: type I, involvement of extrahepatic bile duct only; type II, involvement of intrahepatic bile duct only; type IIIa, involvement of extrahepatic bile duct and unilateral intrahepatic bile duct (left or right); type IIIb, involvement of extrahepatic bile duct and bilateral intrahepatic ducts. Llop *et al.*^[1] classified PB into different degrees of severity: grade I, biliary tree irregularities or angulations; grade II, indentations or strictures without dilation; grade III, strictures with dilation (defined as intrahepatic duct ≥ 4 mm or extrahepatic duct ≥ 7 mm).

At least, Shin *et al.*^[16] distinguished three type of PB base on pathogenetic mechanism: they described

a varicoid type in which biliary irregularities are mainly caused by extrinsic compression, a fibrotic type in which strictures are due to fibrosis and wall thickening that results from ischemic injury, and a mixed type (both kind of alterations and pathogenetic mechanisms are involved).

CLINICAL MANIFESTATIONS AND NATURAL HISTORY

Biliary changes are present in about 77%-100% of patients with PC^[1,3,6]; however, only 5%-38% of patients developed biliary symptoms^[1,3,14]. Symptoms and clinical manifestations of PB can be related to chronic cholestasis and/or biliary stones formations, and they include jaundice, cholangitis, cholecystitis, abdominal pain, cholelithiasis^[17].

Risk factors for symptoms occurrence in PB are older age, longer duration of disease, common bile duct and gallbladder stones, and abnormal liver function tests (LFTs)^[18].

The natural history of PB is still undefined. Dhiman *et al.*^[11] identified four stages in PB progression, shown in Table 1. The progression from stage I to IV is due to worsening of biliary changes, symptoms onset, alterations in liver function tests and complications occurrence. Only one study by Llop *et al.*^[1] investigated the evolution of biliary changes and symptoms in patients with acute and chronic non-cirrhotic non-tumoral PVT: 67 patients were followed with MR angiography (MRA) and MRCP after PVT diagnosis. Among 22 patients with acute PVT, 73% developed biliary alterations at MRA/MR cholangiography (MRC) within a median follow-up of 33 mo (range 1-102): 4 patients had grade I PB, 4 grade II and 8 grade III, while 6 patient didn't had PB. In 14 patients without

Table 1 Characteristics of four stages in portal biliopathy natural history

Stage	Portal cavernoma	Biliopathy	LFTs	Symptoms	Complications
Preclinic	Yes	No	Normal	No	No
Asymptomatic	Yes	Early changes	Normal or abnormal	No	No
Symptomatic	Yes	Advanced changes	Abnormal	Yes	No
Complicated	Yes	Advanced changes	Abnormal	Yes	Yes

LFTs: Liver function tests.

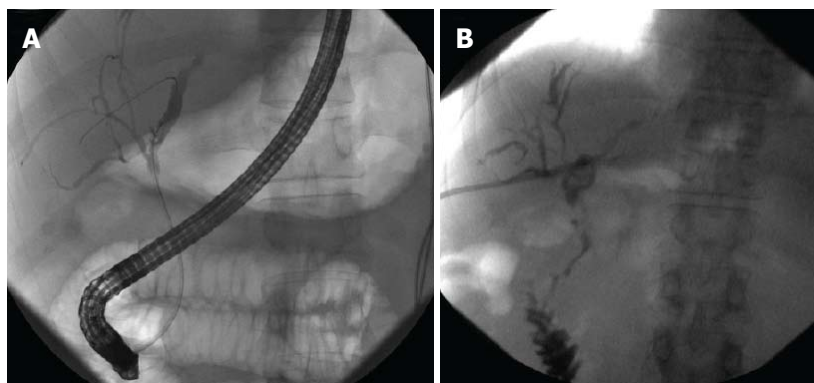


Figure 2 Cholangiographic findings in a patient with symptomatic (jaundice and cholangitis) portal biliopathy secondary to chronic extrahepatic portal vein obstruction and portal cavernoma. Ischemic stenosis with dilatation of the left intrahepatic biliary tree is shown by ERCP (A): patient underwent unsuccessful ERCP with stent insertion and then PTBD placement; PTBD was changed for 3 times in one year because of cholangitis and liver abscess. After clinical and biochemical improvement of BA, patient was treated with surgical splenorenal shunt and after 5 mo PTBD was definitively removed. Last cholangiography obtained before PTBD removal shows significant improvement in biliary dilation (B). Patient is actually asymptomatic for BA and PB management. BA: Bilioenteric anastomosis; ERCP: Endoscopic retrograde cholangiopancreatography; PB: Portal biliopathy; PTBD: Percutaneous transhepatic biliary drainage.

grade III PB, 11 performed another MR during a 43 mo follow-up and no progression to grade III PB was observed. Chronic PVT was present in 45 patients: within a median follow-up of 67 mo (range 0-749), 80% developed PB (3 patients grade I, 7 grade II and 26 grade III). Also in this group, no evolution from grade I - II PB to grade III PB was observed after a mean follow-up of 37 mo. Biliary symptoms occurred in 41% of grade III PB patients, while patients with grade I - II PB remained asymptomatic during follow-up [Positive predictive value (PPV) 41%, Negative predictive value (NPV) 100%]. In conclusion, when PB is established due to the formation of PC in EHPVO, the clinical picture will not change much over time and clinical manifestations will be mainly correlate with site and type of stenosis.

THERAPEUTIC APPROACHES

Treatment of PB is recommended only for symptomatic patients, whereas the presence of biliary abnormalities associated with mild biochemical alterations without clinical manifestations is not an indication for therapeutic intervention but requires a biochemical and clinical follow-up^[11].

Therapy of portal biliopathy should be addressed to firstly reduce portal hypertension and secondly to resolve biliary obstruction. Both surgical and radiological porto-systemic shunt (PSS) can be considered

the treatment of choice to reduce portal hypertension in patients with EHPVO and PC; when PB is related only to a mechanical compression, this approach can resolve both PC and PB at the same time^[19]. However, when the damage of the biliary tree is also ischemic, portal decompression alone is not sufficient to relief biliary obstruction, and in many cases patients need multiple endoscopic and surgical interventions on biliary tree during their life. An example of cholangiographic findings at ERCP before and after endoscopic plastic stent placement is shown in Figure 2.

Medical treatment with ursodeoxycholic acid (UDCA) has a limited role, even if some authors reported resolution or improvement of mild PB symptoms (mainly abdominal pain and biochemical cholestasis without evidence of stones) and prevention in recurrence of cholangitis after UDCA therapy alone^[1,17,20].

At the moment, there is not a standardized flow-chart for PB therapy, and data about different and combined approaches and their outcomes are reported from small series and case reports.

Considering all papers included in this review, a total of 284 PB patients were described, among these, the most frequent described symptoms were jaundice (52.8%), cholangitis (27.1%) and abdominal pain (19.4%). The mean age at PB presentation was 33.5 ± 13.5.

Hereafter we analyze the different types of treatment reported in the included articles.

Endoscopic treatment

Among the total of symptomatic PB patients included in case series and case reports, 114 patients were treated endoscopically at first. Only in 34 patients (29.8%) a single endoscopic treatment resolved PB alterations and symptoms; among these, 13 patients had common bile duct (CBD) stones as PB manifestation resolved after endoscopic sphincterotomy (ES) + stone extraction (SE). In most cases, repeated treatment were necessary to have a complete resolution of biliary abnormalities, often combined with surgical intervention for portal hypertension: after the first treatment, 49 patients (43%) underwent multiple plastic stent exchange, 4 (3.5%) metallic stent placement, 35 (30.7%) surgical treatment with PSS or splenectomy (with or without esophageal devascularisation), 7 (6%) surgical biliary anastomosis, 2 (1.7%) transjugular intrahepatic porto-systemic shunt (TIPS) and 1 (0.9%) liver transplantation (LT). The duration of follow-up, when reported, range between 2 d and 18 years. In these cases the endoscopic approach can be considered safe, even if some complications have been reported. The most frequent is haemobilia, occurred in 24 procedures (in one case after intracholedocal biopsy). The risk of haemobilia during endoscopic treatment for PB is related to the presence of numerous pericholedocal compensatory collateral veins and congestion of biliary duct walls vessels. In particular, the transient pressure elevation in the distal portion of biliary varices during balloon sweeping can increase the risk of bleeding^[21]. For these reasons, a decompressive shunting procedure performed before endoscopic treatment could reduce the risk of haemobilia^[21,22].

Cholangitis were also frequent (reported after 53 procedures), but although they can be seen after ERCP in up to 15.4% of cases^[23], they are often not directly related to the endoscopic treatment but rather to recurrence of sludge or stones inside the biliary stent and can be treated with stent exchange. Sepsis was observed as well in 3 cases. Mortality directly related to endoscopic treatment was 0%, but one patient died for secondary biliary cirrhosis and one for cholangitis, both developed despite multiple stent placements during the treatment period.

The choice of the endoscopic treatment of PB depends on the type of biliary alterations and includes ERCP with ES, SE (with previous mechanical lithotripsy if necessary) for patients with choledocholithiasis, stricture dilation ± biliary stent or nasobiliary drain placement.

The largest series of PB patients endoscopically treated is described by Saraswat *et al.*^[24], who published data about 130 ERCP performed for biliary strictures in 20 symptomatic patients. ES with SE was performed in 8 patients with choledochal stones and 9 patients were treated with plastic stents placement. Eleven patients (for a total of 101 procedures) were treated on the line of postoperative benign biliary strictures, with balloon dilation and plastic stent insertion,

that were exchanged every 3-4 mo until LFTs normalizations; in 8/11 case a cholangiogram normalization was achieved as well. ERCP complications included haemobilia in 9/130 procedures and cholangitis in 40/130 (mainly already present at the moment of ERCP and due to delay in stent exchanged).

Khare *et al.*^[25] published a case series including 13 patients with EHPVO and PC complicated by symptomatic PB divided in 3 groups according to radiological biliary findings: group A included 5 patients with biliary strictures without choledocholithiasis; group B included 3 patients with choledocholithiasis alone; group C included 5 patients with both biliary strictures and choledocholithiasis. In group A, 4 patients were treated endoscopically with biliary stenting alone (n. 3) or with previous dilation (n. 1), followed by surgical PSS for portal hypertension. In 3/4 patients ERCP resolved biliary strictures, while 1 patient showed persistent stenosis at 12 mo and underwent multiple endoscopic procedures with dilation and stenting. In group B, 2/3 patients were treated with endoscopic SE that was successful in one patient; the other patient underwent stent placement and then surgical intervention for portal hypertension (splenectomy with esophagogastric devascularisation). During the follow-up, this patient needed multiple ERCP for choledochus clearance. In group C, four patients were first treated with endoscopic approach but SE failed in all of these patients; after surgical approaches (PSS or splenectomy with esophagogastric devascularisation), 2/4 patients were successfully managed with repeated ERCP with dilation and SE. No complications were observed after ERCP.

In 2009 the group from Birmingham published his experience with 13 patients with symptomatic portal biliopathy^[17]: at the cholangiography (PB was diagnosed with MRC in 12 patients and with ERCP in 1), 12 patients showed biliary strictures, 10 bile duct stones/sludge, 11 gallbladder stones/sludge. In one patients symptoms (right hypocondrial pain and dark urine) resolved spontaneously, while 12 patients underwent therapeutic ERCP that was successful in 8: in one patients with associated Crohn's disease plastic stent insertion did not resolved jaundice and the patient, that was not eligible for surgical portal decompression for PVT extension, was listened for liver and small bowel transplantation; one patient had an excellent response to ES and SE. Among 7 patients with jaundice resolution after plastic stent insertion, 2 patients underwent portal decompression for recurrent cholangitis despite multiple ERCP (one with PSS and one with TIPS), 1 needed repeated plastic stent changes and in 3 patients a metallic biliary stent was placed after several repeat plastic stent changes. Among 4 cases in which ERCP was unsuccessful, 2 had spontaneous resolution. The observed complications during a total of 49 ERCP were haemobilia (4%) and sepsis (6%, two cholangitis and one enterococcal sepsis), and no death directly related to biliary complications was observed during the follow-up.

In particular, the last two articles evidence how complex is to choose the appropriate treatment for PB, and the great variability on patients response to the same therapy, even between patients with the same type of biliary manifestation. This is also due to the difficulty to classify the etiology of PB (varicoid type or fibrotic type) based on cholangiographic findings.

Combined treatment with biliary procedures and percutaneous transhepatic portal vein recanalization (balloon dilation + self-expandable stent placement) have also been reported^[26].

The role of UDCA administration associated with endoscopic procedures is still uncertain: even if some authors reported the absence of biliary symptoms recurrence after endoscopic treatment associated with UDCA therapy^[1,3], equally good results with the only endoscopic management are reported.

All published PB case series and case reports about endoscopic treatment of PB are summarized in Tables 2 and 3^[1,3,15,17,20,22-47], respectively.

Surgical treatment

Indication to surgery in PB patients is given by the need to decompress the portal system through PSS and to resolve the biliary obstruction. In cases in which PB is due to biliary compression by PC, the detension of collateral vessels obtained with the reduction of portal pressure by PSS can resolve in the same time biliary obstruction^[30]. The most common PSS performed are proximal spleno-renal shunt or mesocaval shunt, but other types of surgical shunts include meso-gonadal vein shunt, meso-renal shunt, right-portal ovarian shunt, shunt between a portal varix and cava^[41,48-51].

However, in patients without resolution of biliary abnormalities and symptoms after PSS, a second stage procedure can be required: biliary stenosis can be managed endoscopically, as explain above, or with surgical construction of a bilioenteric anastomosis. In patients without a suitable patent vein, splenectomy associated with esophagogastric devascularisation could reduce pressure in pericholedochal collateral veins and improve biliary symptoms^[52]. A surgical approach with intrahepatic segment 3 bypass has been described to provide definitive treatment for biliary decompression and stone removal in a single time procedure in appropriately selected patients^[47].

The largest PB series^[52] retrospectively included 56 PB patients who underwent surgery from 1996 to 2010; 32/56 (57.1%) were asymptomatic for PB. To reduce portal hypertension, PSS was performed in 40 patients and splenectomy with devascularisation in 16. After first-line surgery, 7 patients required endoscopic treatment for cholangitis or CBD stones, that was successful in 2 patients, while 5 of them required multiple procedures; 2 patients previously treated with PSS at least needed biliary surgery for dominant CBD stricture that required frequent stent exchanges. In addition,

the authors reported a significant reduction in serum biliary levels after first-line surgery (both shunt and no-shunt surgery) and alkaline phosphatases (shunt surgery), confirming that the resolution or improvement in portal hypertension can be effective in relieving biliary obstruction.

Vibert *et al*^[30] published a case series including 19 symptomatic PB patients and propose an interesting 3 steps approach: (1) biliary drainage and antibiotic therapy if cholangitis is present; (2) surgical PSS; and (3) biliodigestive anastomosis with hepatico-jejunal anastomosis with Roux-en-Y. Patients were divided in two groups according to feasibility of PSS: 10 patients were included in the PSS group, 9 patients in the no PSS (NPSS) group. In the first group, one patient with severe sepsis from cholangitis underwent percutaneous transhepatic biliary drainage (PTBD) with extraction of intrahepatic stones. Then, a splenorenal shunt was performed in all 10 patients. Mortality was nil, and complications rate was 27%, including one chylus fistula and 2 early thrombosis, successfully treated with anticoagulant therapy or angiographic-guided pneumatic dilation. Initially, PSS was successful in biliary symptoms resolution in 70% of cases, but within 30 mo after PSS 5/10 patients required a bilio-enteric anastomosis because of persistent jaundice or recurrent cholangitis. In the NPSS group, 3 patients were initially treated with endoscopic approach (1 ES and 2 plastic stent placement); PTBD was positioned in 6 patients (in 3 cases because of recurrence of biliary symptoms after endoscopic treatment); biliodigestive anastomosis was performed in 4 patients. Among these, one patient initially treated with endoscopic stent placement, 2 patients initially treated with PTBD and 4 patients treated with biliodigestive anastomosis needed repeated transhepatic cholangioscopies to remove intrahepatic stones and to improve biliary drainage; except for 2 patients lost in follow-up, at long-term follow-up one patient died for severe cholangitis and haemobilia while other patients were asymptomatic.

Overall, 173 patients underwent surgery intervention as first or second step for PB treatment: PSS was performed in 131 patients, PSS with splenectomy in 7, splenectomy with devascularisation in 18, devascularisation in 1 and 16 patients underwent biliary surgery (biliodigestive anastomosis, cholecystectomy, choledochotomy). The reported follow-up after surgical intervention ranged between 4 mo and 15 years. Considering patients underwent PSS alone as first treatment for PB, biliary symptoms relieve in 64.1% of cases, while in patients firstly treated with surgical biliary anastomosis, only in 30% of cases no other treatment was required.

A total of 6 death was reported: 1 patients died after 10 years from splenectomy for recurrence of gastrointestinal bleeding, 1 patient died for decompensated alcoholic cirrhosis, one for perforated duodenal

Table 2 Endoscopic management of portal biliopathy: summary of case series

Ref.	No. of patients	Biliary abnormalities	First treatment	Follow-up	Further treatments	Complications/ outcome
Bhatia <i>et al</i> ^[27] , 1995	4 symptomatic	Stenosis + stones 3 CBD stones 4	ES + SE + NBD 4	3-8 mo	Multiple ERCP 4	None
Perlemuter <i>et al</i> ^[20] , 1996	8 symptomatic	Stenosis 8 CBD stones 2 Cholangitis 1	ES+NBD 3 BD 1 PSS 1 UDCA 2	6-60 mo	Multiple ES 1	Death 2 (cholangitis 1; stroke 1)
Condat <i>et al</i> ^[3] , 2003	7 symptomatic	Cholecystitis/right hypochondrial pain 4 Cholangitis 1 Stenosis 2	Cholecystostomy + SE 1 Stent 1 BA + PTBD 1 UDCA 4	4-25 mo	-	Haemobilia 1
Sezgin <i>et al</i> ^[28] , 2003	10 symptomatic	Stenosis 9 IE stones 1	ES + stent 10 NBD 4 BD 4	3.3 yr (range 1-7)	Multiple ERCP 5	Haemobilia 1 Cholangitis 5 Death 1
Dumortier <i>et al</i> ^[22] , 2003	6 symptomatic	Stenosis 5 CBD stones 2	ES 5 BD 5 SE 2 Stent 1	10 mo (range 2 d-18 mo)	Multiple ERCP + PSS 4	Cholangitis 1 Cholecystitis 4
Khare <i>et al</i> ^[25] , 2005	13 symptomatic	Stenosis 10 CBD stones 8	Stent 4 BD 6 SE 4	-	PSS 8 BA 1 Multiple ERCP 2 Splenicectomy + devasc 2	Death 1
Dhiman <i>et al</i> ^[29] , 2007	12 symptomatic	Stenosis 7 CBD stones 5 CBD varices 1 Mirizzi's sdr 1	PSS 5 ES 3 ES + BD 2 Stent 4	19 mo (6-132 mo)	Multiple ERCP in pts initially treated with stent	Cholangitis in 2 pts treated with stent
Vibert <i>et al</i> ^[30] , 2007	19 symptomatic	IE biliary dilation 9 IE stones 7 CBD stones 4	PSS group: PTBD 1 SRS 10 NPSS group: ES + stent 2 ES + SE 1 PTBD 6 BA 4	19 pts 8.3 yr	PSS group: BA 5 NPSS group PTBD 1 after ERCP and 4 after BA	Resolution 17 Death 3
Oo <i>et al</i> ^[17] , 2009	13 symptomatic	Stenosis 13 CBD stones 10 GB stones 11	UDCA 1 Stent 7 ES + SE 1 Failed ERCP 4	2 yr (1-18 aa)	Metallic stent 3 Stent exchange 2 PSS 3 (2 TIPS, 1 surgical) LT 1	Haemobilia 2 Sepsis 3
Llop <i>et al</i> ^[1] , 2011	14 symptomatic	Stenosis 14 CBD stones 6 GB stones 2	ES + SE 6 ES + UDCA 2 Cholecystectomy 2	-	Multiple ERCP 1 BA 1	-
Saraswat <i>et al</i> ^[24] , 2013	20 symptomatic	Stenosis 20 CBD stones 8 GB stones 6	ES + SE 8 Stent 9 BD + stent 11	18 mesi (range 3-188)	Multiple ERCP 11	In 130 procedures: Cholangitis 40 Haemobilia 9 - Resolution 5
Ramchandani <i>et al</i> ^[31] , 2013	5 symptomatic	CBD stenosis 2 CHD stenosis 1 CBD stones 2	Metallic stent 1 Plastic stent 2 BD + stent 1 Intracholedocal lithotripsy 1	6-7 mo	SRS 2 Stent Exchange 1	-
Cellich <i>et al</i> ^[23] , 2015	8 symptomatic 1 asymptomatic	Stenosis 7 CBD stones 3 GB stones 1	ES 7 BD 4 SE 2 Stent 7	-	PSS 1 Stent exchange 3 BA 3	Cholangitis 3 Haemobilia 1

CBD: Common bile duct; GB: Gallbladder; IE: Intrahepatic; ES: Endoscopic sphincterotomy; SE: Stone extraction; NBD: Nasobiliary drainage; BD: Balloon dilation; PSS: Porto-systemic shunt; NPSS: No porto-systemic shunt; UDCA: Ursodeoxycholic acid; ERCP: Endoscopic retrograde cholangio-pancreatography; BA: Bilioenteric anastomosis; SRS: Splenorenal shunt; LT: Liver transplantation; TIPS: Transjugular intrahepatic porto-systemic shunt.

ulcer and one for cholangitis and haemobilia after 8.6 years from biliodigestive anastomosis, 2 patients died for intraoperative bleeding during surgery on bile duct (choledocholithotomy and hepaticojejunostomy), suggesting a higher risk of bleeding from biliary tree due to the presence of numerous compensatory collateral veins and the congestion of biliary and splanchnic venous system. Table 4^[2,3,19,25,30,51-58] summarized

papers about surgical intervention in PB patients.

TIPS

In addition to surgical PSS, a TIPS placement can be a valid alternative to improve portal hypertension. Since 1996, Görgül *et al*^[59] observed the resolution of "pseudocholangiocarcinoma" sign after TIPS in 3 patients. In a case report, a 45-years-old woman

Table 3 Endoscopic management of portal biliopathy: summary of case reports

Ref.	Patients	Biliary abnormalities	First treatment	Follow-up	Further treatment	Complications
Mörk <i>et al</i> ^[32] , 1998	2	CBD stenosis 2	Stent 2	-	Multiple Stent exchange + PSS 1	Cholangitis 1
Solmi <i>et al</i> ^[33] , 1998	1	Stenosis	Stent	-	-	-
Mutignani <i>et al</i> ^[34] , 2002	3	CBD stenosis 3	Stent 3	-	PSS 3	Haemobilia 3
Perego <i>et al</i> ^[35] , 2003	1	Stenosis + CBD stones	- Stent	3 yr	Multiple stent exchange→PTBD + dilation and SE	-
Umphress <i>et al</i> ^[15] , 2004	M, 62 yr	IE and CBD stones	ES + SE + stent	1 yr	Stent exchange and cholecistectomy	-
Guerrero Hernández <i>et al</i> ^[36] , 2005	M, 29 yrs	CBD stenosis	ERBD + Sugiura	-	-	-
Rosenthal <i>et al</i> ^[37] , 2008	F, 44 yr	CBD stenosis and stones	Stent + SE	-	PSS	-
Ajayi <i>et al</i> ^[38] , 2009	F, 13 yr	Stenosis	ES + BD + stent	6 mo	Multiple stent exchange	-
Layec <i>et al</i> ^[39] , 2009	F, 74 yr	Stenosis	Metallic stent	18 mo	Metallic stent	Haemobilia
Sharma <i>et al</i> ^[40] , 2009	M, 35 yr	CBD stenosis 3	ES+SE 3	-	-	Haemobilia 3
	F, 30 yr					
	M, 25 yr					
Vasiliadis <i>et al</i> ^[41] , 2009	F, 39 yr	CBD stenosis	ES	19 mo	Multiple stent exchange→PSS + cholecistectomy	-
Cantù <i>et al</i> ^[42] , 2010	M, 31 yr	CBD stenosis	ES + stent	4 yr	-	-
Martinez <i>et al</i> ^[43] , 2011	M, 34 yr	IE dilataions	Stent	-	-	-
Mistry <i>et al</i> ^[44] , 2012	M, 28 yr	CBD stenosis	BD + BA + PTBD	-	Percutaneous transhepatic-gastrostomy	Haemobilia
					Cholecistectomy	-
Alam <i>et al</i> ^[45] , 2012	M, 30 yr	CBD stenosis 2	PTBD	-		
	F, 19 yr	GB stones 1	Stent			
		CBD stones 1				
D'Souza <i>et al</i> ^[46] , 2013	M, 49 yr	CBD stenosis	Stent + BD (after stent removal)	-	PSS + splenectomy	Haemobilia (post-biopsy)
Bernon <i>et al</i> ^[47] , 2014	M, 36 yr	CBD stenosis and stones	SE + stent	1 yr	Stent exchange→PTBD→cholecistectomy, intrahepatic 3 semgment bypass	Cholangitis
Hyun <i>et al</i> ^[26] , 2015	M, 33 yr	CBD stenosis	ERBD→PTBD + portal stent	3 mo	-	Haemobilia

CBD: Common bile duct; ES: Endoscopic sphincterotomy; SE: Stone extraction; BD: Balloon dilation; PSS: Porto-systemic shunt; IE: Intrahepatic; BA: Bilioenteric anastomosis; ERBD: Endoscopic retrograde biliary drainage; PTBD: Percutaneous transhepatic biliary drainage.

affected by cholestatic jaundice due to compression on CBD by extrahepatic portal and splenic vein thrombosis with collateral, was treated with TIPS: in order to decompress the biliary tree before the procedure, a biliary stent was placed and the day after TIPS was successfully performed. The biliary stent was removed after 1 wk and, at 14 mo follow-up, the patient was asymptomatic and MR/MRCP showed a significant improvement of biliary alterations and of cavernoma size^[60]. Another case report described resolution of cholangiographic CBD abnormalities and normalization of LFTs after TIPS performed in a patient with PB and portal hypertension secondary to PVT^[61]. In the case series published by Cellich *et al*^[23] including 13 PB patients, one of these was initially treated with TIPS that was unsuccessful; patient underwent PSS and multiple endoscopic treatment and, at least, bilioenteric anastomosis. Oo *et al*^[17] reported 2 patients successfully treated with TIPS: one after repeated ERCP with plastic stent exchanges obtaining resolution of biliary symptoms and reduction in portal pressure; the second was successfully treated with temporary PTBD placement followed by TIPS. Even if the use of TIPS in PB patients is anecdotal, this technique seems effective and safe in treatment of portal hypertension and PB secondary to PC. However, due to the vascular

alterations secondary to PC, TIPS is not always technically feasible.

LT

There are few data about LT for PB patients. In literature only 4 cases are reported (1 regarding a paediatric patient), 2 living donor LT and 2 deceased donor LT^[62-65]. Indication for LT was secondary biliary cirrhosis, recurrent cholangitis (even with suspicion of cholangiocarcinoma) despite multiple endoscopic treatments, often associated with gastrointestinal bleeding^[62-64]; Zhang *et al*^[65] reported 3 successful living donor LT in 3 paediatric patients with PC, one of these with jaundice and evidence of dilated biliary duct due to PC compression, consistent with PB; however, in all 3 cases the major indication for LT was deteriorating liver function ad recurrent gastrointestinal bleeding. In all the 4 cases of LT for PB the outcome was favourable after a follow up of 12-26 mo.

CONCLUSION

PB is a frequent complication in patients with chronic PVT and PC, however symptoms are present in a minority of cases and only symptomatic patients require therapy.

Table 4 Surgical management of portal biliopathy: summary of case series and case reports

Ref.	No. of patients	Biliary abnormalities	First treatment	Follow-up	Further treatments	Complications/outcome
Chaudhary <i>et al</i> ^[53] , 1998	9 symptomatic	Stenosis: 2 CBD stones: 2	BA 2 SRS 7	9 pts -	BA 2 Stent 1 ES + SE 2	Death 1 Resolution 7
Condat <i>et al</i> ^[53] , 2003	7 symptomatic	Cholecystitis/right hypocondrial pain 4 Cholangitis 1 Stenosis 2	Cholecystostomy + ERCP 1 Stent 1 BA+PTBD 1	4-25 mo	-	Haemobilia 1
Gauthier-Villars <i>et al</i> ^[19] , 2005	8 symptomatic (pediatric)	Stenosis 6 Biliary dilation 8	- PSS 8	8 pts 4.5-15 yr	-	Complete resolution 7 Partial resolution 1
Khare <i>et al</i> ^[25] , 2005	13 symptomatic	A: Stenosis 5 B: CBD stones 3 C: Stenosis + CBD stones 5	A: PSS 4; BA 1 B: ERCP 2; PSS + BA 1 C: Unsuccessful ERCP 4; PSS 3; Splenectomy + devasc 2	-	A: Multiple ERCP: 1 B: Splenectomy 1 (post-ERCP) C: Multiple ERCP 2; BA 1; Splenectomy + BA 1	Death 1
Vibert <i>et al</i> ^[30] , 2007	19 symptomatic	IE biliary dilation 9 IE stones 7 CBD stones 4	PSS group: PTBD 1 SRS 10 NPSS group: ES + stent 2 ES + SE 1 PTBD 6 BA 4	19 pts 4-30 mo	PSS group: BA 5 NPSS group PTBD 1 after ERCP and 4 after BA	Resolution 17 Death 3
Dhiman <i>et al</i> ^[2] , 2007	12 symptomatic	Stenosis: 7 CBD stones: 5 Choledochal varices 2 Mirizzi's syndrome 1	PSS 5 ES 3 ES + dilation 2 Stent 4	19 mo (range 6-132)	Multiple stent exchange in pts initially treated with stent	Cholangitis in 2 pts treated with stent
D'Souza <i>et al</i> ^[54] , 2009	1 symptomatic	CBD stenosis + GB stones	Pre-surgery stent→PSS + BA (single stage)	18 mo	-	Resolution
Camerlo <i>et al</i> ^[51] , 2010	3 symptomatic	Stenosis 3	PSS 3 Stent 1 (pre-PSS)	3 pts 2-13 yr	-	Resolution 3
Agarwal <i>et al</i> ^[55] , 2011	39 symptomatic	Stenosis 15 CBD stones 7 GB stones 12 IE dilation 39	SRS 37 BA 2	37 pts 32 mo	ES ± SE 10 BA 12 ES + cholecystectomy 1	Resolution 35
Chattopadhyay <i>et al</i> ^[52] , 2012	24 symptomatic 32 asymptomatic	CBD stenosis 3 Multiple stenosis 5 IE dilation 14 CBD stones 7 GB stones 11 Stenosis 3	ERCP pre-surgery 12 PSS 40 Splenectomy + devasc. 16 UDCA 1 BA 1 Cholecistectomy	43 pts 48 mo (range 14-120)	ES + SE 2 Multiple ES + stent 5 BA 2	Resolution 38 Death 1
Suárez <i>et al</i> ^[56] , 2013	3 symptomatic	Stenosis 3	UDCA 1 BA 1 Cholecistectomy	-	-	-
Bhatia <i>et al</i> ^[57] , 2014	2 symptomatic	GB stones	Cholecistectomy	-	-	Resolution
Liu <i>et al</i> ^[58] , 2015	18	Stenosis 6 Dilations 6 Stenosis + dilations 6	PSS 18	-	-	Resolution 15

CBD: Common bile duct; GB: Gallbladder; IE: Intrahepatic; ES: Endoscopic sphincterotomy; SE: Stone extraction; BD: Balloon dilation; PSS: Porto-systemic shunt; NPSS: No porto-systemic shunt; UDCA: Ursodeoxycholic acid; ERCP: Endoscopic retrograde cholangio-pancreatography; BA: Bilioenteric anastomosis; SRS: Splenorenal shunt; FU: Follow-up.

The majority of patients with PC and PB need multiple treatments during their life, aimed both to decompress portal circle and to resolve biliary abnormalities and symptoms; only few patients have a complete resolution of biliary and vascular problem after the first intervention, and it can be seen more often in PSS performed for PC compressing the bile duct. In most cases a combined approach is required (endoscopy and surgery), but a consensus on the timing and priority of treatments is not still available.

In Figure 3 we propose a possible algorithm for the management of PB. For asymptomatic patients, no specific therapy is required except the eventual

treatment of portal hypertension complications; during follow-up LFTs monitoring is suggested. For symptomatic patients, cholecistectomy is recommended in case of gallbladder stones or cholecystitis alone. In case of PB due to PC compression (varicoid type), surgical PSS or TIPS (when feasible) should resolve both PC and biliary stenosis. However, if cholangitis or choledocholithiasis are present, they should be treated at first. In case of mixed type, an ischemic damage coexist with the compressive one and the only PSS will not solve the problem; in these case, further interventions on the biliary system are needed: consider ES with/without stent placement and, in case of persistence of bili-

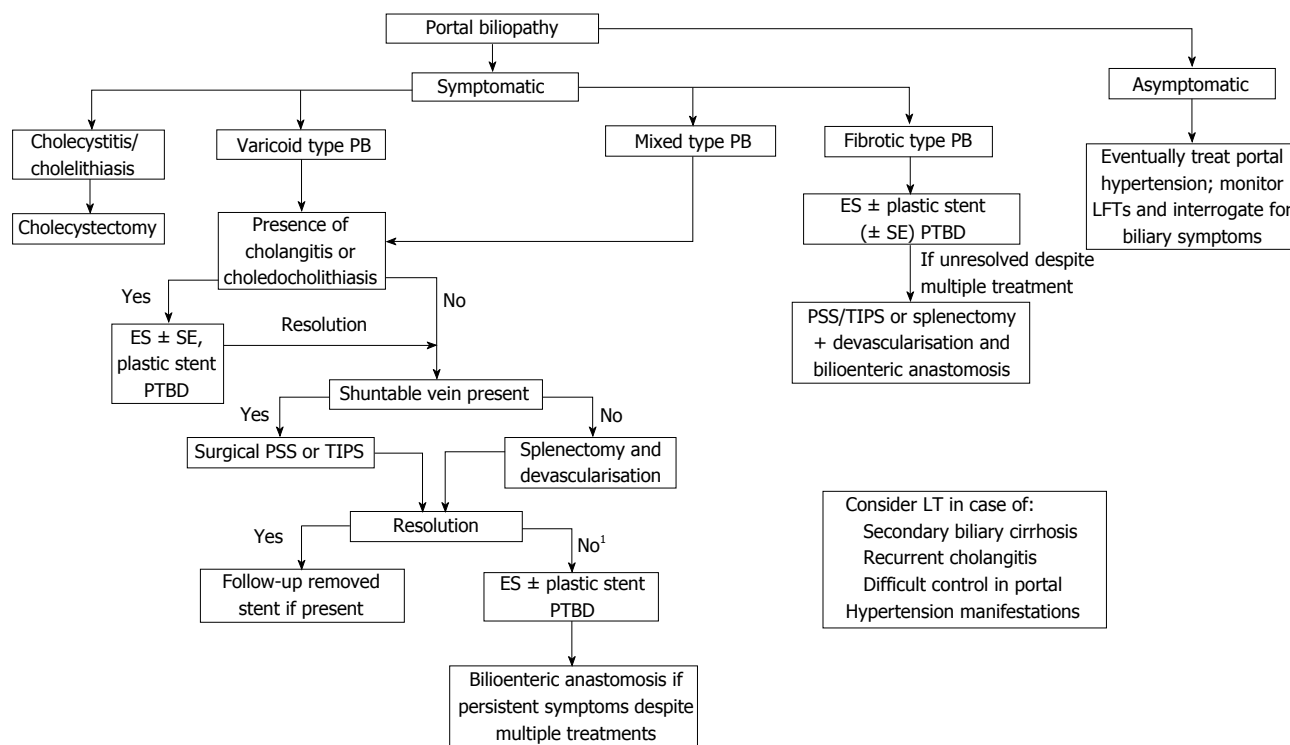


Figure 3 Proposed algorithm for portal biliopathy management. ¹Unsuccessful vascular surgery is frequent in mixed type because of co-presence of ischemic and compressive damage. ES: Endoscopic sphincterotomy; SE: Stone extraction; LFTs: Liver function tests; LT: Liver transplantation; PTBD: Percutaneous transhepatic biliary drainage; PB: Portal biliopathy; PSS: Porto-systemic shunt; TIPS: Transjugular intrahepatic porto-systemic shunt.

ary symptoms despite multiple endoscopic treatments, surgical intervention of bilioenteric anastomosis. When a fibrotic type of PB is diagnosed, PSS will not resolve the biliary alterations. In these cases, PB resolution is difficult to achieve and multiple endoscopic/surgical biliary treatments are required. Patients can be evaluated for LT in case of secondary biliary cirrhosis, recurrent cholangitis despite multiple endoscopic treatments or difficult control in portal hypertension manifestations.

REFERENCES

- 1 Llop E, de Juan C, Seijo S, García-Criado A, Abrales JG, Bosch J, García-Pagán JC. Portal cholangiopathy: radiological classification and natural history. *Gut* 2011; **60**: 853-860 [PMID: 21270119 DOI: 10.1136/gut.2010.230201]
- 2 Dhiman RK, Behera A, Chawla YK, Dilawari JB, Suri S. Portal hypertensive biliopathy. *Gut* 2007; **56**: 1001-1008 [PMID: 17170017 DOI: 10.1136/gut.2006.103606]
- 3 Condat B, Vilgrain V, Asselah T, O'Toole D, Rufat P, Zappa M, Moreau R, Valla D. Portal cavernoma-associated cholangiopathy: a clinical and MR cholangiography coupled with MR portography imaging study. *Hepatology* 2003; **37**: 1302-1308 [PMID: 12774008 DOI: 10.1053/jhep.2003.50232]
- 4 Duseja A. Portal cavernoma cholangiopathy-clinical characteristics. *J Clin Exp Hepatol* 2014; **4**: S34-S36 [PMID: 25755593 DOI: 10.1016/j.jceh.2013.05.014]
- 5 Malkan GH, Bhatia SJ, Bashir K, Khemani R, Abraham P, Gandhi MS, Radhakrishnan R. Cholangiopathy associated with portal hypertension: diagnostic evaluation and clinical implications. *Gastrointest Endosc* 1999; **49**: 344-348 [PMID: 10049418 DOI: 10.1016/S0016-5107(99)70011-8]
- 6 Dilawari JB, Chawla YK. Pseudosclerosing cholangitis in extrahepatic portal venous obstruction. *Gut* 1992; **33**: 272-276 [PMID: 1541425 DOI: 10.1136/gut.33.2.272]
- 7 Bayraktar Y, Balkanci F, Kayhan B, Ozenç A, Arslan S, Telatar H. Bile duct varices or "pseudo-cholangiocarcinoma sign" in portal hypertension due to cavernous transformation of the portal vein. *Am J Gastroenterol* 1992; **87**: 1801-1806 [PMID: 1449145]
- 8 Baskan O, Erol C, Sahingoz Y. Portal biliopathy, magnetic resonance imaging and magnetic resonance cholangiopancreatography findings: a case series. *Gastroenterol Rep (Oxf)* 2016; **4**: 68-72 [PMID: 25216728 DOI: 10.1093/gastro/gou062]
- 9 Le Roy B, Gelli M, Serji B, Memeo R, Vibert E. Portal biliopathy as a complication of extrahepatic portal hypertension: etiology, presentation and management. *J Visc Surg* 2015; **152**: 161-166 [PMID: 26025414 DOI: 10.1016/j.jviscsurg.2015.04.003]
- 10 Chandra R, Kapoor D, Tharakan A, Chaudhary A, Sarin SK. Portal biliopathy. *J Gastroenterol Hepatol* 2001; **16**: 1086-1092 [PMID: 11686833 DOI: 10.1046/j.1440-1746.2001.02562.x]
- 11 Dhiman RK, Saraswat VA, Valla DC, Chawla Y, Behera A, Varma V, Agarwal S, Duseja A, Puri P, Kalra N, Rameshbabu CS, Bhatia V, Sharma M, Kumar M, Gupta S, Taneja S, Kaman L, Zargar SA, Nundy S, Singh SP, Acharya SK, Dilawari JB. Portal cavernoma cholangiopathy: consensus statement of a working party of the Indian national association for study of the liver. *J Clin Exp Hepatol* 2014; **4**: S2-S14 [PMID: 25755591 DOI: 10.1016/j.jceh.2014.02.003]
- 12 Dhiman RK, Puri P, Chawla Y, Minz M, Bapuraj JR, Gupta S, Nagi B, Suri S. Biliary changes in extrahepatic portal venous obstruction: compression by collaterals or ischemic? *Gastrointest Endosc* 1999; **50**: 646-652 [PMID: 10536320 DOI: 10.1016/S0016-5107(99)80013-3]
- 13 Harmanci O, Bayraktar Y. How can portal vein cavernous transformation cause chronic incomplete biliary obstruction? *World J Gastroenterol* 2012; **18**: 3375-3378 [PMID: 22807606 DOI: 10.3748/wjg.v18.i26.3375]
- 14 Khuroo MS, Yattoo GN, Zargar SA, Javid G, Dar MY, Khan

- BA, Boda MI. Biliary abnormalities associated with extrahepatic portal venous obstruction. *Hepatology* 1993; **17**: 807-813 [PMID: 8491448 DOI: 10.1002/hep.1840170510]
- 15 **Umphress JL**, Pecha RE, Urayama S. Biliary stricture caused by portal biliopathy: diagnosis by EUS with Doppler US. *Gastrointest Endosc* 2004; **60**: 1021-1024 [PMID: 15605028 DOI: 10.1016/S0016-5107(04)02216-3]
 - 16 **Shin SM**, Kim S, Lee JW, Kim CW, Lee TH, Lee SH, Kim GH. Biliary abnormalities associated with portal biliopathy: evaluation on MR cholangiography. *AJR Am J Roentgenol* 2007; **188**: W341-W347 [PMID: 17377002 DOI: 10.2214/AJR.05.1649]
 - 17 **Oo YH**, Olliff S, Haydon G, Thorburn D. Symptomatic portal biliopathy: a single centre experience from the UK. *Eur J Gastroenterol Hepatol* 2009; **21**: 206-213 [PMID: 19212209 DOI: 10.1097/MEG.0b013e3283060ee8]
 - 18 **Dhiman RK**, Chawla Y, Duseja A, Chhetri D, Dilawari J. Portal hypertensive biliopathy (PHB) in patients with extrahepatic portal venous obstruction (EHPVO). *J Gastroenterol Hepatol* 2006; **21**: A504
 - 19 **Gauthier-Villars M**, Franchi S, Gauthier F, Fabre M, Pariente D, Bernard O. Cholestasis in children with portal vein obstruction. *J Pediatr* 2005; **146**: 568-573 [PMID: 15812469 DOI: 10.1016/j.jpeds.2004.12.025]
 - 20 **Perlemuter G**, Béjanin H, Fritsch J, Prat F, Gaudric M, Chaussade S, Buffet C. Biliary obstruction caused by portal cavernoma: a study of 8 cases. *J Hepatol* 1996; **25**: 58-63 [PMID: 8836902 DOI: 10.1016/S0168-8278(96)80328-X]
 - 21 **Schlansky B**, Kaufman JA, Bakis G, Naugler WE. Portal Biliopathy Causing Recurrent Biliary Obstruction and Hemobilia. *ACG Case Rep J* 2013; **1**: 44-46 [PMID: 26157818 DOI: 10.14309/crj.2013.16]
 - 22 **Dumortier J**, Vaillant E, Boillot O, Poncet G, Henry L, Scoazec JY, Partensky C, Valette PJ, Paliard P, Ponchon T. Diagnosis and treatment of biliary obstruction caused by portal cavernoma. *Endoscopy* 2003; **35**: 446-450 [PMID: 12701019]
 - 23 **Cellich PP**, Crawford M, Kaffes AJ, Sandroussi C. Portal biliopathy: multidisciplinary management and outcomes of treatment. *ANZ J Surg* 2015; **85**: 561-566 [PMID: 24237891 DOI: 10.1111/ans.12436]
 - 24 **Saraswat VA**, Rai P, Kumar T, Mohindra S, Dhiman RK. Endoscopic management of portal cavernoma cholangiopathy: practice, principles and strategy. *J Clin Exp Hepatol* 2014; **4**: S67-S76 [PMID: 25755598 DOI: 10.1016/j.jceh.2013.08.011]
 - 25 **Khare R**, Sikora SS, Srikanth G, Choudhuri G, Saraswat VA, Kumar A, Saxena R, Kapoor VK. Extrahepatic portal venous obstruction and obstructive jaundice: approach to management. *J Gastroenterol Hepatol* 2005; **20**: 56-61 [PMID: 15610447 DOI: 10.1111/j.1440-1746.2004.03528.x]
 - 26 **Hyun D**, Park KB, Lim SJ, Hwang JH, Sinn DH. Portal Vein Stenting for Portal Biliopathy with Jaundice. *Cardiovasc Intervent Radiol* 2016; **39**: 620-623 [PMID: 26518011 DOI: 10.1007/s00270-015-1222-0]
 - 27 **Bhatia V**, Jain AK, Sarin SK. Choledocholithiasis associated with portal biliopathy in patients with extrahepatic portal vein obstruction: management with endoscopic sphincterotomy. *Gastrointest Endosc* 1995; **42**: 178-181 [PMID: 7590059 DOI: 10.1016/S0016-5107(95)70080-3]
 - 28 **Sezgin O**, Oğuz D, Altıntaş E, Sarıtaş U, Sahin B. Endoscopic management of biliary obstruction caused by cavernous transformation of the portal vein. *Gastrointest Endosc* 2003; **58**: 602-608 [PMID: 14520303 DOI: 10.1067/S0016-5107(03)01975-8]
 - 29 **Dhiman R**, Chhetri D, Behera A, Duseja A, Chawla Y, Singh P, Suri S. Management of biliary obstruction in patients with portal hypertensive biliopathy (PHB). *J Gastroenterol Hepatol* 2006; **21**: A505
 - 30 **Vibert E**, Azoulay D, Aloia T, Pascal G, Veilhan LA, Adam R, Samuel D, Castaing D. Therapeutic strategies in symptomatic portal biliopathy. *Ann Surg* 2007; **246**: 97-104 [PMID: 17592297 DOI: 10.1097/SLA.0b013e318070cada]
 - 31 **Ramchandani M**, Nageshwar Reddy D, Lakhtakia S, Gupta R, Tandan M, Rao GV. Role of single-operator per-oral cholangioscopy and intraductal US in assessment of portal biliopathy (with videos). *Gastrointest Endosc* 2014; **79**: 1015-1019 [PMID: 24713306 DOI: 10.1016/j.gie.2014.01.042]
 - 32 **Mörk H**, Weber P, Schmidt H, Goerig RM, Scheurlen M. Cavernous transformation of the portal vein associated with common bile duct strictures: report of two cases. *Gastrointest Endosc* 1998; **47**: 79-83 [PMID: 9468430 DOI: 10.1016/S0016-5107(98)70305-0]
 - 33 **Solmi L**, Rossi A, Conigliaro R, Sassatelli R, Gandolfi L. Endoscopic treatment of a case of obstructive jaundice secondary to portal cavernoma. *Ital J Gastroenterol Hepatol* 1998; **30**: 202-204 [PMID: 9675660]
 - 34 **Mutignani M**, Shah SK, Bruni A, Perri V, Costamagna G. Endoscopic treatment of extrahepatic bile duct strictures in patients with portal biliopathy carries a high risk of haemobilia: report of 3 cases. *Dig Liver Dis* 2002; **34**: 587-591 [PMID: 12502216 DOI: 10.1016/S1590-8658(02)80093-7]
 - 35 **Perego P**, Cozzi G, Bertolini A. Portal biliopathy. *Surg Endosc* 2003; **17**: 351-352 [PMID: 12417962 DOI: 10.1007/s00464-002-4224-3]
 - 36 **Guerrero Hernández I**, Weimersheimer Sandoval M, López Méndez E, Hernández Calleros J, Tapia AR, Uribe M. Biliary stricture caused by portal biliopathy: case report and literature review. *Ann Hepatol* 2005; **4**: 286-288 [PMID: 16432497]
 - 37 **Rosenthal MD**, White GH, Stephen MS, Gallagher JJ, Sandroussi C. Vascular biliopathy as a cause of common bile duct obstruction successfully treated by mesocaval shunt and endoscopic retrograde cholangiopancreatography biliary stent placement. *Vascular* 2008; **16**: 356-358 [PMID: 19344595 DOI: 10.2310/6670.2008.00066]
 - 38 **Ajayi AO**, Chandrasekar TS, Hammed AH. Portal biliopathy in a 13-year-old Asian girl: a case report and review of literature. *Ann Afr Med* 2009; **8**: 185-188 [PMID: 19884697 DOI: 10.4103/1596-3519.57244]
 - 39 **Layec S**, D'Halluin PN, Pagenault M, Bretagne JF. Massive hemobilia during extraction of a covered self-expandable metal stent in a patient with portal hypertensive biliopathy. *Gastrointest Endosc* 2009; **70**: 555-556; discussion 556 [PMID: 19595317 DOI: 10.1016/j.gie.2009.04.051]
 - 40 **Sharma M**, Ponnusamy RP. Is balloon sweeping detrimental in portal biliopathy? A report of 3 cases. *Gastrointest Endosc* 2009; **70**: 171-173 [PMID: 19409559 DOI: 10.1016/j.gie.2008.11.002]
 - 41 **Vasiliadis K**, Engelmann G, Sauer P, Weitz J, Schmidt J. Right porto-ovarian H-shunt for the surgical treatment of symptomatic portal biliopathy: a case report and literature review. *HPB Surg* 2009; **2009**: 152195 [PMID: 19584934 DOI: 10.1155/2009/152195]
 - 42 **Cantù P**, Bezzio C. Role of a short-term stent-trial in a patient with biliary stricture and portal hypertensive biliopathy: long-term outcome result. *Dig Dis Sci* 2011; **56**: 1242-1244 [PMID: 20721626 DOI: 10.1007/s10620-010-1372-5]
 - 43 **Martínez AF**, Bonacini M, Roberts JP. Image of the month. Portal hypertensive biliopathy. *Arch Surg* 2011; **146**: 625-626 [PMID: 21576616 DOI: 10.1001/archsurg.2011.98-a]
 - 44 **Mistry JH**, Varma V, Mehta N, Kumaran V, Nundy S, Gupta A. Percutaneous transhepatic hepaticogastrostomy for portal biliopathy: a novel approach. *Trop Gastroenterol* 2012; **33**: 140-143 [PMID: 23025062 DOI: 10.7869/tg.2012.32]
 - 45 **Alam MS**, Bin Khalid QS, Zeeshan M, Haider Z. Portal biliopathy. *J Pak Med Assoc* 2012; **62**: 177-180 [PMID: 22755387]
 - 46 **D'Souza SL**, Davenport MS, Elta GH. Biliary stricture secondary to portal biliopathy. *Gastrointest Endosc* 2013; **78**: 942-94; discussion 942-94; [PMID: 24021489 DOI: 10.1016/j.gie.2013.07.052]
 - 47 **Bernon MM**, Sonderup MW, Chinnery GE, Bornman PC, Krige JE. Single-stage definitive surgical treatment for portal biliopathy. *S Afr J Surg* 2014; **52**: 57-60 [PMID: 25216098 DOI: 10.7196/sajs.2062]
 - 48 **Kim HB**, Pomposelli JJ, Lillehei CW, Jenkins RL, Jonas MM, Krawczuk LE, Fishman SJ. Mesogonadal shunts for extrahepatic portal vein thrombosis and variceal hemorrhage. *Liver Transpl* 2005; **11**: 1389-1394 [PMID: 16237690 DOI: 10.1002/lt.20487]
 - 49 **Drews JA**, Castagna J. Inferior mesorenal shunt as a second procedure for portal decompression. *Surg Gynecol Obstet* 1976; **142**: 84-86 [PMID: 1081743]
 - 50 **Warren WD**, Salam A, Smith RB. The meso-spleno-renal shunt

- procedures: a comprehensive approach to portasystemic decompression. *Ann Surg* 1974; **179**: 791-798 [PMID: 4545091 DOI: 10.1097/0000658-197405000-00035]
- 51 **Camerlo A**, Fara R, Barbier L, Grégoire E, Le Treut YP. Which treatment to choose for portal biliopathy with extensive portal thrombosis? *Dig Surg* 2010; **27**: 380-383 [PMID: 20938181 DOI: 10.1159/000314610]
 - 52 **Chattopadhyay S**, Govindasamy M, Singla P, Varma V, Mehta N, Kumaran V, Nundy S. Portal biliopathy in patients with non-cirrhotic portal hypertension: does the type of surgery affect outcome? *HPB (Oxford)* 2012; **14**: 441-447 [PMID: 22672545 DOI: 10.1111/j.1477-2574.2012.00473.x]
 - 53 **Chaudhary A**, Dhar P, Sarin SK, Sachdev A, Agarwal AK, Vij JC, Broor SL. Bile duct obstruction due to portal biliopathy in extrahepatic portal hypertension: surgical management. *Br J Surg* 1998; **85**: 326-329 [PMID: 9529484 DOI: 10.1046/j.1365-2168.1998.00591.x]
 - 54 **D'Souza MA**, Desai D, Joshi A, Abraham P, Shah SR. Bile duct stricture due to caused by portal biliopathy: Treatment with one-stage portal-systemic shunt and biliary bypass. *Indian J Gastroenterol* 2009; **28**: 35-37 [PMID: 19529903 DOI: 10.1007/s12664-009-0010-7]
 - 55 **Agarwal AK**, Sharma D, Singh S, Agarwal S, Girish SP. Portal biliopathy: a study of 39 surgically treated patients. *HPB (Oxford)* 2011; **13**: 33-39 [PMID: 21159101 DOI: 10.1111/j.1477-2574.2010.00232.x]
 - 56 **Suárez V**, Puerta A, Santos LF, Pérez JM, Varón A, Botero RC. Portal hypertensive biliopathy: A single center experience and literature review. *World J Hepatol* 2013; **5**: 137-144 [PMID: 23556047 DOI: 10.4254/wjh.v5.i3.137]
 - 57 **Bhatia P**, John S, Kalhan S, Khetan M. Primary laparoscopic cholecystectomy in patients with portal cavernoma and non-obstructive portal biliopathy: Two case reports. *J Minim Access Surg* 2014; **10**: 161-162 [PMID: 25013336 DOI: 10.4103/0972-9941.134885]
 - 58 **Liu Y**, Hou B, Chen R, Jin H, Zhong X, Ye W, Liang C. Biliary collateral veins and associated biliary abnormalities of portal hypertensive biliopathy in patients with cavernous transformation of portal vein. *Clin Imaging* 2015; **39**: 841-844 [PMID: 26004045 DOI: 10.1016/j.clinimag.2015.04.018]
 - 59 **Görgül A**, Kayhan B, Dogan I, Unal S. Disappearance of the pseudo-cholangiocarcinoma sign after TIPSS. *Am J Gastroenterol* 1996; **91**: 150-154 [PMID: 8561119]
 - 60 **Senzolo M**, Cholongitas E, Tibballs J, Patch D, Triantos CK, Samonakis D, Bettany GE, Burroughs AK. Relief of biliary obstruction due to portal vein cavernoma using a transjugular intrahepatic portosystemic shunt (TIPS) without the need for long-term stenting. *Endoscopy* 2006; **38**: 760 [PMID: 16761208 DOI: 10.1055/s-2006-944541]
 - 61 **Bayraktar Y**, Oztürk MA, Egesel T, Cekirge S, Balkanci F. Disappearance of "pseudocholangiocarcinoma sign" in a patient with portal hypertension due to complete thrombosis of left portal vein and main portal vein web after web dilatation and transjugular intrahepatic portosystemic shunt. *J Clin Gastroenterol* 2000; **31**: 328-332 [PMID: 11129276 DOI: 10.1097/00004836-200012000-00012]
 - 62 **Filippini F**, Urbani L, Catalano G, Iaria G, Biancofiore G, Cioni R, Campatelli A, Mosca F, Campani D, Romagnoli P. Portal biliopathy treated by liver transplantation. *Transplantation* 2004; **77**: 326-327 [PMID: 14743009 DOI: 10.1097/01.TP.0000101795.29250.10]
 - 63 **Hajdu CH**, Murakami T, Diflo T, Taouli B, Laser J, Teperman L, Petrovic LM. Intrahepatic portal cavernoma as an indication for liver transplantation. *Liver Transpl* 2007; **13**: 1312-1316 [PMID: 17763385 DOI: 10.1002/lt.21243]
 - 64 **Gupta S**, Singhal A, Goyal N, Vij V, Wadhawan M. Portal biliopathy treated with living-donor liver transplant: index case. *Exp Clin Transplant* 2011; **9**: 145-149 [PMID: 21453234]
 - 65 **Zhang M**, Guo C, Pu C, Ren Z, Li Y, Kang Q, Jin X, Yan L. Adult to pediatric living donor liver transplantation for portal cavernoma. *Hepatol Res* 2009; **39**: 888-897 [PMID: 19467022 DOI: 10.1111/j.1872-034X.2009.00526.x]

P- Reviewer: Guo XZ, Khuroo MS **S- Editor:** Gong ZM
L- Editor: A **E- Editor:** Liu WX





Published by **Baishideng Publishing Group Inc**

8226 Regency Drive, Pleasanton, CA 94588, USA

Telephone: +1-925-223-8242

Fax: +1-925-223-8243

E-mail: bpgoffice@wjgnet.com

Help Desk: <http://www.wjgnet.com/esps/helpdesk.aspx>

<http://www.wjgnet.com>



ISSN 1007-9327

