

Basic Study

Proton pump inhibitor induced collagen expression in colonocytes is associated with collagenous colitis

Shiori Mori, Yui Kadochi, Yi Luo, Rina Fujiwara-Tani, Yukiko Nishiguchi, Shingo Kishi, Kiyomu Fujii, Hitoshi Ohmori, Hiroki Kuniyasu

Shiori Mori, Yui Kadochi, Yi Luo, Rina Fujiwara-Tani, Yukiko Nishiguchi, Shingo Kishi, Kiyomu Fujii, Hitoshi Ohmori, Hiroki Kuniyasu, Department of Molecular Pathology, Nara Medical University, Shijo-cho, Kashihara 634-8521, Japan

Author contributions: Kuniyasu H designed research; Mori S, Kadochi Y, Luo Y, Fujiwara-Tani R and Nishiguchi Y performed research; Kishi S contributed analytic tools; Fujii K and Ohmori H analyzed data; Mori S wrote the paper.

Supported by MEXT KAKENHI, No. 14478268 and No. 16675788.

Institutional review board statement: The study was approved by the Institutional Review Board of the Nara Medical University (No. 937).

Conflict-of-interest statement: The authors disclose no potential conflicts of interest.

Data sharing statement: No additional data are available.

Open-Access: This article is an open-access article which was selected by an in-house editor and fully peer-reviewed by external reviewers. It is distributed in accordance with the Creative Commons Attribution Non Commercial (CC BY-NC 4.0) license, which permits others to distribute, remix, adapt, build upon this work non-commercially, and license their derivative works on different terms, provided the original work is properly cited and the use is non-commercial. See: <http://creativecommons.org/licenses/by-nc/4.0/>

Manuscript source: Unsolicited manuscript

Correspondence to: Hiroki Kuniyasu, MD, PhD, Professor, Chairman, Department of Molecular Pathology, Nara Medical University, 840 Shijo-cho, Kashihara, Nara 634-8521, Japan. cooninh@zb4.so-net.ne.jp
Telephone: +81-744-223051
Fax: +81-744-257308

Received: September 26, 2016

Peer-review started: September 27, 2016

First decision: October 28, 2016

Revised: November 13, 2016

Accepted: January 2, 2017

Article in press: January 3, 2017

Published online: March 7, 2017

Abstract

AIM

To elucidate the role of proton pump inhibitors (PPIs) in collagenous disease, direct effect of PPI on colonocytes was examined.

METHODS

Collagenous colitis is a common cause of non-bloody, watery diarrhea. Recently, there has been increasing focus on the use of proton PPIs as a risk factor for developing collagenous colitis. Mouse CT26 colonic cells were treated with PPI and/or PPI-induced alkaline media. Expression of fibrosis-associated genes was examined by RT-PCR. In human materials, collagen expression was examined by immunohistochemistry.

RESULTS

CT26 cells expressed a $\text{Na}^+\text{-H}^+$ exchanger gene (solute carrier family 9, member A2). Treatment with PPI and/or PPI-induced alkaline media caused growth inhibition and oxidative stress in CT26 cells. The treatment increased expression of fibrosis inducing factors, transforming growth factor β and fibroblast growth factor 2. The treatment also decreased expression of a negative regulator of collagen production, replication factor C1, resulting in increased expression of collagen types III and IV in association with lipid peroxide. In biopsy specimens from patients with collagenous colitis, type III and IV collagen were increased. Increase of type III collagen was more pronounced in PPI-associated collagenous colitis than in non-PPI-

associated disease.

CONCLUSION

From these findings, the reaction of colonocytes to PPI might participate in pathogenesis of collagenous colitis.

Key words: Proton pump inhibitor; Collagenous colitis; pH; Fibrosis; Oxidative stress

© The Author(s) 2017. Published by Baishideng Publishing Group Inc. All rights reserved.

Core tip: The main contribution of our paper is the finding of the basic mechanism of proton pump inhibitor evoking collagenous colitis with direct effects to colon epithelial cells. The collagenous colitis is a major cause of non-hemorrhagic watery diarrhea; however, the mechanism of the disease has not been fully elucidated. Our research findings show that proton pump inhibitor causes oxidative stress and collagen synthesis in colon epithelial cells, which might provide an impact to understanding pathogenesis of collagenous colitis and the side effect of proton pump inhibitor.

Mori S, Kadochi Y, Luo Y, Fujiwara-Tani R, Nishiguchi Y, Kishi S, Fujii K, Ohmori H, Kuniyasu H. Proton pump inhibitor induced collagen expression in colonocytes is associated with collagenous colitis. *World J Gastroenterol* 2017; 23(9): 1586-1593 Available from: URL: <http://www.wjgnet.com/1007-9327/full/v23/i9/1586.htm> DOI: <http://dx.doi.org/10.3748/wjg.v23.i9.1586>

INTRODUCTION

Collagenous colitis is one type of microscopic colitis and is the most common cause of non-bloody, watery diarrhea^[1,2]. Originally Freeman *et al*^[3] reported as a colitis with watery diarrhea and a lesion of colonic basement membrane. Collagenous colitis is characterized by collagenous bands at the basement membrane under microscopic examination^[4,5]. This disease is treated with anti-inflammatory agents including salicylate^[6]; however, untreated disease might progress into ulcerative colitis^[7,8].

Recently, proton pump inhibitors (PPIs), especially lansoprazole, have been considered a potential cause of collagenous colitis^[5]. Lansoprazole administration caused collagen bands in colonic mucosa in Mongolian gerbils^[9]. However, the role of PPIs in the pathogenesis of collagenous colitis is not fully understood. Many pathologic mechanisms are proposed: colonic contents, mucosal immunity including autoimmunity and flora-associated immunity, eosinophilic reaction, human leukocyte antigen, biliary acids, anaerobic bacteria, fibroblast activation, and reduction of acidity in colonic contents due to suppression of acid secretion to the gastric juice^[5,10]. In these candidates, the role

of colonocytes' response to PPI is not given adequate attention. In the present study, we attempt to elucidate the pathologic importance of the direct effect of PPIs on colonocytes.

MATERIALS AND METHODS

Surgical specimens

We reviewed the pathology and clinical data of 11 patients with collagenous colitis diagnosed in the Department of Molecular Pathology, Nara Medical University from 2012 to 2015. Two samples of non-pathological colonic mucosa were used as controls. Basic patient information is summarized in Table 1. As written informed consent was not obtained, any identifying information was removed from the samples prior to analysis, in order to ensure strict privacy protection. All procedures were performed in accordance with the Ethical Guidelines for Human Genome/Gene Research enacted by the Japanese Government, which was approved by the Ethics Committee of Nara Medical University (Approval Number 937).

Cell lines

CT26 mouse colon cancer cell line was provided by Professor I. J. Fidler (MD Anderson Cancer Center, Texas University). Cells were cultured in Dulbecco's modified Eagle's medium [DMEM; with high glucose (450 mg/dL), low glucose (100 mg/dL) or no glucose; WAKO Purechemical Ind. Ltd., Osaka, Japan), supplemented with 10% fetal bovine serum (FBS, Sigma Chemical Co., St. Louis, MO, United States) at 37 °C in 5% CO₂. Alkaline (pH 8.0) medium was made from DMEM with addition of Tris-HCl (pH 9.0, Sigma). Cell growth was assessed using a tetrazolium dye assay (MTT, Sigma), as previously described^[11].

Reagents and enzyme-linked immunosorbent assay

Pantoprazole (Sigma), MitoGreen (Takara Bio Inc., Kusatsu, Japan), and 4-hydroxynonenal (4HNE) ELISA kit (R&D Systems Inc., Minneapolis, MN, United States) were purchased. For evaluation of MitoGreen, strength of fluorescence was measured in computer-captured images by using Photoshop Image Analyzer (Adobe Systems Inc., San Jose, CA, United States). 4HNE was measured in cell lysate according to the manufacturers' instructions. Whole-cell lysates were prepared using 0.1% nonidet 40 containing lysis buffer as previously described^[12].

Immunohistochemistry

Consecutive 4-μm sections were immunohistochemically stained using the immunoperoxidase technique described previously^[13]. Anti-type IV collagen antibody and anti-type III collagen antibody (Abcam, Cambridge, MA, United States) were used at a concentration of 0.2 μg/mL. Secondary antibodies (Medical and

Table 1 List of primer sets for RT-PCR

Gene	Symbol	Accession No.	Upper primer	Lower primer
Collagen type IV	<i>Col4a1</i>	NM_009931.2	AAAGGGAGAAAGAGGCTTGC	CCTTGTACCGTTGCATCCT
Collagen type VI	<i>Col6a1</i>	NM_009933.4	GATGAGGGTGAAGTGGGAGA	CAGCACGAAGAGGATGTCAA
Collagen type I	<i>Col1a1</i>	NM_007742.4	GAGCGGAGAGTACTGGATCG	GCTTCTTTTCCTTGGGGTTC
Collagen type III	<i>Col3a1</i>	NM_009930.2	GCACAGCAGTCCAACGTAGA	TCTCCAAATGGGATCTCTGG
Solute carrier family 9, member A2	<i>Slc9a2</i>	NM_001033289.2	ACTGGGGTCACAACITCTGG	CTTCACGGCAGTCATTGAGA
Transforming growth factor β 1	<i>Tgfb1</i>	NM_011577.2	TTGCTTCAGCTCCACAGAGA	TGGTTGTAGAGGGCAAGGAC
Fibroblast growth factor 2	<i>Fgf2</i>	NM_008006.2	AGCGGCTCTACTGCAAGAAC	GCCGTCATCTTCTTCATA
Replication factor C1	<i>Rfc1</i>	NM_011258.2	TGATCACAGGAGTGCTGGAG	CGAGGATTTTGTTCACAGA
Glyceraldehyde-3-phosphate dehydrogenase	<i>Gapdh</i>	NM_001289726.1	AACITTTGGCATTGTGGAAGG	ACACATTGGGGGTAGGAACA

Biological Laboratories, Nagoya, Japan) were used at a concentration of 0.2 μ g/mL. Tissue sections were color-developed with diamine benzidine hydrochloride (DAKO, Glostrup, Denmark), and counterstained with Meyer's hematoxylin (Sigma). We evaluated immunopositivity at the basement membrane and stromal fibers. Staining strength was scored from (-) to (++): (-) is no staining; (+) is staining equal to that of non-pathologic mucosa; (++) is staining more pronounced than that of non-pathologic mucosa. All samples were stained at one time to equalize staining conditions. For a negative control, unimmunized rat IgG (Santa-Cruz Biotechnology, Santa-Cruz, CA, United States) was used as primary antibody.

Reverse transcription-polymerase chain reaction

Reverse transcription-polymerase chain reaction (RT-PCR) of 0.5 μ g total RNA extracted using an RNeasy kit (Qiagen, Germantown, MD, United States) was performed. Primer sets used in the experiment are listed in Table 1. Primers were synthesized by Sigma Genosys (Ishikari, Japan). PCR products were electrophoresed in a 2% agarose gel and stained with ethidium bromide.

Statistical analysis

Statistical significance was calculated by using two-tailed Fisher's exact, Chi-square, and unpaired Student-*t* tests by using InStat software (GraphPad, Los Angeles, CA, United States). Statistical significance was defined as a two-sided *P*-value of < 0.05.

RESULTS

Effect of PPI and/or alkaline pH on cell growth of CT26 cells

The effect of PPIs was examined by using CT26 mouse colon cancer cells treated with pantoprazole and/or alkaline media^[14] (Figure 1). PPI treatment did not affect cell proliferation of CT26 cells regardless of glucose concentration (Figure 1A). In contrast, alkaline media suppressed cell proliferation at 100 and 450 mg/dL glucose concentrations (Figure 1B). When treated with PPI and alkaline media together, cell proliferation in 0 and 450 mg/dL glucose concentrations was suppressed more than in 100 mg/dL glucose

concentration (Figure 1C).

Effect of PPI and/or alkaline pH on oxidative stress and mitochondria volume

Next, oxidative stress was examined by 4HNE levels, as it is a marker for lipid peroxide (Figure 2A and B). Treatment with PPI or alkaline media increased levels of 4HNE in various glucose concentrations. Alkaline media-treated cells showed higher 4HNE levels than PPI-treated cells. Treatment with PPI or alkaline media decreased mitochondrial volume (Figure 2C), particularly in 100 and 450 mg/dL glucose concentrations compared to 0 mg/dL glucose concentration (Figure 2D).

Expression of collagen and collagen-associated genes in CT26 cells

We confirmed the expression of Na⁺-H⁺ exchanger (solute carrier family 9, member A2; *SLC9A2*), a pharmacological target of PPIs (Figure 3A). *SLC9A2* expression was not affected by treatment with PPI or alkaline media. Expression of transforming growth factor (TGF) β and fibroblast growth factor (FGF) 2 was increased by treatment with PPI or alkaline media. TGF- β and FGF2 are known to stimulate collagen-producing fibroblasts^[14]. In contrast, expression of replication factor C1 (*RFC1* or *Alp145*), a negative regulator of collagen expression^[15], was downregulated by treatment with PPI or alkaline media. Compared to other collagen types, mRNA expression of type III and IV collagen was increased in CT26 cells treatment with PPI or alkaline media (Figure 3B-D).

Production of collagen type III and IV in human collagenous colitis mucosa

We confirmed the increase of collagen type III and IV in human colonic mucosa of patients with collagenous colitis (Figure 4). HE and Azan staining showed thickening of the basement membrane at the covering epithelium (Figure 4A-C). Immunohistochemistry of collagen type III showed that collagen fibers were increased at the basement membrane and mucosal stroma when compared with non-pathologic mucosa (Figure 4D and E). In contrast, immunohistochemistry of collagen type IV showed that collagen fibers were increased at the basement membrane alone when

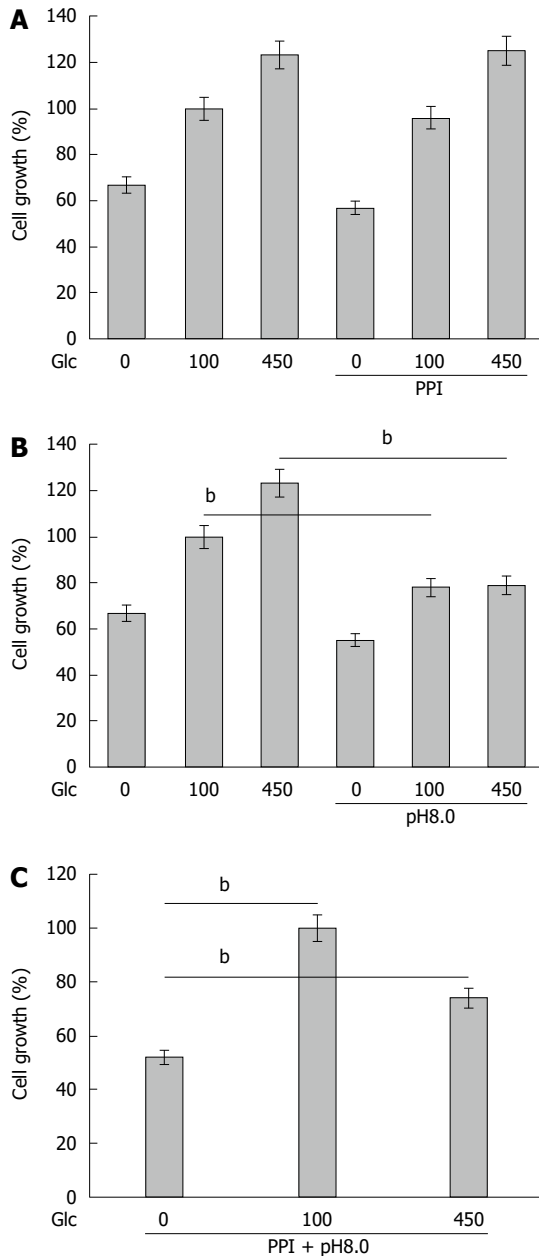


Figure 1 Effect of proton pump inhibitor and/or alkaline pH on CT26 cell growth. Cell growth of CT26 cells was examined in different concentration of glucose (Glc) concentration (0, 100, 450 mg/dL). A: Pantoprazole (10 µg/mL) treatment (PPI); B: DMEM-pH8.0 treatment (pH 8.0); and C: Treatment with PPI and alkaline media (pH 8.0). Error bar, SD calculated from 3 independent experiments by Student's *t*-test. PPI: Proton pump inhibitor. ^b*P* < 0.001.

compared with non-pathologic mucosa.

Finally, expression of collagen type III and IV was compared in 11 collagenous colitis patients (Tables 2 and 3). The levels of collagen type III were increased in PPI-associated collagenous colitis whereas levels of collagen type IV were not different between PPI-associated and non-PPI-associated collagenous colitis.

DISCUSSION

Collagenous colitis is an increasingly common microscopic colitis^[1]. Recently proton pump inhibitors,

Table 2 Expression of collagen III and IV in collagenous colitis

Case no.	Age	Sex	PPI	Expression	
				Collagen III	Collagen IV
1	79	F	+	++	++
2	71	F	+	+++	++
3	87	F	+	++	++
4	26	F	+	+++	++
5	80	M	+	+++	+
6	78	M	+	+++	++
7	80	F	-	++	+
8	45	M	-	+	++
9	67	M	-	++	+
10	59	F	-	+	++
11	77	F	-	++	++

PPI: Proton pump inhibitor.

Table 3 Expression of collagen type III and IV in proton pump inhibitor-associated collagenous colitis

	PPI (+)	PPI (-)	<i>P</i> value
<i>n</i>	6	5	
Age	70.2	65.6	NS
M:F	2:4	2:3	NS
Collagen			
Type III	2.67 ± 0.52	1.6 ± 0.55	0.0089
Type IV	1.83 ± 0.41	1.6 ± 0.55	NS

PPI: Proton pump inhibitor.

especially lansoprazole, are recognized to be associated with onset of collagenous colitis^[5]. Thus, the mechanism of this association is a focus of studies on collagenous colitis. In the present study, we examined the direct effect of PPIs on colonocytes, as well as the effect of increased pH of colonic contents.

We confirmed that the expression of the SLC9A2 Na⁺-H⁺ exchanger is a target of PPIs in the colonocytes. PPIs did not affect CT26 cell growth but alkaline conditions did suppress cell growth. Growth suppression of colonocytes might induce retardation of wound healing causing subsequent persistent inflammation, immune disturbances, and collagen overproduction.

PPI and alkaline condition caused increase of lipid peroxide with decrease of mitochondrial volume. Inhibition of proton efflux might induce acidic alteration of the cytoplasm, which might affect oxidative phosphorylation in mitochondria. Monitoring of mitochondrial function, ATP production and mitochondrial voltage are needed to conclude the effect of PPI on oxidative stress.

PPI and alkaline condition decreased the expression of RFC1, which is a negative regulator of collagen gene expression^[16]. We then examined the alteration of expression of collagen type I, III, IV and VI. Only collagen type III and IV showed increase of mRNA levels in cells treated with PPI or alkaline conditions. In colon biopsy specimens of collagenous colitis patients, the amounts of type III and type IV collagens were

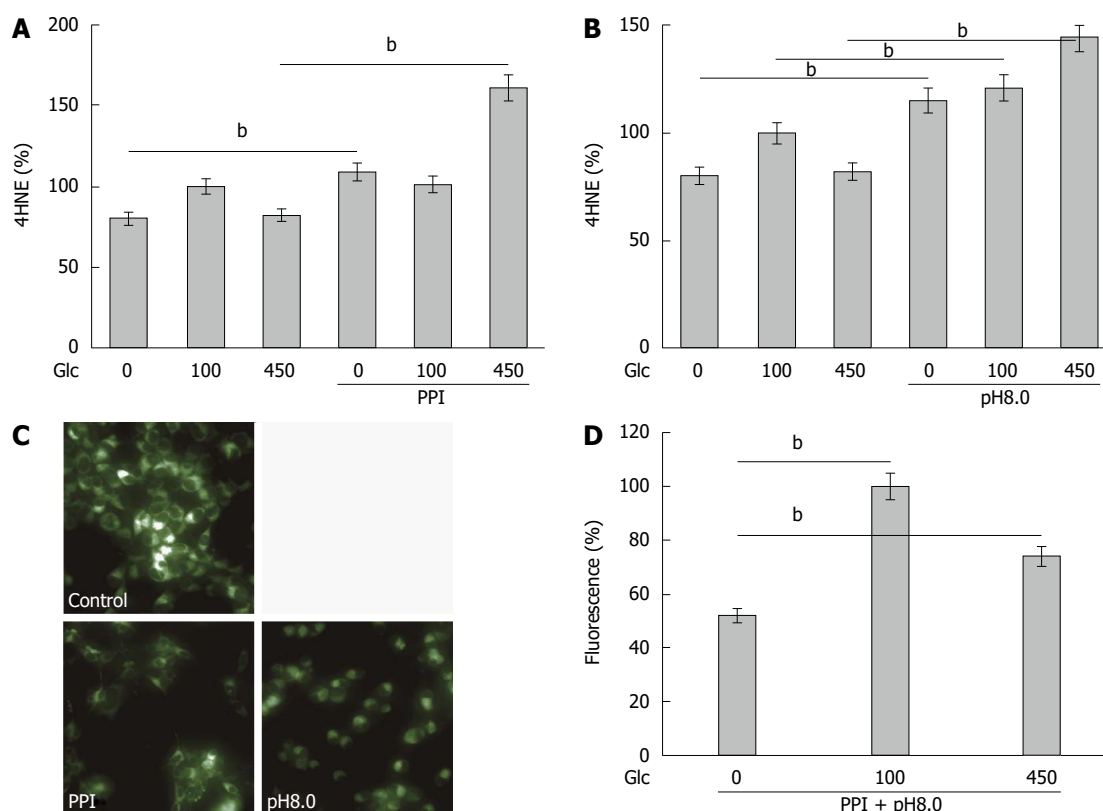


Figure 2 Effect of proton pump inhibitor and/or alkaline pH on oxidative stress and mitochondria volume. A and B: Levels of 4-hydroxynonenal (4HNE) was measured by ELISA. Relative quantities were designated (Glucose 100 mg/dL without PPI or pH8.0 is set to 100%); C: Mitochondrial volume was examined by Mitogreen staining; D: The fluorescence strength of Mitogreen (Strength in cells treated with glucose 0 mg/dL is set to 100%). Error bar, SD calculated from 3 independent experiments by Student's *t*-test. PPI: Proton pump inhibitor. ^b*P* < 0.001.

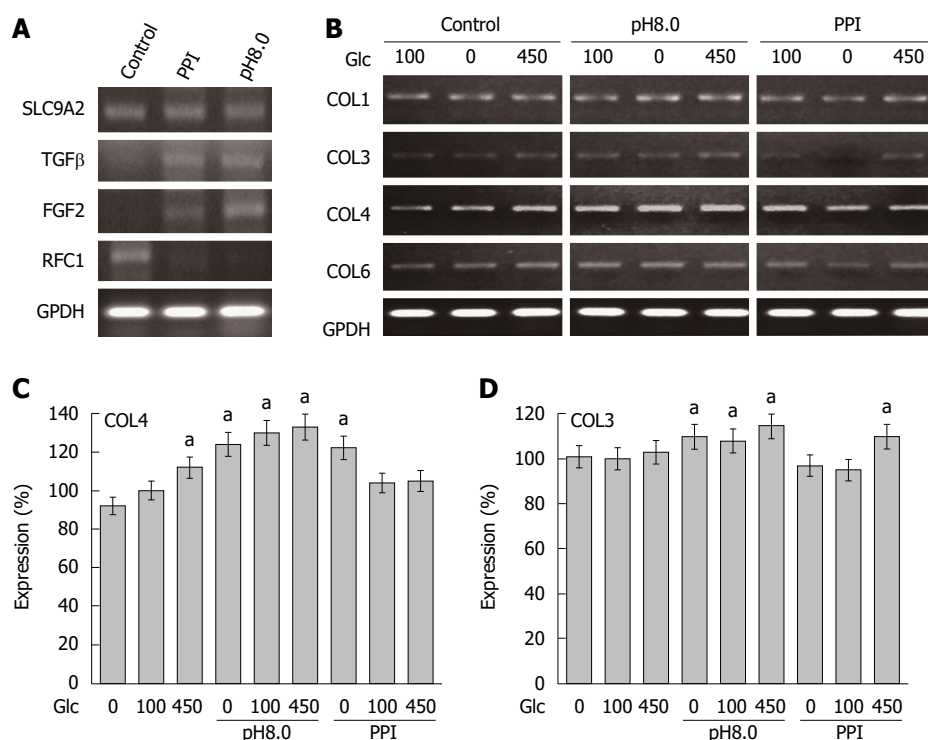


Figure 3 Expression of collagen and collagen-associated genes in CT26 cells. A: Expression of Na⁺-H⁺ exchanger gene (SLC9A2) and collagen-associated genes was examined by RT-PCR in CT26 cells treated with PPI or alkaline media. Glyceraldehyde 3-phosphate dehydrogenase (GPDH) served as an internal control; B: Expression of collagen type I, III, IV and VI in CT26 cells treated with PPI or alkaline media; C and D: The expression of collagen type I, III, IV and VI in CT26 cells was semi-quantitated. Expression in cells without treatment in 100 mg/dL glucose concentration was set to 100% as a reference. Asterisk shows significant difference from the reference. Error bar, SD calculated from 3 independent experiments by Student's *t*-test. PPI: Proton pump inhibitor.

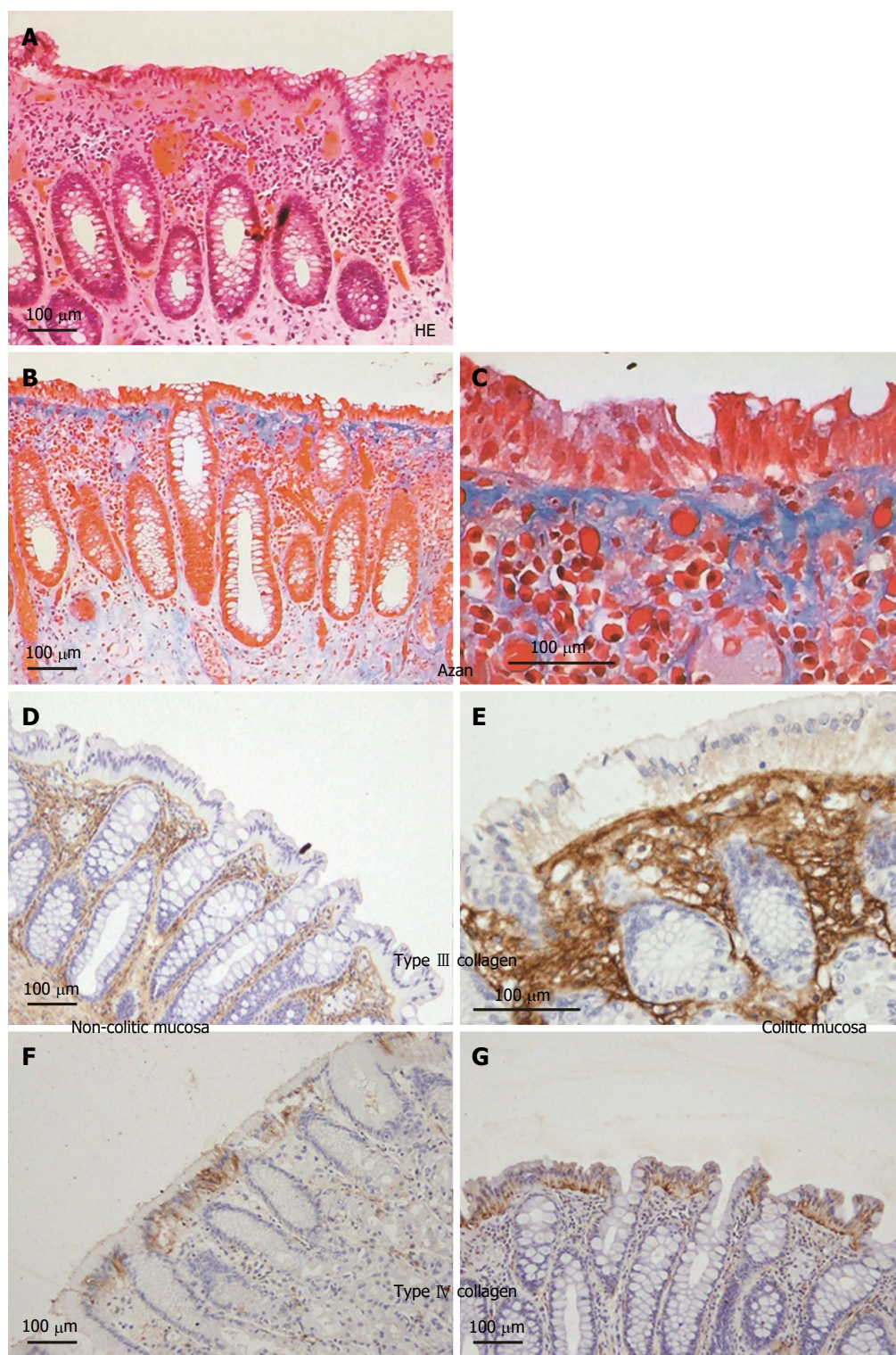


Figure 4 Expression of collagen type III and IV in colonic mucosa of collagenous colitis patients. A-C: Histopathological appearance of colonic mucosa in collagenous colitis patients. Thickened basement membrane at the covering epithelium was observed in HE (A) and Azan (B and C) staining; D-G: Immunohistochemistry of collagen type III (D and E) and type IV (F and G) in non-pathologic mucosa (D and F) and collagenous colitis mucosa (E and G).

increased. Type III collagen was increased in the basement membrane and mucosal stroma, whereas type IV collagen was increased only in the basement membrane. Type IV collagen is a major component of basement membrane collagens^[17]. The expression level of type III collagen in PPI-associated patients was

higher than in non-PPI-associated patients. These discrepancies between our data and Aigner's report might be due to differences in the pathogenesis of collagen disease or due to the influence of PPIs.

We examined pantoprazole in this study. To determine the significance of lansoprazole in occurrence of

collagenous colitis, we examine several kinds of PPIs in future. NSAIDs are also associated with collagenous colitis in cases. The mechanism is also examined to compare with that of PPIs.

In our data, PPI and alkaline condition increased the expression of TGF- β and FGF2, which are well known fibrosis-inducing factors^[15]. We focused on the direct effect of PPI in colonocytes; however, stromal cells, such as fibroblasts are also involved in collagen production in collagenous colitis^[5]. Our results suggest that PPIs induce fibroblast-mediated collagen production *via* stimulation of colonocyte secreting TGF- β and FGF2.

In the literature, alteration of gut flora is relevant for development of collagen colitis; clostridium, in particular, is associated with the disease^[18-20]. Reduction of acidity in colonic contents by PPIs activates clostridium virulence^[10]. The flora alteration might induce collagen production in the colonic mucosa. Anaerobic bacteria, including clostridium, induce TGF- β expression in colonocytes, which enhances collagen deposition in the colonic wall^[21]. The TGF- β induction is caused by activation of the mucosal immunity^[22]. Interleukin-13 increase in the inflammatory mucosa is reported to activate TGF- β expression^[23]. Alkaline conditions might also affect gut flora, whose imbalance is regarded as important in causing collagenous colitis.

These findings suggest that collagen production and expression of collagen producing factors are directly stimulated by PPIs and PPI-induced alkaline change of colonic content. Colonocyte response to these factors might contribute to the pathogenesis of collagenous colitis.

ACKNOWLEDGMENTS

The authors thank Ms. Tomomi Masutani for expert assistance with the preparation of this manuscript.

COMMENTS

Background

Collagenous colitis is a clinical problem recognized recently in an association with administration with proton pump inhibitor (PPI). Since the pathogenesis is still controversy, reveal of the disease mechanism might be expected to develop a new therapy.

Research frontiers

Many recent studies show the immunological and bacteriological effect of PPI. Study on the direct effect of PPI on colonocytes is a novel approach.

Innovations and breakthroughs

PPI and the PPI-resulted alkaline condition altered mitochondrial energy metabolism and collagen expression in colonocytes.

Applications

PPI-induced oxidative stress is not only a possible cause of collagen production in colon epithelium but also an important factor affecting tumor growth or function of mitochondria-rich tissues, such as myocardium, hepatocytes.

Peer-review

Interesting paper on possible mechanism for lansoprazole associated collagenous colitis. It would be very interesting to evaluate other PPIs, such as omeprazole (a much rarer association with collagenous colitis), as well as with other agents (e.g., non-steroidal antiinflammatory drugs) to determine if this mechanism is shared with other agents.

REFERENCES

- 1 **Ingle SB**, Adgaonkar BD, Ingle CR. Microscopic colitis: Common cause of unexplained nonbloody diarrhea. *World J Gastrointest Pathophysiol* 2014; **5**: 48-53 [PMID: 24891975 DOI: 10.4291/wjgp.v5.i1.48]
- 2 **Bohr J**, Wickbom A, Hegedus A, Nyhlin N, Hultgren Hörnquist E, Tysk C. Diagnosis and management of microscopic colitis: current perspectives. *Clin Exp Gastroenterol* 2014; **7**: 273-284 [PMID: 25170275 DOI: 10.2147/CEG.S63905]
- 3 **Freeman HJ**, Weinstein WM, Shnitka TK, Wensel RH, Sartor VE. Watery diarrhea syndrome associated with a lesion of the colonic basement membrane--lamina propria interface. *Ann Royal Coll Phys Surg Canada* 1976; **9**: 45
- 4 **Lazenby AJ**. Collagenous and lymphocytic colitis. *Semin Diagn Pathol* 2005; **22**: 295-300 [PMID: 16939057 DOI: 10.1053/j.semdp.2006.04.006]
- 5 **Ianiro G**, Cammarota G, Valerio L, Annicchiarico BE, Milani A, Siciliano M, Gasbarrini A. Microscopic colitis. *World J Gastroenterol* 2012; **18**: 6206-6215 [PMID: 23180940 DOI: 10.3748/wjg.v18.i43.6206]
- 6 **Chande N**, McDonald JW, Macdonald JK. Interventions for treating collagenous colitis. *Cochrane Database Syst Rev* 2008; **(2)**: CD003575 [PMID: 18425892 DOI: 10.1002/14651858.CD003575.pub5]
- 7 **Freeman HJ**, Berean KW, Nimmo M. Evolution of collagenous colitis into severe and extensive ulcerative colitis. *Can J Gastroenterol* 2007; **21**: 315-318 [PMID: 17505568 DOI: 10.1155/2007/950154]
- 8 **Giardiello FM**, Jackson FW, Lazenby AJ. Metachronous occurrence of collagenous colitis and ulcerative colitis. *Gut* 1991; **32**: 447-449 [PMID: 2026344 DOI: 10.1136/gut.32.4.447]
- 9 **Mizushima T**, Mizoshita T, Sasaki M, Tanida S, Tsukamoto H, Shimura T, Kanematsu T, Kataoka H, Kamiya T, Tsukamoto T, Tatematsu M, Joh T. Lansoprazole induces collagenous colitis in the colon of Mongolian gerbils. *Asian Pac J Cancer Prev* 2011; **12**: 2759-2762 [PMID: 22320988]
- 10 **Hung YP**, Ko WC, Chou PH, Chen YH, Lin HJ, Liu YH, Tsai HW, Lee JC, Tsai PJ. Proton-Pump Inhibitor Exposure Aggravates Clostridium difficile-Associated Colitis: Evidence From a Mouse Model. *J Infect Dis* 2015; **212**: 654-663 [PMID: 25805751 DOI: 10.1093/infdis/jiv184]
- 11 **Kuniyasu H**, Yano S, Sasaki T, Sasahira T, Sone S, Ohmori H. Colon cancer cell-derived high mobility group 1/amphoterin induces growth inhibition and apoptosis in macrophages. *Am J Pathol* 2005; **166**: 751-760 [PMID: 15743787 DOI: 10.1016/S0002-9440(10)62296-1]
- 12 **Kuniyasu H**, Oue N, Wakikawa A, Shigeishi H, Matsutani N, Kuraoka K, Ito R, Yokozaki H, Yasui W. Expression of receptors for advanced glycation end-products (RAGE) is closely associated with the invasive and metastatic activity of gastric cancer. *J Pathol* 2002; **196**: 163-170 [PMID: 11793367 DOI: 10.1002/path.1031]
- 13 **Kuniyasu H**, Yasui W, Shinohara H, Yano S, Ellis LM, Wilson MR, Bucana CD, Rikita T, Tahara E, Fidler IJ. Induction of angiogenesis by hyperplastic colonic mucosa adjacent to colon cancer. *Am J Pathol* 2000; **157**: 1523-1535 [PMID: 11073812 DOI: 10.1016/S0002-9440(10)64790-6]
- 14 **Lai H**, Lin K, Zhang W, Zhang Z, Jie L, Wu Y, He Q. Development of pH- and enzyme-controlled, colon-targeted, pulsed delivery system of a poorly water-soluble drug: preparation and in vitro evaluation. *Drug Dev Ind Pharm* 2010; **36**: 81-92 [PMID: 19640246 DOI: 10.3109/03639040903092335]

- 15 **Hetzel M**, Bachem M, Anders D, Trischler G, Faehling M. Different effects of growth factors on proliferation and matrix production of normal and fibrotic human lung fibroblasts. *Lung* 2005; **183**: 225-237 [PMID: 16211459 DOI: 10.1007/s00408-004-2534-z]
- 16 **Komatsu T**, Kanatsu K, Kuze K, Iehara N, Takeoka H, Yamada Y, Kita T, Doi T. Demonstration of DNA replication factor C in human glomerular lesions. *Clin Nephrol* 1998; **49**: 69-73 [PMID: 9524775]
- 17 **Randles MJ**, Humphries MJ, Lennon R. Proteomic definitions of basement membrane composition in health and disease. *Matrix Biol* 2016; Epub ahead of print [PMID: 27553508 DOI: 10.1016/j.matbio.2016.08.006]
- 18 **Byrne MF**, McVey G, Royston D, Patchett SE. Association of *Clostridium difficile* infection with collagenous colitis. *J Clin Gastroenterol* 2003; **36**: 285 [PMID: 12590248 DOI: 10.1097/00004836-200303000-00023]
- 19 **Khan MA**, Brunt EM, Longo WE, Presti ME. Persistent *Clostridium difficile* colitis: a possible etiology for the development of collagenous colitis. *Dig Dis Sci* 2000; **45**: 998-1001 [PMID: 10795766 DOI: 10.1023/A: 1005593628991]
- 20 **Gustafsson RJ**, Ohlsson B, Benoni C, Jeppsson B, Olsson C. Mucosa-associated bacteria in two middle-aged women diagnosed with collagenous colitis. *World J Gastroenterol* 2012; **18**: 1628-1634 [PMID: 22529692 DOI: 10.3748/wjg.v18.i14.1628]
- 21 **Mourelle M**, Salas A, Guarner F, Crespo E, García-Lafuente A, Malagelada JR. Stimulation of transforming growth factor beta1 by enteric bacteria in the pathogenesis of rat intestinal fibrosis. *Gastroenterology* 1998; **114**: 519-526 [PMID: 9496942 DOI: 10.1016/S0016-5085(98)70535-9]
- 22 **Günaltay S**, Kumawat AK, Nyhlin N, Bohr J, Tysk C, Hultgren O, Hultgren Hörnquist E. Enhanced levels of chemokines and their receptors in the colon of microscopic colitis patients indicate mixed immune cell recruitment. *Mediators Inflamm* 2015; **2015**: 132458 [PMID: 25948880 DOI: 10.1155/2015/132458]
- 23 **Fichtner-Feigl S**, Strober W, Geissler EK, Schlitt HJ. Cytokines mediating the induction of chronic colitis and colitis-associated fibrosis. *Mucosal Immunol* 2008; **1** Suppl 1: S24-S27 [PMID: 19079223 DOI: 10.1038/mi.2008.41]

P- Reviewer: Freeman HJ, Lakatos PL, Koulaouzidis A
S- Editor: Gong ZM **L- Editor:** A **E- Editor:** Wang CH





Published by **Baishideng Publishing Group Inc**

8226 Regency Drive, Pleasanton, CA 94588, USA

Telephone: +1-925-223-8242

Fax: +1-925-223-8243

E-mail: bpgoffice@wjgnet.com

Help Desk: <http://www.wjgnet.com/esps/helpdesk.aspx>

<http://www.wjgnet.com>



ISSN 1007-9327



9 771007 932045