

## Patient selection for transcatheter aortic valve replacement: A combined clinical and multimodality imaging approach

Rosangela Cocchia, Antonello D'Andrea, Marianna Conte, Massimo Cavallaro, Lucia Riegler, Rodolfo Citro, Cesare Sirignano, Massimo Imbriaco, Maurizio Cappelli, Giovanni Gregorio, Raffaele Calabrò, Eduardo Bossone

Rosangela Cocchia, Rodolfo Citro, Eduardo Bossone, Department of Cardiology and Cardiac Surgery, San Giovanni di Dio Hospital, 00733 Salerno, Italy

Antonello D'Andrea, Marianna Conte, Massimo Cavallaro, Lucia Riegler, Maurizio Cappelli, Raffaele Calabrò, Integrated Diagnostic Cardiology, Second University of Naples, AORN "dei Colli", Monaldi Hospital, 80121 Naples, Italy

Cesare Sirignano, Institute of Biostructure and Bioimaging National Research Council, 80121 Naples, Italy

Massimo Imbriaco, Department of Advanced Biomedical Sciences, University Federico II, 80121 Naples, Italy

Giovanni Gregorio, Department of Cardiology, San Luca Hospital, Vallo della Lucania, 00733 Salerno, Italy

**Author contributions:** Cocchia R and D'Andrea A designed the research and wrote the paper; Conte M, Cavallaro M and Riegler L wrote the paper; Citro R and Cappelli M performed the research; Sirignano C reviewed and approved the research; Imbriaco M, Calabrò R and Bossone E reviewed the paper.

**Conflict-of-interest statement:** The authors report no relevant conflicts of interest.

**Open-Access:** This article is an open-access article which was selected by an in-house editor and fully peer-reviewed by external reviewers. It is distributed in accordance with the Creative Commons Attribution Non Commercial (CC BY-NC 4.0) license, which permits others to distribute, remix, adapt, build upon this work non-commercially, and license their derivative works on different terms, provided the original work is properly cited and the use is non-commercial. See: <http://creativecommons.org/licenses/by-nc/4.0/>

**Manuscript source:** Invited manuscript

**Correspondence to:** Antonello D'Andrea, MD, PhD, Integrated Diagnostic Cardiology, Second University of Naples, AORN "dei Colli", Monaldi Hospital, Corso Vittorio Emanuele

121A, 80121 Naples, Italy. [antonellodandrea@libero.it](mailto:antonellodandrea@libero.it)  
 Telephone: +39-81-7062355  
 Fax: +39-81-7064234

Received: October 27, 2016  
 Peer-review started: October 31, 2016  
 First decision: December 1, 2016  
 Revised: December 15, 2016  
 Accepted: January 11, 2017  
 Article in press: January 14, 2017  
 Published online: March 26, 2017

### Abstract

Transcatheter aortic valve replacement (TAVR) has been validated as a new therapy for patients affected by severe symptomatic aortic stenosis who are not eligible for surgical intervention because of major contraindication or high operative risk. Patient selection for TAVR should be based not only on accurate assessment of aortic stenosis morphology, but also on several clinical and functional data. Multi-Imaging modalities should be preferred for assessing the anatomy and the dimensions of the aortic valve and annulus before TAVR. Ultrasounds represent the first line tool in evaluation of this patients giving detailed anatomic description of aortic valve complex and allowing estimating with enough reliability the hemodynamic entity of valvular stenosis. Angiography should be used to assess coronary involvement and plan a revascularization strategy before the implant. Multislice computed tomography play a central role as it can give anatomical details in order to choice the best fitting prosthesis, evaluate the morphology of the access path and detect other relevant comorbidities. Cardiovascular magnetic resonance and positron emission tomography are emergent modality helpful in aortic stenosis evaluation. The aim of this review is to give an overview on

TAVR clinical and technical aspects essential for adequate selection.

**Key words:** Aortic stenosis; Doppler echocardiography; Cardiac computed tomography; Two-dimensional strain; Three dimensional echocardiography; Cardiac magnetic resonance; Transcatheter aortic valve replacement

© **The Author(s) 2017.** Published by Baishideng Publishing Group Inc. All rights reserved.

**Core tip:** Transcatheter aortic valve replacement (TAVR) has been validated as a new therapy for patients affected by severe symptomatic aortic stenosis who are not eligible for surgical intervention because of major contraindication or high operative risk. Patient selection for TAVR should be based not only on accurate assessment of aortic stenosis morphology, but also on several clinical and functional data. Multi-Imaging modalities are preferred for assessing the anatomy and the dimensions of the aortic valve and annulus before TAVR. The aim of this review is to give an overview on TAVR clinical and technical aspects essential for adequate selection.

Cocchia R, D'Andrea A, Conte M, Cavallaro M, Riegler L, Citro R, Sirignano C, Imbriaco M, Cappelli M, Gregorio G, Calabrò R, Bossone E. Patient selection for transcatheter aortic valve replacement: A combined clinical and multimodality imaging approach. *World J Cardiol* 2017; 9(3): 212-229 Available from: URL: <http://www.wjgnet.com/1949-8462/full/v9/i3/212.htm> DOI: <http://dx.doi.org/10.4330/wjc.v9.i3.212>

## INTRODUCTION

Transcatheter aortic valve replacement (TAVR) has been validated as a new therapy for patients affected by severe symptomatic aortic stenosis who are not eligible for surgical intervention because of major contraindication or high operative risk<sup>[1,2]</sup>. Recently this option, performed in experienced centers, using next generation devices has demonstrated to be not inferior to standard surgery also in intermediate-risk patients<sup>[3]</sup>.

The safety and efficacy of prosthesis implantation depends on a proper patient selection and procedural guidance, based on a multimodality imaging approach<sup>[4,5]</sup>. A precise measurements of annulus and aortic root allow to make a correct "sizing", that means to choose the best fitting prosthesis in native aortic seat, representing one of the most important predictor of a successful procedure<sup>[6,7]</sup>.

## CLINICAL EVALUATION

Patient selection requires a multidisciplinary team approach including interventional cardiologists, surgeons, anesthesiologists and imaging specialists in order to delineate risk profile, study the anatomy of

aortic valve, aorta and peripheral vascular structures.

First line risk evaluation is usually performed using the Logistic European System for Cardiac Operative Risk Evaluation (EuroSCORE) and/or the STS Predicted Risk of Mortality Score, defining a high risk in case of logistic EuroSCORE  $\geq 15\%$ -20% or a STS score  $\geq 10\%$ . These scores present clear limitations mostly in elderly population and have not been created for TAVR procedures but for surgery so that their suitability in percutaneous valve implantation has been questioned and a risk overestimation suspected in this context<sup>[8]</sup>.

In patient with prior cardiac surgery, including degeneration of an implanted aortic bioprosthesis (valve in valve implantation), chest radiation therapy, porcelain aorta, liver cirrhosis, pulmonary hypertension and/or right ventricular dysfunction a TAVR approach should be reasonably preferred.

On the other hand, in elderly population, frailty has been associated with worst prognosis in several pathological conditions and also after TAVR and must be considered in patient evaluation. It can be definite as a syndrome of impaired physiologic reserve with decreased resistance to stressors<sup>[9]</sup> and can be quantified using a composite of four markers: Serum albumin, dominant hand grip strength, gait speed on a 15 ft (4.57 m) walk and independence in activities in daily living. These components can be summed to derive a frailty score (ranging 0 to 12) able to identify frail patients in case of score  $\geq 5$ .

Moreover, patients with poor life expectancy (less than 1 year) or in which TAVR has not expected to significantly improve quality of life should be excluded from this selection<sup>[10]</sup>.

Relative and absolute contraindications to TAVR are listed in Table 1.

One of the main advantages of TAVR vs SAVR is the more rapid recovery from TAVR and this benefit is different according to access site and is greater for transfemoral approach. Transapical access for TAVR is an accepted approach for patients in whom vascular anatomy do not permit a transfemoral approach and if on one hand it avoids potential site complications of iliac and femoral vessels, on the other hand has some limitations including an increase in respiratory complications<sup>[11]</sup>.

## ECOCARDIOGRAPHY

### Role of transthoracic echocardiography

Echocardiography represents the first line tool in the setting of pre- and post-interventional evaluation and planning of Transcatheter Aortic Valve Replacement procedures (Figures 1-3).

Transthoracic echocardiography (TTE) gives detailed anatomic description of aortic valve complex and allows to estimate with enough reliability the haemodynamic entity of valvular stenosis.

An adequate TTE examination in a patient presenting with aortic valve stenosis should include information

**Table 1** Contraindications for transcatheter aortic valve implantation**Absolute contraindications**

Absence of heart team or surgery on the site  
 Estimated life expectancy < 1 yr  
 Improvement of quality of life by TAVI unlikely because of comorbidities  
 Severe primary associated disease of other valves with major contribution to the patient's symptoms, that can be treated only by surgery  
 Inadequate annulus size (< 18 mm, > 29 mm)  
 Thrombus in the left ventricle  
 Active endocarditis  
 Elevated risk of coronary ostium obstruction (asymmetric valve calcification, short distance between annulus and coronary ostium, small aortic sinuses)  
 Plaques with mobile thrombi in the ascending aorta, or arch  
 For transfemoral/subclavian approach: inadequate vascular access (vessel size, calcification, tortuosity)

**Relative contraindications**

Bicuspid or non-calcified valves  
 Untreated coronary artery disease requiring revascularization  
 Haemodynamic instability  
 LVEF < 20%  
 For transapical approach: severe pulmonary disease, LV apex not accessible

TAVI: Transcatheter aortic valve implantation; LVEF: Left ventricular EF.

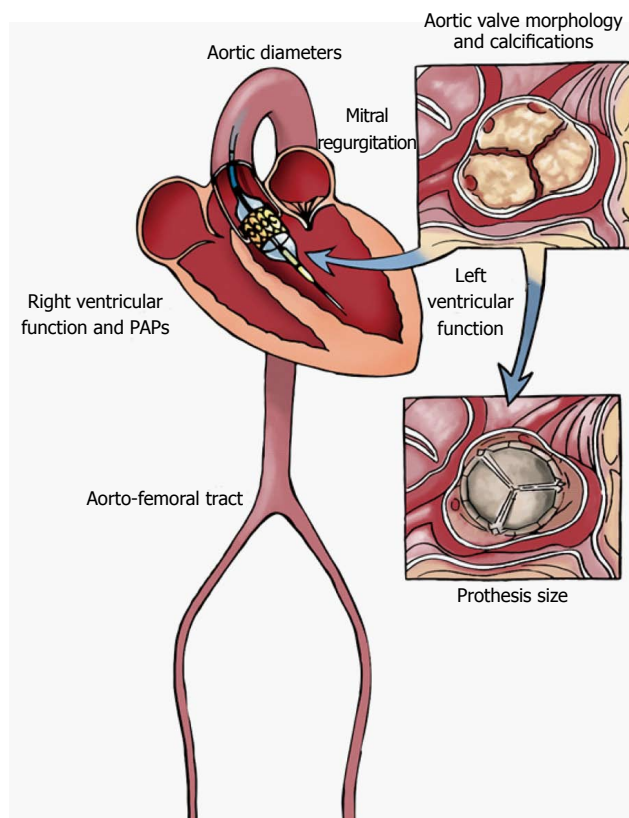
about valve anatomy (bicuspid or tricuspid valve) and severity of impairment of cusp motion. Moreover TTE provides an accurate evaluation of alterations in left and right ventricular morphology and function induced by the increase in afterload and allows to structurally and functionally investigate the other cardiac valves<sup>[12]</sup>.

Ultrasounds allow to underlie factors associated with outcome: In a longitudinal study of echo parameters in cohort A of the PARTNER trial authors showed that the TAVR and the SAVR groups had different univariate factors associated with outcome. In fact, in TAVR group, baseline low peak gradients predicted worse outcome expressing a low stroke volume status while in SAVR population the strongest determinant of mortality was mitral regurgitation<sup>[13]</sup>.

**Severity of aortic stenosis**

An appropriate haemodynamic evaluation of aortic valve stenosis requires the assessment of functional aortic valve area (AVA) or indexed AVA by body surface area, derived using continuity equation, peak transvalvular gradient and velocity (V<sub>max</sub>), mean transvalvular pressure gradient (MPG) and Stroke Volume index (SVi). According to latest recommendations by American College of Cardiology/American Heart Association, aortic valve stenosis is considered severe when V<sub>max</sub> is above 4 m/s, mean pressure exceeds 40 mmHg and estimated or measured AVA is under 1 cm<sup>2</sup> (< 0.6 cm<sup>2</sup>/m<sup>2</sup> if indexed for body surface area), assuming a normal left ventricular EF (LVEF)<sup>[14]</sup>.

When performing continuity equation it should be remembered that diameter of left ventricular outflow tract (LVOT) diameter should be taken within 1 to 5 mm



**Figure 1** Main morphologic and functional parameters to assess by Multi-Imaging approach in the setting of pre-interventional evaluation and planning of Transcatheter Aortic Valve Replacement procedures (illustrator by Germano Massenzio). PAPs: Pulmonary arterial systolic pressure.

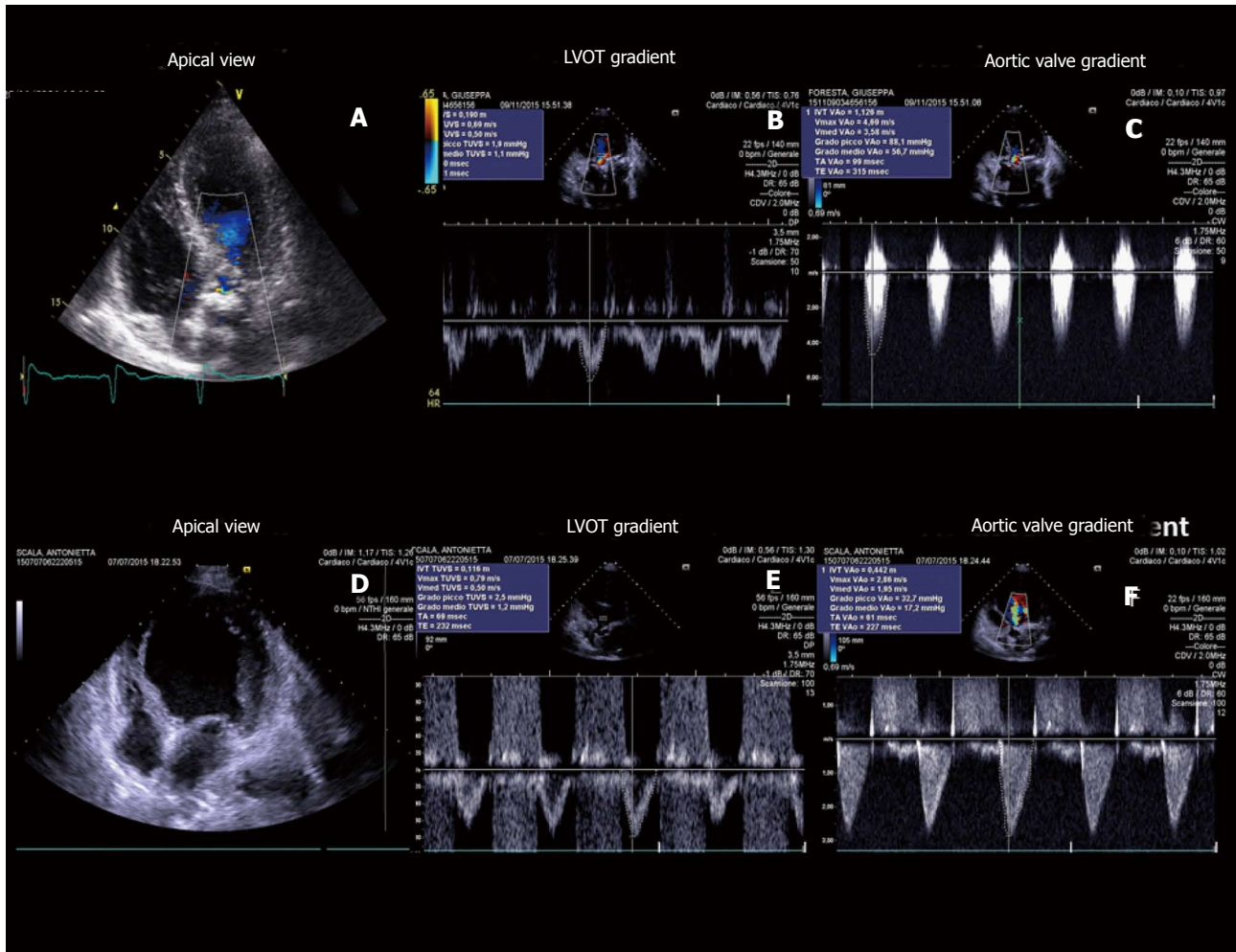
from aortic valve annulus in order to obtain maximum diameter<sup>[15]</sup>. LVOT often is elliptical so in case of measurement of the shortest dimension the continuity equation may still under-estimate the AVA and the stroke volume.

The calculation of the valvuloarterial impedance (Z<sub>va</sub>) should be part of a routine echocardiographic examination because this parameter provides an estimate of the global hemodynamic load<sup>[16]</sup> and can be an useful parameters in the evaluation of paradoxical aortic stenosis.

In clinical practice discordance between these parameters is often encountered so that commonly a severely restricted AVA can be found concomitantly with mean and peak pressure gradients falling into the moderate or mild category. This pattern is typically observed when systolic stroke volume and consequently transvalvular flow are reduced, thus realizing a so called low-flow low-gradient (LF-LG) aortic stenosis. In this condition visual assessment of structure, calcification and mobility of aortic valve is a crucial element as it can allow suspecting the diagnosis of severe aortic stenosis regardless of Doppler values.

Two forms of LF-LG aortic stenosis have been described<sup>[17]</sup>: (1) classical LF-LG aortic stenosis defined as an AVA < 1 cm<sup>2</sup> in presence of LVEF < 50% and MPG < 40 mmHg or V<sub>max</sub> < 4 m/s; (2) paradoxical LF-LG aortic stenosis in presence of an AVA < 1 cm<sup>2</sup>,





**Figure 2** Transthoracic echocardiography gives detailed anatomic description of aortic valve complex and allows to estimate with enough reliability the haemodynamic entity of valvular stenosis by assessment of functional aortic valve area, derived using continuity equation. Two examples of severe aortic stenosis with normal ejection fraction and gradients (A-C), and with classical "low flow-low gradient" pattern (D-F). LVOT: Left ventricular outflow tract.

LVEF > 50%, a reduced left ventricular stroke volume (< 35 mL/m<sup>2</sup>), MPG < 40 mmHg or Vmax < 4 m/s. In this case stroke volume is low usually because of a markedly hypertrophied left ventricle with a small cavity that is unable to be filled appropriately and subsequently eject a normal stroke volume, in case of reduced volume load due to diuretic therapy<sup>[18,19]</sup> or in presence of a high valvulo-arterial impedance (ZVa > 5.5 mmHg/mL/mq)<sup>[20]</sup>. These patients seem to have a dismal prognosis, which can be improved by aortic valve replacement or TAVI, as demonstrated in a PARTNER study sub-group analysis<sup>[21]</sup>.

On the other hand, a severely reduced functional AVA associated with low transvalvular gradient may be consequent to a reduced transvalvular flow due to left ventricular dysfunction that cannot allow cusps opening, defined as "pseudo-severe" aortic stenosis. It is important to distinguish these two conditions since in this last case aortic valve intervention may not improve prognosis. In patients with reduced EF low-dose dobutamine stress echocardiography ( $\leq 20 \mu\text{g/kg}$  per minute) can be used to discriminate LF-LG severe aortic stenosis from pseudosevere aortic stenosis as, in

the case of a severely stenotic valve, estimated AVA remains < 1 cm<sup>2</sup> and contemporarily transvalvular gradient increase<sup>[14,10]</sup>, but this variation can only be achieved in presence of a significant flow reserve (stroke volume increase > 20%).

In patients with asymptomatic severe aortic stenosis echo stress can be used, with caution and in expert centre, for unmask exercise-limiting symptoms, a drop in systolic blood pressure by > 20 mmHg, exercise increase in mean gradient  $\geq 18$  to 20 mmHg, the absence of contractile reserve (no or < 5% exercise increase in LVEF) or the presence of exercise pulmonary hypertension (> 60 mmHg) that are all strong predictors of cardiac events<sup>[22-25]</sup>.

When performing TTE evaluation of a stenotic aortic valve multiple windows should be investigated, including apical three or five chambers views and right parasternal approach, in order to obtain the best alignment of Doppler beam to transvalvular flow, thus avoiding inconsistency between estimated functional AVA and pressure gradient<sup>[26-28]</sup>. Recently in a study including 100 patients it has been shown that right parasternal window is more accurate than apical approach; in fact, when

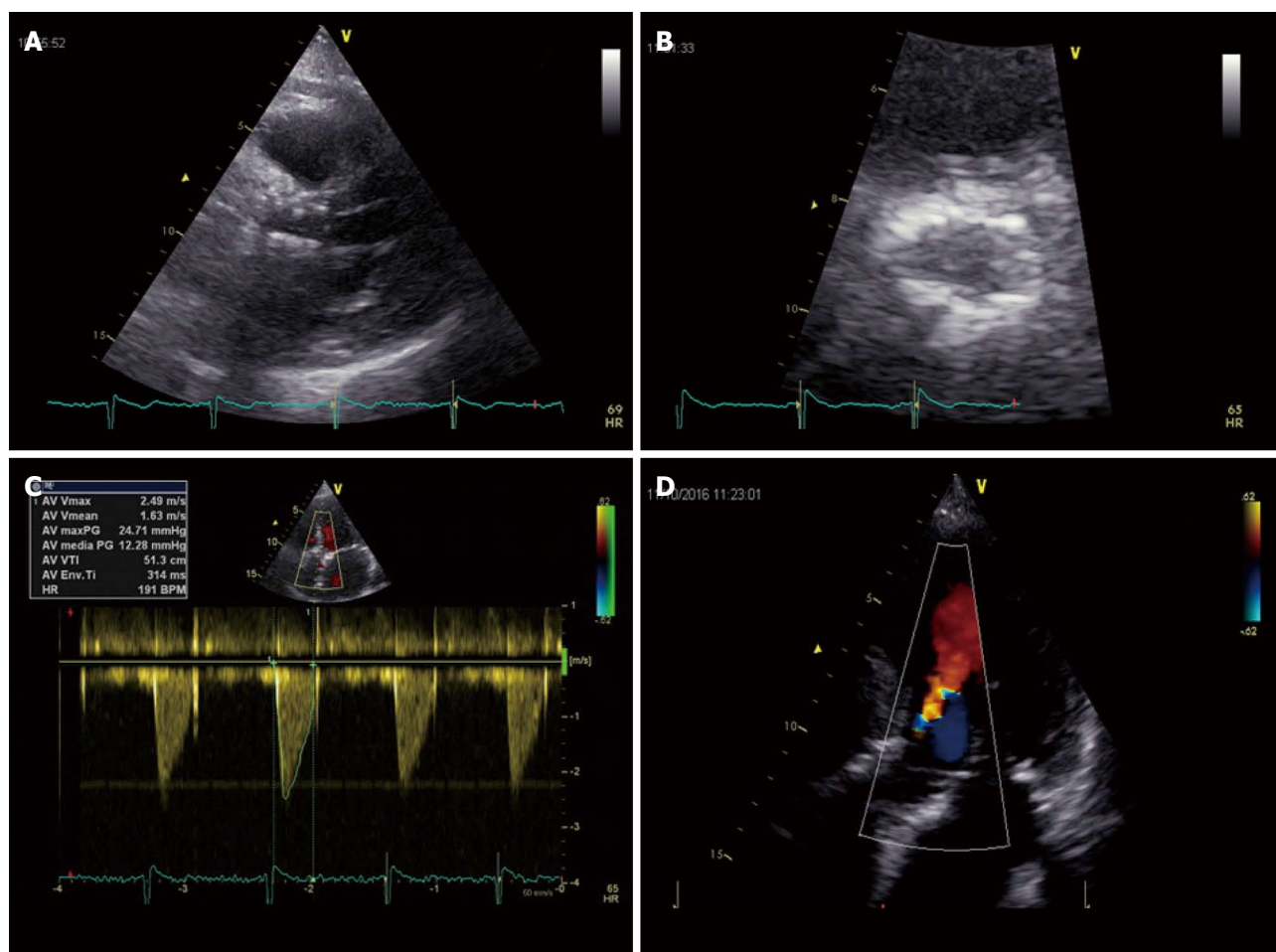


Figure 3 Post-implantation echocardiographic transcatheter aortic valve replacement assessment in long-axis (A) and short-axis (B) parasternal views; Normal trans-prothesis flow gradient by Doppler analysis (C); Mild paravalvular aortic regurgitation in this apical 5-chamber view of the same patient (D).

only apical approach is used a quarter of patients was incorrectly classified, underestimating severity in two thirds of patients deemed as moderate and misjudging a third as paradoxical LF-LG<sup>[29]</sup>.

Systemic blood pressure and calibre of ascending aorta can influence severity estimation, increased left ventricular global afterload due to hypertension may cause a reduction in transvalvular flow, thus leading to stenosis underestimation<sup>[30]</sup>.

Whereas if ascending aorta diameter is smaller than 30 mm, transvalvular pressure gradient may be overestimated because of a pressure recovery phenomenon distally to the aortic valve<sup>[31]</sup>.

### Aortic valve morphology

Conventional 2D-TTE allows in majority of patients to determine the number and disposition of aortic valve cusps. Bicuspid aortic valve with its asymmetrical closure line tends to develop degenerative alterations earlier than normal tricuspid valves and has a markedly elliptical annulus with eccentrically disposed calcium deposition<sup>[32]</sup>.

In presence of a bicuspid aortic valve percutaneous implanted prosthesis may fail to expand completely with consequent periprosthetic regurgitation (up to 28% of

cases) and the risk of valve misplacement<sup>[33,34]</sup>. Dilation of ascending aorta, which can be a contro-indication to TAVI, is also common in bicuspid aortic valve disease, moreover TAVR could increase the risk of aortic dissection in these subjects<sup>[35]</sup>. Because of these technical conundrums PARTNER trial did not include subjects with bicuspid aortic valvular stenosis<sup>[1]</sup>. Anyway TAVR is still possible in these patients and several cases have been reported up today<sup>[36]</sup>. Phan *et al*<sup>[37]</sup> have published a meta-analysis and systematic review of literature collecting 149 patients undergone TAVR procedure there was no significant difference for patients with bicuspid aortic valves in 30-d mortality, post-procedural prosthetic haemodynamics and presence of moderate to severe perivalvular aortic regurgitation or rate of bleeding or vascular complications, indicating that TAVR can be an effective treatment also in this setting. No difference in 30-d and one year mortality between bicuspid and tricuspid stenotic valves undergoing TAVR was also found in the Poland National Registry<sup>[38]</sup>. In light of this evidence more and more centres are proposing TAVR as a valuable option for treatment patients carrying a bicuspid aortic valve, considering this condition no more an absolute but a relative contraindication to the procedure.

### Evaluation of left ventricular function

The presence of a left ventricle systolic dysfunction, defined as aEF < 50%, constitutes a negative prognostic marker both in symptomatic and asymptomatic severe aortic stenosis. In patients considered unsuitable for surgical aortic valve replacement enrolled in PARTNER B cohort 30-d and 1-year prognosis was not different for patients with a LVEF over 50% confronted with those with reduced LVEF<sup>[39]</sup>. Moreover in this arm of PARTNER study an increase in LVEF > 10% subsequently TAVR was found in 50% of patients considered unfit for surgery, especially for those with smaller LV chamber diameters and lower grade of mitral regurgitation before TAVR. Although LVEF improvement was not associated with improvement in survival, in those with no post-procedural increase in LVEF there was a worse prognosis at one year of follow-up.

In light of these evidences TAVR represents a valuable option in severe aortic stenosis and markedly reduced left ventricular systolic function and should be taken in consideration by the Heart Team, because in these very high risk patients for surgery TAVR may show a better outcome.

Furthermore an alteration in LV structure and function has been demonstrated in patients with severe aortic stenosis regardless a preserved LVEF and this phenomenon can be studied also with speckle tracking echocardiography, a relative new technique that provides non-Doppler evaluation of myocardial deformation as expression of systolic and diastolic dynamics<sup>[40]</sup>. In this context, in fact, a reduced GLS (global longitudinal score) has been documented with a more evident alteration in the basal LV segments and a value > -15.9% correlated with adverse prognosis<sup>[41,42]</sup>.

In patients with severe aortic stenosis undergoing TAVR, LV reverse remodelling and improvement of longitudinal myocardial function assessed by speckle tracking echocardiography have been observed together with a decrease of aorto-valvular impedance and an improvement of atrial morphology and function<sup>[43]</sup>. In fact, our group evaluated 55 patients before and 6 mo after CoreValve implantation demonstrating a significant reduction in mean transaortic gradient, LV mass, LA volume index, and an improvement of ejection fraction ( $P < 0.0001$ ). In addition, LV GLS and LA longitudinal strain significantly increased after TAVI and at the multiple logistic regression analysis, LV mass before TAVI ( $P < 0.001$ ) and peak CK MB mass after TAVI ( $P < 0.0001$ ) were powerful independent predictors of lower improvement of LV GLS. Moreover, LV mass index ( $P < 0.001$ ) and LV GLS strain ( $P < 0.001$ ) before TAVI was powerful independent predictor of LA longitudinal strain after TAVI (Figure 4).

### Mitral regurgitation

Haemodynamically relevant mitral regurgitation is present in a substantial amount of patients with severe valvular aortic stenosis. It may have many different underlying mechanisms, both organic and functional.

Functional mitral regurgitation may be also of ischemic nature, because of the common occurrence of coronary artery disease in these subjects. Moreover left ventricular systolic dysfunction and dilatation and concomitant aortic regurgitation may contribute to cause or aggravate mitral regurgitation<sup>[44]</sup>.

In addition high grade mitral regurgitation may result in reduced transvalvular flow and lead to incorrect classification of stenosis severity, so it has to be taken in consideration in pre-procedural TTE for a comprehensive global assessment of aortic valve disease.

Interestingly in these subset of patients improvement of mitral insufficiency is reported in around 50%, more often in the case of secondary mitral regurgitation<sup>[45,46]</sup>. This finding was consistent with the results of a recently published meta-analysis which demonstrated that MR improvement was associated with pre-procedural grade and not with causative mechanism<sup>[47]</sup>.

### Right ventricular function and pulmonary hypertension

Pre-procedural TTE should include a comprehensive evaluation of right ventricular dimensions and function, in addition to estimation of pulmonary arterial systolic pressure (PAPs) from tricuspid regurgitation velocity.

Registries report that after TAVR moderate or severe tricuspid regurgitation is frequent (occurring in about 15%) and in most cases it is not improved after the procedure<sup>[48]</sup>.

Pulmonary hypertension (PH) can be found in up to 25% of subjects affected by severe aortic stenosis, secondary to post-capillary increase of left ventricular filling pressure and the eventual presence of associated mitral regurgitation. PH is a predictor of worse prognosis following surgical aortic valve replacement and recently there is increasing evidence that it is a negative prognostic marker together with tricuspid regurgitation also in the setting of transcatheter aortic intervention<sup>[49]</sup>.

Evidence from TAVR registries suggests that PH (estimated PAPs over 40 mmHg on TTE) does not negatively influence success rate, amount of complications in the early phase and 30-d survival, but a negative prognostic effect is present regarding 1 year mortality, which is raised up to 22% (or higher if estimated PAPs is above 60 mmHg)<sup>[50]</sup>.

### Role of transoesophageal echocardiography

Transesophageal echocardiography (TEE) allows to better visualize aortic cusps, define etiology (bicuspid vs tricuspid) and directly measure aortic valve area by planimetry in doubt cases, when TTE is not conclusive. TEE can be used in association with other imaging techniques for optimal pre-procedural planning in the setting of TAVI.

### Annulus size measurement

Aortic valve annulus can be defined as a ring-shaped structure virtually identifiable at the level of basal attachment of aortic cusps measured in systole<sup>[46]</sup>. A correct measurement of annular size allows an appro-



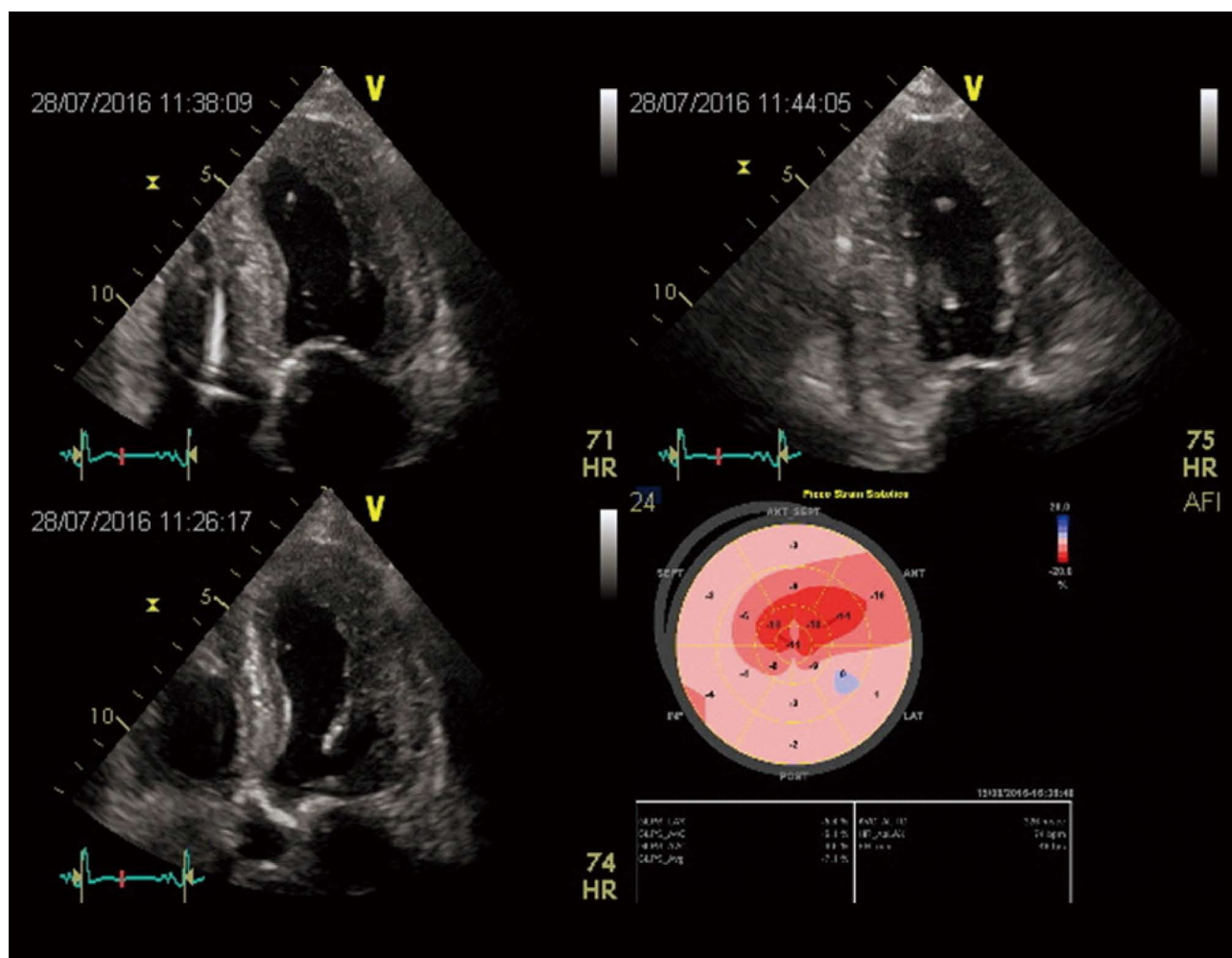


Figure 4 Two-dimensional LV strain in a patient with low flow-low gradient aortic stenosis, showing a severe and diffused impairment of myocardial deformation.

priate delivery of aortic valve prosthesis and reduce the incidence of complications<sup>[51]</sup>.

When aortic annulus is underestimated the delivery of a prosthesis too small can be followed by displacement or paraprosthetic regurgitation<sup>[4]</sup>. On the other hand prosthesis oversizing can cause insufficient expansion and valvular or paraprosthetic regurgitation or annular rupture. Optimal annular sizing aims to deliver a valve of an adequate dimension large enough to avoid paravalvular regurgitation, but not exceeding more than 20% the measured annular diameter, which increases risk of rupture.

In practice antero-posterior annular diameter is measured by TEE in mid-esophageal long axis view (120°-150°) in correspondence of basal hinge points of aortic cusps to aortic root.

Three dimensional TEE allows to visualize the real shape of LVOT, which is oval in 90% of patients<sup>[52]</sup>. 3D-TEE has proved more effective in providing optimal annular measurement and was more useful in predicting paravalvular aortic regurgitation compared to 2D-TEE<sup>[53,54]</sup> (Figure 5).

3D-TEE has been directly compared with cardiac

CT demonstrating the two imaging modalities were equally effective in predicting paraprosthetic aortic regurgitation<sup>[55]</sup>, although annulus diameter and planimetric area determined by 3D-TEE tend to result smaller than those measured by cardiac CT, except for sagittal dimensions. Considering sagittal dimensions both diagnostic techniques were equally accurate in predicting prosthetic dimensions with good post-procedural results. In conclusion before TAVI, 3D-TEE can be considered a valuable alternative to cardiac CT in pre-procedural planning, especially in patients with chronic kidney disease.

### Root anatomy

Transesophageal Echocardiography is able to evaluate the distance of coronary arterial ostia from aortic annulus and to correlate this distance with aortic cusp length, in long axis view. If cusp length is longer than coronary-annular distance there is a risk of coronary occlusion after valve delivery, when aortic valve cusps are displaced by the prosthesis expansion.

In clinical practice in order to avoid coronary occlusion, coronary-annular distance should be higher than

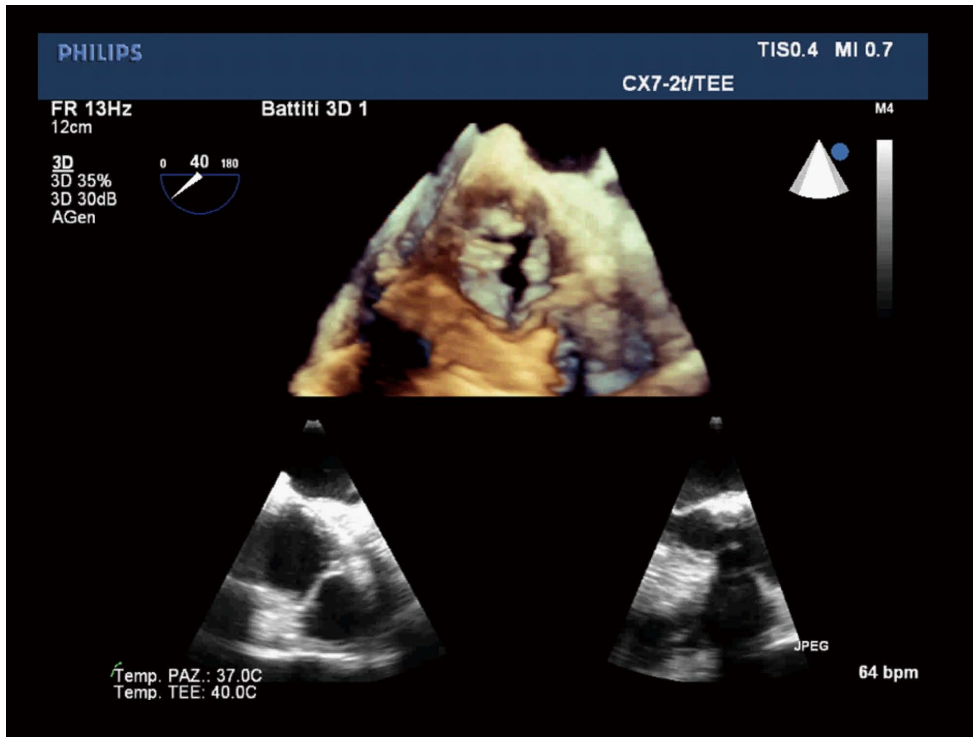


Figure 5 Three dimensional transesophageal echocardiography allows to visualize the real shape of left ventricular outflow tract, and has proved more effective in providing optimal annular measurement and was more useful in predicting paravalvular aortic regurgitation compared to 2D-transesophageal echocardiography.

10 mm<sup>[56,57]</sup>. Moreover aortic valve calcium burden should be always assessed and confronted with aortic sinus capacity. Although it is possible to measure coronary-annular distance with 2D-TEE, in the majority of patients it is necessary to use Multi Slice Computed Tomography (MSCT) or as an alternative 3D-TEE.

#### **Distribution of calcium**

TEE allows visualization of calcium deposits, which are present in almost all subjects affected by degenerative aortic stenosis, and their distribution. The presence of extensive aortic valve calcifications may cause paravalvular regurgitation due to formation of gaps between prosthetic and native valve and increase the risk of coronary ostium obstruction after TAVI delivery<sup>[58]</sup>. In addition extensively calcified sino-tubular junction may impair the expansion at the aortic end of the prosthesis eventually causing ventricular displacement of the prosthetic valve during delivery<sup>[59,60]</sup>. Great amount of calcification, particularly in subvalvular region, is also associated with increased risk of periprocedural annular rupture or sinus rupture.

#### **Characteristics of aorta and significant left ventricular septal hypertrophy**

TEE examination provides an higher spatial and temporal resolution and in pre-procedural phase allows to evaluate the ascending aorta and the descending thoracic tract in order to exclude the presence of extensive and soft atheromas which are associated with higher risk of peri-procedural ischemic stroke because they can be

mobilized and hinder the passage of delivery system<sup>[61,62]</sup>. It remains a suboptimal tool for the assessment of the distal ascending aorta and the proximal arch (TEE "blind spot" due to tracheal air shadowing) as well as for the abdominal aorta. Finally TEE may show a significant basal septal hypertrophy that may lead to prosthesis displacement in periprocedural or postprocedural phase<sup>[63,64]</sup>.

### **CORONARY ANGIOGRAPHY AND PCI**

Coronary angiography represents an essential part of patient evaluation before planning a TAVR procedure. Significant coronary artery disease is commonly found in patients with indication to TAVI, however there is no universal agreement about if and how it should be treated<sup>[61,65]</sup>. Secondary left ventricular hypertrophy may cause myocardial ischemia irrespectively of the presence of obstructive atherosclerotic lesions in major coronary arteries, in fact manifestations of angina are reported also by patients without evidence of relevant coronary artery disease (CAD) on angiographic examination<sup>[66]</sup>.

Moreover even though degenerative stenotic aortic valve disease has the same risk factors of CAD, there is substantial variability in CAD prevalence in aortic stenosis population between different studies, ranging from 34% to 75%<sup>[67,68]</sup>. A possible explanation for this inconsistency can be found in the definition adopted for significant CAD and which method is used for its diagnosis, usually angiographic examination,



which shows relevant interobserver variability. Usually angiographic cut-off for coronary obstruction is considered  $\geq 50\%$ <sup>[69-72]</sup>, but some authors use a cut off value of  $\geq 70\%$ <sup>[73-75]</sup>.

Latest recommendations about myocardial revascularization released from European Society of Cardiology suggest PTCA for patients undergoing TAVI in the presence of coronary obstructive lesions of more than 70% (class IIa, level of evidence C), despite the impact on long term survival of obstructive CAD is controversial according to different TAVI registries<sup>[76-78]</sup>. In order to definite the prognostic benefit of percutaneous revascularization of anatomically relevant CAD in patients undergoing TAVR a randomized controlled trial, the ACTIVATION study, is ongoing<sup>[79]</sup>.

In addition the burden of CAD in this setting fall in a broad spectrum going from a simple single lesion to multiple complex lesions, with different prognostic implications. Currently CAD treatment can be guided by coronary angiography and Anatomical Scoring Systems. Moreover in patients with borderline risk profile the assessment or the exclusion of coronary artery disease can induce the Heart Team to lean towards SAVR or TAVR.

### Angiography-guided revascularization

According to angiographic data significant obstructive CAD is found in 40%-60% of TAVR patients, evaluated through quantitative coronary angiography (QCA). Khawaja *et al*<sup>[66]</sup> in a retrospective study "Coronary artery disease in patients undergoing TAVI- why not to treat" including 271 patients evaluated through QCA, reported an incidence of obstructive CAD of 34% (defined as a 70% or more stenosis of a major coronary artery or 50% or more in left main stem or a venous graft); 26.9% of them underwent revascularization before TAVR procedure. Moreover no significant increase in mortality for patients carrying obstructive CAD was found in this study, either at 30 d or at 1 year and among them, those treated by revascularization also did not show any significant prognostic improvement.

However QCA has several pitfalls: (1) eccentric and markedly calcific plaques are difficult to assess through this technique because of calcium pools projection by X-rays; and (2) extremely tortuous epicardial coronary arteries may cause mistakes in vessel measurement and thus in stenosis evaluation<sup>[80]</sup>. Alternatively markedly calcific and contorted lesions may be more reliably evaluated through optical coherence tomography or intravascular ultrasonography, but at present the use of these techniques has not been investigated in TAVR population.

Finally according to old fashioned studies using QCA of left coronary artery in aortic valve stenosis it was demonstrated a progressive increase in coronary vessel dimensions as aortic valvular stenosis progresses, such phenomenon was reverted by SAVR, so angiographic evaluation may not reliably predict CAD extension after

TAVR procedure<sup>[81]</sup>.

### Anatomical score system

Anatomical scores are used to grade coronary artery disease extension in everyday clinical practice, among them the most frequently used is SYNTAX score<sup>[82]</sup>. Recently these scoring systems have been applied in small TAVR registries, taking in consideration the location and complexity of coronary lesions in order to estimate procedural risk of coronary revascularization<sup>[83,84]</sup>.

In the previously cited retrospective analysis by Khawaja *et al*<sup>[66]</sup> a SYNTAX score  $> 33$  (which defines an high risk according to SYNTAX study) had an higher rate of periprocedural complications during TAVR, whereas a SYNTAX score between 0 and 22 identified patients with a lower risk. Moreover a cut off value of 9 was a predictor of all-cause death at one month and at one year of follow-up so that revascularization may be indicated for patients with a SYNTAX score  $\geq 9$ .

Furthermore comparing surgical aortic valve replacement with TAVR in the setting of low flow-low gradient aortic stenosis, which represent an higher risk population, the extent of CAD evaluated through SYNTAX score or remaining CAD severity assessed by residual SYNTAX score after revascularization were both predictors of worse prognosis and cardiovascular death after 1 year follow-up<sup>[85]</sup>.

### Fractional flow reserve guided revascularization

No methods are validated to assess ischemia in patient with severe aortic stenosis and also evaluation offunctional significance of coronary artery stenosis by fractional flow reserve (FFR) is not recommended in this population. In fact the mechanism of ischemia in severe aortic stenosis is more complex and due to multiple hemodynamic factors so that aortic pressure waveform and coronary blood flow regulation is altered by left ventricular hypertrophy leading to an impaired coronary flow reserve also in absence of coronary obstruction<sup>[86]</sup>. In addition, the increased left ventricular filling pressure will rise left ventricular diastolic wall stress, this phenomenon together with reduced diastolic time may contribute to impair diastolic coronary blood flow per se.

On the other hand the administration of vasodilator drugs, necessary to asses FFR, could induce critical fall in systemic arterial pressure with potentially hemodynamic instability.

## MULTISLICE COMPUTED TOMOGRAPHY

Among the imaging modalities, computed tomography (CT) plays a central role in the evaluation of patients with severe aortic stenosis prior to TAVR since it allows to study anatomical details in order to choice the best fitting prosthesis, evaluate the morphology of the access path, select the best fluoroscopic projection angles and detect other relevant comorbidities (Figure 6).

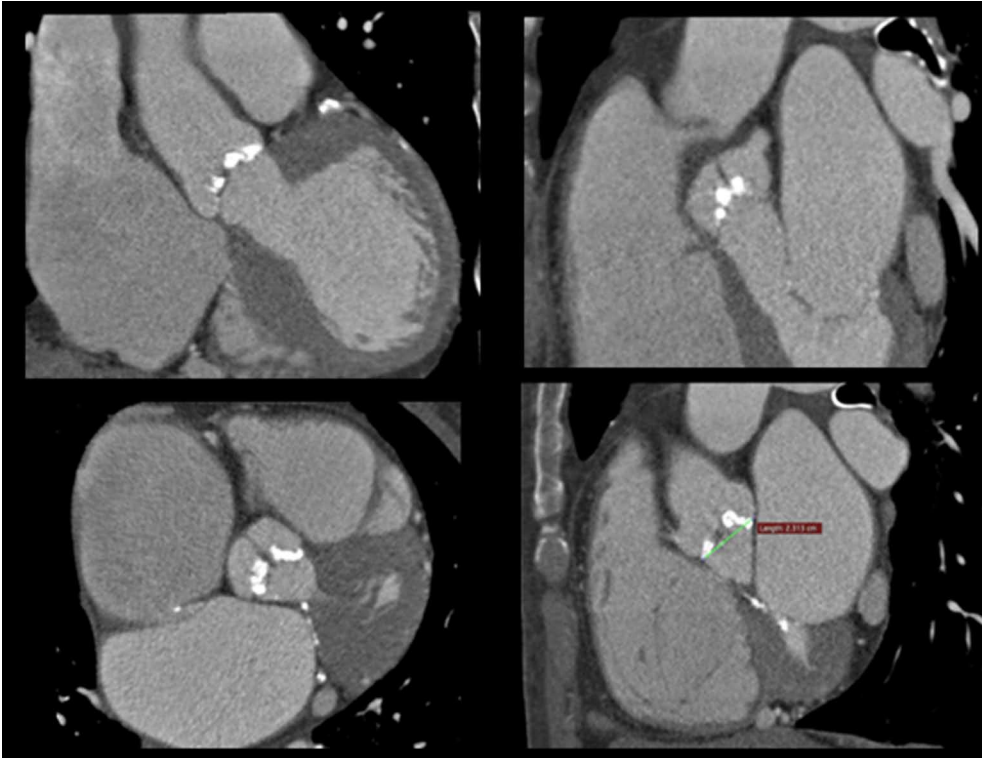


Figure 6 Multi-slice enhanced computed tomography images showing the aortic valve cusps and the first tract of the ascending aorta, with associated presence of extensive valvular calcifications.

#### **Measurement of aortic annulus and evaluation of aortic root**

Multidetector scanners allow multiplanar reformation and 3-dimensional reconstruction of aortic root, ascending tract, arch and descending segments of aorta. Novel technological advances in CT result in higher image quality with substantially reduced scan duration, contrast volume and radiation exposure. CT provide an accurate measurement of anatomic AVA by a cross-sectional view of the aortic valve derived from left sagittal and left coronal oblique views<sup>[52]</sup>. Moreover this modality gives precise measurements diameters, expressed also as mean value between different planar reliefs, area and perimeter of aortic annulus which are essential information for a correct prosthesis choice. The annulus size is larger when measured by MSCT than by 2D transthoracic or transoesophageal echocardiography with an absolute difference  $\leq 1.52 \pm 1.1$  mm. Comparing the measurements of aortic annulus size as obtained by CT angiography and 2-dimensional transoesophageal echocardiography with direct surgical measurement in patients undergoing surgical valve replacement, CTA overestimates aortic annulus diameter in 72.2% of cases, with 46.3%  $> 1$  TAVI valve-size ( $> 3$  mm) overestimations, whereas TEE underestimated aortic annulus diameter in 51.1% of cases, with 16.7%  $> 1$  valve-size underestimations<sup>[87,88]</sup>.

MSCT allows also to give precise measurements of the distance between annulus and coronary ostia and represents the gold standard for this purpose, providing a more comprehensive assessment, showing an average

annular-right coronary artery distance of  $13.6 \pm 2.8$  mm and annular-left coronary artery distance of  $13.4 \pm 3.2$  mm<sup>[89,90]</sup>. The distance between the aortic valve annular plane and the coronary ostia should be at least of  $\geq 10$ -11 mm for both type of most used prosthesis (Corevalve and Edwards). It is important also to evaluate the dimensions of ascending aorta at 45 mm above the annulus plane when the strategy foresees the implantation of a Corevalve prosthesis as this value should not exceed 40 mm for the 26-mm valve and 43 mm for the 29-mm and 31-mm.

This technique is useful to make many reconstructions with adjunctive information about calcification severity, plaque burden and prohibitive risk findings as dissections and complex atheroma of aorta<sup>[91]</sup>.

#### **Aortic valve calcium score**

CT permits to calculate aortic valve calcium scoring. In severe aortic annular calcification the protrusion of calcium into the lumen  $> 4$  mm can lead to an undersizing of the prosthesis valve and predict a post procedural paravalvular regurgitation<sup>[92]</sup>. Furthermore a high calcium score can help to distinguish between severe and pseudosevere aortic stenosis in patients with low left ventricle ejection fraction. Different cutoff values of calcium score in aortic stenosis have been described for men ( $\geq 2000$  AU or  $\geq 480$  AU/cm<sup>2</sup>) and women ( $\geq 1200$  AU or  $\geq 290$  AU/cm<sup>2</sup>) to identify severe AS<sup>[93]</sup>. In risk stratification, mostly in asymptomatic or paucisymptomatic patients, the aortic valve calcium load assessed by MSCT is a powerful predictor of rapid

**Table 2** Magnetic resonance sequences used for pre transcatheter aortic valve implantation evaluation<sup>[94]</sup>

Three-plane localizer	To localize aortic valve plane
Axial SSFP non ECG gated without contrast	To identify potential ascending aorta and subclavian access sites
Breath held free breathing 2D ECG gated SSFP	To determine size, calcification, and presence of aneurysmal dilatation of aorta
Coronal aorta, LVOT and aortic root	To evaluate aortic annulus, aortic valve structure, and sinus higher
SSFP ECG gated images: short axis stack	Planimetry valve orifice area
Breath held free breathing phase contrast at aortic orifice	Calculate ejection fraction, ventricular volumes and mass
3D Navigator assisted SSFP	Calculate blood flow velocity, pressure gradient, and flow volume across the aortic valve
T2 black blood	Calculate Aortic regurgitant volume
	Coronary ostia height
	Aortic diameter
	Useful in presence of susceptibility artifacts from sternal wires of prosthetic valves

LVOT: Left ventricular outflow tract; SSFP: Steady state free procession; ECG: Electrocardiography.

stenosis progression and of cardiac events<sup>[94]</sup>.

### Detection of coronary artery disease

Invasive coronary angiography remains the gold standard diagnostic modality for the detection of significant CAD in patients with severe aortic stenosis. The role of coronary computed tomography angiography (CTA) in selection of patients for TAVR until now remains not established mainly because there are few data regarding on its diagnostic accuracy in this context. In a large unselected cohort of patients with severe aortic stenosis, the identification of significant CAD has been limited by feasibility and an overall moderate accuracy (driven by the high rate of false-positive observations) so that this test cannot be used instead of invasive coronary angiography<sup>[95]</sup>. In fact, also in patients without arrhythmias, high heart rate and coronary stents up to 25% of the CTA images were found to be not fully evaluable representing coronary calcification the major confounding factor<sup>[96-98]</sup>. On the other hand, CTA has shown a good sensitivity (97%) and negative predictive value (97%) so that it can be reasonably be used as a rule-out test in some selected cases mostly in patients without prior known CAD and little calcifications<sup>[95]</sup>.

### Comorbidities detection

Computed tomography as a part of pre-TAVR diagnostic work-up is often able to detect other concomitant pathologies with important influence on outcome and sometimes questioning the indication to the procedure as in case of detection of potentially malignant diseases with poor prognosis. In fact, during CT aortography, images are acquired throughout the thorax and abdomen, and potentially significant incidental findings can be found. Until today patients candidates to TAVR tend to be elderly and it has been shown a very high overall incidence of incidental pathological findings in this population (more than 50%) and in 18.1% of cases a clinical significance has been documented<sup>[99]</sup>.

### Assessment of peripheral accesses

Appropriate approach selection is crucial for a good results of TAVR and is based on minimal aorto-femoral tract diameter detected by projection aortography or

CTA. In addition to conventional angiography (XA), CTA provides more detailed 3D images including calcification and tortuosity and allows to exclude a transfemoral access in patients with poor vessel quality or small diameter in aorto-femoral tract considering that the 18 Fr sheath requires a minimal arterial diameter of 6 mm of the aorto-femoral tract for prosthesis delivery<sup>[100,101]</sup>. It is important to know that the semi-automated CTA diameter measurement of the aorto-iliac tract resulted statistically significantly smaller compared to XA-based measurements.

Patients not suitable for transfemoral TAVR should be considered for transapical implantation or conventional surgery<sup>[102]</sup>.

## MAGNETIC RESONANCE IMAGING

Cardiovascular magnetic resonance (CMR) is an emergent modality for evaluation of patients before TAVR and it is expected to gain more and more space in this setting, mostly in patients with contraindications to contrast medium. As MSCT, this technique provides precise measurements of aortic valve, annulus, aortic root, coronary ostia, definition of the thoraco-abdominal aorta and luminal caliber of the iliofemoral branches (Table 2)<sup>[103]</sup>. Moreover it is able to study LV function with the advantage of not using ionizing radiation (Figure 7).

Non contrast MR should have an important role in preoperative evaluation in selected groups of patients with aortic stenosis: (1) patients affected by severe renal function impairment with GFR < 30 mL/min/mq; (2) patients with inadequate acoustic window mostly in the context of low gradient detection and/or reduced left ventricle ejection fraction; (3) discrepancy between parameters obtained by echocardiography and symptoms; and (4) History of allergic reactions to iodinated contrast medium.

MRI technique are influenced by some limitations. In the first place multiple breath holds, claustrophobia and the presence of arrhythmias can interfere with an adequate acquisition. Aneurism clips, carotid vascular clamp, neurostimulator devices, insulin or infusion pumps, ear implant and ocular foreign bodies represent

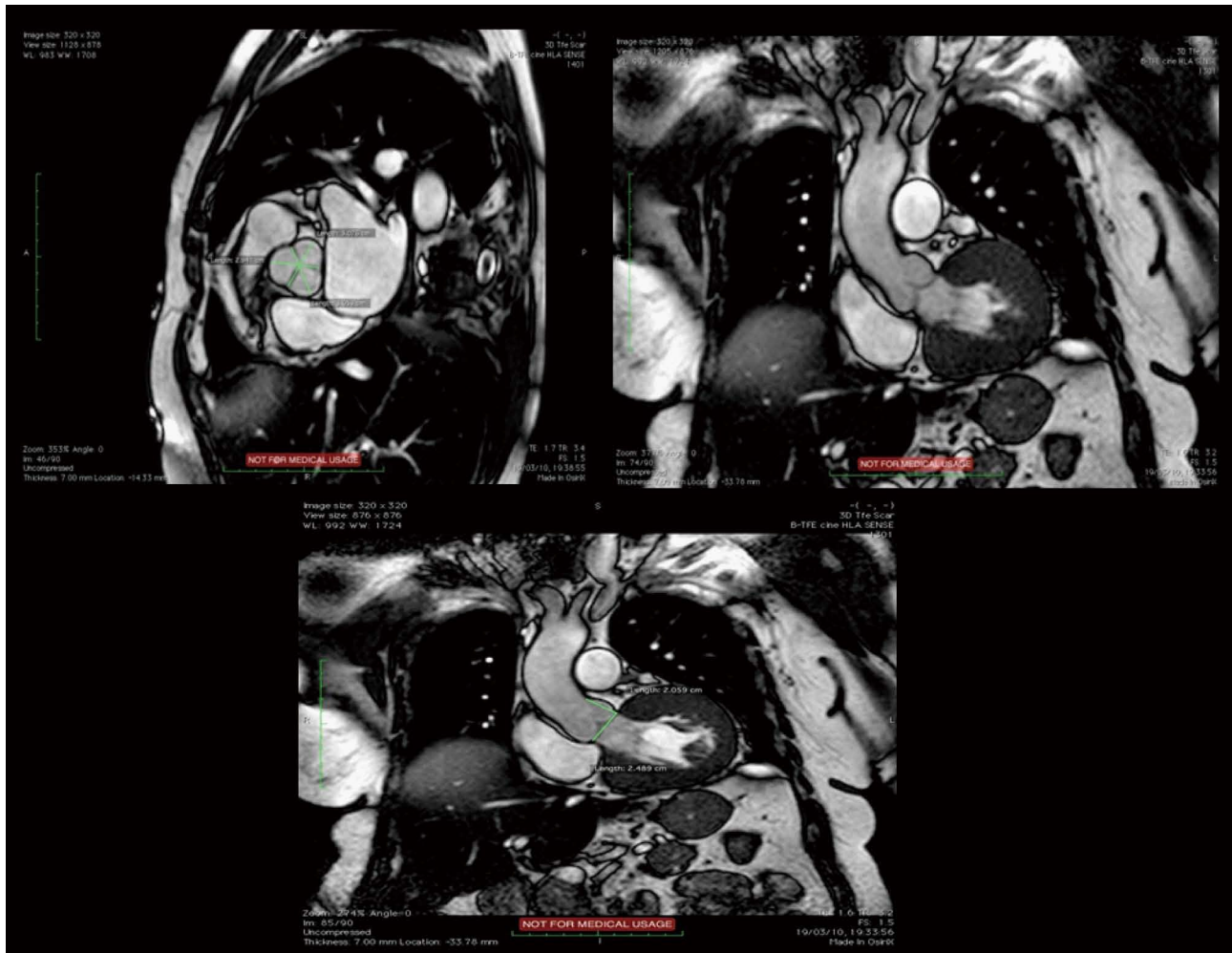


Figure 7 Balanced fast-field echo unenhanced magnetic resonance images showing the normal tricuspid aortic valve, with the typical “Mercedes-Benz Sign” and the first tract of the ascending aorta.

absolute contraindications.

### Aortic valve and root evaluation

MRI is able to provide accurate measurements of aortic annulus that in terms of capacity to predict the presence and the severity of post-implantation aortic regurgitation is similar to MSCT<sup>[104]</sup>. A good concordance between MSCT, CMR and echocardiography has been documented for aortic valve morphology definition and aortic valve area measurements<sup>[105]</sup>. In fact MRI is able to provide the planimetry of aortic valve opening area which is similar to other diagnostic modality as 3D TEE and flow-derived area calculation by catheterization using the Gorlin equation or by Doppler echocardiography using the continuity equation<sup>[106]</sup>. Although anatomic planimetry of aortic stenosis and assessment of valvular anatomy and motion is possible with MRI, this became less than optimal in patients with severe calcifications mostly in the presence of non-planar orifices. Furthermore assessment of severity of aortic stenosis can be completed by velocity-encoded cine MRI with other standard measures as peak anterograde velocity and pressure gradient but

it is necessary to know that velocities and gradients are usually underestimated if compared with Doppler echocardiography<sup>[107]</sup>.

MRI can be an alternative to 3D imaging modality for the measurement of aortic annulus (minor and major diameters, area and perimeter) having showed a good agreement with CT in this context also in presence of oval shape of the structure in which, after adequate plane orientation and 3 dimensional reconstruction, generally the coronal diameter is larger than the sagittal one<sup>[108]</sup>. As for MSCT, MRI diameters were found to be larger than those measured by 2D TEE modality.

Measurements of sinus of Valsalva diameters and definition of aortic root orientation are also possible with this approach but conversely this doesn't represent a good modality to thoracic aorta plaque burden definition as calcifications cause signal voids<sup>[103]</sup>.

The concordance with CT has been documented also for the assessment of the distance between the annulus and the ostium of the left coronary artery in relation to the length of the left coronary leaflet but at the moment more studies are needed to determine whether a strategy based on a different imaging method could



**Table 3** Multimodality imaging in pre transcatheter aortic valve replacement evaluation

Technique	Principal advantages	Disadvantages
Transthoracic echocardiography	Widespread availability First line diagnostic tool	Poor acoustic window Frequent discrepancy between different parameters
Transesophageal echocardiography	Good spatial resolution	Suboptimal for distal ascending aorta and arch
3 D reconstruction	Semi-invasive exam	Anatomic definition and annulus measurement
Multislice computed tomography	Multiplanar reconstruction Quantification of calcium score Evaluation of aorto-femoral tract	Potential nephrotoxicity of contrast medium Radiations exposition Controlled heart rate
Magnetic resonance imaging	Tissue characterization Multiplanar reconstruction Evaluation of aorto-femoral tract Controlled heart rate	Reduced availability Poor evaluation of calcifications Contraindicated in metallic devices wearers
Positron emission tomography	Evaluation of calcification and inflammation	Poor spatial resolution

achieve better results. A3-D SSFP free breathing stack in late diastole with a respiratory navigator allows to measure the height of coronary ostia from the annular plane.

Moreover magnetic resonance angiography can characterize aorto-ilio-femoral arteries in order to plan the more adequate access<sup>[109]</sup>.

### Ventricular volume and function

MRI provides quantitative evaluation of left ventricle volumes and function and late gadolinium enhancement at T1-weighted sequences allows to detect myocardial fibrosis which is more often localized in mid-wall of myocardium, like in pressure-overload cardiomyopathies, and represents a predictor of poor prognosis<sup>[110]</sup>. Fibrosis represents one of the most important factors implicated in progression of hypertrophy towards heart failure and an early detection can be useful in risk profile definition mostly in asymptomatic patients or in case of borderlines parameters at conventional echocardiography evaluation. Advanced fibrosis replacement of left ventricle myocardium predicts a lack of improvement in LV systolic function after aortic valve replacement and is an independent predictor of all-cause mortality<sup>[111,112]</sup>.

### POSITRON EMISSION TOMOGRAPHY/CT

An emergent role in pre-TAVR evaluation is attributable to positron emission tomography (PET)/CT with the advantage of combining the anatomic definition derived from CT and the functional and metabolic characterization gained from PET<sup>[15]</sup>. <sup>18</sup>F-sodium fluoride (<sup>18</sup>F-NaF) is a tracer used to detect calcification and in aortic stenosis the amount of uptake correlates with disease severity and is able to predict the progression of the disease<sup>[113-115]</sup>. On the other hand <sup>18</sup>F-fluorodeoxyglucose uptake, representing the burden of inflammation, is higher in patients with mild or moderate aortic stenosis and decrease with stenosis progression.

### CONCLUSION

Patient selection for TAVR should be based not only on

accurate assessment of aortic stenosis morphology, but also on several clinical and functional data. The Heart Team is key in the overall risk evaluation of this population. Multi-Imaging modalities are preferred for assessing the anatomy and the dimensions of the aortic annulus before TAVI (Table 3). In any case, we should tailor our patient selection and prosthesis selection on a case-to-case basis.

### REFERENCES

- 1 **Leon MB**, Smith CR, Mack M, Miller DC, Moses JW, Svensson LG, Tuzcu EM, Webb JG, Fontana GP, Makkar RR, Brown DL, Block PC, Guyton RA, Pichard AD, Bavaria JE, Herrmann HC, Douglas PS, Petersen JL, Akin JJ, Anderson WN, Wang D, Pocock S. Transcatheter aortic-valve implantation for aortic stenosis in patients who cannot undergo surgery. *N Engl J Med* 2010; **363**: 1597-1607 [PMID: 20961243 DOI: 10.1056/NEJMoa1008232]
- 2 **Nagaraja V**, Raval J, Eslick GD, Ong AT. Transcatheter versus surgical aortic valve replacement: a systematic review and meta-analysis of randomised and non-randomised trials. *Open Heart* 2014; **1**: e000013 [PMID: 25332780 DOI: 10.1136/openhrt-2013-000013]
- 3 **Leon MB**, Smith CR, Mack MJ, Makkar RR, Svensson LG, Kodali SK, Thourani VH, Tuzcu EM, Miller DC, Herrmann HC, Doshi D, Cohen DJ, Pichard AD, Kapadia S, Dewey T, Babaliaros V, Szeto WY, Williams MR, Kereiakes D, Zajarias A, Greason KL, Whisenant BK, Hodson RW, Moses JW, Trento A, Brown DL, Fearon WF, Pibarot P, Hahn RT, Jaber WA, Anderson WN, Alu MC, Webb JG. Transcatheter or Surgical Aortic-Valve Replacement in Intermediate-Risk Patients. *N Engl J Med* 2016; **374**: 1609-1620 [PMID: 27040324 DOI: 10.1056/NEJMoa1514616]
- 4 **Piazza N**, de Jaegere P, Schultz C, Becker AE, Serruys PW, Anderson RH. Anatomy of the aortic valvar complex and its implications for transcatheter implantation of the aortic valve. *Circ Cardiovasc Interv* 2008; **1**: 74-81 [PMID: 20031657 DOI: 10.1161/CIRCINTERVENTIONS.108.780858]
- 5 **Webb JG**, Doshi D, Mack MJ, Makkar R, Smith CR, Pichard AD, Kodali S, Kapadia S, Miller DC, Babaliaros V, Thourani V, Herrmann HC, Bodenhamer M, Whisenant BK, Ramee S, Maniar H, Kereiakes D, Xu K, Jaber WA, Menon V, Tuzcu EM, Wood D, Svensson LG, Leon MB. A Randomized Evaluation of the SAPIEN XT Transcatheter Heart Valve System in Patients With Aortic Stenosis Who Are Not Candidates for Surgery. *JACC Cardiovasc Interv* 2015; **8**: 1797-1806 [PMID: 26718510 DOI: 10.1016/j.jcin.2015.08.017]
- 6 **Généreux P**, Head SJ, Wood DA, Kodali SK, Williams MR, Paradis JM, Spaziano M, Kappetein AP, Webb JG, Cribier A, Leon MB. Transcatheter aortic valve implantation 10-year anniversary: review of current evidence and clinical implications. *Eur Heart J*

- 2012; **33**: 2388-2398 [PMID: 22851654 DOI: 10.1093/eurheartj/ehs220]
- 7 **Généreux P**, Head SJ, Wood DA, Kodali SK, Williams MR, Paradis JM, Spaziano M, Kappetein AP, Webb JG, Cribier A, Leon MB. Transcatheter aortic valve implantation: 10-year anniversary part II: clinical implications. *Eur Heart J* 2012; **33**: 2399-2402 [PMID: 22851655 DOI: 10.1093/eurheartj/ehs223]
- 8 **Osswald BR**, Gegouskov V, Badowski-Zyla D, Tochtermann U, Thomas G, Hagl S, Blackstone EH. Overestimation of aortic valve replacement risk by EuroSCORE: implications for percutaneous valve replacement. *Eur Heart J* 2009; **30**: 74-80 [PMID: 19033261 DOI: 10.1093/eurheartj/ehn523]
- 9 **Green P**, Woglom AE, Genereux P, Daneault B, Paradis JM, Schnell S, Hawkey M, Maurer MS, Kirtane AJ, Kodali S, Moses JW, Leon MB, Smith CR, Williams M. The impact of frailty status on survival after transcatheter aortic valve replacement in older adults with severe aortic stenosis: a single-center experience. *JACC Cardiovasc Interv* 2012; **5**: 974-981 [PMID: 22995885 DOI: 10.1016/j.jcin.2012.06.011]
- 10 **Vahanian A**, Alfieri OR, Al-Attar N, Antunes MJ, Bax J, Cormier B, Cribier A, De Jaegere P, Fournial G, Kappetein AP, Kovac J, Ludgate S, Maisano F, Moat N, Mohr FW, Nataf P, Pierard L, Pomar JL, Schofer J, Tornos P, Tuzcu M, van Hout B, von Segesser LK, Walther T. Transcatheter valve implantation for patients with aortic stenosis: a position statement from the European Association of Cardio-Thoracic Surgery (EACTS) and the European Society of Cardiology (ESC), in collaboration with the European Association of Percutaneous Cardiovascular Interventions (EAPCI). *Eur J Cardiothorac Surg* 2008; **34**: 1-8 [PMID: 18502659 DOI: 10.1016/j.ejcts.2008.04.039]
- 11 **Gada H**, Kirtane AJ, Wang K, Lei Y, Magnuson E, Reynolds MR, Williams MR, Kodali S, Vahl TP, Arnold SV, Leon MB, Thourani V, Szeto WY, Cohen DJ. Temporal Trends in Quality of Life Outcomes After Transapical Transcatheter Aortic Valve Replacement: A Placement of AoRTic TranScathetER Valve (PARTNER) Trial Substudy. *Circ Cardiovasc Qual Outcomes* 2015; **8**: 338-346 [PMID: 26058718 DOI: 10.1161/CIRCOUTCOMES.114.001335]
- 12 **Badiani S**, Bhattacharyya S, Lloyd G. Role of Echocardiography Before Transcatheter Aortic Valve Implantation (TAVI). *Curr Cardiol Rep* 2016; **18**: 38 [PMID: 26960423 DOI: 10.1007/s11886-016-0715-z]
- 13 **Hahn RT**, Pibarot P, Stewart WJ, Weissman NJ, Gopalakrishnan D, Keane MG, Anwaruddin S, Wang Z, Bilsker M, Lindman BR, Herrmann HC, Kodali SK, Makkar R, Thourani VH, Svensson LG, Akin JJ, Anderson WN, Leon MB, Douglas PS. Comparison of transcatheter and surgical aortic valve replacement in severe aortic stenosis: a longitudinal study of echocardiography parameters in cohort A of the PARTNER trial (placement of aortic transcatheter valves). *J Am Coll Cardiol* 2013; **61**: 2514-2521 [PMID: 23623915 DOI: 10.1016/j.jacc.2013.02.087]
- 14 **Dimitrova NA**, Dimitrov GV. Effect of electrical stimulus parameters on the development and propagation of action potentials in short excitable fibres. *Electroencephalogr Clin Neurophysiol* 1988; **70**: 453-459 [PMID: 2460319 DOI: 10.1016/j.jacc.2014.02.536]
- 15 **Nishimura RA**, Otto CM, Bonow RO, Carabello BA, Erwin JP, Guyton RA, O'Gara PT, Ruiz CE, Skubas NJ, Sorajja P, Sundt TM, Thomas JD. 2014 AHA/ACC guideline for the management of patients with valvular heart disease: a report of the American College of Cardiology/American Heart Association Task Force on Practice Guidelines. *J Am Coll Cardiol* 2014; **63**: e57-185 [PMID: 24603191 DOI: 10.1161/CIRCIMAGING.115.004352]
- 16 **Briand M**, Dumesnil JG, Kadem L, Tongue AG, Rieu R, Garcia D, Pibarot P. Reduced systemic arterial compliance impacts significantly on left ventricular afterload and function in aortic stenosis: implications for diagnosis and treatment. *J Am Coll Cardiol* 2005; **46**: 291-298 [PMID: 16022957 DOI: 10.1016/j.jacc.2004.10.081]
- 17 **Dumesnil JG**, Pibarot P, Carabello B. Paradoxical low flow and/or low gradient severe aortic stenosis despite preserved left ventricular ejection fraction: implications for diagnosis and treatment. *Eur Heart J* 2010; **31**: 281-289 [PMID: 19737801 DOI: 10.1093/eurheartj/ehp361]
- 18 **Hachicha Z**, Dumesnil JG, Bogaty P, Pibarot P. Paradoxical low-flow, low-gradient severe aortic stenosis despite preserved ejection fraction is associated with higher afterload and reduced survival. *Circulation* 2007; **115**: 2856-2864 [PMID: 17533183 DOI: 10.1161/CIRCULATIONAHA.106.668681]
- 19 **Herrmann S**, Störk S, Niemann M, Lange V, Strotmann JM, Frantz S, Beer M, Gattenlöhner S, Voelker W, Ertl G, Weidemann F. Low-gradient aortic valve stenosis myocardial fibrosis and its influence on function and outcome. *J Am Coll Cardiol* 2011; **58**: 402-412 [PMID: 21757118]
- 20 **Hachicha Z**, Dumesnil JG, Pibarot P. Usefulness of the valvuloarterial impedance to predict adverse outcome in asymptomatic aortic stenosis. *J Am Coll Cardiol* 2009; **54**: 1003-1011 [PMID: 19729117 DOI: 10.1016/j.jacc.2009.04.079]
- 21 **Herrmann HC**, Pibarot P, Hueter I, Gertz ZM, Stewart WJ, Kapadia S, Tuzcu EM, Babaliaros V, Thourani V, Szeto WY, Bavaria JE, Kodali S, Hahn RT, Williams M, Miller DC, Douglas PS, Leon MB. Predictors of mortality and outcomes of therapy in low-flow severe aortic stenosis: a Placement of Aortic Transcatheter Valves (PARTNER) trial analysis. *Circulation* 2013; **127**: 2316-2326 [PMID: 23661722 DOI: 10.1161/CIRCULATIONAHA.112.001290]
- 22 **Lancellotti P**, Lebois F, Simon M, Tombeux C, Chauvel C, Pierard LA. Prognostic importance of quantitative exercise Doppler echocardiography in asymptomatic valvular aortic stenosis. *Circulation* 2005; **112**: 1377-1382 [PMID: 16159850 DOI: 10.1161/CIRCULATIONAHA.104.523274]
- 23 **Maréchaux S**, Hachicha Z, Bellouin A, Dumesnil JG, Meimoun P, Pasquet A, Bergeron S, Arsenault M, Le Tourneau T, Ennezat PV, Pibarot P. Usefulness of exercise-stress echocardiography for risk stratification of true asymptomatic patients with aortic valve stenosis. *Eur Heart J* 2010; **31**: 1390-1397 [PMID: 20308041 DOI: 10.1093/eurheartj/ehq076]
- 24 **Lancellotti P**, Magne J, Donal E, O'Connor K, Dulgheru R, Rosca M, Pierard LA. Determinants and prognostic significance of exercise pulmonary hypertension in asymptomatic severe aortic stenosis. *Circulation* 2012; **126**: 851-859 [PMID: 22832784 DOI: 10.1161/CIRCULATIONAHA.111.088427]
- 25 **Maréchaux S**, Ennezat PV, LeJemtel TH, Polge AS, de Groote P, Asseman P, Nevière R, Le Tourneau T, Deklunder G. Left ventricular response to exercise in aortic stenosis: an exercise echocardiographic study. *Echocardiography* 2007; **24**: 955-959 [PMID: 17894574 DOI: 10.1111/j.1540-8175.2007.00501.x]
- 26 **Fryearson J**, Edwards NC, Doshi SN, Steeds RP. The role of TTE in assessment of the patient before and following TAVI for AS. *Echo Res Pract* 2016; **3**: R19-R34 [PMID: 27249549 DOI: 10.1530/ERP-16-0004]
- 27 **Baumgartner H**, Hung J, Bermejo J, Chambers JB, Evangelista A, Griffin BP, Iung B, Otto CM, Pellikka PA, Quiñones M. Echocardiographic assessment of valve stenosis: EAE/ASE recommendations for clinical practice. *J Am Soc Echocardiogr* 2009; **22**: 1-23; quiz 101-102 [PMID: 19130998 DOI: 10.1016/j.echo.2008.11.029]
- 28 **Minners J**, Allgeier M, Gohlke-Baerwolf C, Kienzle RP, Neumann FJ, Jander N. Inconsistencies of echocardiographic criteria for the grading of aortic valve stenosis. *Eur Heart J* 2008; **29**: 1043-1048 [PMID: 18156619 DOI: 10.1093/eurheartj/ehm543]
- 29 **Thaden JJ**, Nkomo VT, Lee KJ, Oh JK. Doppler Imaging in Aortic Stenosis: The Importance of the Nonapical Imaging Windows to Determine Severity in a Contemporary Cohort. *J Am Soc Echocardiogr* 2015; **28**: 780-785 [PMID: 25857547 DOI: 10.1016/j.echo.2015.02.016]
- 30 **Kadem L**, Dumesnil JG, Rieu R, Durand LG, Garcia D, Pibarot P. Impact of systemic hypertension on the assessment of aortic stenosis. *Heart* 2005; **91**: 354-361 [PMID: 15710719 DOI: 10.1136/hrt.2003.030601]
- 31 **Baumgartner H**, Stefenelli T, Niederberger J, Schima H, Maurer G. "Overestimation" of catheter gradients by Doppler ultrasound in patients with aortic stenosis: a predictable manifestation of pressure recovery. *J Am Coll Cardiol* 1999; **33**: 1655-1661 [PMID:

- 10334438 DOI: 10.1016/S0735-1097(99)00066-2]
- 32 **Chiam PT**, Chao VT, Tan SY, Koh TH, Lee CY, Tho VY, Sin YK, Chua YL. Percutaneous transcatheter heart valve implantation in a bicuspid aortic valve. *JACC Cardiovasc Interv* 2010; **3**: 559-561 [PMID: 20488414 DOI: 10.1016/j.jcin.2009.11.024]
  - 33 **Mylotte D**, Lefevre T, Søndergaard L, Watanabe Y, Modine T, Dvir D, Bosmans J, Tchetché D, Kornowski R, Sinning JM, Thériault-Lauzier P, O'Sullivan CJ, Barbanti M, Debry N, Buithieu J, Codner P, Dorfmeister M, Martucci G, Nickenig G, Wenaweser P, Tamburino C, Grube E, Webb JG, Windecker S, Lange R, Piazza N. Transcatheter aortic valve replacement in bicuspid aortic valve disease. *J Am Coll Cardiol* 2014; **64**: 2330-2339 [PMID: 25465419]
  - 34 **Himbert D**, Pontnau F, Messika-Zeitoun D, Descoutures F, Détaint D, Cuffé C, Sordi M, Laissy JP, Alkhoder S, Brochet E, Iung B, Depoix JP, Nataf P, Vahanian A. Feasibility and outcomes of transcatheter aortic valve implantation in high-risk patients with stenotic bicuspid aortic valves. *Am J Cardiol* 2012; **110**: 877-883 [PMID: 22677157 DOI: 10.1016/j.amjcard.2012.04.064]
  - 35 **Zegdi R**, Ciobotaru V, Noghin M, Sleilaty G, Lafont A, Latrémouille C, Deloche A, Fabiani JN. Is it reasonable to treat all calcified stenotic aortic valves with a valved stent? Results from a human anatomic study in adults. *J Am Coll Cardiol* 2008; **51**: 579-584 [PMID: 18237689 DOI: 10.1016/j.jacc.2007.10.023]
  - 36 **Delgado V**, Tops LF, Schuijf JD, de Roos A, Brugada J, Schalij MJ, Thomas JD, Bax JJ. Assessment of mitral valve anatomy and geometry with multislice computed tomography. *JACC Cardiovasc Imaging* 2009; **2**: 556-565 [PMID: 19442940 DOI: 10.1016/j.jcmg.2008.12.025]
  - 37 **Phan K**, Wong S, Phan S, Ha H, Qian P, Yan TD. Transcatheter Aortic Valve Implantation (TAVI) in Patients With Bicuspid Aortic Valve Stenosis--Systematic Review and Meta-Analysis. *Heart Lung Circ* 2015; **24**: 649-659 [PMID: 25818374 DOI: 10.1016/j.hlc.2014.12.163]
  - 38 **Kochman J**, Huczek Z, Scisło P, Dabrowski M, Chmielak Z, Szymański P, Witkowski A, Parma R, Ochala A, Chodór P, Wilczek K, Reczuch KW, Kubler P, Rymuza B, Kołowski L, Scibisz A, Wilimski R, Grube E, Opolski G. Comparison of one- and 12-month outcomes of transcatheter aortic valve replacement in patients with severely stenotic bicuspid versus tricuspid aortic valves (results from a multicenter registry). *Am J Cardiol* 2014; **114**: 757-762 [PMID: 25037674 DOI: 10.1016/j.amjcard.2014.05.063]
  - 39 **Elmariah S**, Palacios IF, McAndrew T, Hueter I, Ingleiss I, Baker JN, Kodali S, Leon MB, Svensson L, Pibarot P, Douglas PS, Fearon WF, Kirtane AJ, Maniar HS, Passeri JJ. Outcomes of transcatheter and surgical aortic valve replacement in high-risk patients with aortic stenosis and left ventricular dysfunction: results from the Placement of Aortic Transcatheter Valves (PARTNER) trial (cohort A). *Circ Cardiovasc Interv* 2013; **6**: 604-614 [PMID: 24221391 DOI: 10.1161/CIRCINTERVENTIONS.113.000650]
  - 40 **Pibarot P**, Dumessnil JG. Aortic stenosis: look globally, think globally. *JACC Cardiovasc Imaging* 2009; **2**: 400-403 [PMID: 19580720 DOI: 10.1016/j.jcmg.2009.01.004]
  - 41 **Lafitte S**, Perlant M, Reant P, Serri K, Douard H, DeMaria A, Roudaut R. Impact of impaired myocardial deformations on exercise tolerance and prognosis in patients with asymptomatic aortic stenosis. *Eur J Echocardiogr* 2009; **10**: 414-419 [PMID: 18996958 DOI: 10.1093/ejehocord/jen299]
  - 42 **Lancellotti P**, Donal E, Magne J, Moonen M, O'Connor K, Daubert JC, Pierard LA. Risk stratification in asymptomatic moderate to severe aortic stenosis: the importance of the valvular, arterial and ventricular interplay. *Heart* 2010; **96**: 1364-1371 [PMID: 20483891 DOI: 10.1136/hrt.2009.190942]
  - 43 **D'Andrea A**, Padalino R, Cocchia R, Di Palma E, Riegler L, Scarafile R, Rossi G, Bianchi R, Tartaglione D, Cappelli Bigazzi M, Calabrò P, Citro R, Bossone E, Calabrò R, Russo MG. Effects of transcatheter aortic valve implantation on left ventricular and left atrial morphology and function. *Echocardiography* 2015; **32**: 928-936 [PMID: 25323699 DOI: 10.1111/echo.12808]
  - 44 **Nombela-Franco L**, Ribeiro HB, Urena M, Allende R, Amat-Santos I, DeLarochelière R, Dumont E, Doyle D, DeLarochelière H, Laflamme J, Laflamme L, García E, Macaya C, Jiménez-Quevedo P, Côté M, Bergeron S, Beaudoin J, Pibarot P, Rodés-Cabau J. Significant mitral regurgitation left untreated at the time of aortic valve replacement: a comprehensive review of a frequent entity in the transcatheter aortic valve replacement era. *J Am Coll Cardiol* 2014; **63**: 2643-2658 [PMID: 24681140 DOI: 10.1016/j.jacc.2014.02.573]
  - 45 **Toggweiler S**, Boone RH, Rodés-Cabau J, Humphries KH, Lee M, Nombela-Franco L, Bagur R, Willson AB, Binder RK, Gurvitch R, Grewal J, Moss R, Munt B, Thompson CR, Freeman M, Ye J, Cheung A, Dumont E, Wood DA, Webb JG. Transcatheter aortic valve replacement: outcomes of patients with moderate or severe mitral regurgitation. *J Am Coll Cardiol* 2012; **59**: 2068-2074 [PMID: 22483326 DOI: 10.1016/j.jacc.2012.02.020]
  - 46 **Bedogni F**, Latib A, De Marco F, Agnifili M, Oreglia J, Pizzocri S, Latini RA, Lanotte S, Petronio AS, De Carlo M, Ettori F, Fiorina C, Poli A, Cirri S, De Servi S, Ramondo A, Tarantini G, Marzocchi A, Fiorilli R, Klugmann S, Ussia GP, Tamburino C, Maisano F, Brambilla N, Colombo A, Testa L. Interplay between mitral regurgitation and transcatheter aortic valve replacement with the CoreValve Revalving System: a multicenter registry. *Circulation* 2013; **128**: 2145-2153 [PMID: 24088530]
  - 47 **Chakravarty T**, Van Belle E, Jilaihawi H, Noheria A, Testa L, Bedogni F, Rück A, Barbanti M, Toggweiler S, Thomas M, Khawaja MZ, Hutter A, Abramowitz Y, Siegel RJ, Cheng W, Webb J, Leon MB, Makkar RR. Meta-analysis of the impact of mitral regurgitation on outcomes after transcatheter aortic valve implantation. *Am J Cardiol* 2015; **115**: 942-949 [PMID: 25779617 DOI: 10.1016/j.amjcard.2015.01.022]
  - 48 **Barbanti M**, Binder RK, Dvir D, Tan J, Freeman M, Thompson CR, Cheung A, Wood DA, Leipsic J, Webb JG. Prevalence and impact of preoperative moderate/severe tricuspid regurgitation on patients undergoing transcatheter aortic valve replacement. *Catheter Cardiovasc Interv* 2015; **85**: 677-684 [PMID: 24740834 DOI: 10.1002/ccd.25512]
  - 49 **Luçon A**, Oger E, Bedossa M, Boulmier D, Verhoye JP, Eltchaninoff H, Iung B, Leguerrier A, Laskar M, Leprince P, Gilard M, Le Breton H. Prognostic implications of pulmonary hypertension in patients with severe aortic stenosis undergoing transcatheter aortic valve implantation: study from the FRANCE 2 Registry. *Circ Cardiovasc Interv* 2014; **7**: 240-247 [PMID: 24569597 DOI: 10.1161/CIRCINTERVENTIONS.113.000482]
  - 50 **Lindman BR**, Zajarias A, Maniar HS, Miller DC, Suri RM, Arnold SV, Webb J, Svensson LG, Kodali S, Xu K, Ayele GM, Lin F, Wong SC, Babaliaros V, Thourani VH, Douglas PS, Lim S, Leon MB, Mack MJ. Risk stratification in patients with pulmonary hypertension undergoing transcatheter aortic valve replacement. *Heart* 2015; **101**: 1656-1664 [PMID: 26264371]
  - 51 **Chin D**. Echocardiography for transcatheter aortic valve implantation. *Eur J Echocardiogr* 2009; **10**: i21-i29 [PMID: 19131495 DOI: 10.1093/ejehocord/jen245]
  - 52 **Kempfert J**, Van Linden A, Lehmkuhl L, Rastan AJ, Holzhey D, Blumenstein J, Mohr FW, Walther T. Aortic annulus sizing: echocardiographic versus computed tomography derived measurements in comparison with direct surgical sizing. *Eur J Cardiothorac Surg* 2012; **42**: 627-633 [PMID: 22402450 DOI: 10.1093/ejcts/ezs064]
  - 53 **Saitoh T**, Shiota M, Izumo M, Gurudevan SV, Tolstrup K, Siegel RJ, Shiota T. Comparison of left ventricular outflow geometry and aortic valve area in patients with aortic stenosis by 2-dimensional versus 3-dimensional echocardiography. *Am J Cardiol* 2012; **109**: 1626-1631 [PMID: 22440128 DOI: 10.1016/j.amjcard.2012.01.391]
  - 54 **Messika-Zeitoun D**, Serfaty JM, Brochet E, Ducrocq G, Lepage L, Détaint D, Hyafil F, Himbert D, Pasi N, Laissy JP, Iung B, Vahanian A. Multimodal assessment of the aortic annulus diameter: implications for transcatheter aortic valve implantation. *J Am Coll Cardiol* 2010; **55**: 186-194 [PMID: 20117398 DOI: 10.1016/j.jacc.2009.06.063]
  - 55 **Santos N**, de Agustín JA, Almería C, Gonçalves A, Marcos-Alberca P, Fernández-Golfín C, García E, Hernández-Antolín R, de Isla



- LP, Macaya C, Zamorano J. Prosthesis/annulus discongruence assessed by three-dimensional transoesophageal echocardiography: a predictor of significant paravalvular aortic regurgitation after transcatheter aortic valve implantation. *Eur Heart J Cardiovasc Imaging* 2012; **13**: 931-937 [PMID: 22511810 DOI: 10.1093/ehjci/ies07]
- 56 **Husser O**, Holzamer A, Resch M, Endemann DH, Nunez J, Bodi V, Schmid C, Riegger GA, Gössmann H, Hamer O, Stroszczynski C, Luchner A, Hilker M, Hengstenberg C. Prosthesis sizing for transcatheter aortic valve implantation--comparison of three dimensional transesophageal echocardiography with multislice computed tomography. *Int J Cardiol* 2013; **168**: 3431-3438 [PMID: 23688431 DOI: 10.1016/j.ijcard.2013.04.182]
- 57 **Tops LF**, Krishnan SC, Schuijff JD, Schalij MJ, Bax JJ. Noncoronary applications of cardiac multidetector row computed tomography. *JACC Cardiovasc Imaging* 2008; **1**: 94-106 [PMID: 19356412 DOI: 10.1016/j.jcmg.2007.10.011]
- 58 **Rivard AL**, Bartel T, Bianco RW, O'Donnell KS, Bonatti J, Dichtl W, Cury RC, Feuchtnner GM. Evaluation of aortic root and valve calcifications by multi-detector computed tomography. *J Heart Valve Dis* 2009; **18**: 662-670 [PMID: 20099715]
- 59 **Delgado V**, Kapadia S, Schalij MJ, Schuijff JD, Tuzcu EM, Bax JJ. Transcatheter aortic valve implantation: implications of multimodality imaging in patient selection, procedural guidance, and outcomes. *Heart* 2012; **98**: 743-754 [PMID: 22523059 DOI: 10.1136/heartjnl-2011-301060]
- 60 **John D**, Buellesfeld L, Yuecel S, Mueller R, Latsios G, Beucher H, Gerckens U, Grube E. Correlation of Device landing zone calcification and acute procedural success in patients undergoing transcatheter aortic valve implantations with the self-expanding CoreValve prosthesis. *JACC Cardiovasc Interv* 2010; **3**: 233-243 [PMID: 20170883 DOI: 10.1016/j.jcin.2009.11.015]
- 61 **Haensig M**, Lehmkühl L, Rastan AJ, Kempfert J, Mukherjee C, Gutberlet M, Holzhey DM, Mohr FW. Aortic valve calcium scoring is a predictor of significant paravalvular aortic insufficiency in transapical-aortic valve implantation. *Eur J Cardiothorac Surg* 2012; **41**: 1234-1240; discussion 1234-1240 [PMID: 22241002 DOI: 10.1093/ejcts/ezr244]
- 62 **Kurra V**, Lieber ML, Sola S, Kalahasti V, Hammer D, Gimple S, Flamm SD, Bolen MA, Halliburton SS, Mihaljevic T, Desai MY, Schoenhagen P. Extent of thoracic aortic atheroma burden and long-term mortality after cardiothoracic surgery: a computed tomography study. *JACC Cardiovasc Imaging* 2010; **3**: 1020-1029 [PMID: 20947047 DOI: 10.1016/j.jcmg.2010.08.006]
- 63 **Ghanem A**, Müller A, Nöhle CP, Kocurek J, Werner N, Hammerstingl C, Schild HH, Schwab JO, Mellert F, Fimmers R, Nickenig G, Thomas D. Risk and fate of cerebral embolism after transfemoral aortic valve implantation: a prospective pilot study with diffusion-weighted magnetic resonance imaging. *J Am Coll Cardiol* 2010; **55**: 1427-1432 [PMID: 20188503 DOI: 10.1016/j.jacc.2009.12.026]
- 64 **Bloomfield GS**, Gillam LD, Hahn RT, Kapadia S, Leipsic J, Lerakis S, Tuzcu M, Douglas PS. A practical guide to multimodality imaging of transcatheter aortic valve replacement. *JACC Cardiovasc Imaging* 2012; **5**: 441-455 [PMID: 22498335 DOI: 10.1016/j.jcmg.2011.12.013]
- 65 **Stefanini GG**, Stortecky S, Wenaweser P, Windecker S. Coronary artery disease in patients undergoing TAVI: why, what, when and how to treat. *EuroIntervention* 2014; **10** Suppl U: U69-U75 [PMID: 25256334 DOI: 10.4244/EIJV10SUA10]
- 66 **Khawaja MZ**, Redwood SR, Thomas M. Coronary artery disease in patients undergoing TAVI--why not to treat. *EuroIntervention* 2014; **10** Suppl U: U76-U83 [PMID: 25256336 DOI: 10.4244/EIJV10SUA11]
- 67 **Julius BK**, Spillmann M, Vassalli G, Villari B, Eberli FR, Hess OM. Angina pectoris in patients with aortic stenosis and normal coronary arteries. Mechanisms and pathophysiological concepts. *Circulation* 1997; **95**: 892-898 [PMID: 9054747 DOI: 10.1161/01.CIR.95.4.892]
- 68 **Khawaja MZ**, Asrress KN, Haran H, Arri S, Nadra I, Bolter K, Wilson K, Clack L, Hancock J, Young CP, Bapat V, Thomas M, Redwood S. The effect of coronary artery disease defined by quantitative coronary angiography and SYNTAX score upon outcome after transcatheter aortic valve implantation (TAVI) using the Edwards bioprosthesis. *EuroIntervention* 2015; **11**: 450-455 [PMID: 24832041 DOI: 10.4244/EIJY14M05\_09]
- 69 **Smith CR**, Leon MB, Mack MJ, Miller DC, Moses JW, Svensson LG, Tuzcu EM, Webb JG, Fontana GP, Makkar RR, Williams M, Dewey T, Kapadia S, Babaliaros V, Thourani VH, Corso P, Pichard AD, Bavaria JE, Herrmann HC, Akin JJ, Anderson WN, Wang D, Pocock SJ. Transcatheter versus surgical aortic-valve replacement in high-risk patients. *N Engl J Med* 2011; **364**: 2187-2198 [PMID: 21639811 DOI: 10.1056/NEJMoa1103510]
- 70 **Van Mieghem NM**, van der Boon RM, Faqiri E, Diletti R, Schultz C, van Geuns RJ, Serruys PW, Kappetein AP, van Domburg RT, de Jaegere PP. Complete revascularization is not a prerequisite for success in current transcatheter aortic valve implantation practice. *JACC Cardiovasc Interv* 2013; **6**: 867-875 [PMID: 23871511 DOI: 10.1016/j.jcin.2013.04.015]
- 71 **Abdel-Wahab M**, Mostafa AE, Geist V, Stöcker B, Gordian K, Merten C, Richardt D, Toelg R, Richardt G. Comparison of outcomes in patients having isolated transcatheter aortic valve implantation versus combined with preprocedural percutaneous coronary intervention. *Am J Cardiol* 2012; **109**: 581-586 [PMID: 22133754 DOI: 10.1016/j.amjcard.2011.09.053]
- 72 **Pasic M**, Dreyse S, Unbehaun A, Buz S, Drews T, Klein C, D'Ancona G, Hetzer R. Combined elective percutaneous coronary intervention and transapical transcatheter aortic valve implantation. *Interact Cardiovasc Thorac Surg* 2012; **14**: 463-468 [PMID: 22232234 DOI: 10.1093/icvts/ivr144]
- 73 **Gasparetto V**, Fraccaro C, Tarantini G, Buja P, D'Onofrio A, Yzeiraj E, Pittarello D, Isabella G, Gerosa G, Iliceto S, Napodano M. Safety and effectiveness of a selective strategy for coronary artery revascularization before transcatheter aortic valve implantation. *Catheter Cardiovasc Interv* 2013; **81**: 376-383 [PMID: 22461314 DOI: 10.1002/ccd.24434]
- 74 **Gautier M**, Pepin M, Himbert D, Ducrocq G, Iung B, Dilly MP, Attias D, Nataf P, Vahanian A. Impact of coronary artery disease on indications for transcatheter aortic valve implantation and on procedural outcomes. *EuroIntervention* 2011; **7**: 549-555 [PMID: 21930458 DOI: 10.4244/EIJV7I5A90]
- 75 **Abramowitz Y**, Banai S, Katz G, Steinvil A, Arbel Y, Havakuk O, Halkin A, Ben-Gal Y, Keren G, Finkelstein A. Comparison of early and late outcomes of TAVI alone compared to TAVI plus PCI in aortic stenosis patients with and without coronary artery disease. *Catheter Cardiovasc Interv* 2014; **83**: 649-654 [PMID: 24532332 DOI: 10.1002/ccd.25233]
- 76 **Windecker S**, Kolh P, Alfonso F, Collet JP, Cremer J, Falk V, Filippatos G, Hamm C, Head SJ, Juni P, Kappetein AP, Kastrati A, Knuuti J, Landmesser U, Laufer G, Neumann FJ, Richter DJ, Schauerte P, Sousa Uva M, Stefanini GG, Taggart DP, Torracca L, Valgimigli M, Wijns W, Witkowski A. 2014 ESC/EACTS guidelines on myocardial revascularization. *EuroIntervention* 2015; **10**: 1024-1094 [PMID: 25187201 DOI: 10.4244/EIJY14M09\_01]
- 77 **Ludman PF**, Moat N, de Belder MA, Blackman DJ, Duncan A, Banya W, MacCarthy PA, Cunningham D, Wendler O, Marlee D, Hildick-Smith D, Young CP, Kovac J, Uren NG, Spyt T, Trivedi U, Howell J, Gray H. Transcatheter aortic valve implantation in the United Kingdom: temporal trends, predictors of outcome, and 6-year follow-up: a report from the UK Transcatheter Aortic Valve Implantation (TAVI) Registry, 2007 to 2012. *Circulation* 2015; **131**: 1181-1190 [PMID: 25637628 DOI: 10.1161/CIRCULATIONAHA.114.013947]
- 78 **Masson JB**, Lee M, Boone RH, Al Ali A, Al Bugami S, Hamburger J, John Mancini GB, Ye J, Cheung A, Humphries KH, Wood D, Nietlispach F, Webb JG. Impact of coronary artery disease on outcomes after transcatheter aortic valve implantation. *Catheter Cardiovasc Interv* 2010; **76**: 165-173 [PMID: 20665855 DOI: 10.1002/ccd.22501]
- 79 **Mohr FW**, Morice MC, Kappetein AP, Feldman TE, Stähle E, Colombo A, Mack MJ, Holmes DR, Morel MA, Van Dyck N, Houle VM, Dawkins KD, Serruys PW. Coronary artery bypass graft



- surgery versus percutaneous coronary intervention in patients with three-vessel disease and left main coronary disease: 5-year follow-up of the randomised, clinical SYNTAX trial. *Lancet* 2013; **381**: 629-638 [PMID: 23439102 DOI: 10.1016/S0140-6736(13)60141-5]
- 80 **Tu S**, Xu L, Lighthart J, Xu B, Witberg K, Sun Z, Koning G, Reiber JH, Regar E. In vivo comparison of arterial lumen dimensions assessed by co-registered three-dimensional (3D) quantitative coronary angiography, intravascular ultrasound and optical coherence tomography. *Int J Cardiovasc Imaging* 2012; **28**: 1315-1327 [PMID: 22261998 DOI: 10.1007/s10554-012-0016-6]
- 81 **Villari B**, Hess OM, Meier C, Pucillo A, Gaglione A, Turina M, Krayenbuehl HP. Regression of coronary artery dimensions after successful aortic valve replacement. *Circulation* 1992; **85**: 972-978 [PMID: 1531624 DOI: 10.1161/01.CIR.85.3.972]
- 82 **Khawaja MZ**, Wang D, Pocock S, Redwood SR, Thomas MR. The percutaneous coronary intervention prior to transcatheter aortic valve implantation (ACTIVATION) trial: study protocol for a randomized controlled trial. *Trials* 2014; **15**: 300 [PMID: 25059340 DOI: 10.1186/1745-6215-15-300]
- 83 **Serruys PW**, Morice MC, Kappetein AP, Colombo A, Holmes DR, Mack MJ, Stähle E, Feldman TE, van den Brand M, Bass EJ, Van Dyck N, Leadley K, Dawkins KD, Mohr FW. Percutaneous coronary intervention versus coronary-artery bypass grafting for severe coronary artery disease. *N Engl J Med* 2009; **360**: 961-972 [PMID: 19228612 DOI: 10.1056/NEJMoa0804626]
- 84 **Généreux P**, Palmerini T, Caixeta A, Rosner G, Green P, Dressler O, Xu K, Parise H, Mehran R, Serruys PW, Stone GW. Quantification and impact of untreated coronary artery disease after percutaneous coronary intervention: the residual SYNTAX (Synergy Between PCI with Taxus and Cardiac Surgery) score. *J Am Coll Cardiol* 2012; **59**: 2165-2174 [PMID: 22483327 DOI: 10.1016/j.jacc.2012.03.010]
- 85 **O'Sullivan CJ**, Englberger L, Hosek N, Heg D, Cao D, Stefanini GG, Stortecky S, Gloekler S, Spitzer E, Tüller D, Huber C, Pilgrim T, Praz F, Buellesfeld L, Khattab AA, Carrel T, Meier B, Windecker S, Wenaweser P. Clinical outcomes and revascularization strategies in patients with low-flow, low-gradient severe aortic valve stenosis according to the assigned treatment modality. *JACC Cardiovasc Interv* 2015; **8**: 704-717 [PMID: 25946444 DOI: 10.1016/j.jcin.2014.11.020]
- 86 **Rajappan K**, Rimoldi OE, Dutka DP, Ariff B, Pennell DJ, Sheridan DJ, Camici PG. Mechanisms of coronary microcirculatory dysfunction in patients with aortic stenosis and angiographically normal coronary arteries. *Circulation* 2002; **105**: 470-476 [PMID: 11815430 DOI: 10.1161/hc0402.102931]
- 87 **Wang H**, Hanna JM, Ganapathi A, Keenan JE, Hurwitz LM, Vavalle JP, Kiefer TL, Wang A, Harrison JK, Hughes GC. Comparison of aortic annulus size by transesophageal echocardiography and computed tomography angiography with direct surgical measurement. *Am J Cardiol* 2015; **115**: 1568-1573 [PMID: 25846765 DOI: 10.1016/j.amjcard.2015.02.060]
- 88 **Willson AB**, Webb JG, Freeman M, Wood DA, Gurvitch R, Thompson CR, Moss RR, Toggweiler S, Binder RK, Munt B, Cheung A, Hague C, Ye J, Leipsic JA. Computed tomography-based sizing recommendations for transcatheter aortic valve replacement with balloon-expandable valves: Comparison with transesophageal echocardiography and rationale for implementation in a prospective trial. *J Cardiovasc Comput Tomogr* 2012; **6**: 406-414 [PMID: 23127390 DOI: 10.1016/j.jcct.2012.10.002]
- 89 **Holmes DR**, Mack MJ, Kaul S, Agnihotri A, Alexander KP, Bailey SR, Calhoun JH, Carabello BA, Desai MY, Edwards FH, Francis GS, Gardner TJ, Kappetein AP, Linderbaum JA, Mukherjee C, Mukherjee D, Otto CM, Ruiz CE, Sacco RL, Smith D, Thomas JD. 2012 ACCF/AATS/SCAI/STS expert consensus document on transcatheter aortic valve replacement. *J Am Coll Cardiol* 2012; **59**: 1200-1254 [PMID: 22300974 DOI: 10.1016/j.jacc.2012.01.001]
- 90 **Narang A**, Guerrero M, Feldman T, Pursnani A. Computed tomography assessment for transcatheter mitral valve interventions. *J Cardiovasc Surg (Torino)* 2016; **57**: 360-371 [PMID: 27028331]
- 91 **Barbanti M1**, Immè S, Ohno Y, Gulino S, Todaro D, Sgroi C, Tamburino C2, Patané M, Pilato G, Capodanno D, Tamburino C. Prosthesis choice for transcatheter aortic valve replacement: Improved outcomes with the adoption of a patient-specific transcatheter heart valve selection algorithm. *Int J Cardiol* 2016; **203**: 1009-1010 [DOI: 10.1016/j.ijcard.2015.11.105]
- 92 **Feuchtnner G**, Plank F, Bartel T, Mueller S, Leipsic J, Schachner T, Müller L, Friedrich G, Klauser A, Grimm M, Bonaros N. Prediction of paravalvular regurgitation after transcatheter aortic valve implantation by computed tomography: value of aortic valve and annular calcification. *Ann Thorac Surg* 2013; **96**: 1574-1580 [PMID: 24070700 DOI: 10.1016/j.athoracsur.2013.06.049]
- 93 **Aggarwal SR**, Clavel MA, Messika-Zeitoun D, Cuffe C, Malouf J, Araoz PA, Mankad R, Michelena H, Vahanian A, Enriquez-Sarano M. Sex differences in aortic valve calcification measured by multidetector computed tomography in aortic stenosis. *Circ Cardiovasc Imaging* 2013; **6**: 40-47 [PMID: 23233744 DOI: 10.1161/CIRCIMAGING.112.980052]
- 94 **Clavel MA**, Pibarot P, Messika-Zeitoun D, Capoulade R, Malouf J, Aggarwal S, Araoz PA, Michelena HI, Cuffe C, Larose E, Miller JD, Vahanian A, Enriquez-Sarano M. Impact of aortic valve calcification, as measured by MDCT, on survival in patients with aortic stenosis: results of an international registry study. *J Am Coll Cardiol* 2014; **64**: 1202-1213 [PMID: 25236511 DOI: 10.1016/j.jacc.2014.05.066]
- 95 **Opolski MP**, Kim WK, Liebetrau C, Walther C, Blumenstein J, Gaede L, Kempfert J, Van Linden A, Walther T, Hamm CW, Möllmann H. Diagnostic accuracy of computed tomography angiography for the detection of coronary artery disease in patients referred for transcatheter aortic valve implantation. *Clin Res Cardiol* 2015; **104**: 471-480 [PMID: 25559245 DOI: 10.1007/s00392-014-0806-z]
- 96 **Gilard M**, Cornily JC, Pennec PY, Joret C, Le Gal G, Mansourati J, Blanc JJ, Bosch J. Accuracy of multislice computed tomography in the preoperative assessment of coronary disease in patients with aortic valve stenosis. *J Am Coll Cardiol* 2006; **47**: 2020-2024 [PMID: 16697319 DOI: 10.1016/j.jacc.2005.11.085]
- 97 **Meijboom WB**, Mollet NR, Van Mieghem CA, Kluin J, Weustink AC, Pugliese F, Vourvouri E, Cademartiri F, Bogers AJ, Krestin GP, de Feyter PJ. Pre-operative computed tomography coronary angiography to detect significant coronary artery disease in patients referred for cardiac valve surgery. *J Am Coll Cardiol* 2006; **48**: 1658-1665 [PMID: 17045904 DOI: 10.1016/j.jacc.2006.06.054]
- 98 **Stagnaro N**, Della Latta D, Chiappino D. Diagnostic accuracy of MDCT coronary angiography in patients referred for heart valve surgery. *Radiol Med* 2009; **114**: 728-742 [PMID: 19484586]
- 99 **Lindsay AC**, Sriharan M, Lazoura O, Sau A, Roughton M, Jabbour RJ, Di Mario C, Davies SW, Moat NE, Padley SP, Rubens MB, Nicol ED. Clinical and economic consequences of non-cardiac incidental findings detected on cardiovascular computed tomography performed prior to transcatheter aortic valve implantation (TAVI). *Int J Cardiovasc Imaging* 2015; **31**: 1435-1446 [PMID: 26068211 DOI: 10.1007/s10554-015-0685-z]
- 100 **Achenbach S**, Delgado V, Hausleiter J, Schoenhagen P, Min JK, Leipsic JA. SCCT expert consensus document on computed tomography imaging before transcatheter aortic valve implantation (TAVI)/transcatheter aortic valve replacement (TAVR). *J Cardiovasc Comput Tomogr* 2012; **6**: 366-380 [PMID: 23217460 DOI: 10.1016/j.jcct.2012.11.002]
- 101 **Wiegerinck EM**, Marquering HA, Oldenburger NY, Elattar MA, Planken RN, De Mol BA, Piek JJ, Baan J. Imaging for approach selection of TAVI: assessment of the aorto-iliac tract diameter by computed tomography-angiography versus projection angiography. *Int J Cardiovasc Imaging* 2014; **30**: 399-405 [PMID: 24326399 DOI: 10.1007/s10554-013-0343-2]
- 102 **Dewey TM**, Bowers B, Thourani VH, Babaliaros V, Smith CR, Leon MB, Svensson LG, Tuzcu EM, Miller DC, Teirstein PS, Tyner J, Brown DL, Fontana GP, Makkar RR, Williams MR, George I, Kirtane AJ, Bavaria JE, Mack MJ. Transapical aortic valve replacement for severe aortic stenosis: results from the nonrandomized continued access cohort of the PARTNER trial. *Ann Thorac Surg* 2013; **96**: 2083-2089 [PMID: 23968764 DOI: 10.1016/j.athoracsur.2013.05.093]
- 103 **Chaturvedi A**, Hobbs SK, Ling FS, Chaturvedi A, Knight P. MRI

- evaluation prior to Transcatheter Aortic Valve Implantation (TAVI): When to acquire and how to interpret. *Insights Imaging* 2016; **7**: 245-254 [PMID: 26911969 DOI: 10.1007/s13244-016-0470-0]
- 104 **Jabbour A**, Ismail TF, Moat N, Gulati A, Roussin I, Alpendurada F, Park B, Okoroafor F, Asgar A, Barker S, Davies S, Prasad SK, Rubens M, Mohiaddin RH. Multimodality imaging in transcatheter aortic valve implantation and post-procedural aortic regurgitation: comparison among cardiovascular magnetic resonance, cardiac computed tomography, and echocardiography. *J Am Coll Cardiol* 2011; **58**: 2165-2173 [PMID: 22078422 DOI: 10.1016/j.jacc.2011.09.010]
  - 105 **Pouleur AC**, le Polain de Waroux JB, Pasquet A, Vanoverschelde JL, Gerber BL. Aortic valve area assessment: multidetector CT compared with cine MR imaging and transthoracic and transesophageal echocardiography. *Radiology* 2007; **244**: 745-754 [PMID: 17630357 DOI: 10.1148/radiol.2443061127]
  - 106 **Paelinck BP**, Van Herck PL, Rodrigus I, Claeys MJ, Laborde JC, Parizel PM, Vrints CJ, Bosmans JM. Comparison of magnetic resonance imaging of aortic valve stenosis and aortic root to multimodality imaging for selection of transcatheter aortic valve implantation candidates. *Am J Cardiol* 2011; **108**: 92-98 [PMID: 21529729 DOI: 10.1016/j.amjcard.2011.02.348]
  - 107 **Eichenberger AC**, Jenni R, von Schulthess GK. Aortic valve pressure gradients in patients with aortic valve stenosis: quantification with velocity-encoded cine MR imaging. *AJR Am J Roentgenol* 1993; **160**: 971-977 [PMID: 8470612 DOI: 10.2214/ajr.160.5.8470612]
  - 108 **Koos R**, Altiok E, Mahnken AH, Neizel M, Dohmen G, Marx N, Kühl H, Hoffmann R. Evaluation of aortic root for definition of prosthesis size by magnetic resonance imaging and cardiac computed tomography: implications for transcatheter aortic valve implantation. *Int J Cardiol* 2012; **158**: 353-358 [PMID: 21315460 DOI: 10.1016/j.ijcard.2011.01.044]
  - 109 **Auerbach EG**, Martin ET. Magnetic resonance imaging of the peripheral vasculature. *Am Heart J* 2004; **148**: 755-763 [PMID: 15523304 DOI: 10.1016/j.ahj.2004.04.045]
  - 110 **Dweck MR**, Joshi S, Murigu T, Alpendurada F, Jabbour A, Melina G, Banya W, Gulati A, Roussin I, Raza S, Prasad NA, Wage R, Quarto C, Angeloni E, Refice S, Sheppard M, Cook SA, Kilner PJ, Pennell DJ, Newby DE, Mohiaddin RH, Pepper J, Prasad SK. Midwall fibrosis is an independent predictor of mortality in patients with aortic stenosis. *J Am Coll Cardiol* 2011; **58**: 1271-1279 [PMID: 21903062]
  - 111 **Weidemann F**, Herrmann S, Störk S, Niemann M, Frantz S, Lange V, Beer M, Gattenlöhner S, Voelker W, Ertl G, Strotmann JM. Impact of myocardial fibrosis in patients with symptomatic severe aortic stenosis. *Circulation* 2009; **120**: 577-584 [PMID: 19652094 DOI: 10.1161/CIRCULATIONAHA.108.847772]
  - 112 **Azevedo CF**, Nigri M, Higuchi ML, Pomerantzeff PM, Spina GS, Sampaio RO, Tarasoutchi F, Grinberg M, Rochitte CE. Prognostic significance of myocardial fibrosis quantification by histopathology and magnetic resonance imaging in patients with severe aortic valve disease. *J Am Coll Cardiol* 2010; **56**: 278-287 [PMID: 20633819 DOI: 10.1016/j.jacc.2009.12.074]
  - 113 **Irkle A**, Vesey AT, Lewis DY, Skepper JN, Bird JL, Dweck MR, Joshi FR, Gallagher FA, Warburton EA, Bennett MR, Brindle KM, Newby DE, Rudd JH, Davenport AP. Identifying active vascular microcalcification by (18)F-sodium fluoride positron emission tomography. *Nat Commun* 2015; **6**: 7495 [PMID: 26151378 DOI: 10.1038/ncomms8495]
  - 114 **Dweck MR**, Jenkins WS, Vesey AT, Pringle MA, Chin CW, Malley TS, Cowie WJ, Tsampasian V, Richardson H, Fletcher A, Wallace WA, Pessotto R, van Beek EJ, Boon NA, Rudd JH, Newby DE. 18F-sodium fluoride uptake is a marker of active calcification and disease progression in patients with aortic stenosis. *Circ Cardiovasc Imaging* 2014; **7**: 371-378 [PMID: 24508669 DOI: 10.1161/CIRCIMAGING.113.001508]
  - 115 **Dweck MR**, Jones C, Joshi NV, Fletcher AM, Richardson H, White A, Marsden M, Pessotto R, Clark JC, Wallace WA, Salter DM, McKillop G, van Beek EJ, Boon NA, Rudd JH, Newby DE. Assessment of valvular calcification and inflammation by positron emission tomography in patients with aortic stenosis. *Circulation* 2012; **125**: 76-86 [PMID: 22090163 DOI: 10.1161/CIRCULATIONAHA.111.051052]

**P- Reviewer:** Avanzas P, Shehada SE, Tang JM **S- Editor:** Qi Y  
**L- Editor:** A **E- Editor:** Wu HL





Published by **Baishideng Publishing Group Inc**

8226 Regency Drive, Pleasanton, CA 94588, USA

Telephone: +1-925-223-8242

Fax: +1-925-223-8243

E-mail: [bpgoffice@wjgnet.com](mailto:bpgoffice@wjgnet.com)

Help Desk: <http://www.wjgnet.com/esps/helpdesk.aspx>

<http://www.wjgnet.com>

