

World Journal of *Orthopedics*

World J Orthop 2017 May 18; 8(5): 364-440



**MINIREVIEWS**

- 364 Hallux rigidus: How do I approach it?
Lam A, Chan JJ, Surace MF, Vulcano E

ORIGINAL ARTICLE**Basic Study**

- 372 Light and electron microscopic study of the medial collateral ligament epiligament tissue in human knees
Georgiev GP, Iliev A, Kotov G, Kinov P, Slavchev S, Landzhov B

Observational Study

- 379 Technical note: Anterior cruciate ligament reconstruction in the presence of an intramedullary femoral nail using anteromedial drilling
Lacey M, Lamplot J, Walley KC, DeAngelis JP, Ramappa AJ

Prospective Study

- 385 Functional outcome of tibial fracture with acute compartment syndrome and correlation to deep posterior compartment pressure
Goyal S, Naik MA, Tripathy SK, Rao SK

Randomized Clinical Trial

- 394 Frozen shoulder - A prospective randomized clinical trial
Mukherjee RN, Pandey RM, Nag HL, Mittal R

SYSTEMATIC REVIEWS

- 400 Predicting lower limb periprosthetic joint infections: A review of risk factors and their classification
George DA, Drago L, Scarponi S, Gallazzi E, Haddad FS, Romano CL
- 412 Dementia and osteoporosis in a geriatric population: Is there a common link?
Downey CL, Young A, Burton EF, Graham SM, Macfarlane RJ, Tsapakis EM, Tsiridis E
- 424 Surgery for calcifying tendinitis of the shoulder: A systematic review
Verstraeten FU, Fievez E, Janssen L, Morrenhof W
- 431 Effect of lengthening along the anatomical axis of the femur and its clinical impact
Emara KM, Mahmoud AN, Emara AK, Emara MK

CASE REPORT

- 436 Chest pain caused by multiple exostoses of the ribs: A case report and a review of literature
Mazza D, Fabbri M, Calderaro C, Iorio C, Labianca L, Poggi C, Turturro F, Montanaro A, Ferretti A

Contents

World Journal of Orthopedics
Volume 8 Number 5 May 18, 2017

ABOUT COVER

Editorial Board Member of *World Journal of Orthopedics*, Bruce M Rothschild, MD, Professor, Department of Medicine, Northeast Ohio Medical University, Indiana, PA 15701, United States

AIM AND SCOPE

World Journal of Orthopedics (*World J Orthop*, *WJO*, online ISSN 2218-5836, DOI: 10.5312) is a peer-reviewed open access academic journal that aims to guide clinical practice and improve diagnostic and therapeutic skills of clinicians.

WJO covers topics concerning arthroscopy, evidence-based medicine, epidemiology, nursing, sports medicine, therapy of bone and spinal diseases, bone trauma, osteoarthropathy, bone tumors and osteoporosis, minimally invasive therapy, diagnostic imaging. Priority publication will be given to articles concerning diagnosis and treatment of orthopedic diseases. The following aspects are covered: Clinical diagnosis, laboratory diagnosis, differential diagnosis, imaging tests, pathological diagnosis, molecular biological diagnosis, immunological diagnosis, genetic diagnosis, functional diagnostics, and physical diagnosis; and comprehensive therapy, drug therapy, surgical therapy, interventional treatment, minimally invasive therapy, and robot-assisted therapy.

We encourage authors to submit their manuscripts to *WJO*. We will give priority to manuscripts that are supported by major national and international foundations and those that are of great basic and clinical significance.

INDEXING/ABSTRACTING

World Journal of Orthopedics is now indexed in Emerging Sources Citation Index (Web of Science), PubMed, PubMed Central and Scopus.

FLYLEAF

I-III Editorial Board

EDITORS FOR THIS ISSUE

Responsible Assistant Editor: *Xiang Li*
Responsible Electronic Editor: *Ya-Jing Lu*
Proofing Editor-in-Chief: *Lian-Sheng Ma*

Responsible Science Editor: *Fang-Fang Ji*
Proofing Editorial Office Director: *Xiu-Xia Song*

NAME OF JOURNAL
World Journal of Orthopedics

ISSN
ISSN 2218-5836 (online)

LAUNCH DATE
November 18, 2010

FREQUENCY
Monthly

EDITORS-IN-CHIEF
Quanjun (Trey) Cui, MD, Professor, Department of Orthopaedic Surgery, School of Medicine, University of Virginia, Charlottesville, VA 22908, United States

Bao-Gan Peng, MD, PhD, Professor, Department of Spinal Surgery, General Hospital of Armed Police Force, Beijing 100039, China

EDITORIAL BOARD MEMBERS
All editorial board members resources online at <http://www.wjgnet.com>

www.wjgnet.com/2218-5836/editorialboard.htm

EDITORIAL OFFICE
Xiu-Xia Song, Director
World Journal of Orthopedics
Baishideng Publishing Group Inc
7901 Stoneridge Drive, Suite 501, Pleasanton, CA 94588, USA
Telephone: +1-925-2238242
Fax: +1-925-2238243
E-mail: editorialoffice@wjgnet.com
Help Desk: <http://www.fgpublishing.com/helpdesk>
<http://www.wjgnet.com>

PUBLISHER
Baishideng Publishing Group Inc
7901 Stoneridge Drive,
Suite 501, Pleasanton, CA 94588, USA
Telephone: +1-925-2238242
Fax: +1-925-2238243
E-mail: bpgoffice@wjgnet.com
Help Desk: <http://www.fgpublishing.com/helpdesk>
<http://www.wjgnet.com>

PUBLICATION DATE
May 18, 2017

COPYRIGHT
© 2017 Baishideng Publishing Group Inc. Articles published by this Open-Access journal are distributed under the terms of the Creative Commons Attribution Non-commercial License, which permits use, distribution, and reproduction in any medium, provided the original work is properly cited, the use is non commercial and is otherwise in compliance with the license.

SPECIAL STATEMENT
All articles published in journals owned by the Baishideng Publishing Group (BPG) represent the views and opinions of their authors, and not the views, opinions or policies of the BPG, except where otherwise explicitly indicated.

INSTRUCTIONS TO AUTHORS
<http://www.wjgnet.com/bpg/gerinfo/204>

ONLINE SUBMISSION
<http://www.fgpublishing.com>

Effect of lengthening along the anatomical axis of the femur and its clinical impact

Khaled M Emara, Ahmed Nageeb Mahmoud, Ahmed K Emara, Mariam K Emara

Khaled M Emara, Ahmed Nageeb Mahmoud, Ahmed K Emara, Mariam K Emara, Limb Reconstruction and Deformity Correction Unit, Orthopaedic Surgery Department, Ain Shams University Hospitals, Cairo 11566, Egypt

Author contributions: Emara KM contributed to study design; Mahmoud AN contributed to literature review, research, manuscript design and writing; Emara AK contributed to writing and research; Emara MK contributed to calculation, mathematical engineering and illustrations.

Conflict-of-interest statement: The authors declare that there are no conflicts of interest related to this research.

Data sharing statement: No additional data are available.

Open-Access: This article is an open-access article which was selected by an in-house editor and fully peer-reviewed by external reviewers. It is distributed in accordance with the Creative Commons Attribution Non Commercial (CC BY-NC 4.0) license, which permits others to distribute, remix, adapt, build upon this work non-commercially, and license their derivative works on different terms, provided the original work is properly cited and the use is non-commercial. See: <http://creativecommons.org/licenses/by-nc/4.0/>

Manuscript source: Invited manuscript

Correspondence to: Dr. Khaled M Emara, Professor, Limb Reconstruction and Deformity Correction Unit, Orthopaedic Surgery Department, Ain Shams University Hospitals, 13 B Kornesh EL Nile, Agha Khan, Cairo 11566, Egypt. kmemara@hotmail.com
Telephone: +20-22-2055661
Fax: +20-22-2055662

Received: November 7, 2016
Peer-review started: November 10, 2016
First decision: February 15, 2017
Revised: March 4, 2017
Accepted: March 16, 2017
Article in press: March 17, 2017
Published online: May 18, 2017

Abstract

AIM

To review and study the effect of lengthening along the anatomical axis of long bones and its relation to the mechanical axis deviation.

METHODS

We try in this review to calculate and discuss the exact clinical impact of lengthening along the anatomical axis of the femur on affecting the limb alignment. Also we used a trigonometric formula to predict the change of the femoral distal anatomical mechanical angle (AMA) after lengthening along the anatomical axis.

RESULTS

Lengthening along the anatomical axis of the femur by 10% of its original length results in reduction in the distal femoral AMA by 0.57 degrees. There is no objective experimental scientific data to prove that the Mechanical axis is passing *via* the center of the hip to the center of the knee. There is wide variation in normal anatomical axis for different populations. In deformity correction, surgeons try to reproduce the normal usual bone shape to regain normal function, which is mainly anatomical axis.

CONCLUSION

Lengthening of the femur along its anatomical axis results in mild reduction of the distal femoral AMA. This may partially compensate for the expected mechanical axis lateralisation and hence justify its minimal clinical impact.

Key words: Bone lengthening; Deformity; Femoral lengthening; External fixation; Intramedullary nail; Axis deviation

© The Author(s) 2017. Published by Baishideng Publishing Group Inc. All rights reserved.

Core tip: In deformity correction the aim is to reproduce

the normal anatomical shape of the bone to regain normal function. There is no experimental data to prove the passage of the imaginary mechanical axis and load distribution of the body *via* the center of the hip to the center of the knee. Lengthening along anatomical axis of the bone is expected to cause minimal or no clinical effect on mechanical axis and load distribution on joints.

Emara KM, Mahmoud AN, Emara AK, Emara MK. Effect of lengthening along the anatomical axis of the femur and its clinical impact. *World J Orthop* 2017; 8(5): 431-435 Available from: URL: <http://www.wjgnet.com/2218-5836/full/v8/i5/431.htm> DOI: <http://dx.doi.org/10.5312/wjo.v8.i5.431>

INTRODUCTION

The goal of recent advances in the field of limb lengthening is to increase the patient acceptance and comfort and avoid the common complications of the classic external fixators. One important achievement is the use of totally implantable intramedullary distracting nails for tibia and femur. Among them, the Albizzia nail (DePuy, Villeurbanne, France), Fitbone (Wittenstein, Igersheim, Germany), Intramedullary Skeletal Kinetic Distractor (ISKD, Orthofix Inc., McKinney, TX, United States) and Precise nail (Ellipse Technologies Inc., Irvine, California) were used successfully^[1,2]. These are self-lengthening telescopic intramedullary rods, which could be fully motorized or un-motorized and depend on external apparatus or limb movement to make them extend^[1]. Intramedullary lengthening utilizes the anatomical axis of the bone, in contrast to lengthening with external fixators which occurs along the mechanical axis. In the tibia, no difference would be detected after either ways of lengthening since the anatomical and mechanical axes of the tibia are almost the same^[3]. However, in normal femora, the mechanical and anatomic femoral axes diverge by approximately 5°-9°. This angle is known as the anatomic-mechanical angle (AMA)^[2-4]. When using intramedullary lengthening in femora, lateralization of the overall limb alignment has been observed both theoretically and radiologically^[2-7]. The amount of mechanical axis lateralization has been documented by Burghardt *et al.*^[2], who concluded that each 1 cm lengthening of the femur results in about 1 mm lateralization of the mechanical axis radiologically. However, the exact clinical outcome of such mechanical axis lateralization has not been presented clearly in literature. The purpose of this study is to review the exact effect of lengthening along the anatomical axis on disturbing the normal mechanical alignment of the limb and hence distribution of load along the joint surface. We have reviewed the trigonometric formula to predict the change of the femoral AMA after lengthening along the anatomical axis, and reflected the results on the clinical outcome of mechanical axis deviation.

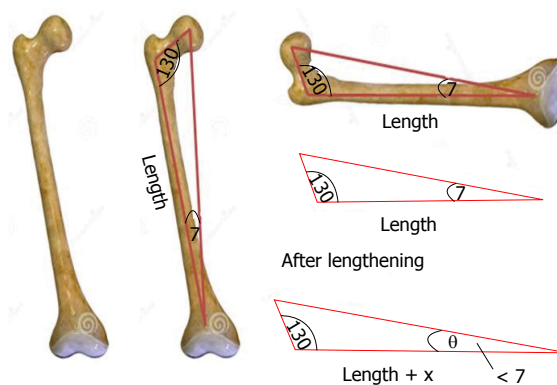


Figure 1 Femoral lengthening along the anatomical axis (length) affects the femoral anatomical mechanical angle (assumed to be 7 degrees). Increasing the femoral length along the anatomical axis would cause decrease in the anatomical mechanical angle (θ).

MATERIALS AND METHODS

Trigonometry was used to calculate the change in the angle between the femoral mechanical and anatomical axes resulting from lengthening along the anatomical axis. The original angle is assumed to be 7°, where "θ" is the angle after lengthening the femur a distance of "x" cm (Figure 1).

The angle θ was calculated for different original bone lengths and different lengthening distances. Original bone lengths used in our calculations are average lengths that vary from 21 cm for a 3 years old, up to 44 cm for an adult female and 47 cm for an adult male^[6]. Femur lengths were considered for different ages with a step of 3 years of age, and so 3, 6, 9, 12, 15 years old, adults' femurs were considered. Lengthening distances that were considered to vary from 3 to 18 cm, adding 3 cm each step (3, 6, 9, 12, 15, and 18) (Figure 2).

RESULTS


Results of the change of the femoral AMA after lengthening were expressed in Table 1. From the calculations, it was deduced that increasing the bone length by 10% its original length results in reduction of the angle between the mechanical and anatomic axes by 0.57°, and increasing the length by 20% reduces the angle by 1.05° approximately.

DISCUSSION

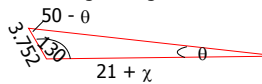
Our hypothesis was that the femoral lengthening along the anatomical axis with a telescopic intramedullary nail induces reduction of the femoral anatomical mechanical angle (AMA) which is normally around 7°. This may compensate for the limb mechanical axis that lateralization that was proven both theoretically and radiologically^[2-4,6], and hence could partially justify the minimal clinical impact of such mechanical angle lateralization after intramedullary lengthening.

A shift of the mechanical axis of the limb has been

A For 21 cm femur (3 years old)

$$\frac{\sin 43}{21} = \frac{\sin 7}{l} \rightarrow l = 3.752$$



-After lengthening



$$\frac{\sin \theta}{3.752} = \frac{\sin (50 - \theta)}{21 + \lambda} \rightarrow \frac{\sin (50 - \theta)}{\sin \theta} = \frac{21 + \lambda}{3.752} \rightarrow \frac{\sin 50 \cos \theta - \cos 50 \sin \theta}{\sin \theta} = \frac{21 + \lambda}{3.752}$$

$$\tan \theta = \frac{\sin 50}{\frac{21 + \lambda}{3.752} + \cos 50} \rightarrow \theta = \tan^{-1} \left(\frac{\sin 50}{\frac{21 + \lambda}{3.752} + \cos 50} \right)$$

B 28 cm femur (6 years old), and equation of angle after lengthening:



$$\theta = \tan^{-1} \left(\frac{\sin 50}{\frac{28 + \lambda}{5} + \cos 50} \right)$$

C 35 cm femur (9 years old), and equation of angle after lengthening:



$$\theta = \tan^{-1} \left(\frac{\sin 50}{\frac{35 + \lambda}{6.25} + \cos 50} \right)$$

D 40 cm femur (12 years old), and equation of angle after lengthening:



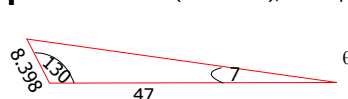
$$\theta = \tan^{-1} \left(\frac{\sin 50}{\frac{40 + \lambda}{7.148} + \cos 50} \right)$$

E 44 cm femur (15 years old/adult female), and equation of angle after lengthening:



$$\theta = \tan^{-1} \left(\frac{\sin 50}{\frac{44 + \lambda}{7.862} + \cos 50} \right)$$

F 47 cm femur (adult male), and equation of angle after lengthening:



$$\theta = \tan^{-1} \left(\frac{\sin 50}{\frac{47 + \lambda}{8.398} + \cos 50} \right)$$

Figure 2 Calculation of the changes in the θ angle after lengthening of different sizes of femora using Law of Sines (A-F).

reported differently in studies about lengthening with a telescopic intramedullary nails^[2,8-11]. Theoretically, Burghardt *et al.*^[4] found lateralization of the limb mechanical axis after lengthening along the anatomical axis using trigonometry. Radiologically, Bughdart *et al.*^[2] found that 26 of 27 limbs which had intramedullary lengthening with the Precise nail, had a lateral shift of the mechanical axis, and concluded that lengthening of the femur by 1 cm causes lateral shift of the limb mechanical axis by 1 mm. In a similar study about femoral lengthening with the Albizzia nail, Guichet *et al.*^[12] found that a lateral shift of the mechanical axis of the limb was seen in all the study cases, with a mean increase in the genu valgum angle by 1.04 degrees, however they could not find a constant correlation between the amount of mechanical axis deviation and the gain in femoral length. Similarly, Baumgart *et al.*^[8] found a maximal mechanical axis deviation of 2 mm after using fully motorized intramedullary nails in femoral lengthening, and hence they recommended shifting the distal fragment laterally before reaming, in order to achieve normal mechanical alignment. Other similar studies about intramedullary femoral lengthening either have not commented on the mechanical axis deviation^[9], noticed very rare occurrence of mechanical axis deviation^[5,10] or did not find any mechanical axis alteration nor angular deformities after

lengthening^[11].

On the other hand, all the studies which found a radiological mechanical axis deviation after femoral lengthening with intramedullary nails did not comment on the isolated femoral axes relation changes, which in our case represented by the distal femoral AMA. Clinically, all these studies have described that mechanical axis lateral shift to be inconsequential or clinically insignificant^[2,5,7,9-12]. This might support our hypothesis, that such mechanical axis shift could be partially compensated by reduction in the distal femoral AMA concluded in our study, and hence no clinical consequences could be observed. Also this might be attributed due to the wide variation of the mechanical limb alignment in (normal) individuals. In the study of Ekhoft *et al.*^[13], only 2% of normal limbs included in the study have a neutral mechanical axis, and as many as 76% deviate from neutral by $> 3^\circ$ varus when measured using CT. Also, Bellemans *et al.*^[14] found that limb alignment differs between males and females as studied by using full-length lower limb radiographs. In this study, 32% of male and 17.2% female knees were in $> 3^\circ$ of constitutional varus. Similarly, Yaniv *et al.*^[15] found that varus knee axis deviation is normally present in football players older than 13 years old.

The mechanical axis is supposed to be the line of body weight loading the joints to the ground, and since

Table 1 Changes in the anatomical mechanical angle after lengthening

Femur length (cm)	X	P	θ	$\Delta\theta$
21	3	14	6.21	0.79
	6	28	5.58	1.42
	9	42	5.06	1.94
	12	57	4.64	2.36
	15	71	4.28	2.72
28	18	85	3.97	3.03
	3	10	6.38	0.62
	6	21	5.87	1.13
	9	32	5.44	1.56
	12	42	5.06	1.94
35	15	53	4.73	2.27
	18	64	4.45	2.55
	3	8	6.5	0.5
	6	17	6.07	0.93
	9	25	5.69	1.31
40	12	34	5.36	1.64
	15	42	5.06	1.94
	18	51	4.8	2.2
	3	7	6.56	0.44
	6	15	6.17	0.83
44	9	22	5.83	1.17
	12	30	5.52	1.48
	15	37	5.25	1.75
	18	45	5	2
	3	7	6.6	0.4
47	6	13	6.24	0.76
	9	20	5.92	1.08
	12	27	5.63	1.37
	15	34	5.37	1.63
	18	41	5.13	1.87
	3	6	6.62	0.38
	6	12	6.28	0.72
	9	19	5.98	1.02
	12	25	5.7	1.3
	15	32	5.45	1.55
	18	38	5.22	1.78

X: Distance lengthened (cm); P: Percentage lengthened distance of the original bone length (%); θ : Angle between mechanical and anatomical axes after lengthening (degree); $\Delta\theta$: Change in the angle between mechanical and anatomical axes due to lengthening (degree).

the body centre of gravity could be affected greatly by postural abnormalities that may be present in different patients, marked differences in the limb mechanical axes could be seen in different individuals. The situation is further complicated by differences in the alignment of the limb when measured in a lying position (which is non-weight bearing) and in a weight-bearing standing position^[16]. In a study by Deep *et al*^[17], they found the limb alignment to be dynamic process that differs according to different postures, and also varies between males and females in normal knees. Deep *et al*^[17] found also a greater tendency into varus malalignment in the study group with normal non-arthritis knees, that go into more varus when changing the position from supine to standing. Walcox *et al*^[16] found similar changes in arthritic knees. Again, the presence of nutritional abnormalities in Calcium and vitamin D metabolism could lead high prevalence of mechanical axes varus malalignment in normally looking adolescents^[18]. Again, in general

population and different races, there is a range of varus and valgus deformation that has no clinical effect, and there is no fixed number for the normal anatomical shape of human bone. Some mild change during lengthening can stay in most of the cases within this range. The assumption of fixed normal passage of mechanical loading on the limb is not exactly compatible with reality due to the different positions the normal human body use along the day in normal life. Also there is no objective Empirical data to prove where is the normal passage of mechanical axis in relation to the human joints. Since the aim of deformity correction surgery is to reproduce the near normal anatomical shape of bones to improve function, anatomical axis should be the main guide for surgeons in deformity correction and limb reconstruction.

All these data, beside the fact that even the documented amount of mechanical axis lateralization, 1 mm for each 1 cm lengthening, remains very little, this may further justify that the actual implementation of the mechanical axis deviation on the clinical outcome could be very mild or even non significant.

In conclusion, although mechanical axis lateralization after lengthening along the anatomical axis was documented theoretically and radiologically in literature, we found that lengthening of the femur along the anatomical axis theoretically reduce the distal femur AMA by around 0.57 degrees approximately for lengthening by 10% of the original bone length. This change, along with the high variation of population mechanical limb alignment could justify the minimal clinical effect seen with of such mechanical axis deviation after femoral lengthening along the anatomical axis.

COMMENTS

Background

Bone lengthening and deformity correction surgery consider the mechanical and anatomical axes during the surgical planning and treatment. This review article aim to stimulate critical thinking to some fixed ideas in the community of orthopaedic surgeons, specially pediatric orthopedics and limb reconstruction.

Research frontiers

There are objective data about anatomical shape of bone and the range of normal variation but there is no sufficient data regarding the normal mechanical axis and its variation between normal population.

Innovations and breakthroughs

The authors recommend considering anatomical axis as the main guide for lengthening, and not to over emphasize on mechanical axis, and mild variations in anatomical axis during lengthening.

Applications

Lengthening along anatomical axis is safe and effective.

Terminology

Anatomical and mechanical axis are terms used in deformity correction and bone lengthening.

Peer-review

The authors present a review article about the effects of lengthening along the anatomical axis, using a trigonometric approach. They refer to the topic of

mechanical axis lateralisation in intramedullary limb lengthening and check the clinical relevance.

REFERENCES

- 1 **Mahmoud AN**, Amgad M, Abdelmohsen MT, Nagy AY, Abuelhadid M, Aref AI, Abdulrahim AF, Al Abdullah MA, Emara K. Is the Intramedullary Skeletal Kinetic Distractor a Safe Measure for Bone Lengthening? A Systematic Review. *JOTR* 2014; **18**: 69-78 [DOI: 10.1016/j.jotr.2014.01.002]
- 2 **Burghardt RD**, Paley D, Specht SC, Herzenberg JE. The effect on mechanical axis deviation of femoral lengthening with an intramedullary telescopic nail. *J Bone Joint Surg Br* 2012; **94**: 1241-1245 [PMID: 22933497 DOI: 10.1302/0301-620X.94B9.28672]
- 3 **Paley D**. Principles of deformity correction. Berlin: Springer-Verlag, 2002
- 4 **Burghardt RD**, Herzenberg JE, Burghardt MH. Trigonometric analysis of the mechanical axis deviation induced by telescopic intramedullary femoral lengthening nails. *J Appl Biomech* 2011; **27**: 385-391 [PMID: 21896945]
- 5 **Paley D**, Herzenberg JE, Paremain G, Bhav A. Femoral lengthening over an intramedullary nail. A matched-case comparison with Ilizarov femoral lengthening. *J Bone Joint Surg Am* 1997; **79**: 1464-1480 [PMID: 9378732]
- 6 **Muthusamy S**, Rozbruch SR, Fragomen AT. The use of blocking screws with internal lengthening nail and reverse rule of thumb for blocking screws in limb lengthening and deformity correction surgery. *Strategies Trauma Limb Reconstr* 2016; **11**: 199-205 [PMID: 27665618 DOI: 10.1007/s11751-016-0265-3]
- 7 **Robert N**. Hensinger. Standards in pediatric orthopedics: tables, charts, and graphs illustrating growth. New York: Raven Press, 1986
- 8 **Baumgart R**, Betz A, Schweiberer L. A fully implantable motorized intramedullary nail for limb lengthening and bone transport. *Clin Orthop Relat Res* 1997; **343**: 135-143 [PMID: 9345218]
- 9 **Cole JD**, Justin D, Kasparis T, DeVlugt D, Knobloch C. The intramedullary skeletal kinetic distractor (ISKD): first clinical results of a new intramedullary nail for lengthening of the femur and tibia. *Injury* 2001; **32** Suppl 4: S129-S139 [PMID: 11812486]
- 10 **García-Cimbreló E**, Curto de la Mano A, García-Rey E, Cordero J, Martí-Ciruelos R. The intramedullary elongation nail for femoral lengthening. *J Bone Joint Surg Br* 2002; **84**: 971-977 [PMID: 12358388]
- 11 **Singh S**, Lahiri A, Iqbal M. The results of limb lengthening by callus distraction using an extending intramedullary nail (Fitbone) in non-traumatic disorders. *J Bone Joint Surg Br* 2006; **88**: 938-942 [PMID: 16799000]
- 12 **Guichet JM**, Deromedis B, Donnan LT, Peretti G, Lascombes P, Bado F. Gradual femoral lengthening with the Albizzia intramedullary nail. *J Bone Joint Surg Am* 2003; **85-A**: 838-848 [PMID: 12728034]
- 13 **Eckhoff DG**, Bach JM, Spitzer VM, Reinig KD, Bagur MM, Baldini TH, Flannery NM. Three-dimensional mechanics, kinematics, and morphology of the knee viewed in virtual reality. *J Bone Joint Surg Am* 2005; **87** Suppl 2: 71-80 [PMID: 16326726]
- 14 **Bellemans J**, Colyn W, Vandenuecker H, Victor J. The Chitranjan Ranawat award: is neutral mechanical alignment normal for all patients? The concept of constitutional varus. *Clin Orthop Relat Res* 2012; **470**: 45-53 [PMID: 21656315 DOI: 10.1007/s11999-011-1936-5]
- 15 **Yaniv M**, Becker T, Goldwirth M, Khamis S, Steinberg DM, Weintraub S. Prevalence of bowlegs among child and adolescent soccer players. *Clin J Sport Med* 2006; **16**: 392-396 [PMID: 17016114]
- 16 **Willcox NM**, Clarke JV, Smith BR, Deakin AH, Deep K. A comparison of radiological and computer navigation measurements of lower limb coronal alignment before and after total knee replacement. *J Bone Joint Surg Br* 2012; **94**: 1234-1240 [PMID: 22933496 DOI: 10.1302/0301-620X.94B9.28250]
- 17 **Deep K**, Eachempati KK, Apsingi S. The dynamic nature of alignment and variations in normal knees. *Bone Joint J* 2015; **97-B**: 498-502 [PMID: 25820888 DOI: 10.1302/0301-620X.97B4.33740]
- 18 **Voloc A**, Esterle L, Nguyen TM, Walrant-Debray O, Colofitchi A, Jehan F, Garabedian M. High prevalence of genu varum/valgum in European children with low vitamin D status and insufficient dairy products/calcium intakes. *Eur J Endocrinol* 2010; **163**: 811-817 [PMID: 20739417 DOI: 101530/EJE-10-0434]

P- Reviewer: Schiedel FM, Zak L **S- Editor:** Song XX **L- Editor:** A
E- Editor: Lu YJ





Published by **Baishideng Publishing Group Inc**
7901 Stoneridge Drive, Suite 501, Pleasanton, CA 94588, USA
Telephone: +1-925-223-8242
Fax: +1-925-223-8243
E-mail: bpgoffice@wjgnet.com
Help Desk: <http://www.f6publishing.com/helpdesk>
<http://www.wjgnet.com>

