

World Journal of *Gastrointestinal Surgery*

World J Gastrointest Surg 2017 August 27; 9(8): 174-185





MINIREVIEWS

- 174 Abdominal tuberculosis: Is there a role for surgery?

Weledji EP, Pokam BT

CASE REPORT

- 182 Novel technique of abdominal wall nerve block for laparoscopic colostomy: Rectus sheath block with transperitoneal approach

Nagata J, Watanabe J, Sawatsubashi Y, Akiyama M, Arase K, Minagawa N, Torigoe T, Hamada K, Nakayama Y, Hirata K

Contents

World Journal of Gastrointestinal Surgery
Volume 9 Number 8 August 27, 2017

ABOUT COVER

Editorial Board Member of *World Journal of Gastrointestinal Surgery*, Robert AFM Chamuleau, MD, PhD, Professor, Department of Hepatology, Academic Medical Center, University of Amsterdam, BK 1105 Amsterdam, The Netherlands

AIM AND SCOPE

World Journal of Gastrointestinal Surgery (*World J Gastrointest Surg*, *WJGS*, online ISSN 1948-9366, DOI: 10.4240) is a peer-reviewed open access academic journal that aims to guide clinical practice and improve diagnostic and therapeutic skills of clinicians.

WJGS covers topics concerning micro-invasive surgery; laparoscopy; hepatic, biliary, pancreatic and splenic surgery; surgical nutrition; portal hypertension, as well as associated subjects. The current columns of *WJGS* include editorial, frontier, diagnostic advances, therapeutics advances, field of vision, mini-reviews, review, topic highlight, medical ethics, original articles, case report, clinical case conference (Clinicopathological conference), and autobiography. Priority publication will be given to articles concerning diagnosis and treatment of gastrointestinal surgery diseases. The following aspects are covered: Clinical diagnosis, laboratory diagnosis, differential diagnosis, imaging tests, pathological diagnosis, molecular biological diagnosis, immunological diagnosis, genetic diagnosis, functional diagnostics, and physical diagnosis; and comprehensive therapy, drug therapy, surgical therapy, interventional treatment, minimally invasive therapy, and robot-assisted therapy.

We encourage authors to submit their manuscripts to *WJGS*. We will give priority to manuscripts that are supported by major national and international foundations and those that are of great basic and clinical significance.

INDEXING/ABSTRACTING

World Journal of Gastrointestinal Surgery is now indexed in Emerging Sources Citation Index (Web of Science), PubMed, and PubMed Central.

FLYLEAF

I-III Editorial Board

EDITORS FOR THIS ISSUE

Responsible Assistant Editor: *Xiang Li*
Responsible Electronic Editor: *Ya-Jing Lu*
Proofing Editor-in-Chief: *Lian-Sheng Ma*

Responsible Science Editor: *Jin-Xin Kong*
Proofing Editorial Office Director: *Jin-Lei Wang*

NAME OF JOURNAL

World Journal of Gastrointestinal Surgery

ISSN

ISSN 1948-9366 (online)

LAUNCH DATE

November 30, 2009

FREQUENCY

Monthly

EDITOR-IN-CHIEF

Timothy M Pawlik, MD, Director, Professor, Department of Surgery, Johns Hopkins University, School of Medical, Baltimore, MD 21287, United States

EDITORIAL BOARD MEMBERS

All editorial board members resources online at <http://www.wjgnet.com/1948-9366/editorialboard.htm>

EDITORIAL OFFICE

Xiu-Xia Song, Director

World Journal of Gastrointestinal Surgery

Baishideng Publishing Group Inc
7901 Stoneridge Drive, Suite 501,
Pleasanton, CA 94588, USA
Telephone: +1-925-2238242
Fax: +1-925-2238243
E-mail: editorialoffice@wjgnet.com
Help Desk: <http://www.f6publishing.com/helpdesk>
<http://www.wjgnet.com>

PUBLISHER

Baishideng Publishing Group Inc
7901 Stoneridge Drive, Suite 501,
Pleasanton, CA 94588, USA
Telephone: +1-925-2238242
Fax: +1-925-2238243
E-mail: bpgoffice@wjgnet.com
Help Desk: <http://www.f6publishing.com/helpdesk>
<http://www.wjgnet.com>

PUBLICATION DATE

August 27, 2017

COPYRIGHT

© 2017 Baishideng Publishing Group Inc. Articles published by this Open-Access journal are distributed under the terms of the Creative Commons Attribution Non-commercial License, which permits use, distribution, and reproduction in any medium, provided the original work is properly cited, the use is non commercial and is otherwise in compliance with the license.

SPECIAL STATEMENT

All articles published in journals owned by the Baishideng Publishing Group (BPG) represent the views and opinions of their authors, and not the views, opinions or policies of the BPG, except where otherwise explicitly indicated.

INSTRUCTIONS TO AUTHORS

<http://www.wjgnet.com/bpg/gerinfo/204>

ONLINE SUBMISSION

<http://www.f6publishing.com>

Novel technique of abdominal wall nerve block for laparoscopic colostomy: Rectus sheath block with transperitoneal approach

Jun Nagata, Jun Watanabe, Yusuke Sawatsubashi, Masaki Akiyama, Koichi Arase, Noritaka Minagawa, Takayuki Torigoe, Kotaro Hamada, Yoshifumi Nakayama, Keiji Hirata

Jun Nagata, Yusuke Sawatsubashi, Masaki Akiyama, Yoshifumi Nakayama, Department of Gastroenterological and General Surgery, Wakamatsu Hospital, University of Occupational and Environmental Health, Fukuoka 808-0024, Japan

Jun Watanabe, Department of Surgery, Yokosuka Kyosai Hospital, Kanagawa 238-0011, Japan

Koichi Arase, Noritaka Minagawa, Takayuki Torigoe, Keiji Hirata, Department of Surgery, University of Occupational and Environmental Health, Fukuoka 808-0024, Japan

Kotaro Hamada, Department of Anesthesiology, Wakamatsu Hospital, University of Occupational and Environmental Health, Fukuoka 808-0024, Japan

Institutional review board statement: This case report was exempt from Institutional Review Board standards at University of Occupational and Environmental Health.

Informed consent statement: The patient involved in this manuscript gave his written informed consent authorizing use and disclosure of his protected health information.

Conflict-of-interest statement: All the authors have no conflict of interests to declare.

Open-Access: This article is an open-access article which was selected by an in-house editor and fully peer-reviewed by external reviewers. It is distributed in accordance with the Creative Commons Attribution Non Commercial (CC BY-NC 4.0) license, which permits others to distribute, remix, adapt, build upon this work non-commercially, and license their derivative works on different terms, provided the original work is properly cited and the use is non-commercial. See: <http://creativecommons.org/licenses/by-nc/4.0/>

Manuscript source: Unsolicited manuscript

Correspondence to: Jun Nagata, MD, PhD, Department of Gastroenterological and General Surgery, Wakamatsu Hospital,

University of Occupational and Environmental Health, 1-17-1 Hamamachi, Wakamatsu-ku, Kitakyushu, Fukuoka 808-0024, Japan. jungy@gmail.com
Telephone: +81-93-7610090
Fax: +81-93-5883904

Received: November 29, 2016

Peer-review started: November 29, 2016

First decision: February 20, 2017

Revised: March 20, 2017

Accepted: April 23, 2017

Article in press: April 24, 2017

Published online: August 27, 2017

Abstract

A 62-year-old man who had acute rectal obstruction due to a large rectal cancer is presented. He underwent emergency laparoscopic colostomy. We used the laparoscopic puncture needle to inject analgesia with the novel transperitoneal approach. In this procedure, both ultrasound and laparoscopic images assisted with the accurate injection of analgesic to the correct layer. The combination of laparoscopic visualization and ultrasound imaging ensured infiltration of analgesic into the correct layer without causing damage to the bowel. Twenty-four hours postoperatively, the patient's pain intensity as assessed by the numeric rating scale was 0-1 during coughing, and a continuous intravenous analgesic was not needed. Colostomy is often necessary in colon obstruction. Epidural anesthesia for postoperative pain cannot be used in patients with a coagulation disorder. We report the use of a novel laparoscopic rectus sheath block for colostomy. There has been no literature described about the nerve block with transperitoneal approach. The laparoscopic rectus sheath block was performed safely and had enough analgesic efficacy for postoperative pain. This technique

could be considered as an optional anesthetic regimen in acute situations.

Key words: Colorectal cancer; Rectus sheath block; Colon obstruction; Postoperative pain

© **The Author(s) 2017.** Published by Baishideng Publishing Group Inc. All rights reserved.

Core tip: This report demonstrated that transperitoneal rectal sheath block can be performed safely in achieving analgesia in patients undergoing laparoscopic colostomy. This transperitoneal rectal sheath block technique has the potential to become an additional postoperative regimen for various forms of laparoscopic abdominal surgery.

Nagata J, Watanabe J, Sawatsubashi Y, Akiyama M, Arase K, Minagawa N, Torigoe T, Hamada K, Nakayama Y, Hirata K. Novel technique of abdominal wall nerve block for laparoscopic colostomy: Rectus sheath block with transperitoneal approach. *World J Gastrointest Surg* 2017; 9(8): 182-185 Available from: URL: <http://www.wjgnet.com/1948-9366/full/v9/i8/182.htm> DOI: <http://dx.doi.org/10.4240/wjgs.v9.i8.182>

INTRODUCTION

Colostomy is often necessary in acute colon obstruction. The indications for laparoscopic colostomy for large bowel obstruction caused by benign colorectal disease have been described previously^[1]. The laparoscopic approach is associated with a significant reduction in postoperative pain, faster recovery, and shorter hospital day compared with open surgery^[2]. However, there is still considerable postoperative pain associated with the laparoscopic procedure as a result of the transabdominal sutures, even in the small incisions.

Strategies for analgesia after laparoscopic colostomy are based on the concepts for the open procedure; epidural analgesia is the standard technique. However, epidural use is sometimes limited because of perioperative anticoagulant therapy and the potential for undesirable complications such as epidural hematomas and infections. Therefore, recently published guidelines from the United Kingdom no longer recommend epidural analgesia as standard pain management after laparoscopic colorectal surgery^[3]. Furthermore, patients with acute colorectal obstruction often have a coagulation disorder and higher risks. For patients with obstruction, especially in emergency cases, regional anesthetic techniques such as the ultrasound-guided rectus sheath (RS) block have become increasingly popular as methods to provide analgesia for laparoscopic surgery. The RS block has gained popularity owing to a relatively high success rate^[4]. However, even the RS block has potential complications such as RS hematoma if the vessels are damaged, and it is possible to puncture the posterior RS, peritoneum, and/or bowel. In this report, we describe

a novel laparoscopic transperitoneal approach and assess its efficacy. This is the first report of laparoscopic colostomy using the transperitoneal approach for the RS block.

CASE REPORT

After approval by the Research Ethics Board of our institution and the patient's informed consent. A 62-year-old man with acute rectal obstruction due to a large rectal cancer underwent laparoscopic colostomy. The procedure was performed as an emergency operation, with the patient placed under general anesthesia with 8% sevoflurane *via* a face mask. Epidural anesthesia was not performed, as the patient had a coagulation disorder.

Laparoscopic colostomy was conducted *via* two incisions; the first incision was made *via* the stoma site (25 mm), and a second navel incision (5 mm) was made. After making the skin incisions, pneumoperitoneum was created with the pressure standardized to 10 mmHg. Intraoperatively, under laparoscopic visualization, a bilateral transperitoneal RS block was performed with ultrasound guidance to reduce unexpected abdominal wall pain. Ultrasound was performed with a linear array probe, 13-6 MHz, SonoSite M-Turbo™ (SonoSite Inc., Bothell, WA, United States). The probe was placed longitudinally on the patient's abdominal wall while the tip of a Peti-needle™ (Hakko Co., Ltd., Adachi-ku, Tokyo, Japan) was inserted through the peritoneum under laparoscopic visualization. A Peti-needle™ was inserted through the 5-mm port at the stoma site, and 20 mL of 0.25% levobupivacaine was injected through the peritoneum (Figure 1): Posterior to the rectus muscle and above the underlying RS block. Infiltration into the correct layer without leakage was checked by both laparoscopic visualization and ultrasound (Figure 2). The technique was repeated on the other site. Surgery was completed successfully and the anesthetic procedure did not affect the operation.

Postoperatively, the patient was brought to the post-anesthesia care unit for continuous monitoring of vital signs. Nurses administered intravenous analgesic as needed. Pain severity was assessed at rest and during coughing using a numeric rating scale (NRS), where no pain = 0, and the worst pain = 10. Three hours postoperatively, the patient's pain intensity as assessed by the NRS was 3 at rest and 4 during coughing. Twenty-four hours postoperatively, the patient's NRS pain intensity was 0-1 during coughing, and an intravenous analgesic was no longer needed. There were no other postoperative problems such as hematoma or severe infection in the muscle.

DISCUSSION

The RS block is a regional anesthetic procedure that was first reported in 1899^[5]. It has been used in the treatment of pediatric chronic abdominal wall pain^[6].

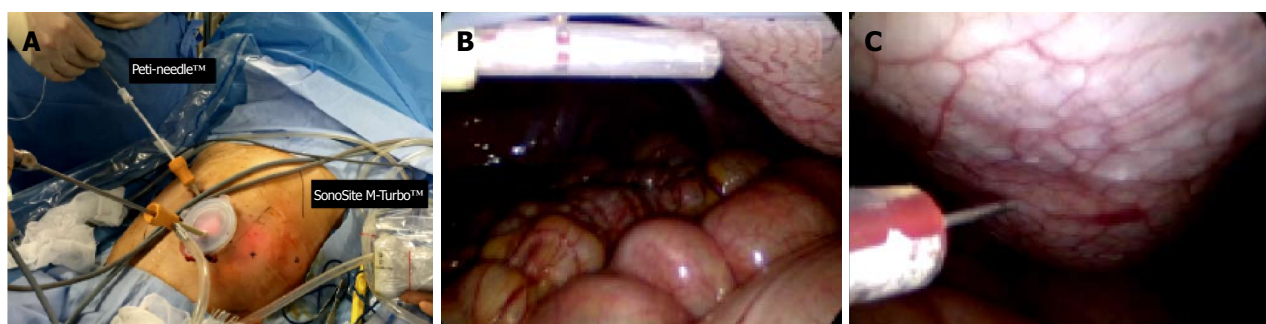

Figure 1 Intraoperative photographs. A: The Peti-needle™ inserted via the naval port (5 mm); B: Delivered to the peritoneum; C: The anesthetic agent was then injected through the Peti-needle™ by the transperitoneal approach under laparoscopic visualization.

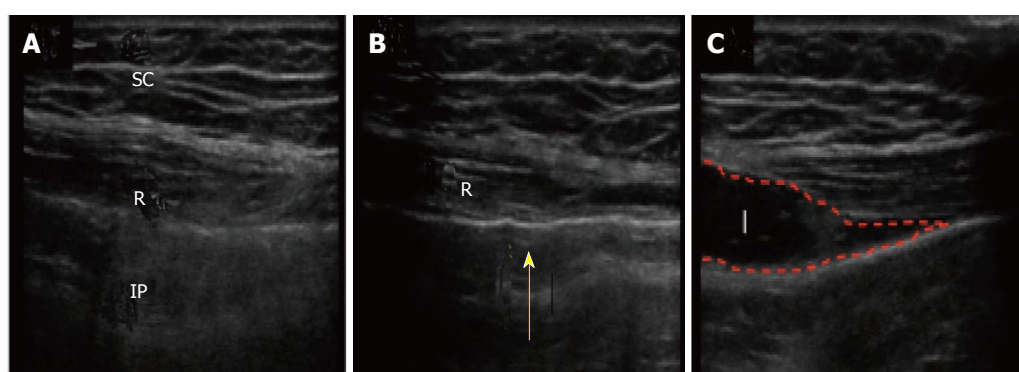


Figure 2 Ultrasound images. A: The muscle layers; B: The Peti-needle™ positioned below the peritoneum, the notch was made by the needle tip (yellow arrow) before the needle was inserted via the peritoneum; C: Local analgesic was then administered into the correct layer. R: Rectus muscle; IP: Intraperitoneal space; SC: Subcutaneous tissue; I: Injectate.

Any regional technique carries a risk of introducing infection, causing bleeding, or damaging local structures^[7]. Proposed benefits of these regional blocks include the avoidance of neuroaxial techniques such as epidural analgesia and their associated risks, as well as a reported reduction in opioid consumption^[8-10].

Laparoscopic-assisted transversus abdominis plane block has been performed for ventral hernia repair^[11] and cholecystectomy^[12]; however, this procedure was done only with ultrasound guidance, and the needle was inserted transcutaneously. Using the transperitoneal approach *via* laparoscopy and ultrasound guidance, the RS block has been demonstrated to be simpler and safer.

RS block *via* the transperitoneal approach in laparoscopic colostomy provided effective and safe postoperative analgesia in a patient with acute colon obstruction. When compared with the open procedure, laparoscopic colostomy itself carries several advantages including early postoperative recovery, less postoperative pain, and rapid restoration of bowel function^[13]. A laparoscopic RS block can be performed by the operating surgeon without perforation of the bowel. This procedure could be performed in high-risk patients who have a coagulation disorder, and also in highly obese patients. Currently, there are no published trials examining the role of the laparoscopically performed RS block *via* the transperitoneal approach for the management of

perioperative pain in laparoscopic abdominal surgery. In the present case, the procedure was performed safely and the transperitoneal RS block provided the effective analgesia in abdominal surgery.

Although the RS block, known as a compartment block, is thought to require a large amount of local anesthetic to provide an analgesic effect, our result showed that it was possible to produce sufficient analgesia with a small dosage of local anesthetic with ultrasonic and laparoscopic visualization. The RS block has no hemodynamic effects, and is ideal for patients with hypotension related to sepsis or hypovolemia. Unlike epidurals and continuous intravenous analgesia, the RS block does not require connection to pumps and stands, thereby enabling early patient mobilization. Our novel analgesia technique has potential use as a regimen for postoperative pain of various laparoscopic surgeries. This study had a limitation; the Peti-needle™ costs twice as much as the needle used for the percutaneous approach. Additional prospective studies are required to evaluate the benefits of laparoscopic transperitoneal RS block in other techniques such as local anesthetic wound infiltration, patient-controlled intravenous opioid administration, and the percutaneous approach.

ACKNOWLEDGMENTS

The authors thank Dr. Reiko Horishita and Dr. Kentaro

Kida for their technical assistance. And all the authors declare that there are no conflict of interest.

COMMENTS

Case characteristics

A 62-year-old man who had huge rectal cancer underwent laparoscopic colostomy and a novel nerve block with transperitoneal injection of analgesia.

Clinical diagnosis

A huge rectal tumor of his pelvic space occurred acute colon obstruction.

Differential diagnosis

Gastrointestinal tumor, neuroendocrine tumor.

Laboratory diagnosis

Only carcino-embryonic antigen was arized, other labs were within normal limits.

Imaging diagnosis

A huge rectal tumor of his pelvic space occurred acute colon obstruction.

Pathological diagnosis

Moderately differentiated adenocarcinoma.

Peer-review

This is a case report that is describing a novel rectus sheath block technique for laparoscopic colostomy in an adult. However, the authors would like to point out the following. Generally, the manuscript is good written.

REFERENCES

- 1 **Panis Y.** [Laparoscopic surgery for benign colorectal diseases]. *J Chir (Paris)* 2000; **137**: 261-267 [PMID: 11033484 DOI: 10.1055/s-0030-1247857]
- 2 **Joshi GP, Bonnet F, Kehlet H.** Evidence-based postoperative pain management after laparoscopic colorectal surgery. *Colorectal Dis* 2012; **15**: 146-155 [DOI: 10.1111/j.1463-1318.2012.03062.x]
- 3 **Gustafsson UO, Scott MJ, Schwenk W, Demartines N, Roulin D, Francis N, McNaught CE, Macfie J, Liberman AS, Soop M, Hill A, Kennedy RH, Lobo DN, Fearon K, Ljungqvist O;** Enhanced Recovery After Surgery (ERAS) Society, for Perioperative Care; European Society for Clinical Nutrition and Metabolism (ESPEN); International Association for Surgical Metabolism and Nutrition (IASMEN). Guidelines for perioperative care in elective colonic surgery: Enhanced Recovery After Surgery (ERAS®) Society recommendations. *World J Surg* 2013; **37**: 259-284 [PMID: 23052794 DOI: 10.1007/s00268-012-1772-0]
- 4 **Sites BD, Brull R.** Ultrasound guidance in peripheral regional anesthesia: philosophy, evidence-based medicine, and techniques. *Curr Opin Anaesthesiol* 2006; **19**: 630-639 [PMID: 17093367 DOI: 10.1097/ACO.0b013e3280101423]
- 5 **Schleich DL.** Schmerzlose operation. 4th ed. Berlin: Springer Verlag, 1899: 240-258
- 6 **Skinner AV, Lauder GR.** Rectus sheath block: successful use in the chronic pain management of pediatric abdominal wall pain. *Paediatr Anaesth* 2007; **17**: 1203-1211 [PMID: 17986041 DOI: 10.1111/j.1460-9592.2007.02345.x]
- 7 **Lancaster P, Chadwick M.** Liver trauma secondary to ultrasound-guided transversus abdominis plane block. *Br J Anaesth* 2010; **104**: 509-510 [PMID: 20228188 DOI: 10.1093/bja/aeq046]
- 8 **Johns N, O'Neill S, Ventham NT, Barron F, Brady RR, Daniel T.** Clinical effectiveness of transversus abdominis plane (TAP) block in abdominal surgery: a systematic review and meta-analysis. *Colorectal Dis* 2012; **14**: e635-e642 [PMID: 22632762 DOI: 10.1111/j.1463-1318.2012.03104.x]
- 9 **Gupta M, Naithani U, Singariya G, Gupta S.** Comparison of 0.25% Ropivacaine for Intraperitoneal Instillation v/s Rectus Sheath Block for Postoperative Pain Relief Following Laparoscopic Cholecystectomy: A Prospective Study. *J Clin Diagn Res* 2016; **10**: UC10-UC15 [PMID: 27656533 DOI: 10.7860/JCDR/2016/18845.8309]
- 10 **Uchinami Y, Sakuraya F, Tanaka N, Hoshino K, Mikami E, Ishikawa T, Fujii H, Ishikawa T, Morimoto Y.** Comparison of the analgesic efficacy of ultrasound-guided rectus sheath block and local anesthetic infiltration for laparoscopic percutaneous extraperitoneal closure in children. *Paediatr Anaesth* 2017; **27**: 516-523 [PMID: 28198572 DOI: 10.1111/pan.13085]
- 11 **Fields AC, Gonzalez DO, Chin EH, Nguyen SQ, Zhang LP, Divino CM.** Laparoscopic-Assisted Transversus Abdominis Plane Block for Postoperative Pain Control in Laparoscopic Ventral Hernia Repair: A Randomized Controlled Trial. *J Am Coll Surg* 2015; **221**: 462-469 [PMID: 26206644 DOI: 10.1016/j.jamcollsurg.2015.04.007]
- 12 **Elamin G, Waters PS, Hamid H, O'Keeffe HM, Waldron RM, Duggan M, Khan W, Barry MK, Khan IZ.** Efficacy of a Laparoscopically Delivered Transversus Abdominis Plane Block Technique during Elective Laparoscopic Cholecystectomy: A Prospective, Double-Blind Randomized Trial. *J Am Coll Surg* 2015; **221**: 335-344 [PMID: 25899736 DOI: 10.1016/j.jamcollsurg.2015.03.030]
- 13 **Shah A, Moftah M, Al-Furaji HN, Cahill RA.** Standardized technique for single port laparoscopic ileostomy and colostomy. *Colorectal Dis* 2014; **16**: 248-252 [DOI: 10.1111/codi.12601]

P- Reviewer: Tang ST, Uygun I **S- Editor:** Qi Y **L- Editor:** A
E- Editor: Lu YJ





Published by **Baishideng Publishing Group Inc**
7901 Stoneridge Drive, Suite 501, Pleasanton, CA 94588, USA
Telephone: +1-925-223-8242
Fax: +1-925-223-8243
E-mail: bpgoffice@wjgnet.com
Help Desk: <http://www.f6publishing.com/helpdesk>
<http://www.wjgnet.com>

