

World Journal of *Gastroenterology*

World J Gastroenterol 2017 June 14; 23(22): 3945-4134



**EDITORIAL**

- 3945** Bleeding with the artificial heart: Gastrointestinal hemorrhage in CF-LVAD patients

Gurvits GE, Fradkov E

REVIEW

- 3954** Role of non-steroidal anti-inflammatory drugs on intestinal permeability and nonalcoholic fatty liver disease

Utzeri E, Usai P

- 3964** Molecular mimicry in *Helicobacter pylori* infections

Chmiela M, Gonciarz W

- 3978** Gallbladder cancer epidemiology, pathogenesis and molecular genetics: Recent update

Sharma A, Sharma KL, Gupta A, Yadav A, Kumar A

ORIGINAL ARTICLE**Basic Study**

- 3999** Serelaxin increases the antifibrotic action of rosiglitazone in a model of hepatic fibrosis

Bennett RG, Simpson RL, Hamel FG

- 4007** Bcl-2 degradation is an additional pro-apoptotic effect of polo-like kinase inhibition in cholangiocarcinoma cells

Sydor S, Jafoui S, Wingerter L, Swoboda S, Mertens JC, Gerken G, Canbay A, Paul A, Fingas CD

- 4016** Effect of *CXCR3/HO-1* genes modified bone marrow mesenchymal stem cells on small bowel transplant rejection

Yin ML, Song HL, Yang Y, Zheng WP, Liu T, Shen ZY

Case Control Study

- 4039** Systemic interleukin-9 in inflammatory bowel disease: Association with mucosal healing in ulcerative colitis

Matusiewicz M, Neubauer K, Bednars-Misa I, Gorska S, Krzystek-Korpacka M

- 4047** Association of keratin 8/18 variants with non-alcoholic fatty liver disease and insulin resistance in Chinese patients: A case-control study

Li R, Liao XH, Ye JZ, Li MR, Wu YQ, Hu X, Zhong BH

Retrospective Study

- 4054** Barcelona Clinic Liver Cancer outperforms Hong Kong Liver Cancer staging of hepatocellular carcinoma in multiethnic Asians: Real-world perspective

Li JW, Goh BBG, Chang PE, Tan CK

Observational Study

- 4064** Single-operator cholangioscopy for biliary complications in liver transplant recipients

Hüsing-Kabar A, Heinzow HS, Schmidt HHJ, Stenger C, Gerth HU, Pohlen M, Thölking G, Wilms C, Kabar I

- 4072** Efficacy and safety of combined directly acting antivirals for treatment of Chinese chronic hepatitis C patients in a real-world setting

Chen JH, Zeng Z, Zhang XX, Zhang Y, Zhang RW, Wang S, Wu CH, Yu M, Liu D, Xi HL, Zhou YX, An YY, Xu XY

- 4080** Observation of the effect of targeted therapy of 64-slice spiral CT combined with cryoablation for liver cancer

Yan QH, Xu DG, Shen YF, Yuan DL, Bao JH, Li HB, Lv YG

Prospective Study

- 4090** Inflammatory bowel disease incidence in Czech children: A regional prospective study, 2000-2015

Schwarz J, Šýkora J, Cvalínová D, Pomahačová R, Klečková J, Kryl M, Včelák P

- 4102** Drug-induced liver injury in inflammatory bowel disease: 1-year prospective observational study

Koller T, Galambosova M, Filakovska S, Kubincova M, Hlavaty T, Toth J, Krajcovicova A, Payer J

SYSTEMATIC REVIEWS

- 4112** Can fecal microbiota transplantation cure irritable bowel syndrome?

Halkjær SI, Boelsen AW, Günther S, Christensen AH, Petersen AM

CASE REPORT

- 4121** Application of novel magnified single balloon enteroscopy for a patient with Cronkhite-Canada syndrome

Murata M, Bamba S, Takahashi K, Imaeda H, Nishida A, Inatomi O, Tsujikawa T, Kushima R, Sugimoto M, Andoh A

- 4127** Synchronous triple occurrence of MALT lymphoma, schwannoma, and adenocarcinoma of the stomach

Choi KW, Joo M, Kim HS, Lee WY

LETTERS TO THE EDITOR

- 4132** Is tremor related to celiac disease?

Ameghino L, Rossi MD, Cerquetti D, Merello M

Contents

World Journal of Gastroenterology
Volume 23 Number 22 June 14, 2017

ABOUT COVER

Editorial board member of *World Journal of Gastroenterology*, Jun-Te Hsu, MD, Associate Professor, Surgeon, Surgical Oncologist, Department of Surgery, Chang Gung Memorial Hospital, Taoyuan County and Chang Gung Medicine College, Tao Yuan 333, Taiwan

AIMS AND SCOPE

World Journal of Gastroenterology (*World J Gastroenterol*, *WJG*, print ISSN 1007-9327, online ISSN 2219-2840, DOI: 10.3748) is a peer-reviewed open access journal. *WJG* was established on October 1, 1995. It is published weekly on the 7th, 14th, 21st, and 28th each month. The *WJG* Editorial Board consists of 1375 experts in gastroenterology and hepatology from 68 countries.

The primary task of *WJG* is to rapidly publish high-quality original articles, reviews, and commentaries in the fields of gastroenterology, hepatology, gastrointestinal endoscopy, gastrointestinal surgery, hepatobiliary surgery, gastrointestinal oncology, gastrointestinal radiation oncology, gastrointestinal imaging, gastrointestinal interventional therapy, gastrointestinal infectious diseases, gastrointestinal pharmacology, gastrointestinal pathophysiology, gastrointestinal pathology, evidence-based medicine in gastroenterology, pancreatology, gastrointestinal laboratory medicine, gastrointestinal molecular biology, gastrointestinal immunology, gastrointestinal microbiology, gastrointestinal genetics, gastrointestinal translational medicine, gastrointestinal diagnostics, and gastrointestinal therapeutics. *WJG* is dedicated to become an influential and prestigious journal in gastroenterology and hepatology, to promote the development of above disciplines, and to improve the diagnostic and therapeutic skill and expertise of clinicians.

INDEXING/ABSTRACTING

World Journal of Gastroenterology (*WJG*) is now indexed in Current Contents[®]/Clinical Medicine, Science Citation Index Expanded (also known as SciSearch[®]), Journal Citation Reports[®], Index Medicus, MEDLINE, PubMed, PubMed Central, Digital Object Identifier, and Directory of Open Access Journals. The 2015 edition of Journal Citation Reports[®] released by Thomson Reuters (ISI) cites the 2015 impact factor for *WJG* as 2.787 (5-year impact factor: 2.848), ranking *WJG* as 38 among 78 journals in gastroenterology and hepatology (quartile in category Q2).

FLYLEAF

I-IX Editorial Board

EDITORS FOR THIS ISSUE

Responsible Assistant Editor: *Xiang Li*
Responsible Electronic Editor: *Cai-Hong Wang*
Proofing Editor-in-Chief: *Lian-Sheng Ma*

Responsible Science Editor: *Yuan Qi*
Proofing Editorial Office Director: *Jin-Lei Wang*

NAME OF JOURNAL
World Journal of Gastroenterology

ISSN
ISSN 1007-9327 (print)
ISSN 2219-2840 (online)

LAUNCH DATE
October 1, 1995

FREQUENCY
Weekly

EDITORS-IN-CHIEF
Damian Garcia-Olmo, MD, PhD, Doctor, Professor, Surgeon, Department of Surgery, Universidad Autonoma de Madrid; Department of General Surgery, Fundacion Jimenez Diaz University Hospital, Madrid 28040, Spain

Stephen C Strom, PhD, Professor, Department of Laboratory Medicine, Division of Pathology, Karolinska Institutet, Stockholm 141-86, Sweden

Andrzej S Tarnawski, MD, PhD, DSc (Med), Professor of Medicine, Chief Gastroenterology, VA Long Beach Health Care System, University of California, Irvine, CA, 5901 E. Seventh Str., Long Beach,

CA 90822, United States

EDITORIAL BOARD MEMBERS
All editorial board members resources online at <http://www.wjgnet.com/1007-9327/editorialboard.htm>

EDITORIAL OFFICE
Jin-Lei Wang, Director
Yuan Qi, Vice Director
Ze-Mao Gong, Vice Director
World Journal of Gastroenterology
Baishideng Publishing Group Inc
7901 Stoneridge Drive, Suite 501,
Pleasanton, CA 94588, USA
Telephone: +1-925-2238242
Fax: +1-925-2238243
E-mail: editorialoffice@wjgnet.com
Help Desk: <http://www.f6publishing.com/helpdesk>
<http://www.wjgnet.com>

PUBLISHER
Baishideng Publishing Group Inc
7901 Stoneridge Drive, Suite 501,
Pleasanton, CA 94588, USA
Telephone: +1-925-2238242
Fax: +1-925-2238243
E-mail: bpgoffice@wjgnet.com
Help Desk: <http://www.f6publishing.com/helpdesk>

<http://www.wjgnet.com>

PUBLICATION DATE
June 14, 2017

COPYRIGHT
© 2017 Baishideng Publishing Group Inc. Articles published by this Open-Access journal are distributed under the terms of the Creative Commons Attribution Non-commercial License, which permits use, distribution, and reproduction in any medium, provided the original work is properly cited, the use is non commercial and is otherwise in compliance with the license.

SPECIAL STATEMENT
All articles published in journals owned by the Baishideng Publishing Group (BPG) represent the views and opinions of their authors, and not the views, opinions or policies of the BPG, except where otherwise explicitly indicated.

INSTRUCTIONS TO AUTHORS
Full instructions are available online at <http://www.wjgnet.com/bpg/gerinfo/204>

ONLINE SUBMISSION
<http://www.f6publishing.com>

Observational Study

Observation of the effect of targeted therapy of 64-slice spiral CT combined with cryoablation for liver cancer

Qiao-Huan Yan, Dian-Guo Xu, Yan-Feng Shen, Ding-Ling Yuan, Jun-Hui Bao, Hai-Bin Li, Ying-Gang Lv

Qiao-Huan Yan, Department of Geriatrics, the First Hospital of Handan, Handan 056001, Hebei Province, China

Dian-Guo Xu, Department of Anatomy, Medical College of Hebei University of Engineering, Handan 056001, Hebei Province, China

Yan-Feng Shen, Hai-Bin Li, Department of Oncology, Affiliated Hospital of Hebei University of Engineering, Handan 056001, Hebei Province, China

Ding-Ling Yuan, Jun-Hui Bao, Ying-Gang Lv, Department of Imaging, Affiliated Hospital of Hebei Medical University, Shijiazhuang 056002, Hebei Province, China

Ying-Gang Lv, Department of Radiology, Affiliated Hospital of Hebei University of Engineering, Handan 056001, Hebei Province, China

Author contributions: Yan QH and Lv YG contributed equally to this work; Yan QH, Xu DG, Shen YF, Yuan DL, Bao JH, Li HB and Lv YG designed research; Yan QH, Yuan DL, Bao JH, Li HB and Lv YG performed research; Yan QH, Xu DG, Shen YF, Li HB and Lv YG contributed new reagents/analytic tools; Yan QH, Xu DG, Shen YF and Lv YG analyzed data; and Yan QH and Lv YG wrote the paper.

Supported by Hebei Province Health Department of Scientific Research Fund Project, No. 20110157.

Institutional review board statement: The study was reviewed and approved by the Affiliated Hospital of Hebei University of Engineering Institutional Review Board.

Informed consent statement: All study participants, or their legal guardian, provided informed written consent prior to study enrollment.

Conflict-of-interest statement: The authors have no conflict of interest related to the manuscript.

Data sharing statement: No additional data are available.

Open-Access: This article is an open-access article which was

selected by an in-house editor and fully peer-reviewed by external reviewers. It is distributed in accordance with the Creative Commons Attribution Non Commercial (CC BY-NC 4.0) license, which permits others to distribute, remix, adapt, build upon this work non-commercially, and license their derivative works on different terms, provided the original work is properly cited and the use is non-commercial. See: <http://creativecommons.org/licenses/by-nc/4.0/>

Manuscript source: Unsolicited manuscript

Correspondence to: Ying-Gang Lv, Deputy Chief Physician, Department of Radiology, Affiliated Hospital of Hebei University of Engineering, Jianshe Street No. 80, Fuxing District, Handan 056001, Hebei Province, China. lvyinggang@126.com

Telephone: +86-310-8577555

Fax: +86-310-8577555

Received: December 10, 2016

Peer-review started: December 12, 2016

First decision: December 29, 2016

Revised: February 15, 2017

Accepted: March 4, 2017

Article in press: March 4, 2017

Published online: June 14, 2017

Abstract

AIM

To observe the effect of targeted therapy with 64-slice spiral computed tomography (CT) combined with cryoablation for liver cancer.

METHODS

A total of 124 patients (142 tumors) were enrolled into this study. According to the use of dual-slice spiral CT or 64-slice spiral CT as a guide technology, patients were divided into two groups: dual-slice group ($n = 56$, 65 tumors) and 64-slice group ($n = 8$, 77 tumors). All patients were accepted and received targeted

therapy by an argon-helium superconducting surgery system. The guided scan times of the two groups was recorded and compared. In the two groups, the lesion ice coverage in diameter of ≥ 3 cm and < 3 cm were recorded, and freezing effective rate was compared. Hepatic perfusion values [hepatic artery perfusion (HAP), portal vein perfusion (PVP), and the hepatic arterial perfusion index (HAPI)] of tumor tissues, adjacent tissues and normal liver tissues at preoperative and postoperative four weeks in the two groups were compared. Local tumor changes were recorded and efficiency was compared at four weeks post-operation. Adverse events were recorded and compared between the two groups, including fever, pain, frostbite, nausea, vomiting, pleural effusion and abdominal bleeding.

RESULTS

Guided scan times in the dual-slice group was longer than that in the 64-slice group ($t = 11.445$, $P = 0.000$). The freezing effective rate for tumors < 3 cm in diameter in the dual-slice group (81.58%) was lower than that in the 64-slice group (92.86%) ($\chi^2 = 5.707$, $P = 0.017$). The HAP and HAPI of tumor tissues were lower at four weeks post-treatment than at pre-treatment in both groups (all $P < 0.05$), and those in the 64-slice group were lower than that in the dual-slice group (all $P < 0.05$). HAP and PVP were lower and HAPI was higher in tumor adjacent tissues at post-treatment than at pre-treatment (all $P < 0.05$). Furthermore, the treatment effect and therapeutic efficacy in the dual-slice group were lower than the 64-slice group at four weeks post-treatment (all $P < 0.05$). Moreover, pleural effusion and intraperitoneal hemorrhage occurred in patients in the dual-slice group, while no complications occurred in the 64-slice group (all $P < 0.05$).

CONCLUSION

64-slice spiral CT applied with cryoablation in targeted therapy for liver cancer can achieve a safe and effective freezing treatment, so it is worth being used.

Key words: 64-slice spiral computed tomography; Cryoablation; Liver cancer

© The Author(s) 2017. Published by Baishideng Publishing Group Inc. All rights reserved.

Core tip: One hundred and twenty-four patients with liver cancer were accepted therapy by argon-helium superconducting surgery system. Compared with 64-row group, guided scan times was longer and freezing effective rate for tumors < 3 cm was lower in the dual-slice group. Four weeks after treatment, compared with dual-slice group, the hepatic artery perfusion and hepatic arterial perfusion index of tumor tissues were lower, the treatment effect and therapeutic efficacy in the 64-row group were higher. Complications were higher in the double-row group than in the 64-row group. 64-slice spiral computed tomography applied with cryoablation in targeted

therapy for liver cancer can achieve a safe and effective freezing treatment.

Yan QH, Xu DG, Shen YF, Yuan DL, Bao JH, Li HB, Lv YG. Observation of the effect of targeted therapy of 64-slice spiral CT combined with cryoablation for liver cancer. *World J Gastroenterol* 2017; 23(22): 4080-4089 Available from: URL: <http://www.wjgnet.com/1007-9327/full/v23/i22/4080.htm> DOI: <http://dx.doi.org/10.3748/wjg.v23.i22.4080>

INTRODUCTION

The incidence of liver cancer in China accounts for third place malignant tumors, and there has been an increasing trend in its incidence in recent years^[1,2]. In clinical practice, the best treatment for early liver cancer is the surgical resection of lesions. However, early symptoms of liver cancer are not obvious. Therefore, most patients diagnosed with liver cancer already developed and their tumors cannot be surgically removed or have poor surgical outcomes, and miss the opportunity for conventional radical surgery^[3-6]. For patients with advanced tumors, if local treatment was available to delay the growth and spread of the tumor, it would help extend survival time and improve the quality of life of patients. With the development of minimally invasive treatments for tumors, these patients can be clinically given advanced cryoablation therapy at present^[7-10]. Cryoablation targeted treatment has features such as a precise curative effect, easy to operate, safe and effective. This has gradually become an important method of minimally invasive treatment for liver cancer. Furthermore, imaging technology has been combined with the application of cryoablation during the course of treatment to observe tumor position and size, develop a preoperative puncture path, and for postoperative evaluation, of which computed tomography (CT) is widely used^[11-14]. However, dual-slice spiral CT scanning technology has a long scan time and can't accurately position smaller tumors. As a guide during the cryosurgical treatment process, it may result in a smaller tumor omission. 64-slice spiral CT has a fast scanning speed and can provide clearer tumor positioning^[15]. In order to better understand the application of 64-slice spiral CT during cryoablation, this study compared and analyzed the dual-slice spiral CT and 64-slice spiral CT guided cryosurgery treatments performed for liver cancer patients in our hospital; provide a reference for the clinical application of 64-slice spiral CT guided cryoablation therapy.

MATERIALS AND METHODS

General information

A total of 124 patients with primary liver cancer, who were treated in our hospital from January 2014 to June

2016, were enrolled in this study. A total of 142 tumors were found from these patients. Among these patients, 83 patients were males and 41 patients were females; and the age of these patients ranged between 31-78 years, with a mean age of 54.5 ± 9.9 years. The diameter of the tumors ranged from 1.1 cm to 9.3 cm (6.3 ± 3.4 cm). In this study, the 124 patients were divided into two groups: dual-slice group and 64-slice group. Patients in the dual-slice group comprised of 56 patients (65 tumors) who underwent dual-slice spiral CT guided cryosurgery from January 2014 to March 2015. Among these patients, 38 were male and 18 were female, and the mean age of these patients was 52.4 ± 10.4 years. Furthermore, the tumor diameters ranged from 1.1 cm to 8.2 cm (6.2 ± 3.1 cm). Patients in the 64-slice group comprised 68 patients (77 tumors) who underwent 64-slice spiral CT guided cryosurgery from April 2015 to June 2016. Among these patients, 45 were male and 23 were female, and the mean age of these patients was 57.4 ± 9.5 years. Furthermore, the tumor diameters ranged from 1.3 to 9.3 cm (6.5 ± 3.6 cm). The difference in age, tumor diameter and other general information between these two groups of patients was not statistically significant ($P > 0.05$).

Inclusion criteria: (1) patients with pathological examination-confirmed primary liver cancer; (2) elderly patients with heart and lung function not suitable for open surgery; (3) patients with liver function Child-Pugh grade A or B; (4) patients without severe hepatocellular jaundice and had a large number of ascites; and (5) patients with no serious coagulation dysfunction. This study was approved by the hospital ethics committee. All patients voluntarily chose cryoablation therapy, understood its importance, and provided a signed informed consent.

Methods

In this study, 64-slice spiral CT guidance technology was Light Speed VCT; GE Company, United States, while the dual-slice spiral CT machine guidance instrument was Prospeed F-II; GE Company, United States. The two groups used the Magnetic Resonance-Compatible Cryotherapy System (Cryo-HIT) manufactured by Galileo, Israel. The surgical operations were performed by the same group of physicians. The patient's preoperative CT and other test results were used to determine the entry route, probe combined model and treatment range. Local anesthesia was performed on the puncture site after conventional disinfection, and intermittent CT scans were performed to observe the probe position and for timely adjustment. To determine the expected location of the needle on the tumor to start the ablation, first, the helium is frozen for 10-15 min. Then, re-warm the helium after three minutes. Repeat freezing and thaw once. Perform regular CT scans to detect iceball formation. Withdraw the frozen knife, hemostasis, and suture and bandaged up the

puncture site.

A full perfusion examination of the liver was performed on patients three days before cryoablation treatment and four weeks after surgery in the Radiation Department of our hospital using Light Speed VCT (GE Company, United States). Preoperative preparation of CT perfusion include prothrombin time, blood biochemistry and other routine preoperative examinations, fasting for 4-6 h, and drinking 1000 mL of warm water 10-15 min before examination. An 18G standard intravenous catheter was placed at the right arm elbow anterior vein. The patient was encapsulated with an abdominal bandage and given breathing exercises, which were mainly chest breathing, supplemented by abdominal breathing. Precautions during the examination were explained to the patient.

Patients were placed in the supine foot first scan position. Before perfusion, patients were first given a routine abdominal plain scan to observe the liver and location of lesions, as well as the extent of the disease. Then, a dynamic volume scan was performed. Next, 40 mL of non-ion contrast agent iohexol and 30 mL of physiological saline (rate 5 mL/s) was administered through the intravenous indwelling needle in front of the elbow using a double-barreled high-pressure syringe. Then, the injection of the contrast agent was performed after eight seconds. The liver perfusion imaging picture obtained through the body perfusion software used dual input mode for analysis. Furthermore, hepatic artery perfusion (HAP), portal vein perfusion (PVP), and the hepatic arterial perfusion index (HAPI) perfusion parameter pseudo-color images were also obtained. Three region of interest (ROI) parameters of perfusion in the axial position, in the coronal and sagittal positions were randomly selected. Notice that the preoperative and postoperative selection of the region should be consistent, and mean values were calculated for the tumor, adjacent tumor and normal liver tissues. After four weeks, liver perfusion examination was carried out and an enhanced scan was performed, enhancement of the lesion was observed, and the local ablation of the tumor was evaluated.

Observation index

CT-guided scan times were recorded and compared between the two groups of patients. Furthermore, the postoperative ice coverage range of ≥ 3 cm and < 3 cm diameter tumors in the two groups were recorded. Then, the freezing effective rate was compared between the two groups. The liver perfusion values of tumor tissues, adjacent tumor tissues, and normal liver tissues between the two groups at preoperative and four weeks after cryoablation treatment were compared. Four weeks after surgery, local changes in the tumor were observed. The treatment was divided as follows: (1) complete ablation, complete necrosis of

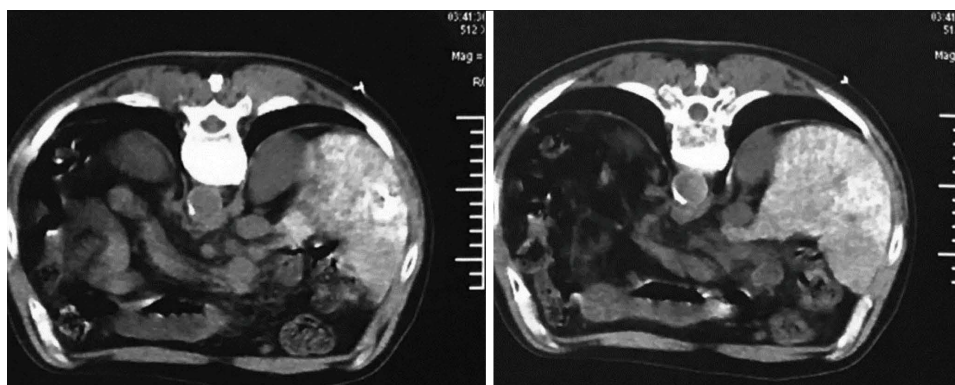


Figure 1 Before cryoablation, patients were placed in the prone position. Liver cancer chemoembolization after interventional therapy is shown, the lipiodol deposition area was the lesion tissue.

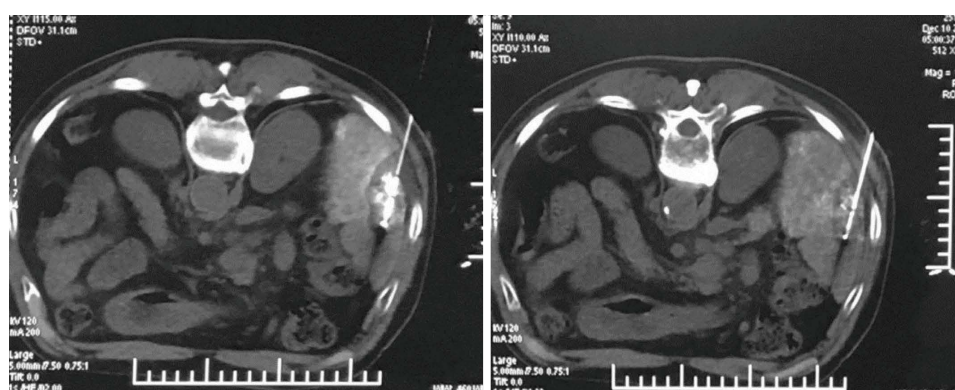


Figure 2 During cryoablation therapy, patients were placed in the prone position. The needle was placed to the right side of the abdominal wall and the puncture needle was positioned to the lesion bottom wall. The effective freezing area covered the lesions.

tumor tissues; (2) mostly ablated: lesion necrosis was $> 80\%$; (3) stable: tumor necrosis was $> 50\%$; and (4) progressive: increased mass or the emergence of newborn foci. The effective rate of the two groups was compared (complete ablation and major ablation). The clinical situation of these patients was closely observed. The following adverse reactions were recorded and compared between the two groups: fever, pain, skin frostbite, nausea, vomiting, pleural effusion, and abdominal bleeding.

Statistical analysis

The data were analyzed using SPSS 17.0 software. Scanning time, hepatic perfusion (HAP, PVP and HAPI), and other measurement data were expressed as mean \pm SD. *t*-test was used to compare the differences between the two groups. The freeze effective rate, effective rate of treatment after four weeks and the incidence of various adverse reactions that occurred and other count data were compared using the χ^2 -test between the two groups. The local therapeutic effects between the two groups were compared using the Mann-Whitney rank sum test. $P < 0.05$ was considered statistically significant.

RESULTS

Freezing effect of different diameter tumors in two groups

In the two groups, a total of 142 lesions successfully underwent puncture and cryotherapy. Before treatment, the location and size of the tumor were observed by scanning to establish a reasonable puncture path. During cryosurgery, scanning was performed to guide the positioning of the puncture needle and to observe the postoperative changes of the tumor. As shown in Figures 1, 2 and 3, the guide-scan time for the dual-slice group (5.7 ± 1.8 min) was greater than that in the 64-slice group (2.8 ± 1.2 min); and the difference was statistically significant ($t = 11.445$, $P = 0.000$). Furthermore, the freeze effective rate of patients with tumor diameters < 3 cm in the dual-slice group was significantly less than that in patients in the 64-slice group; and the difference was statistically significant ($\chi^2 = 5.707$, $P = 0.017$). Moreover, there was no significant difference in the freeze effective rate of patients with tumor diameters > 3 cm between the two groups ($\chi^2 = 0.236$, $P = 0.627$); Table 1.

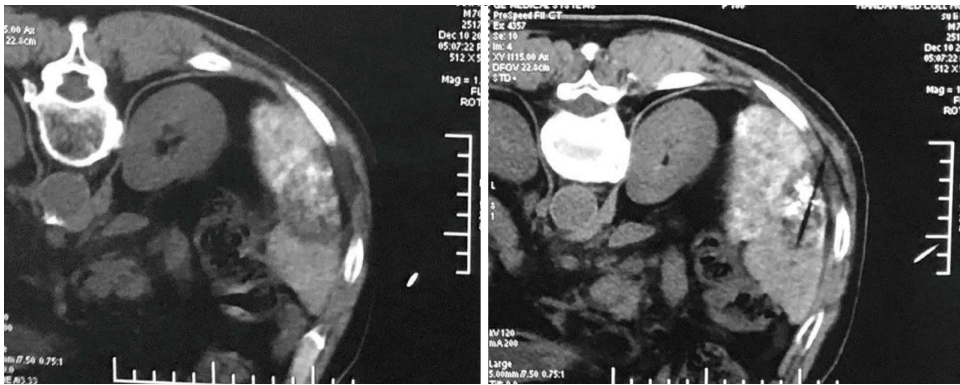


Figure 3 After the cryoablation treatment, the patient was placed in the prone position. The circular low-density area was the frozen necrotic area, which shows the lesions were within the range and it has good treatment effect.

Table 1 Postoperative ice coverage of different tumor sizes						
Groups	Tumor diameter (cm)	Number of tumors (count)	ice coverage (%)			Effective rate
			100	80-99	< 80	
Dual-slice group	< 3	38	19	12	7	81.58%
	≥ 3	27	17	8	2	92.59%
64-slice group	< 3	42	30	9	3	92.86% ^a
	≥ 3	35	26	7	2	94.29%

Effective rate = (ice coverage ≥ 80% of the tumor volume in the number of tumors)/(the total number of tumors) × 100%. ^a*P* < 0.05, vs the dual-slice group.

Comparison of liver perfusion values between the two groups

At four weeks after cryoablation treatment, CT perfusion examination was performed again to observe the change in liver perfusion value. The difference in HAP, PVP and HAPI before treatment in two groups was not statistically significant. In the two groups, HAP and HAPI levels in tumor tissues were lower after treatment than before treatment (*P* < 0.05), and the difference was statistically significant (*P* < 0.05). Furthermore, HAP and HAPI levels in the 64-slice group were lower than in the dual-slice group; and the difference was statistically significant (all *P* < 0.05). HAP and PVP in the two groups were lower after treatment than before treatment, while HAPI increased; and the differences were statistically significant (all *P* < 0.05). There was no significant difference in HAP, HAPI and PVP between the two groups after treatment (*P* > 0.05). Furthermore, there was no significant difference in HAP, PVP and HAPI in normal liver tissues before and after treatment (all *P* > 0.05; Table 2).

Comparison of postoperative local treatment effect between the two groups

Patients in the two groups underwent CT perfusion imaging of the liver after four weeks to assess the therapeutic effect. In comparing these two groups, the treatment effect of patients in the 64-slice group was better than that observed in the dual-slice group; and

the difference was statistically significant (*z* = -2.325, *P* = 0.020). Furthermore, the effective rate in the dual-slice double row group (76.93%) was lower than that in the 64-slice group (92.21%); and the difference was statistically significant (χ^2 = 8.946, *P* = 0.003) (Table 3).

Incidence of post-operative adverse reactions

In terms of post-operative adverse reactions, three patients had pleural effusion and two patients had intraperitoneal hemorrhage in the dual-slice group, however, these two complications did not occur in the 64-slice group, the difference between these two groups was statistically significant (*P* < 0.05). Furthermore, fever rate was slightly higher in the 64-slice group than in the dual-slice group; but the difference was not statistically significant (*P* > 0.05). The difference in pain, skin frostbite, nausea and vomiting between the two groups was not significant (*P* > 0.05; Table 4).

DISCUSSION

For patients who cannot receive radical resection of liver cancer due to poor cardiopulmonary function or combined with extrahepatic metastasis or other factors, ablation therapy can not only removes the cancer cells, but also saves more normal liver function as much as possible. Furthermore, this treatment induces small physical trauma to patients^[16-18]. Cryoablation therapy is a kind of local ablation therapy. With the development of technology in recent years, it has become one of the important means of minimally invasive treatment for liver cancer and other tumors^[8,19]. Cryoablation therapy is the combined application of ultra-low temperature and re-warming technology, in which tumor tissues are rapidly frozen and melted to damage tumor cells^[20,21]. With the right guidance technology, the frozen knife was placed in the tumor tissue; and high pressure argon and helium was successively input at room temperature. Argon at the tip of the knife was rapidly expanded, the tumor tissue was rapidly frozen to -140 °C, and

Table 2 Comparison of liver perfusion values before and after treatment (mean \pm SD)

Tissue		64-slice group			Dual-slice group		
		HAP (mL/min·100 mg)	PVP (mL/min·100 mg)	HAPI (%)	HAP (mL/min·100 mg)	PVP (mL/min·100 mg)	HAPI (%)
Tumor tissue	Pre-treatment	47.82 \pm 16.71	8.51 \pm 3.71	84.31 \pm 13.22	48.42 \pm 12.85	9.16 \pm 3.75	82.27 \pm 14.26
	Post-treatment	20.21 \pm 9.42 ^{a,c}	8.13 \pm 3.22	48.93 \pm 9.42 ^{a,c}	26.21 \pm 9.36 ^a	8.53 \pm 3.22	38.93 \pm 9.42 ^a
Adjacent tumor tissues	Pre-treatment	35.95 \pm 15.25	47.81 \pm 8.51	38.92 \pm 16.91	35.95 \pm 15.25	45.81 \pm 8.51	37.92 \pm 13.91
	Post-treatment	21.34 \pm 9.95 ^a	39.82 \pm 14.33 ^a	47.01 \pm 9.71 ^a	20.34 \pm 9.95 ^a	37.82 \pm 14.33 ^a	46.01 \pm 9.71 ^a
Normal liver tissue	Pre-treatment	25.65 \pm 11.86	57.90 \pm 18.93	28.62 \pm 11.72	24.87 \pm 13.48	58.93 \pm 16.75	27.75 \pm 14.68
	Post-treatment	26.02 \pm 10.13	58.23 \pm 16.94	27.43 \pm 12.23	25.89 \pm 10.78	59.78 \pm 13.76	26.63 \pm 12.25

^a $P < 0.05$, post-treatment *vs* pre-treatment in the group; ^c $P < 0.05$, *vs* the dual-slice group post-treatment. HAP: Hepatic artery perfusion; PVP: Portal vein perfusion; HAPI: Hepatic arterial perfusion index.

Table 3 Follow-up observation of treatment effect

Groups	Number of tumors (<i>n</i>)	Treatment effect (%)				Effective rate
		Complete ablation	Mostly ablated	Stable	Progressive	
Dual-slice group	65	42 (64.62)	8 (12.31)	10 (15.38)	5 (7.69)	76.93%
64-slice group	77	62 (80.52)	9 (11.69)	4 (5.19)	2 (2.60)	92.21%
Test value	-	$z = -2.325$				$\chi^2 = 8.946$
<i>P</i> value	-	0.02				0.003%

Effective rate = (the number complete ablation cases + the number of mostly ablated cases)/ total number of tumors \times 100%.

Table 4 Postoperative adverse reactions *n* (%)

Group	Number of cases	Fever	Pain	Skin frostbite	Nausea and vomiting	Pleural effusion	Intraoperative hemorrhage
Dual-slice group	56	33 (53.57)	5 (8.93)	1 (1.79)	5 (8.93)	3 (5.36)	2 (3.57)
64-slice group	68	43 (63.24)	7 (10.29)	1 (1.47)	6 (8.82)	0	0
χ^2	-	1.925	0.106	0.032	0	5.508	3.635
<i>P</i> value	-	0.165	0.744	0.858	0.978	0.019	0.057

helium which re-entered into the tumor tissue rapidly rise to 40–45 °C. During cryoablation, rapid freezing resulted in the production of intracellular ice crystals. This would destroy the osmotic balance inside and outside the cell membrane. Furthermore, due to cell volume expansion, extracellular ice crystals are formed, resulting in mutual extrusion and increased cell damage^[22–24]. The melting immediate after the freezing causes the ice crystal balls to expand and burst, destroying the tumor cells. Then, after helium re-warms it to a certain extent, frozen ablation was carried out once again. This again damages tumor cells that have not been destroyed by the first cryoablation due to the dehydration of cells, increasing the destruction of tumor tissue^[25,26]. In the treatment of liver cancer, cryosurgery allows the accurate display of the tumor location and peripheral vascular conditions, which is important for an accurate puncture for cryotherapy and the right cryoablation area. Therefore, seeking for a good imaging technology to accurately display the location of the tumor and its surrounding tissue blood vessels can provide guidance in cryoablation treatment. That can significantly reduce damage to the surrounding tissues of the lesion and

reduce postoperative complications^[27–32]. At present, CT guidance has been widely used in the clinic. With the development of CT technology, 64-slice spiral CT has a high scanning speed, provides better resolution images, has a powerful 3D reconstruction capability that provides more intuitive images for the doctor, and can more clearly show the situation of blood vessels. This would help in understanding the relationship between the lesion and the surrounding blood vessels, observe whether blood vessels are within the liver variation, and avoid intraoperative variability vascular puncture accidental injury^[33–36]. Therefore, this study compares and analyzes the cryosurgical treatment effects and complications between 64-slice spiral CT and double-slice spiral CT guidance, and try to observe whether 64-slice spiral CT-guided cryosurgery of the liver cancer can achieve better results.

Effect of cryotherapy in the two groups of patients

Comparing the scan time between the two groups of patients, it can be seen that the scan time of the 64-slice spiral CT is shorter, since the adjustment of the needle position during surgery and the observation of the formation of ice balls needs to be scanned several

times, 64-slice spiral CT scan can help reduce scan waiting time; which speeds up the surgical process. The difference in freezing efficiency rate in tumor lesions ≥ 3 cm in diameter between the two groups was not statistically significant. However, the freezing efficiency rate was significantly greater in tumors < 3 cm in diameter in the 64-slice group. 64-slice spiral CT-guided cryoablation have better results for smaller lesions.

This is because 64-slice spiral CT has higher spatial resolution, compared to dual-slice spiral CT. Furthermore, the 64-slice spiral CT enables the simultaneous collection of a 64-layer sub-millimeter thick image, and covers a long revolution of nearly 40 mm when it rotates in a circular course. In addition, it enables the reconstruction of the cross-section, coronal plane and other arbitrary plane images. The collected images are multi-planar imaging (MPR). That is, scanning is performed once, which can be adjusted in multiple directions. This enables an arbitrary slice image to be obtained, and helps in observing the details of the lesion and its spatial anatomy relationship. These advantages allow the 64-slice spiral CT to more clearly show the edge of the tumor and the formation of the edge of the ice ball during the surgery, help physicians control the ice ball range, and more clearly show the tumor tissue and its surrounding tissue. For smaller lesions, it can also clearly show the edge of the lesion and its adjacent vascular structure. Particularly near the diaphragm of the lesion, hilar large vessels and other special locations, the 64-slice spiral CT provides a clear image that enables physicians reduce intraoperative time, avoid damage to the surrounding normal tissues, and limits the freezing range; which affects the influence of the ablation^[37-40]. 64-slice spiral imaging can directly reflect the internal hemodynamics of the liver, and has good reference value for understanding tumor angiogenesis and its biological characteristics^[11,41-44].

Evaluation of effects after four weeks of treatment

CT perfusion examination after four weeks revealed that HAP and HAPI decreased in tumor tissues in the two groups. However, these decreased more significantly in the 64-slice group, while the difference among HAP, HAPI and PVP between the two adjacent tissues and normal liver tissues was not statistically significant. The significant reduction in HAP and HAPI in the liver after treatment was an indicator of efficacy. This proves that lesion ablation treatment was better in patients in the 64-slice group. The presence of HAP in the tumor may represent the presence of arterial blood supply in the tumor, or the formation of postoperative granulation tissues with small blood vessels. In addition, liver cancer can easily recur and metastasize. Therefore, patients still need to be examined through continuous follow-ups. The effective rate in the 64-slice group was higher than that in the dual-slice group.

The reason is that 64-slice spiral CT can provide good coverage of the ice ball for lesion with ≥ 3 cm and < 3 cm diameters, and improve the ablation effect. Its three-dimensional imaging technology enables physicians to view liver blood vessels and lesions that are more solid, clear, more accurate, and more comprehensive; allowing a reasonable needle puncture and optimizing the freezing effect^[11,29,45,46]. Its rapid scan imaging during surgery allows the detection of the formation of ice ball and freezing conditions, provides an accurate lesion and surrounding tissue image, help in the timely adjustment of the ablation procedure, and prevents damage in surrounding tissues, while improving the effectiveness of tumor tissue ablation^[9,35,47].

Incidence of postoperative complications in the two groups

In the dual-slice group, three patients had pleural effusion and two patients had intraperitoneal hemorrhage. However, none of these complications occurred in patients in the 64-slice group. Furthermore, the difference between fever, pain, skin frostbite, nausea and vomiting occurring in patients in these two groups was not statistically significant. That proves 64-slice spiral CT can be used as a means of guidance, it has fewer postoperative complications, and its absence of pleural effusion and abdominal bleeding may be due to better liver blood vessel imaging technology. Compared to dual-slice spiral CT, 64-slice spiral CT can display a clearer visualization of the distribution of small blood vessels, allows the observation of the presence of variant blood vessels, and reduced the incidence of intraoperative vascular injury. Pleural effusion may occur due to tumors near the diaphragm, the intraoperative frozen stimulation to the diaphragm, or failure to monitor the extent of the frozen lesions in time; stimulating the pleura. The 64-slice spiral CT provides clear imaging, helps the surgeon accurately observe and control the freezing range, and reduces stimulation to the diaphragm and pleura^[48-50].

However, in this study, only the treatment effect between 64-slice spiral CT-guided and dual-slice spiral CT-guided cryoablation were compared. At present, there is a need to further observe and compare the clinical applications of spiral CT, ultrasound, MRI and other guidance imaging technologies; and determine whether there is a difference in the guidance effect of these techniques when compared with 64-slice spiral CT. Furthermore, there is also a need to analyze the clinical applications the current guidance technologies, which has its own advantages; particularly in determining which technology has a better guiding treatment for patients with certain characteristics. In addition, this study followed-up patients up to four weeks after surgery. Future research should extend this follow-up time, in order to observe the recurrence

and metastasis of liver cancer, as well as the survival time of patients after treatment.

In conclusion, 64-slice spiral CT in the cryosurgical treatment of liver cancer targeting process provides a safe and effective freezing treatment. It is a reasonable choice worthy for clinical applications.

COMMENTS

Background

Liver cancer is the third most common malignant tumour in China, and there has been an increasing trend in its incidence in recent years. For patients with advanced tumors, if local treatment is available to delay the growth and spread of the tumor, it would help extend survival time and improve the quality of life of patients. Cryoablation targeted treatment has gradually become an important method of minimally invasive treatment for liver cancer. The guide technology used in argon-helium cryoablation therapy includes double-row spiral computed tomography (CT) and 64-slice spiral CT and so on. To compare the dual-slice spiral CT and 64-slice spiral CT guided cryosurgery treatments performed for liver cancer patients can provide a reference for the clinical application of 64-slice spiral CT guided cryoablation therapy.

Research frontiers

In the treatment of liver cancer, cryosurgery allows the accurate display of the tumor location and peripheral vascular conditions, which is important for an accurate puncture for cryotherapy and the right cryoablation area. The 64-slice spiral CT has a high scanning speed, provides better resolution images, and has a powerful 3D reconstruction capability that provides more intuitive images for the doctor. Therefore, the authors hope that this technology in the guidance of argon helium cryo-knife treatment has a good effect.

Innovations and breakthroughs

The 64-slice spiral CT has higher spatial resolution. For smaller lesions, it can also clearly show the edge of the lesion and its adjacent vascular structure. The 64-slice spiral CT provides a clear image that enables physicians to reduce intraoperative time, avoiding damage to the surrounding normal tissues. This means that guidance of argon-helium cryosurgery treatment of small diameter liver cancer also has a good freezing effect. It has an important clinical application value and is worthy of promoting.

Applications

In this study, compared with the double-row group, the guide scan time is short and more efficient in tumors < 3 cm in diameter in the 64-slice group. Four weeks after treatment, the treatment effect and treatment efficiency is better, less complications in the 64-slice group. Therefore, it is recommended to use 64-slice spiral CT in the treatment of liver cancer by argon helium cryoablation.

Peer-review

This is an interesting manuscript. In this manuscript, the effect of targeted therapy of 64-slice spiral CT combined with cryoablation for liver cancer was observed. A total of 124 patients were enrolled into this study. According to the use of dual-slice spiral CT or 64-slice spiral CT as a guide technology, patients were divided into two groups: dual-slice group and 64-slice group. All the patients were accepted for the targeted therapy by argon-helium superconducting surgery system. The guided scan times of the two groups was recorded and compared. The authors found that the treatment effect and therapeutic efficacy in the dual-slice group were lower than the 64-slice group at four weeks post-treatment.

REFERENCES

- 1 Luo X, Huang Y, Chen Y, Tu Z, Hu J, Tavis JE, Huang A, Hu Y. Association of Hepatitis B Virus Covalently Closed Circular DNA and Human APOBEC3B in Hepatitis B Virus-Related Hepatocellular Carcinoma. *PLoS One* 2016; **11**: e0157708 [PMID: 27310677 DOI: 10.1371/journal.pone.0157708]
- 2 Shimizu T, Ishizuka M, Kato M, Aoki T, Kubota K. Hyaluronic Acid Predicts Postoperative Large Amount of Ascites after Liver Resection for Patients with Hepatocellular Carcinoma. *Dig Surg* 2016; **33**: 520-528 [PMID: 27310663 DOI: 10.1159/000447131]
- 3 Bird TG, Dimitropoulou P, Turner RM, Jenks SJ, Cusack P, Hey S, Blunsum A, Kelly S, Sturgeon C, Hayes PC, Bird SM. Alpha-Fetoprotein Detection of Hepatocellular Carcinoma Leads to a Standardized Analysis of Dynamic AFP to Improve Screening Based Detection. *PLoS One* 2016; **11**: e0156801 [PMID: 27308823 DOI: 10.1371/journal.pone.0156801]
- 4 Liu Y, Chai Y, Zhang J, Tang J. A Function Variant at miR-501 Alters Susceptibility to Hepatocellular Carcinoma in a Chinese Han Population. *Cell Physiol Biochem* 2016; **38**: 2500-2508 [PMID: 27310251 DOI: 10.1159/000445600]
- 5 Terzić D, Svrtlih N. The association of hepatocellular carcinoma with hepatitis C virus and its genotypes in Montenegrin patients. *J Gastrointest Liver Dis* 2016; **25**: 257-258 [PMID: 27308661 DOI: 10.15403/jgld.2014.1121.252.mnt]
- 6 Crissien AM, Frenette C. Current management of hepatocellular carcinoma. *Gastroenterol Hepatol (N Y)* 2014; **10**: 153-161 [PMID: 24829542]
- 7 Chen Y, Gao SG, Chen JM, Wang GP, Wang ZF, Zhou B, Jin CH, Yang YT, Feng XS. Risk factors for the Long-Term Efficacy, Recurrence, and Metastasis in Small Hepatocellular Carcinomas. *Cell Biochem Biophys* 2015; **72**: 627-631 [PMID: 25663533 DOI: 10.1007/s12013-015-0514-y]
- 8 Huang M, Wang X, Bin H. Effect of Transcatheter Arterial Chemoembolization Combined with Argon-Helium Cryosurgery System on the Changes of NK Cells and T Cell Subsets in Peripheral Blood of Hepatocellular Carcinoma Patients. *Cell Biochem Biophys* 2015; **73**: 787-792 [PMID: 27259326 DOI: 10.1007/s12013-015-0699-0]
- 9 Maida M, Macaluso FS, Valenza F, Virdone R. Complete and Sustained Off-Therapy Response to Sorafenib in Advanced Hepatocellular Carcinoma. *J Gastrointest Liver Dis* 2016; **25**: 253-255 [PMID: 27308660 DOI: 10.15403/jgld.2014.1121.252.off]
- 10 Nault JC, Datta S, Imbeaud S, Franconi A, Zucman-Rossi J. Adeno-associated virus type 2 as an oncogenic virus in human hepatocellular carcinoma. *Mol Cell Oncol* 2016; **3**: e1095271 [PMID: 27308626 DOI: 10.1080/23723556.2015.1095271]
- 11 Hao XJ, Li JP, Jiang HJ, Li DQ, Ling ZS, Xue LM, Feng GL. CT assessment of liver hemodynamics in patients with hepatocellular carcinoma after argon-helium cryoablation. *Hepatobiliary Pancreat Dis Int* 2013; **12**: 617-621 [PMID: 24322747]
- 12 Hu KQ. Advances in clinical application of cryoablation therapy for hepatocellular carcinoma and metastatic liver tumor. *J Clin Gastroenterol* 2014; **48**: 830-836 [PMID: 25148553 DOI: 10.1097/MCG.0000000000000201]
- 13 Zhou L, Fu JL, Lu YY, Fu BY, Wang CP, An LJ, Wang XZ, Zeng Z, Zhou CB, Yang YP, Wang FS. Regulatory T cells are associated with post-cryoablation prognosis in patients with hepatitis B virus-related hepatocellular carcinoma. *J Gastroenterol* 2010; **45**: 968-978 [PMID: 20411280 DOI: 10.1007/s00535-010-0243-3]
- 14 Xin'an L, Jianying Z, Lizhi N, Fei Y, Xiaohua W, Jibing C, Jialiang L, Kecheng X. Alleviating the pain of unresectable hepatic tumors by percutaneous cryoablation: experience in 73 patients. *Cryobiology* 2013; **67**: 369-373 [PMID: 24383131]
- 15 Yang Y, Wang C, Lu Y, Bai W, An L, Qu J, Gao X, Chen Y, Zhou L, Wu Y, Feng Y, Zhang M, Chang X, Lv J. Outcomes of ultrasound-guided percutaneous argon-helium cryoablation of hepatocellular carcinoma. *J Hepatobiliary Pancreat Sci* 2012; **19**: 674-684 [PMID: 22187145 DOI: 10.1007/s00534-011-0490-6]
- 16 Moore A, Cohen-Naftaly M, Benjaminov O, Braun M, Issachar A, Mor E, Tovar A, Sarfaty M, Gordon N, Stemmer SM. Radiotherapy and Sorafenib in the Management of Patients with Hepatocellular Carcinoma Have Led to Improved Survival: A Single Center Experience. *J Cancer* 2016; **7**: 883-889 [PMID: 27313777 DOI: 10.7150/jca.14721]
- 17 Zhou C, Wei B, Gao K, Zhai R. Biliary tract perforation following

- percutaneous endobiliary radiofrequency ablation: A report of two cases. *Oncol Lett* 2016; **11**: 3813-3816 [PMID: 27313699 DOI: 10.3892/ol.2016.4436]
- 18 **Zhu M**, Lu Y, Li W, Guo J, Dong X, Lin B, Chen Y, Xie X, Li M. Hepatitis B Virus X Protein Driven Alpha Fetoprotein Expression to Promote Malignant Behaviors of Normal Liver Cells and Hepatoma Cells. *J Cancer* 2016; **7**: 935-946 [PMID: 27313784 DOI: 10.7150/jca.13628]
 - 19 **Wang D**, Sun L, Zhang H, Jiang H, Liu M, Tian J, Hu N, Sun S. A canine model of osteonecrosis of the femoral head induced by MRI guided argon helium cryotherapy system. *Int J Clin Exp Med* 2015; **8**: 12890-12897 [PMID: 26550205]
 - 20 **Li M**, Cui Y, Li X, Guo Y, Wang B, Zhang J, Xu J, Han S, Shi X. Functional Changes of Dendritic Cells in C6 Glioma-Bearing Rats That Underwent Combined Argon-Helium Cryotherapy and IL-12 Treatment. *Technol Cancer Res Treat* 2016; **15**: 618-624 [PMID: 26316012 DOI: 10.1177/1533034615606322]
 - 21 **Wang Y**, Kan HL, Sun H, Wang DX, Wang HW, Liu JX. Magnetic resonance imaging-navigated argon-helium cryoablation therapy against a rabbit VX2 brain tumor. *Exp Ther Med* 2015; **9**: 2229-2234 [PMID: 26136965 DOI: 10.3892/etm.2015.2375]
 - 22 **Sun L**, Zhang W, Liu H, Yuan J, Liu W, Yang Y. Computed tomography imaging-guided percutaneous argon-helium cryoablation of muscle-invasive bladder cancer: initial experience in 32 patients. *Cryobiology* 2014; **69**: 318-322 [PMID: 25169033 DOI: 10.1016/j.cryobiol.2014.08.006]
 - 23 **Xu H**, Wang Q, Lin C, Yin Z, He X, Pan J, Lu G, Zhang S. Synergism between cryoablation and GM-CSF: enhanced immune function of splenic dendritic cells in mice with glioma. *Neuroreport* 2015; **26**: 346-353 [PMID: 25735009 DOI: 10.1097/WNR.0000000000000351]
 - 24 **Chaudhuri AA**, Binkley MS, Aggarwal S, Qian Y, Carter JN, Shah R, Loo BW. Severe Chest Wall Toxicity From Cryoablation in the Setting of Prior Stereotactic Ablative Radiotherapy. *Cureus* 2016; **8**: e477 [PMID: 27004154 DOI: 10.7759/cureus.477]
 - 25 **Hu KW**, Li QW, Zuo MH, Sun T, Jiang M. Clinical observation on the combined treatment of 57 cases of non-small cell lung cancer using argon-helium cryosurgery and Chinese herbal medicine. *Chin J Integr Med* 2007; **13**: 224-227 [PMID: 17898956 DOI: 10.1007/s11655-007-0224-4]
 - 26 **Song Q**, Zhan Y, Li LJ. [Clinical application of CT-guided percutaneous targeted argon-helium cryoablation for soft tissue sarcoma]. *Nan Fang Yi Ke Da Xue Xue Bao* 2006; **26**: 229-230 [PMID: 16503539]
 - 27 **Lin C**, Wang Q, Lu G, Yin Z, He X, Xu H, Pan J, Zhang S. In-situ administration of dendritic cells following argon-helium cryosurgery enhances specific antiglioma immunity in mice. *Neuroreport* 2014; **25**: 900-908 [PMID: 24942351 DOI: 10.1097/WNR.0000000000000196]
 - 28 **Wang D**, Wang G, Liu M, Sun L, Zong W, Jiang H, Zhang H, Li H, Gong J, Sun S. A novel animal model of osteonecrosis of the femoral head induced using a magnetic resonance imaging-guided argon-helium cryotherapy system. *Exp Ther Med* 2014; **7**: 1525-1528 [PMID: 24926337 DOI: 10.3892/etm.2014.1625]
 - 29 **Li Y**, Guo Z, Wang HT, Liu F, Ni H. [Clinical study of cryoablation in the salvage treatment of stage III non-small cell lung cancer]. *Zhonghua Yi Xue Za Zhi* 2011; **91**: 2205-2207 [PMID: 22094040]
 - 30 **Wang H**, Ma H, Luo L, Li H. Cryosurgery Combined with Radioactive Seeds and Release-controlled Chemical Drugs Implantation for the Treatment of Lung Carcinoma. *Zhongguo Fei Ai Za Zhi* 2009; **12**: 408-411 [PMID: 20719135 DOI: 10.3779/j.issn.1009-3419.2009.05.006]
 - 31 **Zhang Y**, Li S, Cao K, Feng Y, Zhang X, Xiao Y, Li J. Mechanism research on combination of decoction for reinforcing lung qi and argon helium lancet in treatment of non-small cell lung cancer. *J Tradit Chin Med* 2013; **33**: 307-311 [PMID: 24024324]
 - 32 **Wendler JJ**, Friebe B, Baumunk D, Blana A, Franiel T, Ganzer R, Hadaschik B, Henkel T, Köhrmann KU, Köllermann J, Kuru T, Machtens S, Roosen A, Salomon G, Schlemmer HP, Sentker L, Witzsch U, Liehr UB, Ricke J, Schostak M. [Focal therapy for small renal masses: Observation, ablation or surgery]. *Urologe A* 2016; **55**: 594-606 [PMID: 27119957 DOI: 10.1007/s00120-016-0075-8]
 - 33 **Jiang PF**, Dai XY, Lv Y, Liu S, Mu XY. Imaging study on the optic canal using sixty four-slice spiral computed tomography. *Int J Clin Exp Med* 2015; **8**: 21247-21251 [PMID: 26885062]
 - 34 **Sun ZQ**, Cheng XF, Ge YX, Chen L, Yue JG, Jin LF, Xie ZH, Zhang HD, Xuan YH. Role of CT perfusion imaging in patients with variously differentiated gastric adenocarcinoma. *J Xray Sci Technol* 2015; **23**: 737-744 [PMID: 26756409 DOI: 10.3233/XST-150524]
 - 35 **Wen Z**, Yao F, Wang Y. 64-Slice spiral computed tomography and three-dimensional reconstruction in the diagnosis of cystic pancreatic tumors. *Exp Ther Med* 2016; **11**: 1506-1512 [PMID: 27073473 DOI: 10.3892/etm.2016.3031]
 - 36 **Yan M**, Li X, Yin H, Wu D, Yang D, Xu G. [The assessed value of 64 slice spiral CT perfusion imaging in laryngeal squamous cell carcinoma after chemotherapy and radiotherapy]. *Lin Chung Er Bi Yan Hou Tou Jing Wai Ke Za Zhi* 2015; **29**: 1002-1005 [PMID: 26536703]
 - 37 **Binnebösel M**, Bruners P, Klink CD, Kuhl C, Neumann UP. [Oligometastasized stage IV colorectal cancer: Surgical resection and local ablative procedures]. *Chirurg* 2016; **87**: 371-379 [PMID: 27146386 DOI: 10.1007/s00104-016-0187-0]
 - 38 **Yang FB**, Guo WL, Sheng M, Sun L, Ding YY, Xu QQ, Xu MG, Lv HT. Diagnostic accuracy of coronary angiography using 64-slice computed tomography in coronary artery disease. *Saudi Med J* 2015; **36**: 1156-1162 [PMID: 26446324 DOI: 10.15537/smj.2015.10.12415]
 - 39 **Zhang L**, Xiao J, Xu G, Kong X, Fu M, Wang Z, Li J. [Construction of a three-dimensional digital model of the liver of Wuzhishan mini-pig]. *Nan Fang Yi Ke Da Xue Xue Bao* 2015; **35**: 1362-1365 [PMID: 26403757]
 - 40 **Ali AM**, Lizhi N, Jialiang L, Fei Y, Yuan W, Jianying Z, Jin Y, Jibing C, Feng M, Kecheng X. Cryoprotective therapy for hepatocellular carcinoma: study of 51 patients with a single lesion. *Cryobiology* 2014; **69**: 61-67 [PMID: 24859156 DOI: 10.1016/j.cryobiol.2014.05.003]
 - 41 **Ichikawa T**, Motosugi U, Morisaka H, Sano K, Ali M, Araki T. Volumetric low-tube-voltage CT imaging for evaluating hypervascular hepatocellular carcinoma; effects on radiation exposure, image quality, and diagnostic performance. *Jpn J Radiol* 2013; **31**: 521-529 [PMID: 23793776 DOI: 10.1007/s11604-013-0217-5]
 - 42 **Li JJ**, Zheng JS, Cui SC, Cui XW, Hu CX, Fang D, Ye LC. C-arm Lipiodol CT in transcatheter arterial chemoembolization for small hepatocellular carcinoma. *World J Gastroenterol* 2015; **21**: 3035-3040 [PMID: 25780303 DOI: 10.3748/wjg.v21.i10.3035]
 - 43 **Ma GL**, Jiang HJ, Chen M. [Hemodynamic study of hepatocellular carcinoma nodules by multi-slice spiral computed tomographic perfusion]. *Zhonghua Yi Xue Za Zhi* 2013; **93**: 1146-1149 [PMID: 23902883]
 - 44 **Ozbülül NI**, Yurdakul M, Tola M. Does the right inferior phrenic artery have a supplying role in liver cirrhosis without hepatocellular carcinoma? A 64-slice CT study. *Diagn Interv Radiol* 2011; **17**: 239-242 [PMID: 20690077 DOI: 10.4261/1305-3825.DIR.3395-10.1]
 - 45 **Beaudoin EL**, Chee A, Stather DR. Interventional pulmonology: an update for internal medicine physicians. *Minerva Med* 2014; **105**: 197-209 [PMID: 24988085]
 - 46 **Chou HP**, Chen CK, Shen SH, Sheu MH, Wu MH, Wu YC, Chang CY. Percutaneous cryoablation for inoperable malignant lung tumors: midterm results. *Cryobiology* 2015; **70**: 60-65 [PMID: 25541142 DOI: 10.1016/j.cryobiol.2014.12.004]
 - 47 **Grandhi MS**, Kim AK, Ronnekleiv-Kelly SM, Kamel IR, Ghasebeh MA, Pawlik TM. Hepatocellular carcinoma: From diagnosis to treatment. *Surg Oncol* 2016; **25**: 74-85 [PMID: 27312032 DOI: 10.1016/j.suronc.2016.03.002]

- 48 **Amini A**, Gamblin TC. Palliation: treating patients with inoperable biliary tract and primary liver tumors. *Surg Oncol Clin N Am* 2014; **23**: 383-397 [PMID: 24560116 DOI: 10.1016/j.soc.2013.10.008]
- 49 **Shyn PB**, Mauri G, Alencar RO, Tatli S, Shah SH, Morrison PR, Catalano PJ, Silverman SG. Percutaneous imaging-guided cryoablation of liver tumors: predicting local progression on 24-hour MRI. *AJR Am J Roentgenol* 2014; **203**: W181-W191 [PMID: 24555531 DOI: 10.2214/AJR.13.10747]
- 50 **Gómez FM**, Patel PA, Stuart S, Roebuck DJ. Systematic review of ablation techniques for the treatment of malignant or aggressive benign lesions in children. *Pediatr Radiol* 2014; **44**: 1281-1289 [PMID: 24821394 DOI: 10.1007/s00247-014-3001-5]

P- Reviewer: Sumi K, Villanueva MT **S- Editor:** Ma YJ
L- Editor: O'Neill M **E- Editor:** Wang CH





Published by **Baishideng Publishing Group Inc**
7901 Stoneridge Drive, Suite 501, Pleasanton, CA 94588, USA
Telephone: +1-925-223-8242
Fax: +1-925-223-8243
E-mail: bpgoffice@wjgnet.com
Help Desk: <http://www.f6publishing.com/helpdesk>
<http://www.wjgnet.com>



ISSN 1007-9327



9 771007 932045