

World Journal of *Gastroenterology*

World J Gastroenterol 2017 June 28; 23(24): 4317-4472



**EDITORIAL**

- 4317 Risk of hepatitis B reactivation in patients treated with direct-acting antivirals for hepatitis C
Aggeletopoulou I, Konstantakis C, Manolakopoulos S, Triantos C
- 4324 Role of new endoscopic techniques in inflammatory bowel disease management: Has the change come?
Goran L, Negreanu L, Negreanu AM

REVIEW

- 4330 Implication of the Hedgehog pathway in hepatocellular carcinoma
Della Corte CM, Viscardi G, Papaccio F, Esposito G, Martini G, Ciardiello D, Martinelli E, Ciardiello F, Morgillo F

ORIGINAL ARTICLE**Basic Study**

- 4341 Indole phytoalexin derivatives induce mitochondrialmediated apoptosis in human colorectal carcinoma cells
Tischlerova V, Kello M, Budovska M, Mojzis J
- 4354 Naringenin prevents experimental liver fibrosis by blocking TGF β -Smad3 and JNK-Smad3 pathways
Hernández-Aquino E, Zarco N, Casas-Grajales S, Ramos-Tovar E, Flores-Beltrán RE, Arauz J, Shibayama M, Favari L, Tsutsumi V, Segovia J, Muriel P
- 4369 Intestinal anti-inflammatory activity of Ground Cherry (*Physalis angulata* L.) standardized CO₂ phytopharmaceutical preparation
Almeida Junior LD, Quaglio AEV, de Almeida Costa CAR, Di Stasi LC
- 4381 *Maytenus erythroxylon* Reissek (Celastraceae) ethanol extract presents antidiarrheal activity *via* antimotility and antisecretory mechanisms
Formiga RO, Quirino ZGM, Diniz MFFM, Marinho AF, Tavares JF, Batista LM
- 4390 Gastric cancer-derived heat shock protein-gp96 peptide complex enhances dendritic cell activation
Lu WW, Zhang H, Li YM, Ji F
- Retrospective Cohort Study**
- 4399 Para-aortic node involvement is not an independent predictor of survival after resection for pancreatic cancer
Sperti C, Gruppo M, Blandamura S, Valmasoni M, Pozza G, Passuello N, Beltrame V, Moletta L

Retrospective Study

- 4407 Risk factors for metachronous gastric carcinoma development after endoscopic resection of gastric dysplasia: Retrospective, single-center study

Moon HS, Yun GY, Kim JS, Eun HS, Kang SH, Sung JK, Jeong HY, Song KS

- 4416 New magnifying endoscopic classification for superficial esophageal squamous cell carcinoma

Kim SJ, Kim GH, Lee MW, Jeon HK, Baek DH, Lee BE, Song GA

- 4422 Procalcitonin as a diagnostic marker to distinguish upper and lower gastrointestinal perforation

Gao Y, Yu KJ, Kang K, Liu HT, Zhang X, Huang R, Qu JD, Wang SC, Liu RJ, Liu YS, Wang HL

Observational Study

- 4428 Healthcare utilization and costs associated with gastroparesis

Wadhwa V, Mehta D, Jobanputra Y, Lopez R, Thota PN, Sanaka MR

- 4437 Variability of anti-human transglutaminase testing in celiac disease across Mediterranean countries

Smarrazzo A, Magazzù G, Ben-Hariz M, Legarda Tamara M, Velmishi V, Roma E, Kansu A, Mičetić-Turk D, Bravi E, Stellato P, Arcidiaco C, Greco L

- 4444 Appropriateness of the study of iron deficiency anemia prior to referral for small bowel evaluation at a tertiary center

Rodrigues JP, Pinho R, Silva J, Ponte A, Sousa M, Silva JC, Carvalho J

Randomized Clinical Trial

- 4454 Comparing reduced-dose sodium phosphate tablets to 2 L of polyethylene glycol: A randomized study

Ako S, Takemoto K, Yasutomi E, Sakaguchi C, Murakami M, Sunami T, Oka S, Kenta H, Okazaki N, Baba Y, Yamasaki Y, Asato T, Kawai D, Takenaka R, Tsugeno H, Hiraoka S, Kato J, Fujiki S

CASE REPORT

- 4462 Case of pediatric traditional serrated adenoma resected *via* endoscopic submucosal dissection

Kondo S, Mori H, Nishiyama N, Kondo T, Shimono R, Okada H, Kusaka T

- 4467 Pancreatic T/histiocyte-rich large B-cell lymphoma: A case report and review of literature

Zheng SM, Zhou DJ, Chen YH, Jiang R, Wang YX, Zhang Y, Xue HL, Wang HQ, Mou D, Zeng WZ

ABOUT COVER

Editorial board member of *World Journal of Gastroenterology*, Christian Martin Grieser, MD, PhD, Associate Professor, Doctor, Center for Modern Diagnostics, Schwachhauser Heerstr. 63a, Bremen 28209, Germany

AIMS AND SCOPE

World Journal of Gastroenterology (*World J Gastroenterol*, *WJG*, print ISSN 1007-9327, online ISSN 2219-2840, DOI: 10.3748) is a peer-reviewed open access journal. *WJG* was established on October 1, 1995. It is published weekly on the 7th, 14th, 21st, and 28th each month. The *WJG* Editorial Board consists of 1375 experts in gastroenterology and hepatology from 68 countries.

The primary task of *WJG* is to rapidly publish high-quality original articles, reviews, and commentaries in the fields of gastroenterology, hepatology, gastrointestinal endoscopy, gastrointestinal surgery, hepatobiliary surgery, gastrointestinal oncology, gastrointestinal radiation oncology, gastrointestinal imaging, gastrointestinal interventional therapy, gastrointestinal infectious diseases, gastrointestinal pharmacology, gastrointestinal pathophysiology, gastrointestinal pathology, evidence-based medicine in gastroenterology, pancreatology, gastrointestinal laboratory medicine, gastrointestinal molecular biology, gastrointestinal immunology, gastrointestinal microbiology, gastrointestinal genetics, gastrointestinal translational medicine, gastrointestinal diagnostics, and gastrointestinal therapeutics. *WJG* is dedicated to become an influential and prestigious journal in gastroenterology and hepatology, to promote the development of above disciplines, and to improve the diagnostic and therapeutic skill and expertise of clinicians.

INDEXING/ABSTRACTING

World Journal of Gastroenterology (*WJG*) is now indexed in Current Contents[®]/Clinical Medicine, Science Citation Index Expanded (also known as SciSearch[®]), Journal Citation Reports[®], Index Medicus, MEDLINE, PubMed, PubMed Central and Directory of Open Access Journals. The 2017 edition of Journal Citation Reports[®] cites the 2016 impact factor for *WJG* as 3.365 (5-year impact factor: 3.176), ranking *WJG* as 29th among 79 journals in gastroenterology and hepatology (quartile in category Q2).

FLYLEAF

I-IX Editorial Board

EDITORS FOR THIS ISSUE

Responsible Assistant Editor: *Xiang Li*
Responsible Electronic Editor: *Cui-Hong Wang*
Proofing Editor-in-Chief: *Lian-Sheng Ma*

Responsible Science Editor: *Yuan Qi*
Proofing Editorial Office Director: *Jin-Lei Wang*

NAME OF JOURNAL
World Journal of Gastroenterology

ISSN
ISSN 1007-9327 (print)
ISSN 2219-2840 (online)

LAUNCH DATE
October 1, 1995

FREQUENCY
Weekly

EDITORS-IN-CHIEF
Damian Garcia-Olmo, MD, PhD, Doctor, Professor, Surgeon, Department of Surgery, Universidad Autonoma de Madrid; Department of General Surgery, Fundacion Jimenez Diaz University Hospital, Madrid 28040, Spain

Stephen C Strom, PhD, Professor, Department of Laboratory Medicine, Division of Pathology, Karolinska Institutet, Stockholm 141-86, Sweden

Andrzej S Tarnawski, MD, PhD, DSc (Med), Professor of Medicine, Chief Gastroenterology, VA Long Beach Health Care System, University of California, Irvine, CA, 5901 E. Seventh Str., Long Beach,

CA 90822, United States

EDITORIAL BOARD MEMBERS
All editorial board members resources online at <http://www.wjgnet.com/1007-9327/editorialboard.htm>

EDITORIAL OFFICE
Jin-Lei Wang, Director
Yuan Qi, Vice Director
Ze-Mao Gong, Vice Director
World Journal of Gastroenterology
Baishideng Publishing Group Inc
7901 Stoneridge Drive, Suite 501,
Pleasanton, CA 94588, USA
Telephone: +1-925-2238242
Fax: +1-925-2238243
E-mail: editorialoffice@wjgnet.com
Help Desk: <http://www.f6publishing.com/helpdesk>
<http://www.wjgnet.com>

PUBLISHER
Baishideng Publishing Group Inc
7901 Stoneridge Drive, Suite 501,
Pleasanton, CA 94588, USA
Telephone: +1-925-2238242
Fax: +1-925-2238243
E-mail: bpoffice@wjgnet.com
Help Desk: <http://www.f6publishing.com/helpdesk>

<http://www.wjgnet.com>

PUBLICATION DATE
June 28, 2017

COPYRIGHT
© 2017 Baishideng Publishing Group Inc. Articles published by this Open-Access journal are distributed under the terms of the Creative Commons Attribution Non-commercial License, which permits use, distribution, and reproduction in any medium, provided the original work is properly cited, the use is non commercial and is otherwise in compliance with the license.

SPECIAL STATEMENT
All articles published in journals owned by the Baishideng Publishing Group (BPG) represent the views and opinions of their authors, and not the views, opinions or policies of the BPG, except where otherwise explicitly indicated.

INSTRUCTIONS TO AUTHORS
Full instructions are available online at <http://www.wjgnet.com/bpg/gerinfo/204>

ONLINE SUBMISSION
<http://www.f6publishing.com>

Basic Study

Intestinal anti-inflammatory activity of Ground Cherry (*Physalis angulata* L.) standardized CO₂ phytopharmaceutical preparation

Luiz Domingues Almeida Junior, Ana Elisa Valencise Quaglio, Celso Acácio Rodrigues de Almeida Costa, Luiz Claudio Di Stasi

Luiz Domingues Almeida Junior, Ana Elisa Valencise Quaglio, Celso Acácio Rodrigues de Almeida Costa, Luiz Claudio Di Stasi, Laboratory of Phytomedicines, Pharmacology and Biotechnology (PhytoPharmaTech), Department of Pharmacology, Institute of Biosciences, Universidade Estadual Paulista UNESP, Botucatu, São Paulo, CEP 18618-970, Brazil

Author contributions: This paper was part of the Master research of Almeida Junior LD, who drafted the manuscript, was responsible for animal care and management, and supervised and accompanied all of the experiments; Quaglio AEV contributed to performing the appropriate statistical assessments and supervised the molecular analyses; de Almeida Costa CAR accompanied the experiments and contributed to the revision of the manuscript; Di Stasi LC is the senior author and designed the experiments, contributed to the drafting of the manuscript, supervised the entire work and gave final approval of the manuscript.

Supported by São Paulo Research Foundation (FAPESP), No. 11/50512-2 and No. 15/15267-8; Fellowships: Almeida-Junior from Coordination for the Improvement of Higher Education Personnel (Brazilian Ministry of Education); Costa from São Paulo Research Foundation (FAPESP); and Quaglio and Di Stasi from National Council for Scientific and Technological Development (CNPq - Brazilian Ministry of Science and Technology).

Institutional animal care and use committee statement: Approved by the Ethical Committee for Animal Research (Protocol number 042/04-CEEA), Institute of Biosciences, Universidade Estadual Paulista (UNESP).

Conflict-of-interest statement: The authors declare that they have no conflicts of interest.

Open-Access: This article is an open-access article which was selected by an in-house editor and fully peer-reviewed by external reviewers. It is distributed in accordance with the Creative Commons Attribution Non Commercial (CC BY-NC 4.0) license, which permits others to distribute, remix, adapt, build upon this

work non-commercially, and license their derivative works on different terms, provided the original work is properly cited and the use is non-commercial. See: <http://creativecommons.org/licenses/by-nc/4.0/>

Manuscript source: Invited manuscript

Correspondence to: Dr. Luiz Claudio Di Stasi, Professor, Laboratory of Phytomedicines, Pharmacology and Biotechnology (PhytoPharmaTech), Department of Pharmacology, Institute of Biosciences, Universidade Estadual Paulista UNESP, Botucatu, São Paulo, CEP 18618-970, Brazil. ldstasi@ibb.unesp.br
Telephone: +55-14-38800216
Fax: +55-14-38113744

Received: December 13, 2016

Peer-review started: December 14, 2016

First decision: February 9, 2017

Revised: February 25, 2017

Accepted: April 12, 2017

Article in press: April 12, 2017

Published online: June 28, 2017

Abstract

AIM

To investigate the effects of Ground Cherry (*Physalis angulata* L.) standardized supercritical CO₂ extract in trinitrobenzenesulphonic acid (TNBS) model of rat intestinal inflammation.

METHODS

The animals were divided into groups that received vehicle or *P. angulata* extract (PACO₂) orally at the doses 25, 50 and 100 mg/kg daily by 5 d before TNBS damage. Protective effects of PACO₂ were assessed by macroscopic analysis, biochemical determinations of the

levels of myeloperoxidase (MPO), alkaline phosphatase (ALP), glutathione and cytokines (such as INF- γ , IL-1 β , IL-6, IL-10 and TNF- α), gene expression evaluation (including Hsp70, heparanase, NF- κ B, mitogen-activated protein kinases (Mapk) 1, 3, 6 and 9, and the mucins genes Muc 1, 2, 3 and 4) and histopathological studies using optical, and electronic (transmission and scanning) microscopy.

RESULTS

PACO₂ extract promoted a significant reduction in MPO and ALP activities, reducing oxidative stress and neutrophil infiltration. These effects were accompanied by significant reduction of colonic levels of IFN- γ and IL-6 and down-regulation of heparanase, Hsp70, Mapk3, Mapk9, Muc1 and Muc2 genes expression when compared with TNBS-control animals. In addition, protective effects were also evidenced by reduced neutrophil infiltration, recovery of cell architecture and replacement of mucin by histopathological and ultrastructural analysis.

CONCLUSION

Physalis angulata supercritical CO₂ extract is an intestinal anti-inflammatory product that modulates oxidative stress, immune response and expression of inflammatory mediators, with potentially utility for treating inflammatory bowel disease.

Key words: Intestinal disease; Inflammatory bowel disease; *Physalis angulata* L. trinitrobenzenesulphonic acid

© The Author(s) 2017. Published by Baishideng Publishing Group Inc. All rights reserved.

Core tip: We report, at the first time, the protective effects of a supercritical CO₂ plant extract from aerial parts of Ground Cherry (*Physalis angulata* L.) in a model of intestinal inflammation induced by trinitrobenzenesulphonic acid in rats. The effects were related to presence of plant steroids, compounds chemically related to glucocorticoids, reference drugs used to treat human inflammatory bowel disease (IBD). The intestinal anti-inflammatory activity of *Physalis angulata* plant extract was related to its capacity to modulate oxidative stress, immune response and gene expression of inflammatory mediators. This way, the standardized plant extract of Ground Cherry enriched with phytosterols has potential for use to treat IBD.

Almeida Junior LD, Quaglio AEV, de Almeida Costa CAR, Di Stasi LC. Intestinal anti-inflammatory activity of Ground Cherry (*Physalis angulata* L.) standardized CO₂ phytopharmaceutical preparation. *World J Gastroenterol* 2017; 23(24): 4369-4380 Available from: URL: <http://www.wjgnet.com/1007-9327/full/v23/i24/4369.htm> DOI: <http://dx.doi.org/10.3748/wjg.v23.i24.4369>

INTRODUCTION

Inflammatory bowel diseases (IBD), comprising ulcerative colitis (UC) and Crohn's disease (CD), are diseases of modern society associated with a modern and urbanized lifestyle and caused by an increase in stress, bad diet habits and sedentariness^[1,2]. CD and UC are chronic inflammatory disorders affecting the gastrointestinal tract and are characterized by periods of exacerbation followed by prolonged intervals of remission of symptoms^[3,4]. The etiopathogenesis of these diseases has not been fully elucidated, but is presumed to result from a complex interplay among genetic, environmental, microbial and immune factors^[5]. An exaggerated and inappropriate mucosal immune response mediated by mucosal T cells triggers intense synthesis and release of several pro-inflammatory mediators, including reactive species of oxygen and nitrogen, and a multitude of pro- and anti-inflammatory cytokines^[6,7].

The available drugs, such as 5-aminosalicylate derivatives, glucocorticoids, immunosuppressive and monoclonal antibodies, have exhibited beneficial effects in the treatment of IBD, but do not represent a definitive cure. Indeed, these drugs have several side effects, and many patients do not respond to these treatments^[3,8,9]. Dissatisfaction with the current pharmacological treatments has resulted in an increased interest to use complementary medicine approaches, including medicinal plant extracts or natural active compounds^[10]. Based on this, our research group has been interested in studying the pharmacological activities of natural products against intestinal inflammation, focusing on tropical medicinal plants, of which Ground Cherry (*Physalis angulata* L.) was selected based upon its ethnopharmacological, pharmacological and chemical data.

Ground cherry is a native Brazilian weed from the Solanaceae family, which grows especially in the Brazilian Amazon Forest and other tropical countries of Africa, America and Asia, where it has been used traditionally as an anti-inflammatory herbal product and to treat several health disorders, such as cold, cough, fever, pain, malaria and nervous diseases^[11,12]. Fruits from the Ground Cherry are used as food in several countries, particularly as a sophisticated additive to salads. Reputed pharmacological effects, such as antinociceptive, immunosuppressive, anti-protozoal, antineoplastic and anti-inflammatory, have been associated with the constituent presence of sitosterol, stigmasterol and other phytosterols, representing the major components of the plant extract^[13-16].

Based on the ethnopharmacological data and pharmacological and chemical studies, a standardized CO₂ supercritical preparation from aerial parts of *P. angulata* containing 10%-18% of phytosterols was patented by our research group, claiming corticoid-like

effects evidenced by reduction of TNF- α , IL-6, IL-1 β and COX-2 levels in non-stimulated and stimulated human fibroblasts and keratinocytes^[17]. In the study presented herein, we evaluated this standardized plant extract from *P. angulata* in a model of intestinal inflammation induced by trinitrobenzenesulphonic acid (TNBS) in rats.

MATERIALS AND METHODS

Plant material and extract standardization

Physalis angulata L. was cultivated using organic agricultural methods and submitted to taxonomic identification at herbarium Irina Gemtchujnikov (Department of Botany, Institute of Biosciences, Universidade Estadual Paulista - UNESP/SP/BR), where a voucher specimen was deposited. The aerial parts were collected, dehydrated in hothouse with air circulation and renewal, and pulverized in an industrial mill.

A supercritical extraction system (Parker Autoclave Engineers, Erie, PA, United States), under the conditions of 300 bar, 40 °C and CO₂ flux of 5 L/min during 150 min, was used to generate a supercritical CO₂ extract enriched with phytosterols, including sitosterol, stigmasterol and physalins, which are the main constituents of *Physalis* plants. The enrichment of supercritical CO₂ extract was compared with water:butileneglycol 1:1 extract and evaluated by Liebermann-Burchard reaction and ultraviolet spectrometry at 621 nm (Hewlett-Packard, Palo Alto, CA, United States). *P. angulata* L. supercritical CO₂ extract (PACO₂) was standardized in 10%-18% of total phytosterols and provided by Chemyunion Química Ltda (Sorocaba, Brazil).

Animals

Male Wistar rats (180-200 g) obtained from ANILAB - Animais de Laboratório, Paulínia, São Paulo (Brazil), were housed in standard environmental conditions (21 °C, 60%-70% humidity) with 12-h light/dark cycle and air filtration. Animals had free access to water and food (Biobase). Experimental protocols met the "Guidelines of Animal Experimentation" approved by the Ethical Committee for Animal Research (Protocol number 042/04-CEEA), Institute of Biosciences, Universidade Estadual Paulista (UNESP).

Induction of colitis and assessment of the inflammatory process

Colitis was induced using the method originally described by Morris *et al.*^[18]. Briefly, animals were fasted overnight and then anaesthetized. Under anesthesia, they were inoculated with 10 mg of TNBS dissolved in 0.25 mL 50% ethanol (v/v), by means of a Teflon cannula inserted 8 cm into the anus. During and after the TNBS administration, the rats remained in a head-down position until they recovered from the

anesthesia.

Rats received 25, 50 or 100 mg/kg of the PACO₂ extract orally at 96, 72, 48, 24 and 2 h before colitis induction, using an esophageal catheter (volume: 10 mL/kg). Two additional groups were included for reference: a non-colitis group and a colitic group (TNBS-control group) that received vehicle (10 mL/kg methylcellulose) orally. The animal body weights, the occurrence of diarrhea (as detected by perianal fur soiling) and the total food intakes for each group were recorded daily. Animals from all groups ($n = 7$) were killed at 48 h after colitis induction.

The colonic segments were obtained after laparotomy and the adhesions eventual occurrence between the colon and adjacent organs were noted. These colonic segments were placed on an ice-cold plate, cleaned of fat and mesentery, blotted on filter paper, and then the colon was weighed and its length measured under a constant load (2 g). The colon was opened longitudinally and scored for macroscopically visible damage on a 0-10 scale, according to Bell *et al.*^[19]. Subsequently, the colon was longitudinally divided into different pieces to be used for the following determinations: myeloperoxidase (MPO), and alkaline phosphatase (ALP) activity, total glutathione (GSH) content, IL-1 β , IL-6, IL-10, TNF- α and INF- γ levels, and gene expression analysis.

Biochemical assays in colonic specimens

MPO activity was measured according to the technique described by Krawisz *et al.*^[20] and the results were expressed as MPO units per g of wet tissue. Total GSH content was quantified with the recycling assay^[21] and the results were expressed as nmol per g of wet tissue. ALP activity was measured spectrophotometrically, as previously described, and the results were expressed as mU per mg of protein^[22,23]. Quantification of cytokines (TNF- α , IL-1 β , IL-6, IL-10 and INF- γ) was made on colonic samples previously weighed, homogenized, minced on an ice-cold plate and resuspended in a centrifugation tube containing 10 mmol/L phosphate-buffered saline (pH 7.4; 1:5 w/v). The tubes were placed in a shaker submerged in a 37 °C water bath for 20 min and then centrifuged at 9000 *g* for 30 s at 4 °C. The supernatants were frozen at -80 °C until assayed. The TNF- α , IL-1 β , IL-6, IL-10 and INF- γ levels were quantified by a DuoSet ELISA Kit (R&D Systems, Inc., Minneapolis, MN, United States) to measure the concentration of the natural and recombinant rat enzyme according to the manufacturer's instructions. The results were expressed as pg per mL.

Gene expression analysis

Colon samples (100 mg) were collected and stored in -80 °C until use for analyses of genes: GAPDH, β -actin, HPRT, HSP70, heparanase, NF- κ B, mitogen-activated protein kinase (MAP)K1, MAPK3, MAPK6,

Table 1 Details of primers used for real-time PCR analysis

Target	Sequence	Annealing, °C	Oligo concentration, nmol/L	Fragment size, bp	NCBI reference sequence	cDNA concentration, µL
<i>GAPDH</i>	F TGA CTCTACCCACGGCAAGTTCAA R ACGACATACTCAGACCAGCATCA	60	200	141	NM_017008.3	1.000
<i>β-actin</i>	F TTGCTGACAGGATGCAGAAGGAGA R ACTCCTGCTTGCTGATCCACATCT	60	100	159	NM_031144.2	1.000
<i>HPRT</i>	F AGGGAAGTGACAATCTACCTGACG R GAAATGTCTGTTGCTGCGTCCCTT	60	100	81	AA900579.1	0.125
<i>HSP70</i>	F ACTCCTTCGTTCCGTTGCAATCA R CTGGGAATGCAAAGCACACGTGAA	60	200	92	NM_031971.2	0.125
<i>Heparanase</i>	F TGTCAAGAGTGAAAGGCCAGACA R GCAGCTCAAGTGCTTGGTGACAT	60	200	141	NM_022605.1	0.125
<i>NF-κB</i>	F AAACCAAAGCCCTGAAAGGCCATC R TCGGAAGGCCTCGAATGACATCAA	60	200	120	XM_342346.4	0.125
<i>MAPK1</i>	F AACAGTTGTTCCCAAACGCTGAC R AGTCGTCAGCTCCATGTCAAACCT	60	200	187	NM_053842.1	0.500
<i>MAPK3</i>	F TACCTGGACCAGCTCAACCACATT R AGCAGGTCAAGAGCTTTGGAGTCA	60	200	173	NM_017347.2	0.500
<i>MAPK6</i>	F AACTGAGCCAGTGGAAGAAGGGAA R TTAACGTGGCCTGGATGGACTTGA	60	200	164	NM_031622.2	1.000
<i>MAPK9</i>	F TCATGGGAGAGCTGGTGAAGGTT R ATGAACCTGCGGATGGTGTTCCT	60	200	106	NM_017322.2 NM_001270544.1 NM_001270545.1	1.000
<i>MUC1</i>	F CCGCTACTACCAAGAACTGAAG R GAGCCTGACCTGAACCTGATAG	60	200	102	NM_012602.1	0.500
<i>MUC2</i>	F GGCTCTGCTCTCTGTGTTATAG R CAGTTTGGGAAGAAGGTAGGG	60	200	123	U68172.1	1.000
<i>MUC3</i>	F GGGAATAGACCTGCAGTTAG R GATCATCGCTTGCCGTCATA	60	200	107	U76551.1	0.125
<i>MUC4</i>	F ATGTGGAGGTGGGAGAAATG R CCCTGGAACCTGGAATTAGAGAC	60	200	122	AF240632.1	0.500

MAPK9, MUC1, MUC2, MUC3, and MUC4. For the homogenization, we used 1 mL of Trizol[®] (Invitrogen-Life Technologies, Carlsbad, CA, United States) and a Polytron homogenizer. The total RNA extraction was made according to the Trizol[®] manufacturer's protocol. The purity was determined by A₂₆₀/A₂₈₀ ratio using a Nanodrop 2000 (Thermo Scientific, Waltham, MA, United States). After that, 1 µg of the total RNA of colon tissue samples was incubated with DNase I (1 U/mg RNA; Invitrogen), and then reverse transcribed with SuperScript[®] III (200 U/mL; Life Technologies) and oligo-d (T) primer. Primers for targets and reference genes were designed based on the rat sequences and using the IDT primer quest software (<http://www.idtdna.com/primerquest/Home/Index>; Invitrogen). Relative real-time RT-PCR analysis was performed with a StepOne Plus[™] (Applied Biosystems Inc., Foster City, CA, United States) using Power SYBR Green PCR Master Mix[®] (Life Technologies) for all the genes. Amplification efficiencies for target and reference genes were similar. The primer sequences, fragment size, annealing temperature, primer concentration, NCBI reference sequence and sample concentration for each gene are shown in Table 1.

Reactions were optimized to provide maximum amplification efficiency for each gene. PCR was performed in 25 µL reaction volumes in duplicate, in a MicroAmp[®] Fast Optical 96-Well Reaction Plate, 0.1 mL (Applied Biosystems Inc.), and the specificity of

each PCR product was determined by melting curve analysis. Negative controls (water replacing cDNA) were run in every plate.

The relative expression of each target gene was calculated using the $\Delta\Delta C_t$ method with efficiency correction^[24]; the control was a cDNA sample from each cell type analyzed. To select the most stable reference gene for detailed analyses, *glyceraldehyde-3-phosphate dehydrogenase (GAPDH)*, *β-actin* and *HPRT* amplification profiles were compared using the RefFinder software (<http://www.leonxie.com/referencegene.php?type=reference>). All gene expression analysis was performed with *β-actin* as the reference gene for colon tissue.

Histological evaluation and ultrastructure analysis

A representative colon fragment located 1 cm above the lesion was collected for histological slide preparation and stained with hematoxylin and eosin (HE) for analysis of the microscopic damage. Images were acquired using Zeiss Imager Axio Vision 4.8.2.0 software. Samples of the colon were fixed in 2.5% glutaraldehyde and 4% paraformaldehyde solutions in 0.1 mol/L phosphate buffer (pH 7.3) for transmission electron microscopy (TEM) analysis. Afterwards, the material was post-fixed in a 1% osmium tetroxide solution in 0.1 mol/L phosphate buffer (pH 7.3) at room temperature for 2 h, dehydrated through a graded series of acetone, and embedded in Araldite[®]

Table 2 Macroscopic effects of the PACO₂ standardized extract (25, 50 or 100 mg/kg) in acute phase response of intestinal inflammation induced by trinitrobenzenesulphonic acid

Group	Damage score, 0-10 ¹	Extension of lesion, cm ²	Colonic weight, mg/cm ²	Diarrhea ³	Adherence ³
Non-colitic	0 ^a	0 ^a	82.7 ± 2.10 ^a	0% ^a	0% ^a
TNBS-control	7 (2-8)	2.55 ± 0.28	136.0 ± 5.87	87.50%	81.25%
PACO ₂ - 25 mg/kg	7 (5-8)	2.44 ± 0.18	135.0 ± 6.86	100.00%	71.42%
PACO ₂ - 50 mg/kg	7 (2-9)	2.11 ± 0.34	124.0 ± 7.72	85.71%	71.42%
PACO ₂ - 100 mg/kg	7 (4-9)	2.93 ± 0.20	162.0 ± 5.04	100.00%	57.14%

¹Score data are expressed as the median (range); ²Extension of lesion and colonic weight data are expressed as the mean ± SE of the mean; ³Diarrhea and adherence were analyzed by Fisher's exact test. ^a*P* ≤ 0.01.

Table 3 Effects of the PACO₂ standardized extract (25, 50 or 100 mg/kg) on glutathione content, myeloperoxidase and alkaline phosphatase activities in acute phase response of intestinal inflammation induced by trinitrobenzenesulphonic acid

Group	GSH, nmol/g tissue	MPO, U/g tissue	ALP, mU/mg protein
Non-colitic	1687 ± 54.2 ^a	104 ± 13.7 ^a	8.91 ± 2.17 ^a
TNBS control	1295 ± 60	1703 ± 390	28.9 ± 3.07
PACO ₂ , 25 mg/kg	1208 ± 33.8	1360 ± 286	21.0 ± 2.44
PACO ₂ , 50 mg/kg	1350 ± 85.1	921 ± 181	18.0 ± 1.62 ^c
PACO ₂ , 100 mg/kg	1428 ± 50.6	831 ± 108 ^c	19.5 ± 1.50 ^c

Data are expressed as mean ± standard error of the mean. ^a*P* ≤ 0.05 and ^a*P* ≤ 0.01. GSH: Glutathione; MPO: Myeloperoxidase; ALP: Alkaline phosphatase.

resin. Ultra-thin sections (70 nm) were double-stained with uranyl acetate and lead citrate. All samples were analyzed and images were acquired using a Tecnai Spirit TEM from Fei Company, 80 kV. For scanning electron microscopy (SEM) analysis, small fragments of the colon were fixed in a 2.5% glutaraldehyde solution in 0.1 mol/L phosphate buffer (pH 7.3) and post-fixed in 1% osmium tetroxide in 0.1 mol/L phosphate buffer (pH 7.3) at room temperature for 2 h. Samples were dehydrated through the serial application of increasingly concentrated ethanol, critical point-dried with liquid CO₂, and sputter-coated with gold (10 nm). All samples were analyzed and images were acquired using a QUANTA 200 SEM from Fei Company, 80 kV.

Statistical analysis

The parametric results are expressed as the mean ± SE of the mean, and the differences between means were tested for statistical significance using one-way analysis of variance followed by Dunnett's post-test. Nonparametric data (score) are expressed as the median (range) and were analyzed with the Kruskal-Wallis test, followed by Dunn post-test. Differences between proportions were analyzed by Fisher's exact test. Statistical significance was set at *P* ≤ 0.05.

RESULTS

TNBS instillation resulted in colonic inflammation,

which was evidenced after 48 h by severe necrosis of the mucosa (extending for 2 to 3 cm along the colon), hyperemia, significant increase in the colonic weight/length ratio, incidence of diarrhea and adherence to adjacent organs (Table 2). These effects were related to significant reduction in both body weight and food intake (data not shown).

Biochemically, the colonic damage induced by TNBS was characterized by increased activities of MPO (13-fold) and ALP (4-fold) and high levels of colonic TNF-α, IL-1β, IL-6, IFN-γ and IL-10 compared with healthy animals. Furthermore, significant colonic GSH depletion took place in the inflamed colon.

Administration of *P. angulata* extract (PACO₂) at the doses of 50 and 100 mg/kg decreased ALP activity relative to TNBS-control group. Reduction of INF-γ and IL-6 colonic levels, and MPO activity were observed after treatment with 50 and 100 mg/kg, respectively. The 25 mg/kg dose of PACO₂ did not alter any cytokine analyzed (Tables 3 and 4).

Expression of genes involved in the inflammatory process (Hpse, Hsp70, Mapk1, Mapk3, Mapk6, Mapk9, and NF-κB) and genes involved in the protective functions (Muc1, Muc2, Muc3, and Muc4) were differentially affected by the plant extract treatment. PACO₂ was able to diminish the expression of Hsp70, Mapk3, Mapk9, Muc1, and Muc2 at doses of 25, 50 and 100 mg/kg and Hpse at doses of 25 and 100 mg/kg, as compared with the TNBS-control group (Figure 1).

Histopathological evaluation demonstrated that treatments with PACO₂ led to improved colon cytoarchitecture, including the restoration of tubular glands containing goblet cells, especially at the doses of 50 mg/kg and 100 mg/kg; moreover, edema was significantly reduced, as compared to the TNBS-control group (Figure 2). In SEM, PACO₂ at a dose of 25 mg/kg showed a slight recovery of the polygonal shape of absorptive cells; however, the number of goblet cells remained elevated. At a dose of 50 mg/kg, a greater recovery of polygonal appearance and increase of the main was observed compared to the TNBS-control group. PACO₂ at a dose of 100 mg/kg exhibited a good recovery of mucosal architecture, with goblet cells similar to healthy animals, including crypts and mucin (Figure 3). In transmission ultrastructure analysis, reduced

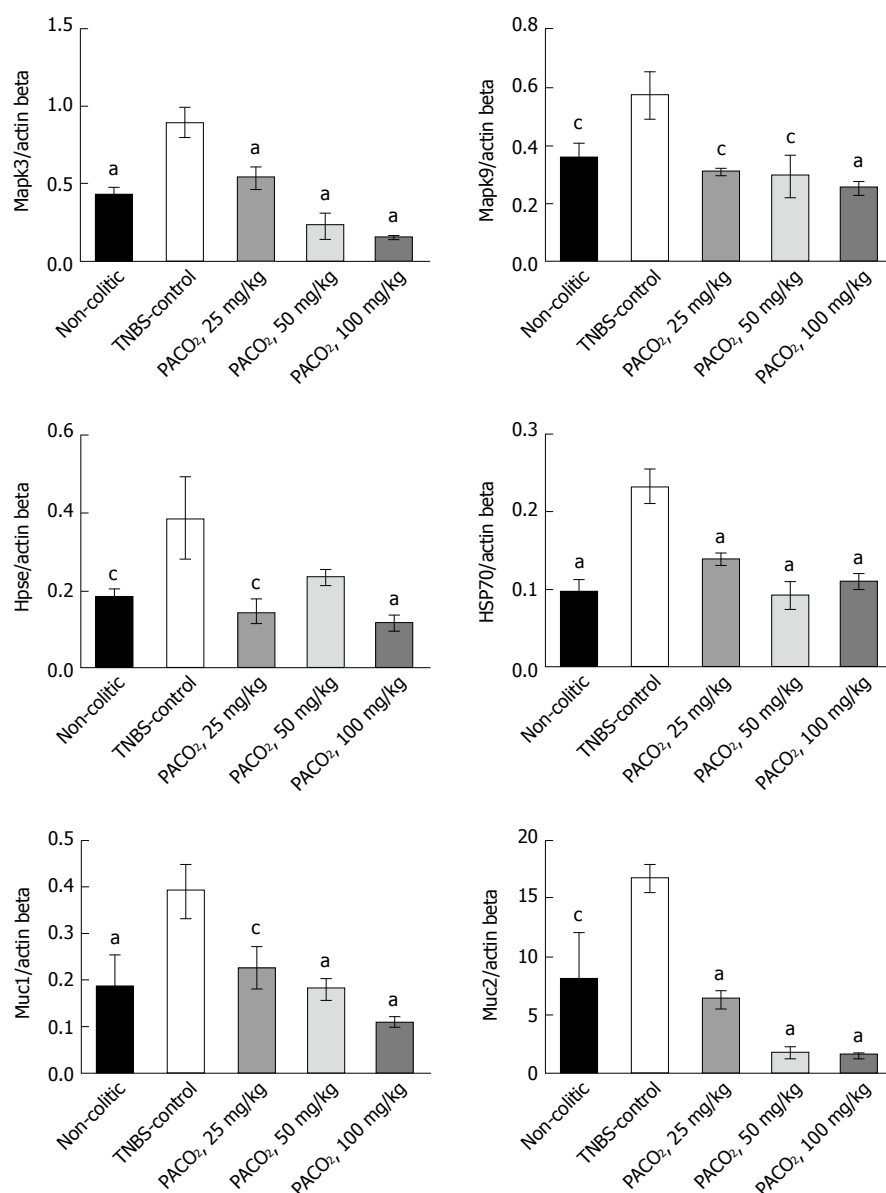


Figure 1 Effects of the PACO₂ standardized extract (25, 50 or 100 mg/kg) in the gene expression of *Mapk3*, *Mapk9*, *heparanase*, *Hsp70*, *Muc1* and *Muc2* in acute phase response of intestinal inflammation induced by trinitrobenzenesulphonic acid. Data are expressed as mean ± standard error of the mean. ^cP ≤ 0.05, ^aP ≤ 0.01 vs TNBS control group.

Table 4 Effects of the PACO₂ standardized extract (25, 50 or 100 mg/kg) on cytokine levels in acute phase response of intestinal inflammation induced by trinitrobenzenesulphonic acid

Group	IFN- γ	TNF- α	IL1- β	IL-6	IL-10
Non-colitic	78.2 ± 7.9 ^c	121.2 ± 7.0 ^a	1395.0 ± 136.9 ^a	421.1 ± 45.3 ^a	467.1 ± 31.1 ^a
TNBS control	125 ± 20.4	240.3 ± 34.3	2205.0 ± 147.4	893.8 ± 105.5	675.5 ± 38.6
PACO ₂ 25 mg/kg	92.1 ± 8.6	246.6 ± 34.3	1867.0 ± 221.4	891.9 ± 87.09	674.5 ± 40.4
PACO ₂ 50 mg/kg	67 ± 11.7 ^c	167.9 ± 23.6	2106.0 ± 128.9	563.4 ± 55.5 ^c	626.9 ± 66.5
PACO ₂ 100 mg/kg	76.4 ± 12.7 ^c	205.5 ± 34.5	2323.0 ± 154.1	649.5 ± 86.9	537.4 ± 41.1

Data are expressed as mean ± SE of the mean. ^cP ≤ 0.05 and ^aP ≤ 0.01.

mucin granules were observed in colonic goblet cells at a dose of 25 mg/kg, but the intercellular edema was lower. Already at dose of 50 mg/kg, the colonocytes are juxtaposed with nucleus in basal

position and preserved microvilli. The 100 mg/kg-treated group showed goblet cells with mucus granules similar to healthy animals, the nucleus in basal position, mild intercellular edema and atypical

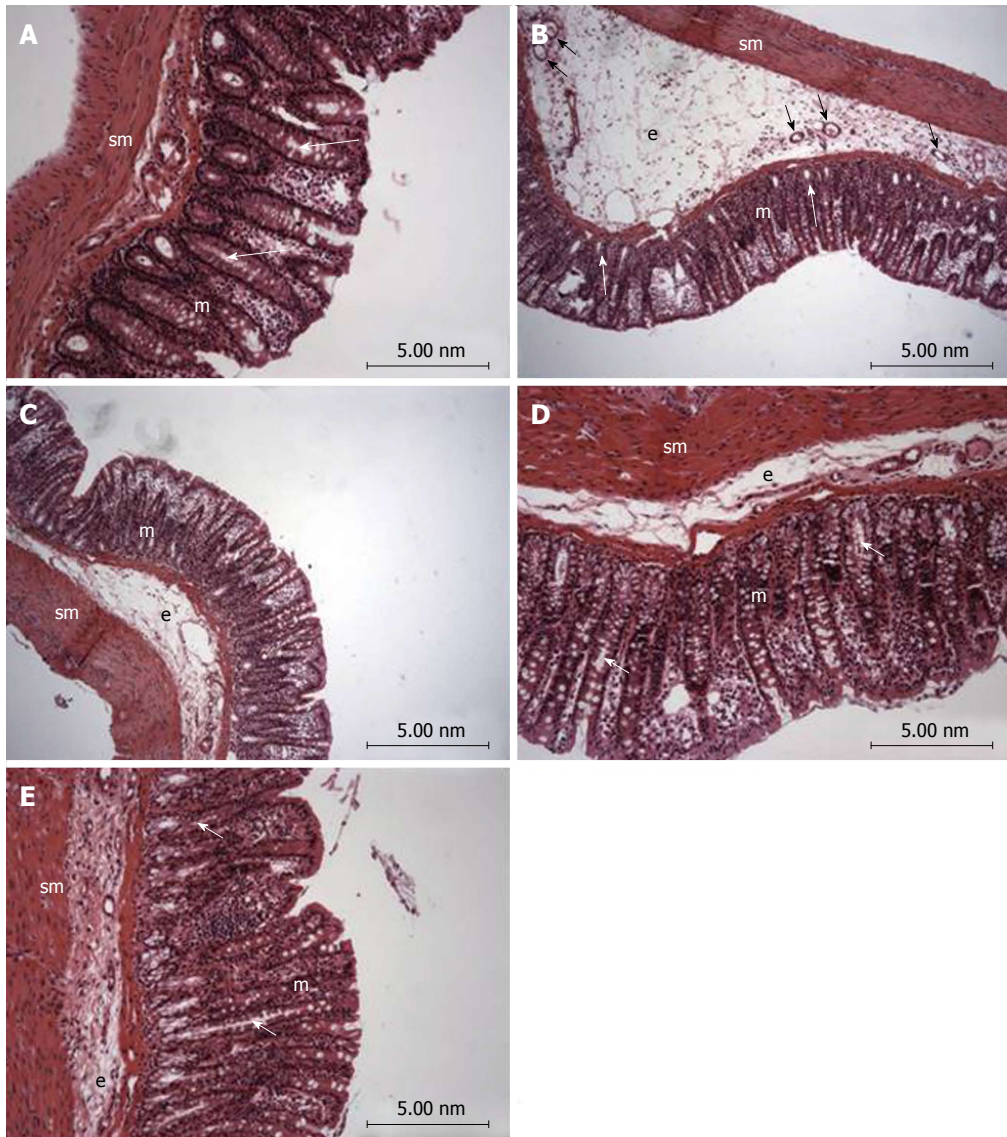


Figure 2 Photomicrography (hematoxylin and eosin) of colon samples from different experimental groups. Mucosa (m), tubular glands (white arrows), blood vessels (black arrow), submucosa (sm) and edema (e). In A (non-colitic group): the mucosa (m) contains numerous straight tubular glands (white arrows) with many lightly stained goblet cells; the crypt (black arrow), submucosa (sm) and luminal epithelium was intact with a typical morphology; In B (TNBS control group): tubular glands (white arrows) were reduced and the goblet cells were atypical; a disruption with extensive edema (e) and blood vessels (black arrow) can be observed. In PACO₂-treated groups, colon cytoarchitecture was recovering and included the restoration of tubular glands (white arrows) containing goblet cells, especially at the doses of 50 mg/kg (D) and 100 mg/kg (E); edema (e) was significantly reduced in animals treated with at doses of 50 mg/kg (D) and 100 mg/kg (E) and in a lower proportion in animals treated with doses of 25 mg/kg (C), when compared to the TNBS control group (B).

microvilli (Figure 4).

DISCUSSION

The combination of products that improve the anti-inflammatory activity of drugs would be an important approach for IBD treatment, since the current pharmacological treatments for IBD, including aminosalicylates, corticosteroids, biological agents and immunosuppressant, result in serious side effects and most patients do not respond to these therapies^[3,8,9]. The results of this study showed that a phytosterol standardized extract obtained from aerial parts of *P. angulata* improved the response of animals throughout the duration of intestinal damage induced by TNBS,

modulating oxidative stress, immune response and inflammatory genes expression.

The biochemical changes that occur after administration of TNBS were similar to what occurs in humans, mainly excessive production of reactive oxygen and nitrogen metabolites^[25]. Neutrophils are responsible for tissue injury in inflammatory diseases, producing free radicals and hypochlorous acid that increase the local oxidative stress and cause damage^[26]. In this process, MPO plays a central role, generating reactive intermediates (primarily hypochlorous acid) and leading to oxidative damage of lipids and proteins, thereby acting as an enzyme strongly linked to both inflammation and oxidative stress^[27]. Indeed, MPO acts as an inflammatory




Figure 3 Electromicrographs (scanning electron microscopy) of colon samples from different experimental groups. Crypts (white arrows), goblet cells (black arrows) and mucin (m). In A (non-colitic group): regular mucosal architecture with polygonal units as structural subunits, regular microvilli giving a smooth velvety appearance, crypts (white arrows), goblet cells (black arrows) and mucin (m) extruded; In B (TNBS control group): complete loss of the smooth velvety appearance and polygonal shape of absorptive cells, hyperplasia of goblet cells (white arrows), absence of mucin extrusion and crypts, characteristics of ulcerative colitis and Crohn's disease; In C (PACO₂ 25 mg/kg-treated group): slight recovery of polygonal shape (black arrows) of absorptive cells, however the number of goblet cells remained elevated; In D (PACO₂ 50 mg/kg-treated group): smaller number of goblet cells, greater recovery of polygonal appearance (black arrows) and increased mucin (m) compared to TNBS control group; In E (PACO₂ 100mg/kg-treated group): good recovery of mucosa architecture, with goblet cells (black arrows) similar to healthy animals including crypts (white arrows) and mucin (m) for protection.

marker, so that activity reduction of this enzyme is also related to lower cellular infiltration into the colon.

ALP is also a sensitive inflammatory process biochemical marker, which is increased as a consequence of tissue-non-specific isoform and associated with an influx of inflammatory cells^[28,29]. However, studies suggest that ALP release occurs as a consequence of lipid peroxidation of membranes^[30]. Although oxidative stress can also be measured by GSH levels (the first line of defense against the toxic products of oxygen and other hydroperoxides^[31,32]), PACO₂ at the tested dose was ineffective for avoiding the GSH depletion induced by inflammatory process. Nevertheless, the inhibitory effects on the MPO and ALP activity can be interpreted either by antioxidant or anti-inflammatory properties of the PACO₂.

The focus on the adaptive immune response in IBD led to a consensus that the mucosa is dominated by CD4+ (Th1) lymphocyte phenotypes, characterized by the production of IFN- γ ^[33]. Immune response in the colon after TNBS administration is also characterized by increased production of IFN- γ ^[34]. The increased synthesis of IFN- γ has been associated with the aggravation of disease in patients with IBD^[35]. IL-6 plays a central role in diverse inflammatory responses *via* recruiting CD4 (Th17) lymphocyte phenotypes, so

it is evident that neutralization of IL-6 has a beneficial effect on intestinal inflammation, acting in tissue remodeling and neutrophil infiltration^[35-37]. Our results showed that PACO₂ anti-inflammatory properties were also related to down-regulation of colonic IFN- γ and IL-6 levels; but, at the tested doses, no effects were observed on other cytokines, such as TNF- α , IL-1 β and IL-10.

The genetic profiling identified a number of genes or genetic loci that have been associated with IBD conditions, and many of these genes are directly related to signaling pathways that regulate the innate and adaptive immune systems, triggering complex intracellular cascades^[38,39]. One of these ways of controlling signaling are MAPKs, an evolutionarily conserved family of serine/threonine kinases involved in a wide range of biological processes, such as cell growth, proliferation, differentiation, migration and apoptosis^[40,41]. Studies show that Mapk1 and Mapk3 were significantly expressed in animals from the TNBS-control group, indicating that these genes play a significant role in the inflammation caused by TNBS, and are expressed in the active phases of IBD^[38,42]. Indeed, evidence has shown that Mapk3 activation plays an essential role in the signaling mechanisms that lead to increased neutrophil adhesion^[43]. Our data

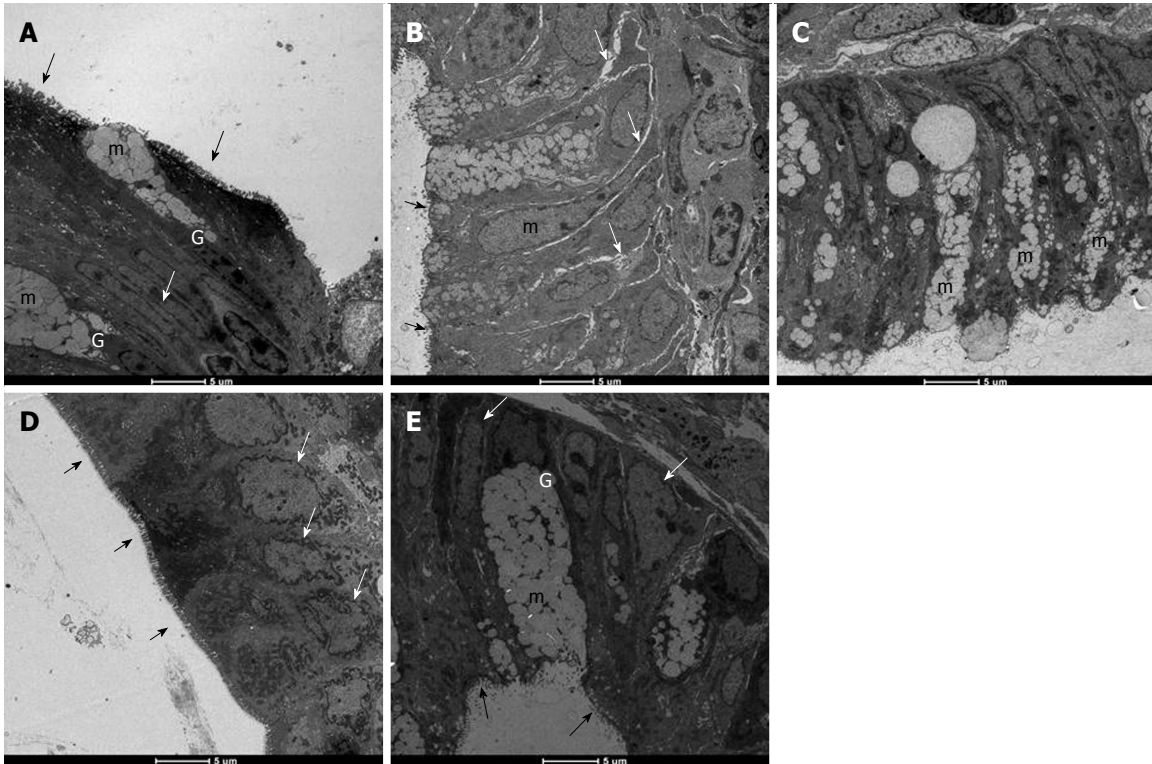


Figure 4 Electromicrographs (transmission electron microscopy) of colon samples from different experimental groups. Goblet cells (G), mucus granules (m); Microvilli (black arrows); nucleus in a basal position (white arrow); edema (grey arrows). In A (non-colitic group): colonic goblet cells (G) showing the mucus granules (m); absorptive epithelial cells with a well-developed brush border containing numerous regular microvilli (black arrows) typical of enterocytes and its nucleus in a basal position (n) shows chromatin (white arrow); In B (TNBS control group): mucin granules in colonic goblet cells are reduced and disarranged (m); surface cells have no distinct brush border with atypical microvilli (black arrow); the intercellular space was enhanced as a signal of edema (white arrows); In C (PACO₂ 25 mg/kg-treated group): mucin granules in colonic goblet cells are reduced and disarranged (m), but intercellular edema is reduced (white arrows); In D (PACO₂ 50 mg/kg-treated group): juxtaposed colonocytes with nucleus in basal position (white arrows) and preserved microvilli (black arrows); In E (PACO₂ 100 mg/kg-treated group): goblet cells (G) showing the mucus granules (m) similar to healthy animals; nucleus in basal position (yellow arrows); mild intercellular edema and atypical microvilli (black arrows).

showed that PACO₂ decreased expression of Mapk3 genes, probably contributing to the reduced neutrophil infiltration evidenced by histopathological analysis. In fact, reduced neutrophil infiltration promoted by PACO₂ can be closely associated to inhibition of MPO activity and reduction of IL-6 colonic levels.

Another kinase that has the ability to phosphorylate other protein targets is Mapk9, also known as JNK2^[38]. In our research, we found increased Mapk9 gene expression after TNBS administration, indicating a participation of this MAPK in the development of inflammation. Mapk9 has been implicated as an important regulator of cytokine release and in the response of the neutrophils to release inflammatory stimuli^[44]. Indeed, a specific inhibitor of Mapk9 in the murine IBD model reduced production of inflammatory cytokines, including IFN- γ and IL-6^[45]. This way, it is possible to suggest that modulatory effects of PACO₂ on cytokine production was dependent of down-regulation of Mapk9 gene expression.

A complex network involving heparanase and other inflammatory pathways, such as hsp70 and NF- κ B, has been proposed to explain the immunomodulatory response in inflammatory conditions^[46,47]. Heparanase has an important role in body physiology and

inflammatory responses, where its expression is an important mechanism underlying chronic colonic inflammation^[48]. In fact, it has been hypothesized that heparanase activates macrophages, increasing NF- κ B signaling and releasing several cytokines and reactive oxygen species, as well as heparanase, *via* TNF- α -dependent mechanisms, promoting disruption of the cell membrane^[46-49].

Recently, the relationship among heparanase, hsp70, NF- κ B and cytokine profile was identified by our research group in the TNBS-model of intestinal inflammation, demonstrating the pharmacological importance of the heparanase modulation as a target of new drugs^[50]. Indeed, in the complex inflammatory response, heat shock proteins have been implicated in the pathogenesis of IBD, mainly Hsp70 that confers resistance to various tissues and are synthesized rapidly after exposure to the offending agent, being useful in maintaining homeostasis, facilitating the repair of damaged areas and providing protection against injuries^[51,52]. According to results, the anti-inflammatory properties of PACO₂ were closely related to inhibitory gene expression of both heparanase and Hsp70, leading to a lower colonic damage as observed by histopathological analysis.

Another important factor related to gut homeostasis is mucus production, responsible for formation of gel layers covering the gastrointestinal tract and providing a semi-permeable barrier between the lumen and the epithelium^[53]. The mucus gel barrier, formed by building blocks of mucins, which determine the thickness and properties of mucus, contributes to maintaining the integrity of the epithelium in the colon and plays a key role in IBD^[53,54]. In small and large intestine, Muc2 is the major secretory mucin synthesized and secreted by goblet cells, whereas goblet and absorptive cells express the membrane-bound mucins Muc1, Muc3, Muc4 and Muc13 in the apical membrane^[53-55]. Although the hypothesis that mucins and mucus barrier are protective factors in IBD is difficult to prove in humans, animal models, including the TNBS model, permit detailed analysis of the role of mucins in intestinal inflammation. In fact, our results showed that TNBS increased colonic Muc1 and Muc2 expression, probably as a response against inflammatory process and to maintain the mucosal barrier integrity^[56]. Although PACO₂ reversed these effects, an increased production of mucus was observed by histopathological analysis and was clearly evidenced in the TEM and SEM studies.

The main structural damage induced by TNBS was detected by histopathological analysis, and included membrane disruption, reduction in mucus production and increase of inflammatory cells. These effects were clearly related to reduction in MPO activity and modulation of IL-6 and INF- γ , whereas membrane integrity was affected by heparanase and Hsp70 up-regulation. These damaged effects were completely reversed by treatment with different doses of PACO₂, which acted as an anti-inflammatory agent modulating oxidative stress, immune response and inflammatory gene expression.

All protective effects produced by PACO₂ can be partially attributed to presence of phytosterols in the standardized plant extract, natural compounds with several pharmacological activities able to regulate the balance of Th1 and Th2 response, and inhibition of nitric oxide production, TNF- α and IFN- γ ^[9,57]. The main group of sterols in this plant are the seco-sterols (named physalins) and molecules derived from ergostane^[9,58], which were identified as active compounds from *P. angulata*, reducing vascular permeability, neutrophil infiltration^[59], inflammatory cytokine production such as of IFN- γ and IL-6, and modulating the expression of Mapks^[60], as observed in our experiments. Indeed, administration of seco-sterols of *P. angulata* has been useful to treat autoimmune diseases, allergies or in cases of transplant rejection with lower toxicity when compared to glucocorticoids^[59]. These studies showed that phytosterols of *P. angulata* are promising compounds for treatment of inflammatory diseases, suggesting that the search for new natural compounds similar to steroids such as glucocorticoids is a promising field of

research to obtain new drugs with efficacy and safety.

In conclusion, the standardized extract of *P. angulata* L.-PACO₂-exerts intestinal anti-inflammatory effect by modulating a series of pathways and mediators of the inflammatory response, mainly related to oxidative stress and immune response. These effects were related to the presence of phytosterols, natural compounds structurally related to steroids, which are promising substances for the treatment of inflammatory diseases. In this way, PACO₂ from *Physalis angulata* is an innovative active ingredient and a phytopharmaceutical preparation with potential clinical applications in the control of intestinal inflammation.

ACKNOWLEDGMENTS

The authors acknowledge technical support provided by Aline W Fantinati, Alexandre S Chagas, Alexandre Tanimoto, Adriana Del Ben, Tainan FS Curimbaba, Juliana Severi e Juliana R Ribeiro. Chemyunion Chemistry provided us with the standard extract of *Physalis angulata* (PACO₂).

COMMENTS

Background

Inflammatory bowel disease (IBD) is a chronic inflammatory process of the gut, including two different disorders: ulcerative colitis and Crohn's disease. Nowadays, the search for new drugs to treat IBD is based in immunomodulators, modulators of intestinal microbiota and antioxidative natural and synthetic compounds. This manuscript describes a study of a potential product for use as complementary therapy based on a phytopharmaceutical preparation with Ground Cherry (*Physalis angulata*), a rich phytosterols medicinal plant.

Research frontiers

The study demonstrated that a CO₂ supercritical herbal preparation containing steroidal natural compounds produces a potent intestinal anti-inflammatory activity. These data open a new perspective for use of supercritical extraction method as well as for the study of phytosterols as active components with intestinal anti-inflammatory effects.

Innovations and breakthroughs

Several medicinal plants have been studied as immunomodulators in several chronic diseases, but this research is the first to investigate Ground Cherry using a supercritical carbon dioxide extraction and fractionation for its effects on chemically-induced intestinal inflammation.

Applications

The main application of these data is their potential application as a phytopharmaceutical preparation complementary to current drugs to treat IBD.

Peer-review

This is very well done study, very supported, results are excellent, and observations do support the conclusion. The article is good work, perfectly analyzed, presented the results and discussed them perfectly.

REFERENCES

- 1 Danese S, Fiocchi C. Ulcerative colitis. *N Engl J Med* 2011; **365**: 1713-1725 [PMID: 22047562 DOI: 10.1056/NEJMra1102942]

- 2 **Crohn BB**, Ginzburg L, Oppenheimer GD. Regional ileitis: a pathologic and clinical entity. 1932. *Mt Sinai J Med* 2000; **67**: 263-268 [PMID: 10828911]
- 3 **Pithadia AB**, Jain S. Treatment of inflammatory bowel disease (IBD). *Pharmacol Rep* 2011; **63**: 629-642 [PMID: 21857074]
- 4 **Gitnick G**. Inflammatory bowel disease: a new assessment. *Scand J Gastroenterol Suppl* 1996; **220**: 83-86 [PMID: 8898442]
- 5 **Witaicenis A**, Luchini AC, Hiruma-Lima CA, Felisbino SL, Garrido-Mesa N, Utrilla P, Gálvez J, Di Stasi LC. Suppression of TNBS-induced colitis in rats by 4-methylesculetin, a natural coumarin: comparison with prednisolone and sulphasalazine. *Chem Biol Interact* 2012; **195**: 76-85 [PMID: 22119283 DOI: 10.1016/j.cbi.2011.11.004]
- 6 **Tang C**, Chen S, Qian H, Huang W. Interleukin-23: as a drug target for autoimmune inflammatory diseases. *Immunology* 2012; **135**: 112-124 [PMID: 22044352 DOI: 10.1111/j.1365-2567.2011.03522.x]
- 7 **Múzes G**, Molnár B, Tulassay Z, Sipos F. Changes of the cytokine profile in inflammatory bowel diseases. *World J Gastroenterol* 2012; **18**: 5848-5861 [PMID: 23139600 DOI: 10.3748/wjg.v18.i41.5848]
- 8 **Yamamoto T**, Nakahigashi M, Saniabadi AR. Review article: diet and inflammatory bowel disease--epidemiology and treatment. *Aliment Pharmacol Ther* 2009; **30**: 99-112 [PMID: 19438426 DOI: 10.1111/j.1365-2036.2009.04035.x]
- 9 **Morrison G**, Headon B, Gibson P. Update in inflammatory bowel disease. *Aust Fam Physician* 2009; **38**: 956-961 [PMID: 20369146]
- 10 **Kong SC**, Hurlstone DP, Pocock CY, Walkington LA, Farquharson NR, Bramble MG, McAlindon ME, Sanders DS. The Incidence of self-prescribed oral complementary and alternative medicine use by patients with gastrointestinal diseases. *J Clin Gastroenterol* 2005; **39**: 138-141 [PMID: 15681910]
- 11 **Di Stasi LC**, Hiruma CA, Guimarães EM, Santos CM. Medicinal Plants popularly used in brazilian amazon. *Fitoterapia* 1994; **65**: 529-540
- 12 **Richter RK**, Carlson TJ. Reporting biological assay results on tropical medicinal plants to host country collaborators. *J Ethnopharmacol* 1998; **62**: 85-88 [PMID: 9720617]
- 13 **Jin Z**, Mashuta MS, Stolorow NJ, Vaisberg AJ, Stivers NS, Bates PJ, Lewis WH, Hammond GB. Physangulidines A, B, and C: three new antiproliferative withanolides from *Physalis angulata* L. *Org Lett* 2012; **14**: 1230-1233 [PMID: 22329497 DOI: 10.1021/ol203498a]
- 14 **Lima Mda S**, Evangelista AF, Santos GG, Ribeiro IM, Tomassini TC, Pereira Soares MB, Villarreal CF. Antinociceptive properties of physalins from *Physalis angulata*. *J Nat Prod* 2014; **77**: 2397-2403 [PMID: 25396337 DOI: 10.1021/np5003093]
- 15 **Wu SY**, Leu YL, Chang YL, Wu TS, Kuo PC, Liao YR, Teng CM, Pan SL. Physalin F induces cell apoptosis in human renal carcinoma cells by targeting NF-kappaB and generating reactive oxygen species. *PLoS One* 2012; **7**: e40727 [PMID: 22815798 DOI: 10.1371/journal.pone.0040727]
- 16 **Yu Y**, Sun L, Ma L, Li J, Hu L, Liu J. Investigation of the immunosuppressive activity of Physalin H on T lymphocytes. *Int Immunopharmacol* 2010; **10**: 290-297 [PMID: 19951747 DOI: 10.1016/j.intimp.2009.11.013]
- 17 **Velasquez Pereda MC**, Nogueira C, de Campos Diemant G, Berlin S, Mussi L, De Tarso Vieira e Rosa P, Polezel MA, inventors. Brazil. 2009
- 18 **Morris GP**, Beck PL, Herridge MS, Depew WT, Szwczuk MR, Wallace JL. Hapten-induced model of chronic inflammation and ulceration in the rat colon. *Gastroenterology* 1989; **96**: 795-803 [PMID: 2914642]
- 19 **Bell CJ**, Gall DG, Wallace JL. Disruption of colonic electrolyte transport in experimental colitis. *Am J Physiol* 1995; **268**: G622-G630 [PMID: 7733288]
- 20 **Krawisz JE**, Sharon P, Stenson WF. Quantitative assay for acute intestinal inflammation based on myeloperoxidase activity. Assessment of inflammation in rat and hamster models. *Gastroenterology* 1984; **87**: 1344-1350 [PMID: 6092199]
- 21 **Anderson ME**. Determination of glutathione and glutathione disulfide in biological samples. *Methods Enzymol* 1985; **113**: 548-555 [PMID: 4088074]
- 22 **Bessey OA**, Lowry OH, Brock MJ. A method for the rapid determination of alkaline phosphates with five cubic millimeters of serum. *J Biol Chem* 1946; **164**: 321-329 [PMID: 20989492]
- 23 **Smith GP**, Harris H, Peters TJ. Studies of the biochemical and immunological properties of human neutrophil alkaline phosphatase with comparison to the established alkaline phosphatase isoenzymes. *Clin Chim Acta* 1984; **142**: 221-230 [PMID: 6499206]
- 24 **Pfaffl MW**. A new mathematical model for relative quantification in real-time RT-PCR. *Nucleic Acids Res* 2001; **29**: e45 [PMID: 11328886]
- 25 **Kruidenier L**, Verspaget HW. Antioxidants and mucosa protectives: realistic therapeutic options in inflammatory bowel disease? *Mediators Inflamm* 1998; **7**: 157-162 [PMID: 9705602 DOI: 10.1080/09629359891081]
- 26 **Dhiman M**, Estrada-Franco JG, Pando JM, Ramirez-Aguilar FJ, Spratt H, Vazquez-Corzo S, Perez-Molina G, Gallegos-Sandoval R, Moreno R, Garg NJ. Increased myeloperoxidase activity and protein nitration are indicators of inflammation in patients with Chagas' disease. *Clin Vaccine Immunol* 2009; **16**: 660-666 [PMID: 19297613 DOI: 10.1128/CVI.00019-09]
- 27 **Karakas M**, Koenig W. Myeloperoxidase production by macrophage and risk of atherosclerosis. *Curr Atheroscler Rep* 2012; **14**: 277-283 [PMID: 22407325 DOI: 10.1007/s11883-012-0242-3]
- 28 **Sánchez de Medina F**, Vera B, Gálvez J, Zarzuelo A. Effect of quercitrin on the early stages of hapten induced colonic inflammation in the rat. *Life Sci* 2002; **70**: 3097-3108 [PMID: 12008093]
- 29 **Tuin A**, Poelstra K, de Jager-Krikken A, Bok L, Raaben W, Velders MP, Dijkstra G. Role of alkaline phosphatase in colitis in man and rats. *Gut* 2009; **58**: 379-387 [PMID: 18852260 DOI: 10.1136/gut.2007.128868]
- 30 **Dalakioglu S**, Genc GE, Aksoy NH, Akcıt F, Gumuslu S. Resveratrol ameliorates methotrexate-induced hepatotoxicity in rats via inhibition of lipid peroxidation. *Hum Exp Toxicol* 2013; **32**: 662-671 [PMID: 23424212 DOI: 10.1177/0960327112468178]
- 31 **DeLeve LD**, Kaplowitz N. Glutathione metabolism and its role in hepatotoxicity. *Pharmacol Ther* 1991; **52**: 287-305 [PMID: 1820580]
- 32 **Masella R**, Di Benedetto R, Vari R, Filesi C, Giovannini C. Novel mechanisms of natural antioxidant compounds in biological systems: involvement of glutathione and glutathione-related enzymes. *J Nutr Biochem* 2005; **16**: 577-586 [PMID: 16111877 DOI: 10.1016/j.jnutbio.2005.05.013]
- 33 **Corridoni D**, Arseneau KO, Cominelli F. Inflammatory bowel disease. *Immunol Lett* 2014; **161**: 231-235 [PMID: 24938525 DOI: 10.1016/j.imlet.2014.04.004]
- 34 **Strober W**, Fuss IJ, Blumberg RS. The immunology of mucosal models of inflammation. *Annu Rev Immunol* 2002; **20**: 495-549 [PMID: 11861611 DOI: 10.1146/annurev.immunol.20.100301.064816]
- 35 **Sanchez-Munoz F**, Dominguez-Lopez A, Yamamoto-Furusho JK. Role of cytokines in inflammatory bowel disease. *World J Gastroenterol* 2008; **14**: 4280-4288 [PMID: 18666314 DOI: 10.3748/wjg.14.4280]
- 36 **Yen D**, Cheung J, Scheerens H, Poulet F, McClanahan T, McKenzie B, Kleinschek MA, Owyang A, Mattson J, Blumenschein W, Murphy E, Sathe M, Cua DJ, Kastelein RA, Rennick D. IL-23 is essential for T cell-mediated colitis and promotes inflammation via IL-17 and IL-6. *J Clin Invest* 2006; **116**: 1310-1316 [PMID: 16670770 DOI: 10.1172/jci21404]
- 37 **Shen W**, Durum SK. Synergy of IL-23 and Th17 cytokines: new light on inflammatory bowel disease. *Neurochem Res* 2010; **35**: 940-946 [PMID: 19915978 DOI: 10.1007/s11064-009-0091-9]
- 38 **Broom OJ**, Widjaya B, Troelsen J, Olsen J, Nielsen OH. Mitogen activated protein kinases: a role in inflammatory bowel disease?

- Clin Exp Immunol* 2009; **158**: 272-280 [PMID: 19793335 DOI: 10.1111/j.1365-2249.2009.04033.x]
- 39 **Xavier RJ**, Podolsky DK. Unravelling the pathogenesis of inflammatory bowel disease. *Nature* 2007; **448**: 427-434 [DOI: 10.1038/nature06005]
 - 40 **Dhillon AS**, Hagan S, Rath O, Kolch W. MAP kinase signalling pathways in cancer. *Oncogene* 2007; **26**: 3279-3290 [PMID: 17496922 DOI: 10.1038/sj.onc.1210421]
 - 41 **Chang L**, Karin M. Mammalian MAP kinase signalling cascades. *Nature* 2001; **410**: 37-40 [PMID: 11242034 DOI: 10.1038/35065000]
 - 42 **Quaglio AE**, Castilho AC, Di Stasi LC. Experimental evidence of MAP kinase gene expression on the response of intestinal anti-inflammatory drugs. *Life Sci* 2015; **136**: 60-66 [PMID: 26141991 DOI: 10.1016/j.lfs.2015.06.012]
 - 43 **József L**, Khreiss T, Fournier A, Chan JS, Filep JG. Extracellular signal-regulated kinase plays an essential role in endothelin-1-induced homotypic adhesion of human neutrophil granulocytes. *Br J Pharmacol* 2002; **135**: 1167-1174 [PMID: 11877323 DOI: 10.1038/sj.bjp.0704561]
 - 44 **Mitsuyama K**, Suzuki A, Tomiyasu N, Tsuruta O, Kitazaki S, Takeda T, Satoh Y, Bennett BL, Toyonaga A, Sata M. Pro-inflammatory signaling by Jun-N-terminal kinase in inflammatory bowel disease. *Int J Mol Med* 2006; **17**: 449-455 [PMID: 16465391]
 - 45 **Assi K**, Pillai R, Gómez-Muñoz A, Owen D, Salh B. The specific JNK inhibitor SP600125 targets tumour necrosis factor- α production and epithelial cell apoptosis in acute murine colitis. *Immunology* 2006; **118**: 112-121 [PMID: 16630028 DOI: 10.1111/j.1365-2567.2006.02349.x]
 - 46 **Hermano E**, Lerner I, Elkin M. Heparanase enzyme in chronic inflammatory bowel disease and colon cancer. *Cell Mol Life Sci* 2012; **69**: 2501-2513 [PMID: 22331282 DOI: 10.1007/s00018-012-0930-8]
 - 47 **Goldberg R**, Meirovitz A, Hirshoren N, Bulvik R, Binder A, Rubinstein AM, Elkin M. Versatile role of heparanase in inflammation. *Matrix Biol* 2013; **32**: 234-240 [PMID: 23499528 DOI: 10.1016/j.matbio.2013.02.008]
 - 48 **Vlodavsky I**, Beckhove P, Lerner I, Pisano C, Meirovitz A, Ilan N, Elkin M. Significance of Heparanase in Cancer and Inflammation. *Cancer Microenvironment* 2011; **5**: 115-132 [DOI: 10.1007/s12307-011-0082-7]
 - 49 **Edovitsky E**, Lerner I, Zcharia E, Peretz T, Vlodavsky I, Elkin M. Role of endothelial heparanase in delayed-type hypersensitivity. *Blood* 2006; **107**: 3609-3616 [PMID: 16384929 DOI: 10.1182/blood-2005-08-3301]
 - 50 **Quaglio AE**, Castilho AC, Di Stasi LC. Experimental evidence of heparanase, Hsp70 and NF- κ B gene expression on the response of anti-inflammatory drugs in TNBS-induced colonic inflammation. *Life Sci* 2015; **141**: 179-187 [PMID: 26434698 DOI: 10.1016/j.lfs.2015.09.023]
 - 51 **Kaufmann SH**. Heat shock proteins and the immune response. *Immunol Today* 1990; **11**: 129-136 [PMID: 2187470]
 - 52 **Wu C**. Heat shock transcription factors: structure and regulation. *Annu Rev Cell Dev Biol* 1995; **11**: 441-469 [PMID: 8689565 DOI: 10.1146/annurev.cb.11.110195.002301]
 - 53 **Einerhand AW**, Renes IB, Makkink MK, van der Sluis M, Büller HA, Dekker J. Role of mucins in inflammatory bowel disease: important lessons from experimental models. *Eur J Gastroenterol Hepatol* 2002; **14**: 757-765 [PMID: 12169985]
 - 54 **Buisine MP**, Desreumaux P, Debailleul V, Gambiez L, Geboes K, Ectors N, Delescaut MP, Degand P, Aubert JP, Colombel JF, Porchet N. Abnormalities in mucin gene expression in Crohn's disease. *Inflamm Bowel Dis* 1999; **5**: 24-32 [PMID: 10028446]
 - 55 **Kim YS**, Ho SB. Intestinal goblet cells and mucins in health and disease: recent insights and progress. *Curr Gastroenterol Rep* 2010; **12**: 319-330 [PMID: 20703838 DOI: 10.1007/s11894-010-0131-2]
 - 56 **Hoebler C**, Gaudier E, De Coppet P, Rival M, Cherbut C. MUC genes are differently expressed during onset and maintenance of inflammation in dextran sodium sulfate-treated mice. *Dig Dis Sci* 2006; **51**: 381-389 [PMID: 16534686 DOI: 10.1007/s10620-006-3142-y]
 - 57 **Sun L**, Liu J, Liu P, Yu Y, Ma L, Hu L. Immunosuppression effect of Withangulatin A from *Physalis angulata* via heme oxygenase 1-dependent pathways. *Process Biochemistry* 2011; **46**: 482-488 [DOI: 10.1016/j.procbio.2010.09.022]
 - 58 **Bastos GN**, Santos AR, Ferreira VM, Costa AM, Bispo CI, Silveira AJ, Do Nascimento JL. Antinociceptive effect of the aqueous extract obtained from roots of *Physalis angulata* L. on mice. *J Ethnopharmacol* 2006; **103**: 241-245 [PMID: 16169699 DOI: 10.1016/j.jep.2005.08.008]
 - 59 **Vieira AT**, Pinho V, Lepsch LB, Scavone C, Ribeiro IM, Tomassini T, Ribeiro-dos-Santos R, Soares MB, Teixeira MM, Souza DG. Mechanisms of the anti-inflammatory effects of the natural secosteroids physalins in a model of intestinal ischaemia and reperfusion injury. *Br J Pharmacol* 2005; **146**: 244-251 [PMID: 16025143 DOI: 10.1038/sj.bjp.0706321]
 - 60 **Sun L**, Liu J, Cui D, Li J, Yu Y, Ma L, Hu L. Anti-inflammatory function of Withangulatin A by targeted inhibiting COX-2 expression via MAPK and NF- κ B pathways. *J Cell Biochem* 2010; **109**: 532-541 [PMID: 19950196 DOI: 10.1002/jcb.22430]

P- Reviewer: Al-Rejaie SS, Prasad S **S- Editor:** Yu J

L- Editor: Filipodia **E- Editor:** Zhang FF





Published by **Baishideng Publishing Group Inc**
7901 Stoneridge Drive, Suite 501, Pleasanton, CA 94588, USA
Telephone: +1-925-223-8242
Fax: +1-925-223-8243
E-mail: bpgooffice@wjgnet.com
Help Desk: <http://www.f6publishing.com/helpdesk>
<http://www.wjgnet.com>



ISSN 1007-9327

