

World Journal of *Clinical Cases*

World J Clin Cases 2017 September 16; 5(9): 349-372



**MINIREVIEWS**

- 349** Primary prevention of cardiovascular disease in older adults in China
Yong J, Lin D, Tan XR

CASE REPORT

- 360** Conservative approach to the acute management of a large mesenteric cyst
Leung BC, Sankey R, Fronza M, Maatouk M
- 364** Recurrent aneurysmal bone cyst of talus resulted in tibiotalar calcaneal arthrodesis
Vosoughi AR, Mozaffarian K, Erfani MA
- 368** Anti-N-methyl-D-aspartate receptor encephalitis that aggravates after acinetobacter baumannii pneumonia: A case report
Wang CC, Li DJ, Xia YQ, Liu K

Contents

World Journal of Clinical Cases
Volume 5 Number 9 September 16, 2017

ABOUT COVER

Editorial Board Member of *World Journal of Clinical Cases*, Harrison S Weisinger, PhD, Director, School of Medicine, Faculty of Health, Deakin University, Geelong, VIC 3217, Australia

AIM AND SCOPE

World Journal of Clinical Cases (*World J Clin Cases*, *WJCC*, online ISSN 2307-8960, DOI: 10.12998) is a peer-reviewed open access academic journal that aims to guide clinical practice and improve diagnostic and therapeutic skills of clinicians.

The primary task of *WJCC* is to rapidly publish high-quality Autobiography, Case Report, Clinical Case Conference (Clinicopathological Conference), Clinical Management, Diagnostic Advances, Editorial, Field of Vision, Frontier, Medical Ethics, Original Articles, Clinical Practice, Meta-Analysis, Minireviews, Review, Therapeutics Advances, and Topic Highlight, in the fields of allergy, anesthesiology, cardiac medicine, clinical genetics, clinical neurology, critical care, dentistry, dermatology, emergency medicine, endocrinology, family medicine, gastroenterology and hepatology, geriatrics and gerontology, hematology, immunology, infectious diseases, internal medicine, obstetrics and gynecology, oncology, ophthalmology, orthopedics, otolaryngology, pathology, pediatrics, peripheral vascular disease, psychiatry, radiology, rehabilitation, respiratory medicine, rheumatology, surgery, toxicology, transplantation, and urology and nephrology.

INDEXING/ABSTRACTING

World Journal of Clinical Cases is now indexed in PubMed, PubMed Central.

FLYLEAF

I-V

Editorial Board

EDITORS FOR THIS ISSUE

Responsible Assistant Editor: *Xiang Li*
Responsible Electronic Editor: *Li-Min Zhao*
Proofing Editor-in-Chief: *Lian-Sheng Ma*

Responsible Science Editor: *Jin-Xin Kong*
Proofing Editorial Office Director: *Ze-Mao Gong*

NAME OF JOURNAL

World Journal of Clinical Cases

ISSN

ISSN 2307-8960 (online)

LAUNCH DATE

April 16, 2013

FREQUENCY

Monthly

EDITORS-IN-CHIEF

Giuseppe Di Lorenzo, MD, PhD, Professor, Genitourinary Cancer Section and Rare-Cancer Center, University Federico II of Napoli, 80131, Naples, Italy

Jan Jacques Michiels, MD, PhD, Professor, Primary Care, Medical Diagnostic Center Rijnmond Rotterdam, Bloodcoagulation, Internal and Vascular Medicine, Erasmus University Medical Center, Rotterdam, Goodheart Institute and Foundation, 3069 AT, Erasmus City, Rotterdam, The Netherlands

Sandro Vento, MD, Department of Internal Medicine, University of Botswana, Private Bag 00713, Gaborone, Botswana

Shuhei Yoshida, MD, PhD, Division of Gastroenterology, Beth Israel Deaconess Medical Center, Dana 509, Harvard Medical School, Boston, MA 02215, United States

EDITORIAL BOARD MEMBERS

All editorial board members resources online at <http://www.wjnet.com/2307-8960/editorialboard.htm>

EDITORIAL OFFICE

Xiu-Xia Song, Director
World Journal of Clinical Cases
Baishideng Publishing Group Inc
7901 Stoneridge Drive, Suite 501, Pleasanton, CA 94588, USA
Telephone: +1-925-2238242
Fax: +1-925-2238243
E-mail: editorialoffice@wjnet.com
Help Desk: <http://www.f6publishing.com/helpdesk>
<http://www.wjnet.com>

PUBLISHER

Baishideng Publishing Group Inc
7901 Stoneridge Drive,
Suite 501, Pleasanton, CA 94588, USA
Telephone: +1-925-2238242
Fax: +1-925-2238243
E-mail: bpgoffice@wjnet.com

Help Desk: <http://www.f6publishing.com/helpdesk>
<http://www.wjnet.com>

PUBLICATION DATE

September 16, 2017

COPYRIGHT

© 2017 Baishideng Publishing Group Inc. Articles published by this Open Access journal are distributed under the terms of the Creative Commons Attribution Non-commercial License, which permits use, distribution, and reproduction in any medium, provided the original work is properly cited, the use is non commercial and is otherwise in compliance with the license.

SPECIAL STATEMENT

All articles published in journals owned by the Baishideng Publishing Group (BPG) represent the views and opinions of their authors, and not the views, opinions or policies of the BPG, except where otherwise explicitly indicated.

INSTRUCTIONS TO AUTHORS

<http://www.wjnet.com/bpg/gerinfo/204>

ONLINE SUBMISSION

<http://www.f6publishing.com>

Anti-N-methyl-D-aspartate receptor encephalitis that aggravates after acinetobacter baumannii pneumonia: A case report

Cheng C Wang, Da J Li, Yi Q Xia, Kai Liu

Cheng C Wang, Da J Li, Kai Liu, Center of Infectious Diseases, West China Hospital of Sichuan University, Chengdu 610041, Sichuan Province, China

Yi Q Xia, Emergency Department, West China Hospital of Sichuan University, Chengdu 610041, Sichuan Province, China

Author contributions: Liu K designed the research, revised the paper and provided fundamental support; Wang CC searched the literature and wrote the paper; Li DJ and Xia YQ helped to search the literature and write the paper.

Institutional review board statement: This case report was exempt from the Institutional Review Board standards at West China Hospital of Sichuan University, Chengdu 610041, Sichuan Province, China.

Informed consent statement: The patient involved in this study gave his written informed consent authorizing use and disclosure of his protected health information.

Conflict-of-interest statement: The authors have declared no competing interests exist.

Data sharing statement: No additional data are available.

Open-Access: This article is an open-access article which was selected by an in-house editor and fully peer-reviewed by external reviewers. It is distributed in accordance with the Creative Commons Attribution Non Commercial (CC BY-NC 4.0) license, which permits others to distribute, remix, adapt, build upon this work non-commercially, and license their derivative works on different terms, provided the original work is properly cited and the use is non-commercial. See: <http://creativecommons.org/licenses/by-nc/4.0/>

Manuscript source: Unsolicited manuscript

Correspondence to: Dr Kai Liu, Associate Professor, Center of Infectious Diseases, West China Hospital of Sichuan University, No.37 Guo Xue Xiang, Wuhou District, Chengdu 610041, Sichuan Province, China. liubusiness@163.com

Fax: +86-28-85423597

Received: January 3, 2017

Peer-review started: January 6, 2017

First decision: March 7, 2017

Revised: April 20, 2017

Accepted: June 30, 2017

Article in press: July 3, 2017

Published online: September 16, 2017

Abstract

We report an atypical case of anti-N-methyl-D-aspartate receptor encephalitis (ANMDARE). A 27-year-old man diagnosed with ANMDARE received immunotherapy and had a good recovery. However, within one month, he developed severe status epilepticus and decreased level of conscience with new hyperpyrexia and dyspnea, and was admitted to the emergency intensive care unit. *Acinetobacter baumannii* were found in the sputum culture; and anti-NMDAR antibodies were positive (titer: 1/80) in the cerebrospinal fluid. Repeated immunotherapy was administered with antibacterial agents, and the patient recovered except for mild psychiatric sequelae. This is the first report of ANMDARE that aggravates after *acinetobacter baumannii* pneumonia. Awareness and knowledge of this disorder should be extended, especially in the emergency medicine community.

Key words: Anti-N-methyl-D-aspartate receptor encephalitis; *Acinetobacter baumannii* pneumonia; Emergency

© The Author(s) 2017. Published by Baishideng Publishing Group Inc. All rights reserved.

Core tip: In this paper we presented a very rare

case of an anti-N-methyl-D-aspartate receptor encephalitis in which the patient aggravated after acinetobacter baumannii pneumonia and well responded to immunotherapy. The mechanism underlying the association needs attention.

Wang CC, Li DJ, Xia YQ, Liu K. Anti-N-methyl-D-aspartate receptor encephalitis that aggravates after acinetobacter baumannii pneumonia: A case report. *World J Clin Cases* 2017; 5(9): 368-372 Available from: URL: <http://www.wjgnet.com/2307-8960/full/v5/i9/368.htm> DOI: <http://dx.doi.org/10.12998/wjcc.v5.i9.368>

INTRODUCTION

Anti-N-methyl-D-aspartate receptor encephalitis (ANMDARE) was initially identified in young females with ovarian tumor and was classified as a new immune-mediated encephalitis, producing antibodies to the target ANMDARE^[1]. Following a growing attention paid to this disease, an increasing number of reports and analyses have appeared in recent years^[2-5]. Early in the disease course, ANMDARE may resemble the first presentation of viral encephalitis^[2]. Compared with viral encephalitis, clinical features including psychosis, hallucinations, behavior and personality changes, seizure activity were observed more often among cases of ANMDARE^[2]. This disorder is confirmed by the identification of NMDAR antibodies in cerebrospinal fluid (CSF) or serum^[1,2]. It deteriorates rapidly with no or delayed treatment, but commonly improves with the application of immunotherapy or through a tumor resection, if applicable. The recovery process is slow, taking nearly 18 mo^[3]. Complications in patients while receiving treatment are yet to be established. Acinetobacter baumannii pneumonia has rarely been described in patients with ANMDARE^[4,6]. We here report a case of ANMDARE in a man whose clinical condition had improved after immunotherapy, but became worse in no more than one month due to acinetobacter baumannii pneumonia.

CASE REPORT

A 27-year-old man without a previous medical history, initially presenting with an acute psychiatric syndrome, including personality and behavioral change, was first evaluated by a psychiatrist and admitted to the psychiatric department in our hospital. He behaved friendly with focused attention and clear consciousness, but responded slowly to questions and manifested with emotional instability. Interruption of thinking, and thinking burst were observed in psychiatric examination with absence of hallucination, delusion and impulsive aggression. Psychotropic drugs

were used, but nothing worked. Rigidity emerged in seven days after admission. On day 12, he was transferred to neurology department with suspected viral encephalitis, in consideration of neurological impairment, including abnormal movements and tachycardia. He soon progressed to status epilepticus, insomnia, confusion of consciousness, and memory deficits, but without fever.

An electroencephalogram (EEG) showed diffuse or general slowing in the patient (Figure 1). Magnetic resonance imaging (MRI) of the brain revealed no abnormal changes (Figure 2). The first evaluation of CSF in psychotropic department was analyzed with ignorance of antibody detection. It only showed mild elevations of the protein level (90 mg/dL) and karyocyte count ($50 \times 10^6/L$), with a normal glucose level (Table 1). In the neurology department, antibody against NR1 heteromeric NMDAR was detected in the CSF (titer: 1/100), and the serum (titer: 1/10). Comprehensive tumor screening, including repeated enhanced computerized tomography (CT) and a urogenital examination for testicular tumors, was performed, with no tumors or inflammatory lesions detected. The patient was eventually diagnosed with ANMDARE without tumors, and was immediately treated with anti-epileptic drugs, corticosteroids (steroid pulse therapy of methylprednisolone 1 g/d for 5 d, followed by tapered-off oral prednisolone) as well as intravenous immunoglobulin (IVIG, 400 mg/kg daily for 5 d). After these treatments, his general condition gradually improved and he was discharged from hospital, with clear mind and normal behaviors.

However, no more than one month after the initial onset, the man typically manifested with new hyperpyrexia and dyspnea and then developed severe status epilepticus, decreased level of consciousness and convulsion of the limbs again. He was admitted to the emergency intensive care unit (EICU) where supplemental oxygen via a nonrebreather mask was initiated. The temperature was up to 39.0 °C. On physical examination, perspiration and cutaneous pallor were observed. He presented mild tachypnea (35 bpm) and severe hypoxemia (SaO₂ 86%). On auscultation, he had a good air entrance bilaterally with scattered to diffuse crackles and rhonchi. Serum C-reactive protein was 75 mg/L and procalcitonin (PCT) was 22 ng/mL. CT in the chest revealed acute lung inflammation (Figure 3); CSF was abnormal, and anti-NMDAR antibodies were positive (titer: 1/80) (Table 1). Herpes simplex virus (HSV) DNA polymerase chain reaction (PCR) in the CSF was negative. Acinetobacter baumannii was found in the sputum culture. A relapse of anti-NMDAR encephalitis combined with pneumonia caused by acinetobacter baumannii was diagnosed, and a cycle of steroid and IVIG pulse therapy were administered once again with antibacterial agents as well as other supportive therapies. There was no positive detection in tumor screening. The patient gradually recovered except for mild psychiatric

Table 1 Examination of cerebrospinal fluid

	First hospitalization	Post-treatment	Second hospitalization
Cerebrospinal pressure	Normal	Normal	Normal
NMDAR-Ab	1:100(+)	-	1:80(+)
CSF protein (g/L)	0.9	0.27	0.8
CSF glucose (mmol/L)	4.26	3.88	3.66
CSF chlorine (mmol/L)	12.6	128	120.1
CSF karyota count	$50 \times 10^6/L$	0	$60 \times 10^6/L$

CSF: Cerebrospinal fluid; NMDAR-Ab: Anti-N-methyl-D-aspartate receptor-Ab.

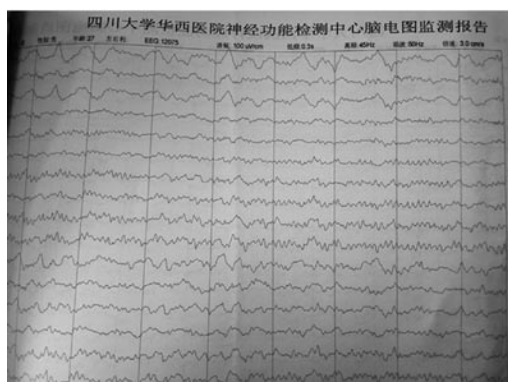

Figure 1 Electroencephalogram monitoring revealed low amplitude slow wave almost universally.

sequelae.

DISCUSSION

In our case, ANMDARE relapsed and the condition of the patient got worse following acinetobacter baumannii pneumonia, similar to that with possible mycoplasma pneumoniae infection in a previous study^[2]. In recent reports^[4,6], pneumonia was seen from 55% to 65% of patients with ANMDARE, more likely to accompany with status epilepticus, and was regarded as one of the risk factors influencing the outcome of this disease. The Chinese cohort study have firstly focused on and explore the causes of death of patients with ANMDARE, revealing that all the patients died with the existence of pneumonia^[6]. Complications such as severe pneumonia, multiple organ dysfunction syndrome (MODS), refractory status epilepticus (RSE) and sepsis were the main causes of death of patients with ANMDARE^[1,4,6]. Acinetobacter baumannii pneumonia may be a direct infectious complication of the use of immunosuppressant and may result in a fatal episode of respiratory failure or sepsis. But this has rarely been described in patients with ANMDARE. It is fairly clear that the occurrence of acinetobacter baumannii pneumonia has provoked the relapse and aggravation

of ANMDARE in our case. However, the mechanism of the underlying association is not clear, and whether this connection is meaningful warrants further study. There is increasing evidence that ANMDARE might develop in the context of viral encephalitis, and in term of etiology, a viral trigger (e.g., herpes simplex) might be considered in the synaptic autoimmunity^[5,7]. Moreover, the frequency of ANMDARE is likely to be four times higher than HSV encephalitis in young individuals in the California Encephalitis Project^[8]. Approximately 4.4% of encephalitis with unclear cause are anti-NMDAR encephalitis, followed by HSV type 1, enterovirus, varicella zoster virus, and West Nile virus^[8]. The correlation between ANMDARE and viral etiology is important^[5]. Whether the lung infection could be a trigger of ANMDARE and its mechanism need further studies.

Although the clinical spectrum of ANMDARE was widely reported, the disease often cannot be diagnosed earlier till the later clinical courses due to the nonspecific nature of symptoms and insufficient awareness of the disorder^[9] in most departments except the neurology, especially in the emergency department. There are several challenges in managing ANMDARE: The outcome is poor among developing countries, including China, due to the knowledge gap compared with developed countries, delays in diagnosis and misdiagnosis, complications as well as economic affordability. While approximately 80% of patients have good outcome^[3,10], ANMDARE carries a significant morbidity and mortality because of life-threatening illnesses such as intractable seizure, ventilator care, rhabdomyolysis or pneumonia^[4,10,11]. Patients could die of MODS during hospitalization, even after immunotherapy^[12]. Moreover, a minority of patients received second-line immunotherapy. It is important to make decisions regarding instance to facilitate a second-line immunotherapy and therapy timing typically based on symptoms, doctors' experience, therapeutic response, or patients' preference. Furthermore, many patients were discharged before they fully recovered due to the financial burden or ward beds shortage in hospital. While being back home or transferred to a primary care center, the condition may worse due to the progress of the disorder or complications including lung infection, urinary infection, rhabdomyolysis, venous thrombosis and hypersexuality^[4,10,13]. In China, awareness and knowledge of this disorder among not only neurologists but also psychiatrists and primary care physicians, should be extended and taken into consideration in the differential diagnosis when they encounter patients with a new onset of neurologic complaints preceded by psychiatric symptoms. Meanwhile, the popularity and feasibility of test method of NMDAR-Abs are required in most hospitals in China, so that physicians can more readily identify those affected with this potentially treatable disorder, facilitating earlier treatment and good outcome.

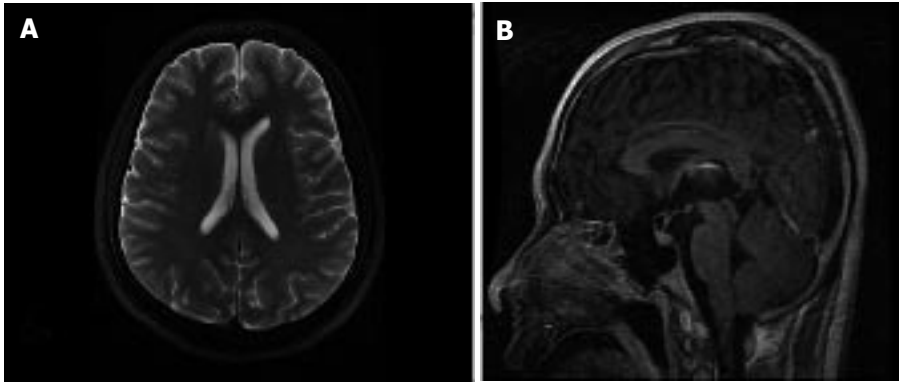


Figure 2 Transverse (A) and sagittal (B) views of magnetic resonance imaging was normal on admission.

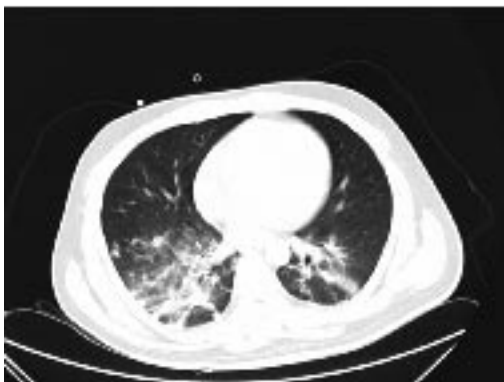


Figure 3 Computerized tomography in the chest revealed acute lung inflammation.

In conclusion, *acinetobacter baumannii* pneumonia can aggravate the process of ANMDARE. The mechanism underlying the association remains unknown and needs further studies. In China, awareness and knowledge of this disorder associated with lung infection should be extended, especially in the emergency medicine community.

COMMENTS

Case characteristics

A 27-year-old male with status epilepticus.

Clinical diagnosis

Anti-N-methyl-D-aspartate receptor encephalitis (ANMDARE).

Differential diagnosis

Viral encephalitis.

Laboratory diagnosis

Elevated titers of antibody against NMDAR in the cerebrospinal fluid.

Imaging diagnosis

Magnetic resonance imaging of the brain revealed no abnormal changes.

Treatment

Steroid and intravenous immunoglobulin pulse therapy.

Related reports

About 30 cases of NMDAR encephalitis after *acinetobacter baumannii* pneumonia.

Term explanation

ANMDARE developed multiple psychiatric and neurological features in the clinical course, including psychosis, epileptic seizures, autonomic instability, dyskinesia, decreased consciousness, and hypoventilation. It predominantly affects young adults and children with or without tumors and well responds to immunotherapy.

Experiences and lessons

This case report shows ANMDARE that aggravates after *acinetobacter baumannii* pneumonia. It's rarely reported.

Peer-review

This is an interesting case report.

REFERENCES

- 1 **Dalmau J**, Tüzün E, Wu HY, Masjuan J, Rossi JE, Voloschin A, Baehring JM, Shimazaki H, Koide R, King D, Mason W, Sansing LH, Dichter MA, Rosenfeld MR, Lynch DR. Paraneoplastic anti-N-methyl-D-aspartate receptor encephalitis associated with ovarian teratoma. *Ann Neurol* 2007; **61**: 25-36 [PMID: 17262855 DOI: 10.1002/ana.21050]
- 2 **Gable MS**, Gavali S, Radner A, Tilley DH, Lee B, Dyner L, Collins A, Dengel A, Dalmau J, Glaser CA. Anti-NMDA receptor encephalitis: report of ten cases and comparison with viral encephalitis. *Eur J Clin Microbiol Infect Dis* 2009; **28**: 1421-1429 [PMID: 19718525 DOI: 10.1007/s10096-009-0799-0]
- 3 **Titulaer MJ**, McCracken L, Gabilondo I, Armangué T, Glaser C, Iizuka T, Honig LS, Benseler SM, Kawachi I, Martinez-Hernandez E, Aguilar E, Gresa-Arribas N, Ryan-Flanagan N, Torrents A, Saiz A, Rosenfeld MR, Balice-Gordon R, Graus F, Dalmau J. Treatment and prognostic factors for long-term outcome in patients with anti-NMDA receptor encephalitis: an observational cohort study. *Lancet Neurol* 2013; **12**: 157-165 [PMID: 23290630 DOI: 10.1016/S1474-4422(12)70310-1]
- 4 **Huang Q**, Wu Y, Qin R, Wei X, Ma M. Clinical characteristics and outcomes between children and adults with anti-N-Methyl-D-Aspartate receptor encephalitis. *J Neurol* 2016; **263**: 2446-2455 [PMID: 27632180 DOI: 10.1007/s00415-016-8282-1]
- 5 **Gilbert GJ**. Herpes simplex virus-1 encephalitis can trigger anti-NMDA receptor encephalitis: case report. *Neurology* 2014; **82**: 2041 [PMID: 24891544 DOI: 10.1212/01.wnl.0000450946.75616.32]
- 6 **Chi X**, Wang W, Huang C, Wu M, Zhang L, Li J, Zhou D. Risk factors for mortality in patients with anti-NMDA receptor encephalitis. *Acta Neurol Scand* 2017; **136**: 298-304 [PMID: 27632180 DOI: 10.1007/s00415-016-8282-1]

- 28028820 DOI: 10.1111/ane.12723]
- 7 **Ellul MA**, Griffiths MJ, Iyer A, Avula S, Defres S, Baborie A, Vincent A, Martin NG, Sadarangani M, Pollard AJ, Solomon T, Kneen R. Anti-N-Methyl-D-Aspartate Receptor Encephalitis In A Young Child With Histological Evidence On Brain Biopsy Of Coexistent Herpes Simplex Virus Type 1 Infection. *Pediatr Infect Dis J* 2016; **35**: 347-349 [PMID: 26658379 DOI: 10.1097/INF.0000000000001011]
- 8 **Gable MS**, Sheriff H, Dalmau J, Tilley DH, Glaser CA. The frequency of autoimmune N-methyl-D-aspartate receptor encephalitis surpasses that of individual viral etiologies in young individuals enrolled in the California Encephalitis Project. *Clin Infect Dis* 2012; **54**: 899-904 [PMID: 22281844 DOI: 10.1093/cid/cir1038]
- 9 **Barry H**, Byrne S, Barrett E, Murphy KC, Cotter DR. Anti-N-methyl-d-aspartate receptor encephalitis: review of clinical presentation, diagnosis and treatment. *BJPsych Bull* 2015; **39**: 19-23 [PMID: 26191419 DOI: 10.1192/pb.bp.113.045518]
- 10 **Wang W**, Li JM, Hu FY, Wang R, Hong Z, He L, Zhou D. Anti-NMDA receptor encephalitis: clinical characteristics, predictors of outcome and the knowledge gap in southwest China. *Eur J Neurol* 2016; **23**: 621-629 [PMID: 26563553 DOI: 10.1111/ene.12911]
- 11 **Lim JA**, Lee ST, Kim TJ, Moon J, Sunwoo JS, Byun JI, Jung KH, Jung KY, Chu K, Lee SK. Frequent rhabdomyolysis in anti-NMDA receptor encephalitis. *J Neuroimmunol* 2016; **298**: 178-180 [PMID: 27609293 DOI: 10.1016/j.jneuroim.2016.08.002]
- 12 **Liu J**, Wang D, Xiong Y, Liu B, Liu M. Anti-NMDAR Encephalitis of 11 Cases in China - Detailed Clinical, Laboratory and Imagiological Description. *Eur Neurol* 2015; **74**: 73-78 [PMID: 26277996 DOI: 10.1159/000435953]
- 13 **Sakamoto H**, Hirano M, Samukawa M, Ueno S, Maekura S, Fujimura H, Kuwahara M, Hamada Y, Isono C, Tanaka K, Kusunoki S, Nakamura Y. Details of treatment-related difficulties in men with anti-N-methyl-D-aspartate receptor encephalitis. *Eur Neurol* 2013; **69**: 21-26 [PMID: 23128856 DOI: 10.1159/000342023]

P- Reviewer: Peluso I, Tan XR **S- Editor:** Ji FF **L- Editor:** A
E- Editor: Zhao LM





Published by **Baishideng Publishing Group Inc**
7901 Stoneridge Drive, Suite 501, Pleasanton, CA 94588, USA
Telephone: +1-925-223-8242
Fax: +1-925-223-8243
E-mail: bpgoffice@wjgnet.com
Help Desk: <http://www.f6publishing.com/helpdesk>
<http://www.wjgnet.com>

