

World Journal of *Gastroenterology*

World J Gastroenterol 2017 April 21; 23(15): 2635-2818



**EDITORIAL**

- 2635 Dietary compliance in celiac disease

Freeman HJ

- 2640 Is there still a role for the hepatic locoregional treatment of metastatic neuroendocrine tumors in the era of systemic targeted therapies?

Cavalcoli F, Rausa E, Conte D, Nicolini AF, Massironi S

REVIEW

- 2651 Hepatitis B virus infection and alcohol consumption

Iida-Ueno A, Enomoto M, Tamori A, Kawada N

- 2660 Endoscopic management of pancreatic fluid collections-revisited

Nabi Z, Basha J, Reddy DN

ORIGINAL ARTICLE**Basic Study**

- 2673 Overexpression of fibrinogen-like protein 2 protects against T cell-induced colitis

Bartczak A, Zhang J, Adeyi O, Amir A, Grant D, Gorczynski R, Selzner N, Chruscinski A, Levy GA

- 2685 Changes in human hepatic metabolism in steatosis and cirrhosis

Schofield Z, Reed MAC, Newsome PN, Adams DH, Günther UL, Lalor PF

- 2696 Effect of *Lactobacillus rhamnosus* HN001 and *Bifidobacterium longum* BB536 on the healthy gut microbiota composition at phyla and species level: A preliminary study

Toscano M, De Grandi R, Stronati L, De Vecchi E, Drago L

- 2705 Effects of Hwangryunhaedok-tang on gastrointestinal motility function in mice

Kim H, Kim I, Lee MC, Kim HJ, Lee GS, Kim H, Kim BJ

- 2716 Role of $\Delta 133p53$ isoform in NF- κ B inhibitor PDTC-mediated growth inhibition of MKN45 gastric cancer cells

Zhang HM, Sang XG, Wang YZ, Cui C, Zhang L, Ji WS

Retrospective Cohort Study

- 2723 Optimal treatment for Siewert type II and III adenocarcinoma of the esophagogastric junction: A retrospective cohort study with long-term follow-up

Hosoda K, Yamashita K, Moriya H, Mieno H, Watanabe M

Retrospective Study

- 2731 Colorectal and interval cancers of the Colorectal Cancer Screening Program in the Basque Country (Spain)

Portillo I, Arana-Arri E, Idigoras I, Bilbao I, Martínez-Indart L, Bujanda L, Gutierrez-Ibarluzea I

- 2743 Performance of 18-fluoro-2-deoxyglucose positron emission tomography for esophageal cancer screening

Sekiguchi M, Terauchi T, Kakugawa Y, Shimada N, Saito Y, Matsuda T

- 2750 Association of obesity with
- Helicobacter pylori*
- infection: A retrospective study

Xu MY, Liu L, Yuan BS, Yin J, Lu QB

- 2757 Outcomes and prognostic factors of patients with stage IB and II A pancreatic cancer according to the 8
- th
- edition American Joint Committee on Cancer criteria

Li Y, Tang CG, Zhao Y, Cao WY, Qu GF

Clinical Trials Study

- 2763 Patients with non-viral liver disease have a greater tumor burden and less curative treatment options when diagnosed with hepatocellular carcinoma

Mohsen W, Rodov M, Prakoso E, Charlton B, Bowen DG, Koorey DJ, Shackel NA, McCaughan GW, Strasser SI

- 2771 Urinary metabolomics analysis identifies key biomarkers of different stages of nonalcoholic fatty liver disease

Dong S, Zhan ZY, Cao HY, Wu C, Bian YQ, Li JY, Cheng GH, Liu P, Sun MY

Observational Study

- 2785 Age-related impairment of esophagogastric junction relaxation and bolus flow time

Cock C, Besanko LK, Burgstad CM, Thompson A, Kritas S, Heddle R, Fraser RJL, Omari TI

- 2795 Endoscopic ultrasound-guided cutting of holes and deep biopsy for diagnosis of gastric infiltrative tumors and gastrointestinal submucosal tumors using a novel vertical diathermic loop

Liu YM, Yang XJ

- 2802 Non-ALT biomarkers for markedly abnormal liver histology among Chinese persistently normal alanine aminotransferase-chronic hepatitis B patients

Cheng JL, Wang XL, Yang SG, Zhao H, Wu JJ, Li LJ

CASE REPORT

- 2811 One step minilaparotomy-assisted transmesenteric portal vein recanalization combined with transjugular intrahepatic portosystemic shunt placement: A novel surgical proposal in pediatrics

Pelizzo G, Quaretti P, Moramarco LP, Corti R, Maestri M, Iacob G, Calcaterra V

ABOUT COVER

Editorial board member of *World Journal of Gastroenterology*, Oya Yucel, PhD, Associate Professor, Pediatric Department, Baskent University, Istanbul Teaching and Medical Research Hospital, Istanbul 34662, Turkey

AIMS AND SCOPE

World Journal of Gastroenterology (*World J Gastroenterol*, *WJG*, print ISSN 1007-9327, online ISSN 2219-2840, DOI: 10.3748) is a peer-reviewed open access journal. *WJG* was established on October 1, 1995. It is published weekly on the 7th, 14th, 21st, and 28th each month. The *WJG* Editorial Board consists of 1375 experts in gastroenterology and hepatology from 68 countries.

The primary task of *WJG* is to rapidly publish high-quality original articles, reviews, and commentaries in the fields of gastroenterology, hepatology, gastrointestinal endoscopy, gastrointestinal surgery, hepatobiliary surgery, gastrointestinal oncology, gastrointestinal radiation oncology, gastrointestinal imaging, gastrointestinal interventional therapy, gastrointestinal infectious diseases, gastrointestinal pharmacology, gastrointestinal pathophysiology, gastrointestinal pathology, evidence-based medicine in gastroenterology, pancreatology, gastrointestinal laboratory medicine, gastrointestinal molecular biology, gastrointestinal immunology, gastrointestinal microbiology, gastrointestinal genetics, gastrointestinal translational medicine, gastrointestinal diagnostics, and gastrointestinal therapeutics. *WJG* is dedicated to become an influential and prestigious journal in gastroenterology and hepatology, to promote the development of above disciplines, and to improve the diagnostic and therapeutic skill and expertise of clinicians.

INDEXING/ABSTRACTING

World Journal of Gastroenterology (*WJG*) is now indexed in Current Contents[®]/Clinical Medicine, Science Citation Index Expanded (also known as SciSearch[®]), Journal Citation Reports[®], Index Medicus, MEDLINE, PubMed, PubMed Central, Digital Object Identifier, and Directory of Open Access Journals. The 2015 edition of Journal Citation Reports[®] released by Thomson Reuters (ISI) cites the 2015 impact factor for *WJG* as 2.787 (5-year impact factor: 2.848), ranking *WJG* as 38 among 78 journals in gastroenterology and hepatology (quartile in category Q2).

FLYLEAF

I-IX Editorial Board

EDITORS FOR THIS ISSUE

Responsible Assistant Editor: Xiang Li
Responsible Electronic Editor: Fen-Fen Zhang
Proofing Editor-in-Chief: Lian-Sheng Ma

Responsible Science Editor: Ze-Mao Gong
Proofing Editorial Office Director: Jin-Lei Wang

NAME OF JOURNAL
World Journal of Gastroenterology

ISSN
ISSN 1007-9327 (print)
ISSN 2219-2840 (online)

LAUNCH DATE
October 1, 1995

FREQUENCY
Weekly

EDITORS-IN-CHIEF
Damian Garcia-Olmo, MD, PhD, Doctor, Professor, Surgeon, Department of Surgery, Universidad Autonoma de Madrid; Department of General Surgery, Fundacion Jimenez Diaz University Hospital, Madrid 28040, Spain

Stephen C Strom, PhD, Professor, Department of Laboratory Medicine, Division of Pathology, Karolinska Institutet, Stockholm 141-86, Sweden

Andrzej S Tarnawski, MD, PhD, DSc (Med), Professor of Medicine, Chief Gastroenterology, VA Long Beach Health Care System, University of California, Irvine, CA, 5901 E. Seventh Str., Long Beach,

CA 90822, United States

EDITORIAL BOARD MEMBERS
All editorial board members resources online at <http://www.wjgnet.com/1007-9327/editorialboard.htm>

EDITORIAL OFFICE
Jin-Lei Wang, Director
Yuan Qi, Vice Director
Ze-Mao Gong, Vice Director
World Journal of Gastroenterology
Baishideng Publishing Group Inc
7901 Stoneridge Drive, Suite 501,
Pleasanton, CA 94588, USA
Telephone: +1-925-2238242
Fax: +1-925-2238243
E-mail: editorialoffice@wjgnet.com
Help Desk: <http://www.f6publishing.com/helpdesk>
<http://www.wjgnet.com>

PUBLISHER
Baishideng Publishing Group Inc
7901 Stoneridge Drive, Suite 501,
Pleasanton, CA 94588, USA
Telephone: +1-925-2238242
Fax: +1-925-2238243
E-mail: bpoffice@wjgnet.com
Help Desk: <http://www.f6publishing.com/helpdesk>

<http://www.wjgnet.com>

PUBLICATION DATE
April 21, 2017

COPYRIGHT
© 2017 Baishideng Publishing Group Inc. Articles published by this Open-Access journal are distributed under the terms of the Creative Commons Attribution Non-commercial License, which permits use, distribution, and reproduction in any medium, provided the original work is properly cited, the use is non commercial and is otherwise in compliance with the license.

SPECIAL STATEMENT
All articles published in journals owned by the Baishideng Publishing Group (BPG) represent the views and opinions of their authors, and not the views, opinions or policies of the BPG, except where otherwise explicitly indicated.

INSTRUCTIONS TO AUTHORS
Full instructions are available online at <http://www.wjgnet.com/bpg/gerinfo/204>

ONLINE SUBMISSION
<http://www.f6publishing.com>

Observational Study

Endoscopic ultrasound-guided cutting of holes and deep biopsy for diagnosis of gastric infiltrative tumors and gastrointestinal submucosal tumors using a novel vertical diathermic loop

Yu-Mei Liu, Xiu-Jiang Yang

Yu-Mei Liu, Xiu-Jiang Yang, Department of Endoscopy, Fudan University Shanghai Cancer Center, Shanghai 200032, China

Yu-Mei Liu, Xiu-Jiang Yang, Department of Oncology, Shanghai Medical College, Fudan University, Shanghai 200032, China

Author contributions: Liu YM drafted the manuscript and assisted with data collection and analysis; Yang XJ participated in the design and oversight of the study and performed the majority of operations; all authors read and approved the final manuscript.

Institutional review board statement: The study was reviewed and approved by the Institutional Review Board and Ethics Committee of Fudan University Shanghai Cancer Center.

Informed consent statement: Informed consent was obtained from all participants or their legal guardian.

Conflict-of-interest statement: The authors of this manuscript have no conflicts of interest to disclose.

Data sharing statement: There is no additional data available.

Open-Access: This article is an open-access article which was selected by an in-house editor and fully peer-reviewed by external reviewers. It is distributed in accordance with the Creative Commons Attribution Non Commercial (CC BY-NC 4.0) license, which permits others to distribute, remix, adapt, build upon this work non-commercially, and license their derivative works on different terms, provided the original work is properly cited and the use is non-commercial. See: <http://creativecommons.org/licenses/by-nc/4.0/>

Manuscript source: Unsolicited manuscript

Correspondence to: Xiu-Jiang Yang, MD, Professor, Department of Endoscopy, Fudan University Shanghai Cancer Center, 270 Dong'an Road, Shanghai 200032, China. yangxj1960@163.com

Telephone: +86-21-34610367

Received: January 5, 2017

Peer-review started: January 5, 2017

First decision: February 9, 2017

Revised: February 13, 2017

Accepted: March 15, 2017

Article in press: March 15, 2017

Published online: April 21, 2017

Abstract

AIM

To report on a more accurate diagnostic possibility offered by endoscopic ultrasound-guided cutting of holes and deep biopsy (EUS-CHDB) for pathologic diagnosis of gastric infiltrative tumors and gastrointestinal submucosal tumors.

METHODS

Ten consecutive patients who were suspected of having gastric invasive tumors or gastrointestinal submucosal tumors underwent EUS-CHDB with a novel vertical diathermic loop. We reviewed their medical data and analysed the effectiveness and safety of this new method. The final diagnosis was based on the surgical pathology or clinical/imaging follow-up.

RESULTS

EUS-CHDB was performed successfully in all the ten patients. Neither severe haemorrhage nor perforation occurred in any patient. Among the ten patients, there were three cases of gastric linitis plastica, one case of gastric lymphoma, five cases of gastrointestinal stromal tumors (GISTs), and only one case of chronic non-atrophic gastritis. That is, nine (90%) of the cases

treated by EUS-CHDB showed positive findings.

CONCLUSION

EUS-CHDB may be a technically feasible and safe option for patients with gastric infiltrative tumors or gastrointestinal submucosal tumors. EUS-CHDB may be used as a remedial or even preferred biopsy method for submucosal lesions.

Key words: Endoscopic ultrasound; Cutting holes; Deep biopsy; Vertical diathermic loop; Gastric linitis plastica; Gastrointestinal submucosal tumors

© **The Author(s) 2017.** Published by Baishideng Publishing Group Inc. All rights reserved.

Core tip: This was a prospective clinical diagnostic trial seeking to evaluate the efficacy of endoscopic ultrasound-guided cutting of holes and deep biopsy for the diagnosis of gastric infiltrative tumors and gastrointestinal submucosal tumors using a novel vertical diathermic loop. This new technique was proved to be a safe, technically feasible and more accurate option for patients with gastric infiltrative tumors or gastrointestinal submucosal tumors.

Liu YM, Yang XJ. Endoscopic ultrasound-guided cutting of holes and deep biopsy for diagnosis of gastric infiltrative tumors and gastrointestinal submucosal tumors using a novel vertical diathermic loop. *World J Gastroenterol* 2017; 23(15): 2795-2801 Available from: URL: <http://www.wjgnet.com/1007-9327/full/v23/i15/2795.htm> DOI: <http://dx.doi.org/10.3748/wjg.v23.i15.2795>

INTRODUCTION

Gastric infiltrative tumors, commonly referred to as gastric linitis plastica (GLP) and gastric lymphoma, along with gastrointestinal submucosal tumors often have more than one negative pathological finding on ordinary endoscopic biopsies. Such troublesome phenomena are associated with the biopsy technique itself and the deep location of the tumors. GLP, which is also known as Borrmann type IV or diffuse infiltrating-type gastric cancer or scirrhous carcinoma, is an invasive and diffuse carcinoma that is characterized by a thickened, tough and rigid gastric wall and a narrow cavity^[1]. In general, GLP infiltrates the submucosal layer without destroying the superficial structure of the gastric wall; thus, pathological findings in the mucosal layer are not available for making a diagnosis *via* common biopsy^[2]. Therefore, making an early diagnosis is difficult, and peritoneal metastasis is common at the time of detection, which results in a poor prognosis^[3,4]. Primary gastric lymphomas, which are the major malignant tumors of the stomach secondary to gastric carcinoma, mostly originate in the

submucosa, and their diagnosis *via* endoscopic forceps biopsy is often difficult, with a positive rate of only 29% in the initial detection^[5,6]. For patients with primary gastric lymphoma, in contrast to those with GLP, effective chemotherapy produces a good outcome, and unnecessary surgery is avoided. Therefore, the distinction between GLP and gastric lymphoma is also significant for treatment. Similarly, for gastrointestinal stromal tumors (GISTs), which generally originate from the muscularis propria, a common endoscopic biopsy cannot acquire the correct tumor tissue that is usually resected during surgery or endoscopic submucosal dissection (ESD) for immunohistochemistry analysis.

Endoscopic ultrasound (EUS) is reliable in the diagnosis and staging of gastrointestinal malignancies and has become an indispensable evaluation in patients who are suspected of having submucosal tumors of the upper gastrointestinal tract^[7,8]. Specimens obtained with a standard endoscopic biopsy rarely provide a confirmative diagnosis because lesions in the submucosa are difficult to reach directly with forceps. The excavating biopsy, snaring biopsy and endoscopic mucosal resection (EMR), derived from the traditional biopsy methods, are considered unsafe for frequent complications such as haemorrhage and perforation^[9,10]. EUS enables the detection of the thickness of the wall and invasive depth of lesions. Therefore, it may reduce the operational risks and complications to finish a deep biopsy under the guidance of EUS in real time, which makes up for the deficiency of routine endoscopy. In addition, given the deficiencies of the currently available biopsy methods, such as a large wound, an inadequate depth and a rigid gastric wall, we invented a novel assistant tool, a reform of the diathermic snare. It contains a control handle, an insulated sheath and an electric metal wire whose tail end wields a small loop vertically. This vertical diathermic loop connected with an electrosurgical unit can be used to cut holes by fulguration into the tumor through the biopsy channel first, and the biopsy forceps can be poked into the holes to acquire deep tissue samples. Here, we retrospectively investigated the safety and efficacy of this novel process, called EUS-guided cutting of holes and deep biopsy (EUS-CHDB), for diagnosing gastric infiltrative tumors and gastrointestinal submucosal tumors.

MATERIALS AND METHODS

Patients

From March 2014 to June 2016, ten consecutive patients (including five men) at our department who were suspected of having gastric invasive tumors or GISTs underwent EUS-CHDB with the novel electric ring. All patients had undergone ordinary endoscopic biopsies one to four times, and their pathology showed negative results. We extracted and analyzed their medical data. The study was approved by the Institutional Review Board of Fudan University

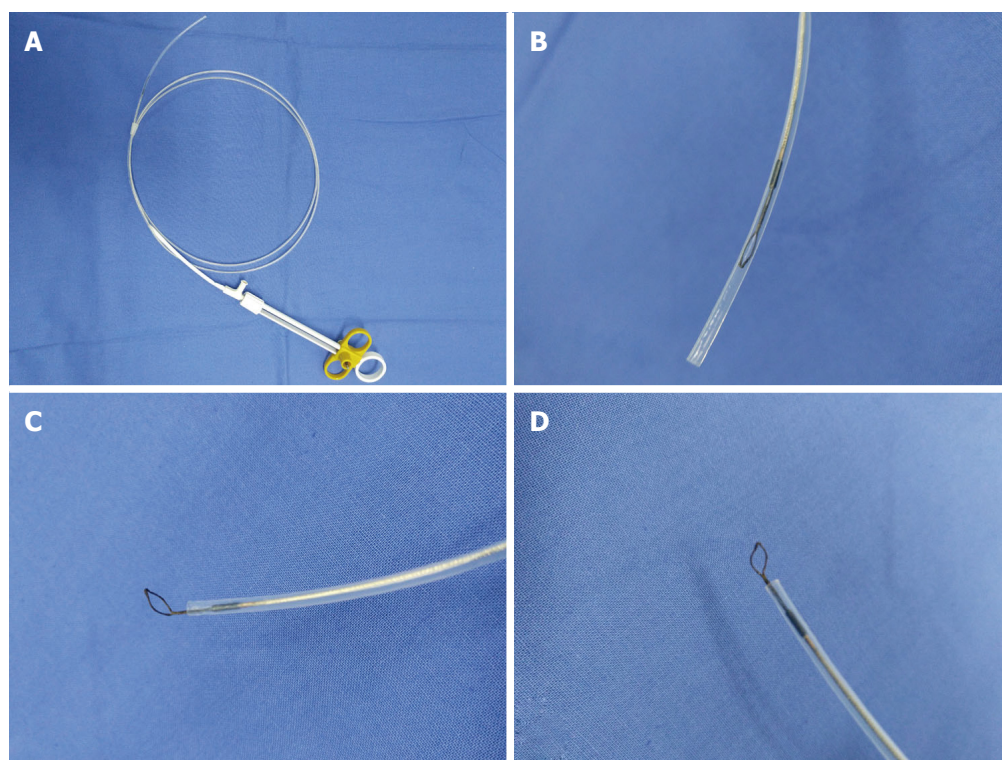


Figure 1 Vertical electrode loop. A: The vertical electrode loop device; B: The loop is dragged into the sheath when not working; C and D: When working, the small loop that is vertically welded to the end of the electric metal wire is pushed out of the sheath.

Shanghai Cancer Center, and informed consent for the procedure was obtained.

EUS equipment and biopsy instruments

EUS equipment in our endoscopy centre is composed of an ultrasound mainframe (Hitachi Preirus; Hitachi, Tokyo, Japan) and linear echoendoscopes (PANTAX EG-3870UTK and EG-3270UK; PANTAX, Tokyo, Japan). Biopsy instruments consisted of the following: a vertical diathermic loop, composed of a control handle, an insulated sheath and an electric metal wire whose end vertically welds a small loop with a diameter of 3–5 mm. The available length of this device was 155 cm. The small ring could be pushed out with the largest length at 1.5 cm or pulled into the sheath with a diameter of approximately 2 mm (Figure 1). An electrosurgical unit was connected to the handle of the loop, and energy delivery was controlled by a foot switch. A small conventional biopsy forceps with a diameter of 1.8 mm was attached.

Biopsy process

All patients experienced conventional EUS examination first to determine the targeted focus characterized by the obviously thick and rigid wall on the tumor. Subsequently, the vertical diathermic loop connected to an electrosurgical unit could be used to cut cylindrical holes under the guidance of EUS by fulguration into the targeted focus through the biopsy channel, and then a conventional biopsy forceps was poked into the holes to acquire the deep tissue samples. The diameters

of the holes were approximately 3–5 mm, and the depth to the location was equivalent to the muscularis propria. Every tumor required cutting 2–3 holes to acquire more than seven blocks of tissue specimens. When the biopsy was finished, if the incision was too broad or still bleeding after spraying thrombin locally, an endoclip was selectively used to close it (Figure 2).

RESULTS

EUS-CHDB was performed successfully in all the 10 patients. The median age of the patients was 52.4 years (range: 41–75 years), and the male to female ratio was 5:5. Characteristics of the patients and tumors and the final diagnoses are shown in Table 1.

The average numbers of cut holes and tissue specimens were 2.29 (range: 2–3) and 8.57 (range: 7–12), respectively. There were two cases still haemorrhaging after spraying thrombin locally and three cases showing a large wound, so endoclips were used to close the incision. Neither severe haemorrhage nor perforation occurred in any patient. According to the pathology results from the samples obtained by EUS-CHDB, among the ten patients, there were three GLP cases, one gastric lymphoma case, five GIST cases, and only one case showing chronic non-atrophic gastritis (Figure 3). Three of the five patients diagnosed with GISTs underwent surgical treatment, and the surgical pathology findings were consistent with the EUS-CHDB findings. The patient showing chronic non-atrophic gastritis was diagnosed with GLP

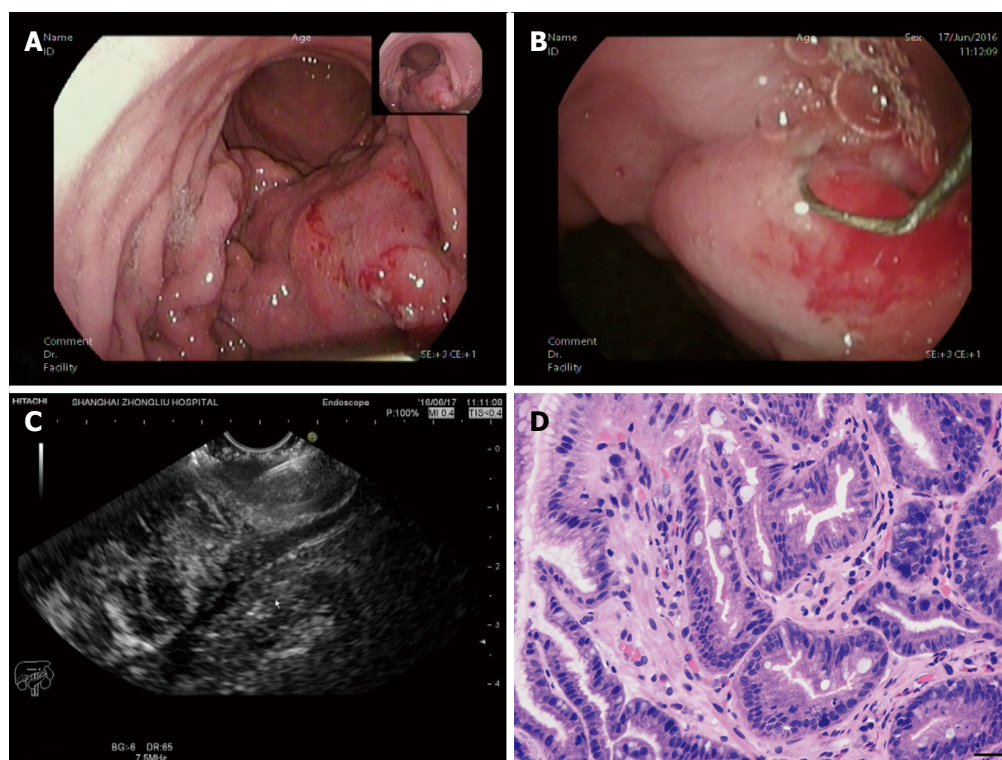


Figure 2 A case diagnosed with gastric linitis plastica. A: Endoscopic characteristics: thick and rigid gastric duplication and a narrow cavity; B: The loop was placed on the targeted focus characterized by the obviously thick and rigid wall on the tumor, then the holes were cut; C: A biopsy forceps was poked into the holes to acquire the deep tissue samples under the guidance of EUS; D: The tissue specimen was then analysed histopathologically and shown to be gastric adenocarcinoma.

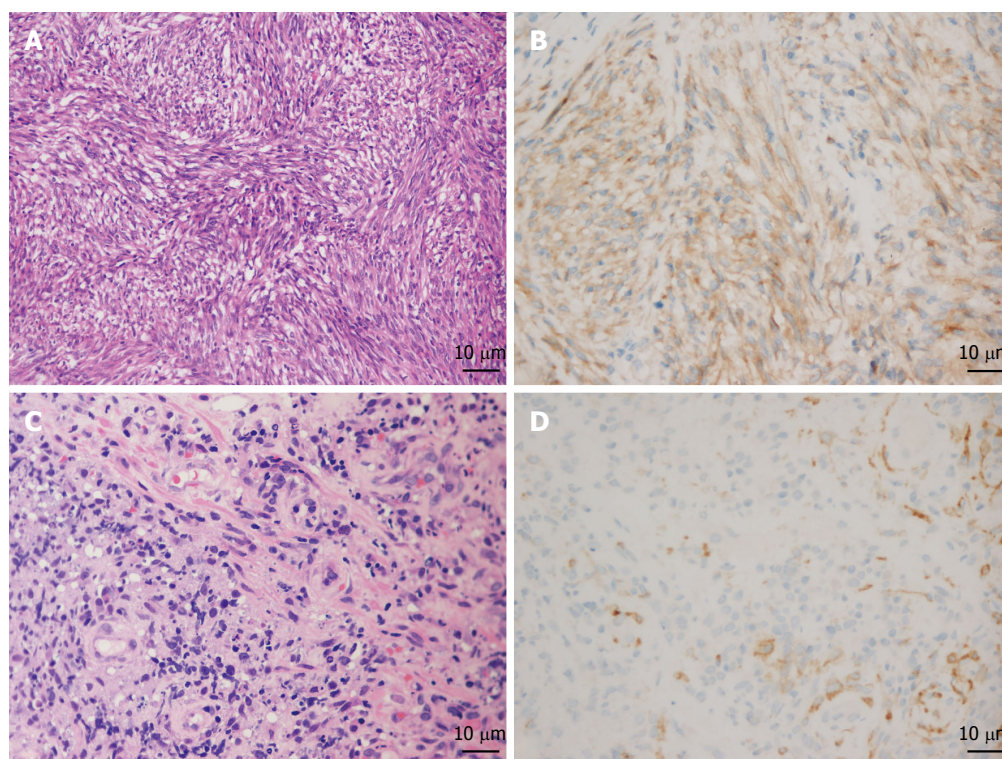


Figure 3 Results of pathology and immunohistochemistry of gastrointestinal stromal tumors and gastric lymphoma. A and B: The pathology characterized by spindle cells (HE, × 200) and immunohistochemistry showing positive CD117 staining proved the diagnosis of gastrointestinal stromal tumors (GIST); C and D: Increased and dispersively distributed lymphocytes (HE, × 400) with positive CD10 staining according to the immunohistochemistry results confirmed the diagnosis of gastric diffuse large B-cell lymphoma.

Table 1 Patient and tumor characteristics

Age, median (range), yr	52.4 (41-75)		
Male, <i>n</i> (%)	5 (50)		
Tumour thickness, median (range), mm	25.34 (10.6-45.2)		
Tumour location, <i>n</i>			
Gastric fundus	2		
Gastric body	5		
Gastric fundus and body	1		
Gastric body and antrum	1		
Descending duodenum	1		
Final diagnosis, <i>n</i>			
Pathology obtained by EUS-CHDB	Surgical resection or clinical follow-up		
Histological type	Gastric adenocarcinoma	GIST	Gastric lymphoma
Gastric adenocarcinoma	3	0	0
GIST	0	5	0
Gastric lymphoma	0	0	1
Chronic non-atrophic gastritis	1	0	0
The overall accuracy rate	90%		

GIST: Gastrointestinal stromal tumors.

by surgical resection. According to the clinical/imaging follow-up, the diagnosis of patients without surgical resection was consistent with the EUS-CHDB findings. That is, nine (90%) of the cases treated by EUS-CHDB had positive findings.

DISCUSSION

Primary gastric lymphoma (PGL) accounts for 2% to 8% of all malignant gastric tumors, which spread mainly in a longitudinal growth style. Suekane *et al.*^[11] divided the patients into four groups according to the endoscopic ultrasonography findings: superficially spreading type, diffusely infiltrating type, mass-forming type, and mixed type. Among the four groups, the superficially spreading type had the highest frequency with EUS imaging features of diffused gastric wall thickening and replacing of the second and third layers with a hypoecho mass. Based on the morphological characteristics of the gastric tumor visualized by common endoscopy or EUS, a differential diagnosis of GLP and gastric lymphoma is difficult in most cases. In our outpatient department of endoscopy, a 34-year-old female patient who was clinically suspected of having gastric lymphoma for more than 3 years but treated as chronic gastritis subsequently suffered from a huge abdominal mass suspected of being the product of metastasis. We suggest that the correct histopathologic findings are closely tied to the prognosis of GLP; the sooner the pathology, the better the treatment. However, a study showed that only eight cases were correctly diagnosed by preoperative biopsy among 45 cases of GPL^[12]. Thus, finding an effective biopsy method may be the key point.

A meta-analysis^[4] showed that compared with Borrmann type "others", B-4 had a higher incidence

of poorly differentiated carcinoma ($P < 0.01$), lymph node metastasis ($P < 0.01$), peritoneal metastasis ($P < 0.01$), and serosal invasion ($P < 0.01$). Kim *et al.*^[2] showed that the missed rate of ordinary biopsies in diagnosing Borrmann type IV gastric cancer was as high as 55.9%. Lesions showing thickening of the gastric mucosa generally originate from the submucosa, whose tissue samples obtained by large-capacity biopsy forceps can improve the diagnostic rate, but only to 17%^[13]. For patients with gastric infiltrative tumors whose initial biopsy is negative for malignancy, the following two to four biopsies enable an increase in the positive rate, but limited, and repeated endoscopy examinations and biopsies may bring more suffering, cost burdens and even delayed treatment.

Along with the advancement of endoscopic diagnostic and therapeutic technology, several novel technologies, such as EUS-guided fine needle aspiration (EUS-FNA), excavating biopsy, snaring biopsy and EMR, have emerged. EUS-FNA for gastric infiltrative tumors can be used to acquire cytology findings, but for large tissue specimens for histopathology analysis, with the disadvantages of difficult operations, long time and high expenses, the positive finding rate is still undesirable^[14-16]. Al-Haddad *et al.*^[17] reported that the sensitivity, specificity and accuracy rates of EUS-FNA in the diagnosis of lymphoma were 80%-87%, 92%-93%, and 83%-89%, respectively. Recently, Zhou *et al.*^[18] confirmed that endoscopic ultrasound-guided deep and large biopsy technique provided a definitive and conclusive diagnosis in 29 (80.6%) of the 36 patients suspected of having gastric infiltrating tumors. Excavating biopsy, snaring biopsy and endoscopic mucosal resection (EMR), which generally cannot obtain the correct deep tissue samples, are considered unsafe due to frequent complications such as haemorrhage and perforation^[18].

GISTs, demonstrated to stem from gain-of-function mutations of the platelet-derived growth factor receptor alpha gene and/or c-kit gene^[19,20], account for 1% of primary gastrointestinal tumors. Although surgical resection has been the main modality of treatment^[21], many cases are locally advanced and unresectable at present. In addition, after curative resections, approximately 40% of cases will develop recurrences in the form of local or distant metastasis^[22,23]. Imatinib mesylate (IM), a tyrosine kinase targeted therapy, is now the standard adjuvant therapy before or after surgical resection of non-metastatic GISTs with a significant risk of recurrence^[24,25]. In locally advanced or unresectable GISTs, use of neoadjuvant IM helps decrease the extent of resection and surgical morbidity by diminishing the tumor and reducing the intraoperative spillage of tumor cells^[26-28]. Obtaining the gene mutation status from the biopsy specimens before neoadjuvant IM therapy makes the process more accurate, which is in accordance with the latest

edition of the NCCN clinical practice guidelines (2016) for gastrointestinal stromal tumors. Decisions to improve the outcomes in the management of GISTs are based on the risk of progression, pathologic characteristics, and tumor location^[29]. Limited by a fine needle, specimens obtained by EUS-FNA are often not sufficient to allow immunohistochemistry and genotype analysis, which could occur with EUS-CHDB with careful operations to reduce the intraoperative spillage of tumor cells^[30].

Using the vertical diathermic loop, gastric infiltrative tumors were open to the biopsy forceps safely by electric coagulation, which resulted in a positive rate of 90% in this study. In particular, for a rigid and tough wall, the diathermic loop, similar to a knife, makes the tumor incised and revealed. The vertical angle makes cutting holes in tumors easier than with other electroexcision tools or biopsy forceps. Under the guidance of EUS, we can determine the most characterized targeted focus, guarantee electroexcision without risk, and avoid areas with abundant irregular branch blood flow signals. In this way, EUS-CHDB was preliminarily proved to be quite safe because neither severe haemorrhaging nor perforation occurred in any patient. In contrast to EUS-FNA, EUS-CHDB is less costly, easier to carry out and, most significantly, allows more histopathology findings. Meanwhile, EUS-CHDB can obtain a larger tissue specimen and may thus increase the rate of positive diagnostic findings compared with conventional biopsies. For the only negative case who was suspected of having GLP but suffered a negative pathology, the rational speculation was focused on an inadequate depth, insufficient biopsy samples or invalid biopsy on the tissue that received electrocoagulation. For negative cases, if necessary, EUS-FNA combined with EUS-CHDB may offer a satisfactory solution.

As a limitation, this study was performed at a single centre with a small number of patients and without a control group. Further large studies on this method are needed to clarify the indications and clinical outcomes.

In conclusion, under the guidance of high-definition longitudinal axis EUS, the vertical diathermic loop can safely and efficiently break up the shield of a thick and rigid wall of the gastric or mucous layer above the tumor. EUS-CHDB may be a technically feasible and safe option for patients with gastric infiltrative tumors or gastrointestinal submucosal tumors. EUS-CHDB could be recommended as a remedial or even preferred biopsy method for some submucosal lesions.

COMMENTS

Background

Gastric infiltrative tumors, such as gastric linitis plastica (GLP) and gastric lymphoma, and gastrointestinal submucosal tumors often have more than one negative pathological finding on ordinary endoscopic biopsies. The authors invented a novel vertical diathermic loop to perform EUS-guided cutting of holes and deep biopsy (EUS-CHDB).

Research frontiers

For patients suspected with gastric infiltrative tumors or gastrointestinal submucosal tumors, diagnosis *via* endoscopic forceps biopsy is often difficult, with a low positive rate in the initial detection. Several novel technologies, such as EUS-guided fine needle aspiration, excavating biopsy, snaring biopsy and endoscopic mucosal resection, have emerged. However, the positive finding rate of the above techniques is still undesirable.

Innovations and breakthroughs

This study reported on a more accurate diagnostic possibility offered by EUS-CHDB for pathologic diagnosis of gastric infiltrative tumors and gastrointestinal submucosal tumors. This new technique was proved to be a safe, technically feasible and more accurate option for patients with gastric infiltrative tumors or gastrointestinal submucosal tumors.

Applications

This study provides the evidence supporting a new technique about biopsy, EUS-CHDB, which may improve the diagnostic accuracy and even assist in the early diagnosis of gastric infiltrative tumors and gastrointestinal submucosal tumors.

Terminology

EUS: an endoscopy with an ultrasonic probe in the head end, which can detect and scan lesions of the gastrointestinal tract, pancreas, liver, gallbladder and adjacent organs by virtue of ultrasound. GLP: a special type of diffuse infiltrative gastric carcinoma with tumor growth direction to the submucosa so that the gastric cavity becomes small and gastric full layer is thickening and hardening.

Peer-review

Gastric infiltrative tumors, such as gastric linitis plastica and gastric lymphoma, and gastrointestinal submucosal tumors often have more than one negative pathological finding on ordinary endoscopic biopsies. The authors invented a novel vertical electrode loop to perform EUS-guided cutting of holes and deep biopsy (EUS-CHDB). The authors report on a more accurate diagnostic possibility offered by EUS-CHDB for pathologic diagnosis of gastric infiltrative tumors and gastrointestinal submucosal tumors. The results are interesting.

REFERENCES

- 1 **Yokota T**, Teshima S, Saito T, Kikuchi S, Kunii Y, Yamauchi H. Borrmann's type IV gastric cancer: clinicopathologic analysis. *Can J Surg* 1999; **42**: 371-376 [PMID: 10526523]
- 2 **Kim JI**, Kim YH, Lee KH, Kim SY, Lee YJ, Park YS, Kim N, Lee DH, Kim HH, Park do J, Lee HS. Type-specific diagnosis and evaluation of longitudinal tumor extent of borrmann type IV gastric cancer: CT versus gastroscopy. *Korean J Radiol* 2013; **14**: 597-606 [PMID: 23901317 DOI: 10.3348/kjr.2013.14.4.597]
- 3 **Yook JH**, Oh ST, Kim BS. Clinicopathological analysis of Borrmann type IV gastric cancer. *Cancer Res Treat* 2005; **37**: 87-91 [PMID: 19956485 DOI: 10.4143/crt.2005.37.2.87]
- 4 **Luo Y**, Gao P, Song Y, Sun J, Huang X, Zhao J, Ma B, Li Y, Wang Z. Clinicopathologic characteristics and prognosis of Borrmann type IV gastric cancer: a meta-analysis. *World J Surg Oncol* 2016; **14**: 49 [PMID: 26912240 DOI: 10.1186/s12957-016-0805-9]
- 5 **Psyrris A**, Papageorgiou S, Economopoulos T. Primary extranodal lymphomas of stomach: clinical presentation, diagnostic pitfalls and management. *Ann Oncol* 2008; **19**: 1992-1999 [PMID: 18647965 DOI: 10.1093/annonc/mdn525]
- 6 **Vetro C**, Chiarenza A, Romano A, Amico I, Calafiore V, Di Raimondo C, Coppolino F, Di Raimondo F. Prognostic assessment and treatment of primary gastric lymphomas: how endoscopic ultrasonography can help in tailoring patient management. *Clin Lymphoma Myeloma Leuk* 2014; **14**: 179-185 [PMID: 24369919 DOI: 10.1016/j.clml.2013.10.010]
- 7 **Mortensen MB**, Edwin B, Hünerbein M, Liedman B, Nielsen HO, Hovendal C. Impact of endoscopic ultrasonography (EUS) on surgical decision-making in upper gastrointestinal tract cancer:

- an international multicenter study. *Surg Endosc* 2007; **21**: 431-438 [PMID: 17180286 DOI: 10.1007/s00464-006-9029-3]
- 8 **Han C**, Lin R, Shi H, Liu J, Qian W, Ding Z, Hou X. The role of endoscopic ultrasound on the preoperative T staging of gastric cancer: A retrospective study. *Medicine* (Baltimore) 2016; **95**: e4580 [PMID: 27603347 DOI: 10.1097/MD.0000000000004580]
 - 9 **Cantor MJ**, Davila RE, Faigel DO. Yield of tissue sampling for subepithelial lesions evaluated by EUS: a comparison between forceps biopsies and endoscopic submucosal resection. *Gastrointest Endosc* 2006; **64**: 29-34 [PMID: 16813799 DOI: 10.1016/j.gie.2006.02.027]
 - 10 **Chiyo T**, Kobara H, Mori H, Katsuki N, Haba R, Masaki T. Submucosal Endoscopic Sampling for Indefinite Gastric Linitis Plastica Infiltrating into the Submucosal Layer. *J Gastrointest Liver Dis* 2015; **24**: 375-378 [PMID: 26405710]
 - 11 **Suekane H**, Iida M, Yao T, Matsumoto T, Masuda Y, Fujishima M. Endoscopic ultrasonography in primary gastric lymphoma: correlation with endoscopic and histologic findings. *Gastrointest Endosc* 1993; **39**: 139-145 [PMID: 8495833]
 - 12 **Butkeviciene L**, Dubinskiene L, Verbiene I. [Diagnosis of malignant lymphoma of the stomach]. *Medicina* (Kaunas) 2002; **38**: 172-175 [PMID: 12474735]
 - 13 **Hunt GC**, Smith PP, Faigel DO. Yield of tissue sampling for submucosal lesions evaluated by EUS. *Gastrointest Endosc* 2003; **57**: 68-72 [PMID: 12518134 DOI: 10.1067/mge.2003.34]
 - 14 **Rong L**, Kida M, Yamauchi H, Okuwaki K, Miyazawa S, Iwai T, Kikuchi H, Watanabe M, Imaizumi H, Koizumi W. Factors affecting the diagnostic accuracy of endoscopic ultrasonography-guided fine-needle aspiration (EUS-FNA) for upper gastrointestinal submucosal or extraluminal solid mass lesions. *Dig Endosc* 2012; **24**: 358-363 [PMID: 22925290 DOI: 10.1111/j.1443-1661.2012.01243.x]
 - 15 **Buscaglia JM**, Nagula S, Jayaraman V, Robbins DH, Vadada D, Gross SA, DiMaio CJ, Pais S, Patel K, Sejal DV, Kim MK. Diagnostic yield and safety of jumbo biopsy forceps in patients with subepithelial lesions of the upper and lower GI tract. *Gastrointest Endosc* 2012; **75**: 1147-1152 [PMID: 22425270 DOI: 10.1016/j.gie.2012.01.032]
 - 16 **Lee JH**, Choi KD, Kim MY, Choi KS, Kim DH, Park YS, Kim KC, Song HJ, Lee GH, Jung HY, Yook JH, Kim BS, Kang YK, Kim JH. Clinical impact of EUS-guided Trucut biopsy results on decision making for patients with gastric subepithelial tumors ≥ 2 cm in diameter. *Gastrointest Endosc* 2011; **74**: 1010-1018 [PMID: 21889136 DOI: 10.1016/j.gie.2011.06.027]
 - 17 **Al-Haddad M**, Savabi MS, Sherman S, McHenry L, Leblanc J, Cramer H, Emerson R, O'Neil J, Khashab M, Dewitt J. Role of endoscopic ultrasound-guided fine-needle aspiration with flow cytometry to diagnose lymphoma: a single center experience. *J Gastroenterol Hepatol* 2009; **24**: 1826-1833 [PMID: 19845824 DOI: 10.1111/j.1440-1746.2009.06005.x]
 - 18 **Zhou XX**, Pan HH, Usman A, Ji F, Jin X, Zhong WX, Chen HT. Endoscopic ultrasound-guided deep and large biopsy for diagnosis of gastric infiltrating tumors with negative malignant endoscopy biopsies. *World J Gastroenterol* 2015; **21**: 3607-3613 [PMID: 25834327 DOI: 10.3748/wjg.v21.i12.3607]
 - 19 **Ahn JB**, Ha TK, Lee HR, Kwon SJ. An Insufficient Preoperative Diagnosis of Borrmann Type 4 Gastric Cancer in Spite of EMR. *J Gastric Cancer* 2011; **11**: 59-63 [PMID: 22076203 DOI: 10.5230/jgc.2011.11.1.59]
 - 20 **Hirota S**, Isozaki K, Moriyama Y, Hashimoto K, Nishida T, Ishiguro S, Kawano K, Hanada M, Kurata A, Takeda M, Muhammad Tunio G, Matsuzawa Y, Kanakura Y, Shinomura Y, Kitamura Y. Gain-of-function mutations of c-kit in human gastrointestinal stromal tumors. *Science* 1998; **279**: 577-580 [PMID: 9438854]
 - 21 **Zheng S**, Chen LR, Wang HJ, Chen SZ. Analysis of mutation and expression of c-kit and PDGFR- α gene in gastrointestinal stromal tumor. *Hepatogastroenterology* 2007; **54**: 2285-2290 [PMID: 18265649]
 - 22 **Roberts PJ**, Eisenberg B. Clinical presentation of gastrointestinal stromal tumors and treatment of operable disease. *Eur J Cancer* 2002; **38** Suppl 5: S37-S38 [PMID: 12528771]
 - 23 **Rutkowski P**, Debiec-Rychter M, Ruka W. Gastrointestinal stromal tumors: key to diagnosis and choice of therapy. *Mol Diagn Ther* 2008; **12**: 131-143 [PMID: 18510377]
 - 24 **Hirota S**, Ohashi A, Nishida T, Isozaki K, Kinoshita K, Shinomura Y, Kitamura Y. Adjuvant imatinib mesylate after resection of localised, primary gastrointestinal stromal tumour: a randomised, doubleblind, placebo-controlled trial. *Lancet* 2009; **373**: 1097-104 [DOI: 10.1016/S0140-6736(09)60500-6]
 - 25 **Joensuu H**, Vehtari A, Riihimäki J, Nishida T, Steigen SE, Brabec P, Plank L, Nilsson B, Cirilli C, Braconi C, Bordoni A, Magnusson MK, Linke Z, Sufliarsky J, Federico M, Jonasson JG, Dei Tos AP, Rutkowski P. Risk of recurrence of gastrointestinal stromal tumour after surgery: an analysis of pooled population-based cohorts. *Lancet Oncol* 2012; **13**: 265-274 [PMID: 22153892 DOI: 10.1016/S1470-2045(11)70299-6]
 - 26 **Joensuu H**, Eriksson M, Sundby Hall K, Hartmann JT, Pink D, Schütte J, Ramadori G, Hohenberger P, Duyster J, Al-Batran SE, Schlemmer M, Bauer S, Wardelmann E, Sarlomo-Rikala M, Nilsson B, Sihto H, Monge OR, Bono P, Kallio R, Vehtari A, Leinonen M, Alvegård T, Reichardt P. One vs three years of adjuvant imatinib for operable gastrointestinal stromal tumor: a randomized trial. *JAMA* 2012; **307**: 1265-1272 [PMID: 22453568 DOI: 10.1001/jama.2012.347]
 - 27 **Shrikhande SV**, Marda SS, Suradkar K, Arya S, Shetty GS, Bal M, Shukla PJ, Goel M, Mohandas KM. Gastrointestinal stromal tumors: case series of 29 patients defining the role of imatinib prior to surgery. *World J Surg* 2012; **36**: 864-871 [PMID: 22350473 DOI: 10.1007/s00268-012-1440-4]
 - 28 **Koontz MZ**, Visser BM, Kunz PL. Neoadjuvant imatinib for borderline resectable GIST. *J Natl Compr Canc Netw* 2012; **10**: 1477-1482; quiz 1482 [PMID: 23221786]
 - 29 **Tielen R**, Verhoef C, van Coevorden F, Gelderblom H, Sleijfer S, Hartgrink HH, Bonenkamp JJ, van der Graaf WT, de Wilt JH. Surgical treatment of locally advanced, non-metastatic, gastrointestinal stromal tumours after treatment with imatinib. *Eur J Surg Oncol* 2013; **39**: 150-155 [PMID: 23084087 DOI: 10.1016/j.ejso.2012.09.004]
 - 30 **von Mehren M**. Management of Gastrointestinal Stromal Tumors. *Surg Clin North Am* 2016; **96**: 1059-1075 [PMID: 27542643 DOI: 10.1016/j.suc.2016.05.011]

P- Reviewer: Fernandez JM, Sato H **S- Editor:** Qi Y **L- Editor:** A
E- Editor: Wang CH





Published by **Baishideng Publishing Group Inc**
7901 Stoneridge Drive, Suite 501, Pleasanton, CA 94588, USA
Telephone: +1-925-223-8242
Fax: +1-925-223-8243
E-mail: bpgoffice@wjgnet.com
Help Desk: <http://www.f6publishing.com/helpdesk>
<http://www.wjgnet.com>



ISSN 1007-9327



9 771007 932045