

World Journal of *Orthopedics*

World J Orthop 2017 July 18; 8(7): 524-605



**MINIREVIEWS**

- 524 Radiation exposure and reduction in the operating room: Perspectives and future directions in spine surgery

Narain AS, Hijji FY, Yom KH, Kudaravalli KT, Haws BE, Singh K

- 531 Use of recombinant human bone morphogenetic protein-2 in spine surgery

Lykissas M, Gkiatas I

ORIGINAL ARTICLE**Basic Study**

- 536 Possibilities for arthroscopic treatment of the ageing sternoclavicular joint

Rathcke M, Tranum-Jensen J, Krosgaard MR

Retrospective Study

- 545 Epidemiology of open fractures in sport: One centre's 15-year retrospective study

Wood AM, Robertson GAJ, MacLeod K, Porter A, Court-Brown CM

- 553 Acetabular revisions using porous tantalum components: A retrospective study with 5-10 years follow-up

Evola FR, Costarella L, Evola G, Barchitta M, Agodi A, Sessa G

- 561 Non-ossifying fibromas: Case series, including in uncommon upper extremity sites

Sakamoto A, Arai R, Okamoto T, Matsuda S

Observational Study

- 567 Distal radius volar rim plate: Technical and radiographic considerations

Spiteri M, Roberts D, Ng W, Matthews J, Power D

SYSTEMATIC REVIEWS

- 574 Return to sport following tibial plateau fractures: A systematic review

Robertson GAJ, Wong SJ, Wood AM

- 588 Systematic review on the use of autologous matrix-induced chondrogenesis for the repair of articular cartilage defects in patients

Shaikh N, Seah MKT, Khan WS

CASE REPORT

- 602 Painless swollen calf muscles of a 75-year-old patient caused by bilateral venous malformations

Piekaar RSM, Zwitter EW, Hedeman Joosten PPA, Jansen JA

Contents

World Journal of Orthopedics
Volume 8 Number 7 July 18, 2017

ABOUT COVER

Editorial Board Member of *World Journal of Orthopedics*, Michalis Zenios, BM BCh, MSc, Senior Lecturer, Paediatric Orthopaedics, University of Nicosia, Limassol 3025, Cyprus

AIM AND SCOPE

World Journal of Orthopedics (*World J Orthop*, *WJO*, online ISSN 2218-5836, DOI: 10.5312) is a peer-reviewed open access academic journal that aims to guide clinical practice and improve diagnostic and therapeutic skills of clinicians.

WJO covers topics concerning arthroscopy, evidence-based medicine, epidemiology, nursing, sports medicine, therapy of bone and spinal diseases, bone trauma, osteoarthritis, bone tumors and osteoporosis, minimally invasive therapy, diagnostic imaging. Priority publication will be given to articles concerning diagnosis and treatment of orthopedic diseases. The following aspects are covered: Clinical diagnosis, laboratory diagnosis, differential diagnosis, imaging tests, pathological diagnosis, molecular biological diagnosis, immunological diagnosis, genetic diagnosis, functional diagnostics, and physical diagnosis; and comprehensive therapy, drug therapy, surgical therapy, interventional treatment, minimally invasive therapy, and robot-assisted therapy.

We encourage authors to submit their manuscripts to *WJO*. We will give priority to manuscripts that are supported by major national and international foundations and those that are of great basic and clinical significance.

INDEXING/ABSTRACTING

World Journal of Orthopedics is now indexed in Emerging Sources Citation Index (Web of Science), PubMed, PubMed Central and Scopus.

FLYLEAF

I-III Editorial Board

EDITORS FOR THIS ISSUE

Responsible Assistant Editor: *Xiang Li*
Responsible Electronic Editor: *Huan-Liang Wu*
Proofing Editor-in-Chief: *Lian-Sheng Ma*

Responsible Science Editor: *Jin-Xin Kong*
Proofing Editorial Office Director: *Jin-Lei Wang*

NAME OF JOURNAL
World Journal of Orthopedics

ISSN
ISSN 2218-5836 (online)

LAUNCH DATE
November 18, 2010

FREQUENCY
Monthly

EDITORS-IN-CHIEF
Quanjun (Trey) Cui, MD, Professor, Department of Orthopaedic Surgery, School of Medicine, University of Virginia, Charlottesville, VA 22908, United States

Bao-Gan Peng, MD, PhD, Professor, Department of Spinal Surgery, General Hospital of Armed Police Force, Beijing 100039, China

EDITORIAL BOARD MEMBERS
All editorial board members resources online at <http://www.wjgnet.com>

www.wjgnet.com/2218-5836/editorialboard.htm

EDITORIAL OFFICE
Xiu-Xia Song, Director
World Journal of Orthopedics
Baishideng Publishing Group Inc
7901 Stoneridge Drive, Suite 501, Pleasanton, CA 94588, USA
Telephone: +1-925-2238242
Fax: +1-925-2238243
E-mail: editorialoffice@wjgnet.com
Help Desk: <http://www.fjpublishing.com/helpdesk>
<http://www.wjgnet.com>

PUBLISHER
Baishideng Publishing Group Inc
7901 Stoneridge Drive,
Suite 501, Pleasanton, CA 94588, USA
Telephone: +1-925-2238242
Fax: +1-925-2238243
E-mail: bpgoffice@wjgnet.com
Help Desk: <http://www.fjpublishing.com/helpdesk>
<http://www.wjgnet.com>


PUBLICATION DATE
July 18, 2017

COPYRIGHT
© 2017 Baishideng Publishing Group Inc. Articles published by this Open-Access journal are distributed under the terms of the Creative Commons Attribution Non-commercial License, which permits use, distribution, and reproduction in any medium, provided the original work is properly cited, the use is non commercial and is otherwise in compliance with the license.

SPECIAL STATEMENT
All articles published in journals owned by the Baishideng Publishing Group (BPG) represent the views and opinions of their authors, and not the views, opinions or policies of the BPG, except where otherwise explicitly indicated.

INSTRUCTIONS TO AUTHORS
<http://www.wjgnet.com/bpg/gerinfo/204>

ONLINE SUBMISSION
<http://www.fjpublishing.com>



Retrospective Study

Non-ossifying fibromas: Case series, including in uncommon upper extremity sites

Akio Sakamoto, Ryuzo Arai, Takeshi Okamoto, Shuichi Matsuda

Akio Sakamoto, Ryuzo Arai, Takeshi Okamoto, Shuichi Matsuda, Department of Orthopaedic Surgery, Graduate School of Medicine, Kyoto University, Kyoto City 606-8507, Japan

Author contributions: Sakamoto A drafted the manuscript; Arai R and Okamoto T participated in the design of the study; Matsuda S conceived of the study, participated in its design and coordination, and helped draft the manuscript; all authors read and approved the final manuscript.

Institutional review board statement: This study was reviewed and approved by the Ethics Committee of National Hospital Organization, Kokura Medical Center, Kitakyushu city, Japan, where the research was performed.

Informed consent statement: Patients were not required to give informed consent to the study because the analysis used anonymous clinical data that were obtained after each patient had been notified at the home page of National Hospital Organization, Kokura Medical Center that the data could be used for a clinical study.

Conflict-of-interest statement: The authors have no financial relationships to disclose.

Data sharing statement: No additional data are available.

Open-Access: This article is an open-access article which was selected by an in-house editor and fully peer-reviewed by external reviewers. It is distributed in accordance with the Creative Commons Attribution Non Commercial (CC BY-NC 4.0) license, which permits others to distribute, remix, adapt, build upon this work non-commercially, and license their derivative works on different terms, provided the original work is properly cited and the use is non-commercial. See: <http://creativecommons.org/licenses/by-nc/4.0/>

Manuscript source: Unsolicited manuscript

Correspondence to: Akio Sakamoto, MD, Lecturer, Department of Orthopaedic Surgery, Graduate School of Medicine, Kyoto University, Shogoin, Kawahara-cho 54, Sakyo-ku, Kyoto City 606-8507, Japan. akiosaka@kuhp.kyoto-u.ac.jp
Telephone: +81-75-7513366

Fax: +81-75-7518409

Received: January 13, 2017

Peer-review started: January 16, 2017

First decision: March 28, 2017

Revised: April 10, 2017

Accepted: May 3, 2017

Article in press: May 5, 2017

Published online: July 18, 2017

Abstract

AIM

To investigate non-ossifying fibromas (NOFs) common fibrous bone lesions in children that occur in bones of the lower extremities.

METHODS

We analyzed 44 cases of NOF including 47 lesions, which were referred with a working diagnosis of neoplastic lesions. Lesions were located in the upper extremities (1 proximal humerus, 1 distal radius) and the lower extremities (25 distal femurs, 12 proximal and 4 distal tibias, and 4 proximal fibulas).

RESULTS

Three cases had NOFs in multiple anatomical locations (femur and fibula in 1 case, femur and tibia in 2 cases). Overall, larger lesions > 4 cm and lesion expansion at the cortex were seen in 21% and 32% of cases, respectively. Multiple lesions with bilateral symmetry in the lower extremities suggest that these NOFs were developmental bone defects. Two patients suffered from fracture and were treated without surgery, one in the radius and one in the femur. Lesions in the upper extremities (*i.e.*, humerus of a 4-year-old female and radius of a 9-year-old male) expanded at the cortex and lesion size increased with slow ossification.

CONCLUSION

NOFs in the lower extremity had fewer clinical problems, regardless of their size and expansiveness. In these two upper extremity cases, the NOFs had aggressive biological features. It seems that there is a site specific difference, especially between the upper extremity and the lower extremity. Furthermore, NOFs in the radius are predisposed to fracture because of the slender structure of the radius and the susceptibility to stress.

Key words: Non-ossifying fibroma; Humerus; Radius; Fibula; Upper extremity

© **The Author(s) 2017.** Published by Baishideng Publishing Group Inc. All rights reserved.

Core tip: Non-ossifying fibromas (NOFs) are common lesions in the lower extremities of children. We analyzed 44 cases of NOF including 47 lesions comprising 2 upper extremity cases and 45 lower extremity cases. Larger lesions > 4 cm and lesion expansion at the cortex were seen in 21% and 32% of cases, respectively. Lesions in the upper extremities in the humerus and the radius expanded at the cortical bone, and lesion size increased with slow ossification, suggestive of aggressive biological features. Furthermore, NOFs in the radius are predisposed to fracture because of the slender structure of the radius and the susceptibility to stress.

Sakamoto A, Arai R, Okamoto T, Matsuda S. Non-ossifying fibromas: Case series, including in uncommon upper extremity sites. *World J Orthop* 2017; 8(7): 561-566 Available from: URL: <http://www.wjgnet.com/2218-5836/full/v8/i7/561.htm> DOI: <http://dx.doi.org/10.5312/wjo.v8.i7.561>

INTRODUCTION

Non-ossifying fibromas (NOFs) are a common type of benign fibrous lesion that tend to occur in the metaphysis of the long bones in the lower extremities^[1,2]. NOF can be diagnosed based on its presentation on plain radiographs^[3,4] where it typically appears as a small, cortical osteolytic lesion. Approximately 30% of young patients in their first or second decade of life can have a NOF^[2]. Typically, NOFs are asymptomatic and lesions are found incidentally. A lesion is usually self-limiting and disappears by the age of 20 to 25 years in most cases^[3]. Therefore, lesions are considered to be a developmental bone defect rather than a true neoplasm^[1,2]. Histologically, NOFs are composed of spindle-shaped fibroblasts, multinucleated giant cells, and foamy histiocytes, which are identical to a benign fibrous histiocytoma (BFH), which is a neoplastic lesion^[2]. BFHs occur predominantly in adults, and a BFH is considered to have more aggressive biological features compared with a NOF. Interestingly, the current case series includes some patients with NOFs in less common sites such as the humerus, radius, and

fibula. Herein we discuss upper and lower extremity NOFs and emphasize the anatomical differences between them.

MATERIALS AND METHODS

A clinical summary of the 44 cases of NOF is shown in Table 1. A total of 47 lesions were referred to our institution with a working diagnosis of neoplastic lesions. A diagnosis of NOF was made based on plain radiographic findings. NOF appears as a cortically based osteolytic lesion with an osteosclerotic rim. In cases with atypically large lesions, a magnetic resonance image (MRI) examination was added in order to exclude aggressive bone tumors, such as osteosarcomas. The NOF cases we analyzed were in 26 males and 18 females. The average age at the first visit was 10.5 (range, 4 to 16) years. The NOFs were located in a humerus ($n = 1$), radius ($n = 1$), femurs ($n = 25$), tibias ($n = 16$), and fibulas ($n = 4$). Among these cases, lesions occurred in multiple locations in 3 cases with femur involvement, in 2 cases with tibia involvement and in 1 case with femur and fibula involvement. Bilateral lesions, in which the size and the location were almost symmetrical such that we counted them as a single lesion, were seen in 3 cases with femur involvement. The location of each lesion was also classified as anterior, medial, lateral, posterior, or inter-medullary. Findings of expansion at the cortices adjacent to lesions were assessed. A lesion > 4 cm in size was defined as large.

RESULTS

Among the NOF cases, a lesion size > 4 cm was seen in 10 out of 47 (21%) cases. Cortical expansions were seen in 15 out of 47 (32%) cases. The cases of upper extremity NOFs involved 1 humerus and 1 radius. A 4-year-old female had a NOF on the proximal side of her humerus. Plain radiographs revealed a multinodular osteolytic lesion in the cortex on the anterior aspect of the humerus. Thinning and expansion of the adjacent cortex was observed. During a 7-mo follow-up, it was noted that the size of the lesion had increased. Ossification was seen, but the earlier osteolytic finding was still prominent on a follow-up radiograph taken 31 mo later (Figure 1). A 9-year-old male had a NOF on the distal diaphysis of his radius. The lesion was discovered when he sustained a pathological fracture at the site of the lesion. Upon initial assessment, the plain radiographs revealed an irregularity of the adjacent cortex, suggesting a fracture. An osteolytic lesion with marginal sclerosis was seen. The size of the lesion was observed to increase at a 2 years and 5 mo follow-up because the patient had refractured his radius at the lesion site. Although ossification was evident on the proximal aspect of the lesion, an osteolytic lesion was also prominent at the 3-year follow-up (Figure 2).

The cases of lower extremity NOFs involved femurs,

Table 1 Clinical summary of 44 cases with non-ossifying fibromas

Bone site	NOFs, <i>n</i>	M:F	Mean age, yr	R/L/B extremities, <i>n</i>	Lesion > 4 cm, <i>n</i> (%)	Ant/med/lat/post/intramed location, <i>n</i>	Expansion, <i>n</i> (%)	Fracture, <i>n</i> (%)
Humerus	1							
Proximal	1	0:1	4.0	1/0/0	1 (100)	1/0/0/0/0	1 (100)	0
Radius	1							
Distal	1	1:0	7.0	0/1/0	0	0/0/0/0/1	1 (100)	1 (100)
Femur	25							
Distal	25	15:10	9.2	9/9/7	5 (20)	0/5/0/20/0	5 (20)	1 (4)
Tibia	16							
Proximal	12	8:4	14.5	6/6/0	2 (17)	0/4/1/7/0	3 (25)	0
Distal	4	2:2	13.5	3/1/0	2 (50)	0/0/4/0/0	2 (50)	0
Fibula	4							
Proximal	4	2:2	12.5	2/2/0	0	0/0/1/3/0	3 (75)	0
Total lesions ¹	47	26:18	10.5	21/19/7	10 (21)	1/9/6/30/1	15 (32)	2 (4)

¹Total cases *n* = 44. Ant: Anterior; B: Bilateral; F: Female; intramed: Intramedullary; L: Left; lat: Lateral; M: Male; med: Medial; NOFs: Non-ossifying fibromas; post: Posterior; R: Right.

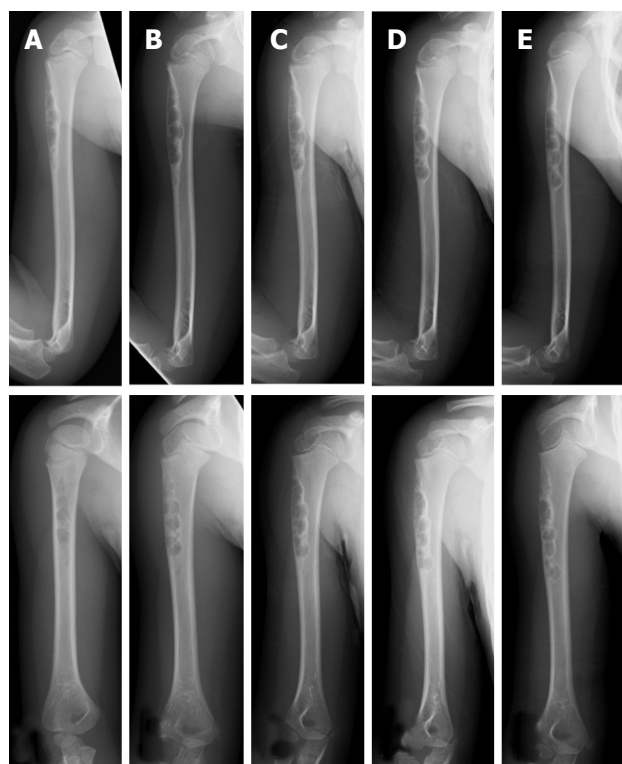


Figure 1 Plain radiographs of a non-ossifying fibroma in the humerus of a 4-year-old female. An osteolytic lesion is shown at the cortex in the proximal humerus (A). Radiographs taken after 7 mo (B), 1 year (C), 1 year and 7 mo (D), and 2 years and 7 mo (E) together reveal the location of the lesion became more distal with growth of the child. The size of the lesion increased as it slowly ossified (plain radiographs: Anteroposterior view, top; lateral view, bottom).

tibias, and fibulas. All femoral lesions were at distal locations. Both large-sized lesions with expansion at the cortex were seen in 20% of cases with femoral involvement. One case of NOF in the femur was diagnosed with a concurrent fracture based on an MRI finding of a high signal intensity at the cortex adjacent to the lesion (Figure 3). Of the 16 cases with tibia involvement, 12 lesions were in a proximal location and 4 were distal. Large-sized lesions occurred in 2

out of 12 (17%) cases in the proximal tibia and in 2 out of 4 (50%) cases in the distal tibia. Extension at the cortex was seen in 3 out of 12 (25%) cases in the proximal tibia and in 2 out of 4 (50%) cases in the distal tibia. These femoral and tibial lesions were in either the medial, lateral, or posterior locations, in contrast to the anterior location in the case of humerus involvement. All 4 cases of NOFs in fibulas presented with lesions in proximal locations. NOF cases with cortical expansion were seen in 3 out of 4 (75%) cases with fibula involvement. One fibular case had multiple lesions that included the femur (Figure 4).

DISCUSSION

NOF predominantly occurs in the lower extremities, especially around the knee^[1,2]. In the current series, the frequency of a distal location in the femur was rather low, because all the referred cases were considered as potential neoplastic lesions, and when small more typical NOFs in the distal femur were identified, the patients were not referred. NOFs are not considered to be true neoplasms, but rather a developmental bone defect^[1-3]. Cases with multiple affected locations, such as the femur and fibula or the femur and tibia, support the notion of a natural developmental defect.

Findings of lesion size increases with expansion at the cortex suggest NOFs can be more aggressive in nature. Cytological abnormalities of translocation (1;4)(p31;q34) and del(4)(p14) supplied evidence for some NOFs with neoplastic characteristics^[5,6]. It is possible that NOFs could have a neoplastic nature because histologically they are indistinguishable from the neoplastic lesions of BFH, which are more aggressive in nature than those of NOFs^[7]. Using image analysis techniques to differentiate between BFHs and NOFs, BFHs appear more likely to have less distinct borders that are central rather than eccentric^[7,8]. BFHs tend to occur in adults, while the vast majority of cases of NOF occur in children. However, it has been

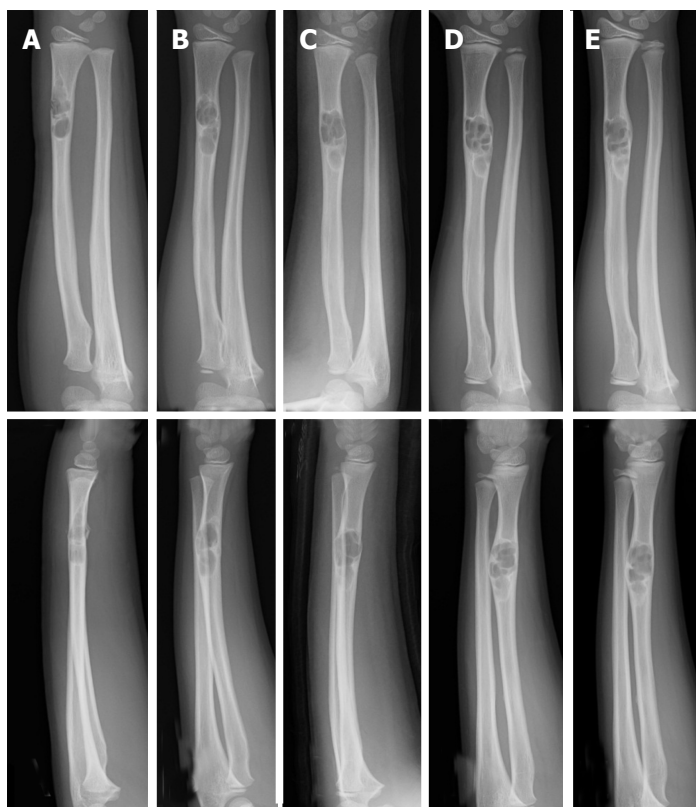


Figure 2 Plain radiographs of a non-ossifying fibroma in the radius of a 9-year-old male. At the initial assessment an osteolytic lesion in the distal radius is shown with an osteosclerotic rim. Fracture of the irregular adjacent cortex is revealed (A). Radiographs taken after 11 mo (B), 2 years and 1 mo (C), 2 years and 5 mo (D), and 3 years (E). The size of the lesion increased and ossification at the distal end was observed (plain radiographs: Anteroposterior view, top; lateral view, bottom).

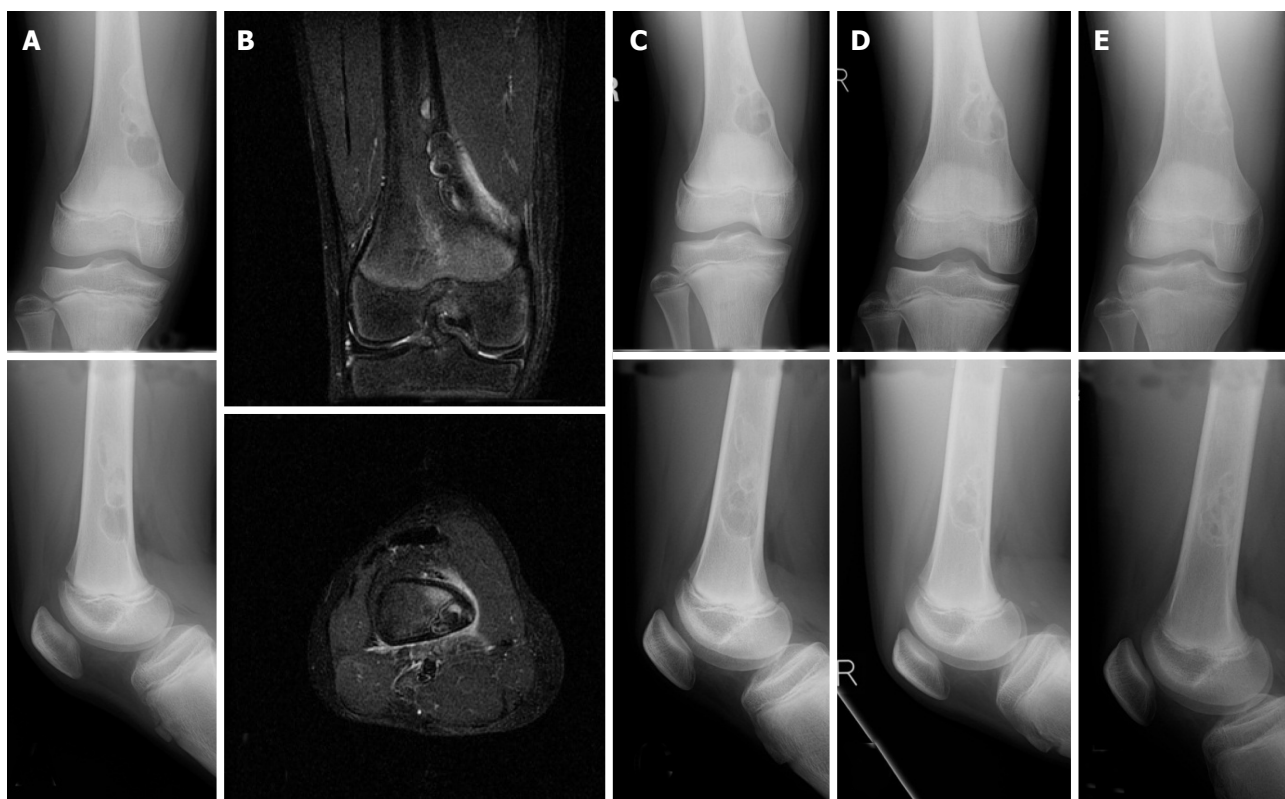

Figure 3 Plain radiograph and MRI of a NOF in the femur of a 13-year-old male who sustained a fracture. The plain radiographs reveal a multinodular lesion located at the medial posterior part of the distal femur. The lesion is osteolytic at the distal end and ossified at the proximal end. The lesion has expanded at the medial cortex (A). T2-weighted fat-suppression MRIs show high signal intensity and suggest the presence of a fracture (B) (coronal, top; axial, bottom). Radiographs taken after 1 year (C), 1 year and 8 mo (D), and 2 years and 8 mo (E); these radiographs reveal the lesion had enlarged as well as ossified (plain radiographs: anteroposterior view, top; lateral view, bottom).

proposed that BFHs may be underestimated among patients less than 20 years of age, and the diagnosis

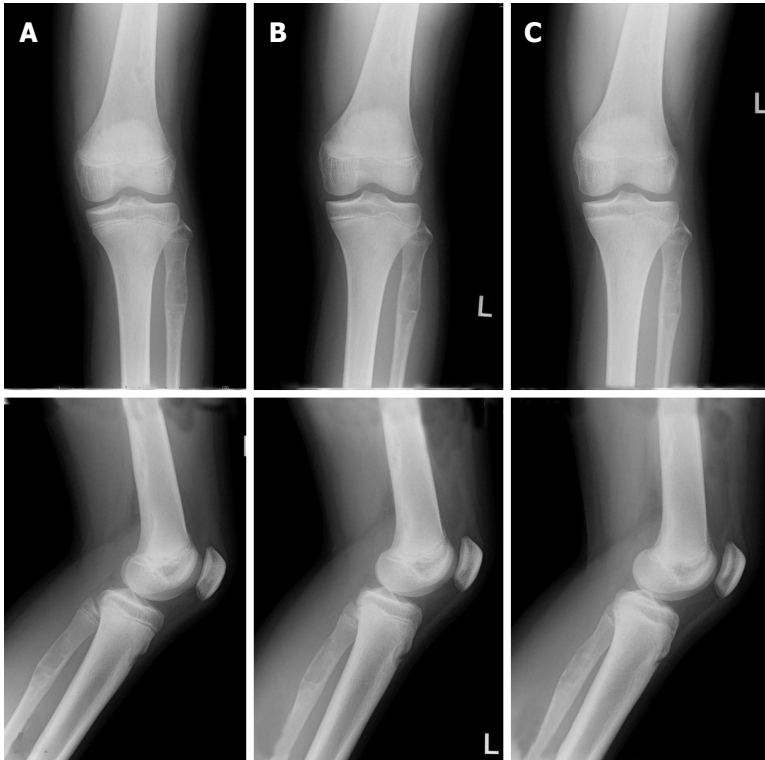


Figure 4 Plain radiographs of non-ossifying fibromas in the femur and the fibula of a 13-year-old female. The radiographs reveal an osteolytic lesion in the proximal fibula, as well as a NOF in the distal femur (A). Radiographs taken after 9 mo (B) and 1 year and 9 mo (C); the femoral and fibular lesions ossified (plain radiographs: Anteroposterior view, top; lateral view, bottom).

of BFH should be considered when NOF-like pathology is accompanied by pain or rapid lesion growth^[7]. In the current series, NOFs in the lower extremities ossified, even in cases with large lesions that increased in size, but none was diagnosed as BFH.

NOFs located in the humerus and radius were included in this study although the upper extremities are an uncommon site for these lesions. Both lesions had extended at the cortex and lesion size increased over time; however, ossification was observed despite osteolytic findings still being prominent at 3 years of follow up. Although the number of upper extremity NOF cases was small, they can have an aggressive nature with BFH-like features when compared with the NOFs in the lower extremities. The NOF located in the radius resulted in a complication when the patient sustained repeated fractures. NOF lesions that occupy more than 50% of the transverse diameter of the involved bone are more likely to lead to a fracture^[2,9]. The slender anatomical structure of the radius would also have contributed to the risk of a pathological fracture at the location of the NOF in this case.

In conclusion, NOFs in lower extremities have the non-neoplastic characteristics of a developmental bone defect. In contrast, NOFs in the humerus and the radius tended to have more aggressive biological characteristics similar in nature to those of BFHs with expansion at the cortex, an increase in size, and slow ossification. It seems that there is a site specific difference between the upper and lower extremities.

In addition, NOFs in the radius are potentially prone to fracture because of the slender structure of the affected bone.

COMMENTS

Background

Non-ossifying fibromas (NOFs) are a common type of benign fibrous lesion that tend to occur in the metaphysis of the long bones in the lower extremities. The upper extremity is less common for NOFs. NOFs are considered to be a developmental bone defect rather than a true neoplasm. However, the histology of NOFs is identical to that of benign fibrous histiocytoma, which is a neoplastic lesion.

Research frontiers

Small NOFs have no clinical significance. The neoplastic characterization of NOFs was difficult. Therefore, the authors collected NOF cases that were referred with a working diagnosis of neoplastic lesions. Consequently, large NOFs with possible aggressive characteristics, as well as NOFs in rare locations, were collected.

Innovations and breakthroughs

The authors analyzed 44 cases of NOFs including 47 lesions comprising two upper extremity cases and 45 lower extremity cases. Clinical information and plain radiographs were collected. The findings associated with possible aggressiveness were further analyzed, such as incidence of fracture and radiographic observations of size and expansiveness. It seems that there is a site specific difference between the upper and lower extremities. NOFs in the lower extremity are considered to be a developmental bone defect rather than a true neoplasm, even though NOFs can be large and have expansion at the cortex. Lesions in the humerus and the radius were expanded at the cortex and lesion size increased with slow ossification. Furthermore, NOFs in the radius are predisposed to fracture because of the slender structure of the radius and

its susceptibility to stress.

Applications

The results are useful for clinicians in the making a diagnosis of NOF and following up the patients.

Terminology

NOF: Non-ossifying fibroma; BFH: Benign fibrous histiocytoma; MRI: Magnetic resonance image.

Peer-review

This is a well-designed paper about a rarely seen clinical condition.

REFERENCES

- 1 **Hetts SW**, Hilchey SD, Wilson R, Franc B. Case 110: Nonossifying fibroma. *Radiology* 2007; **243**: 288-292 [PMID: 17392261 DOI: 10.1148/radiol.2431040427]
- 2 **Dorfman HD**, Czerniak B. Bone tumors. St Louis, MO, Mosby, 1998. *Hum Pathol* 1999; **30**: 1269
- 3 **Betsy M**, Kupersmith LM, Springfield DS. Metaphyseal fibrous defects. *J Am Acad Orthop Surg* 2004; **12**: 89-95 [PMID: 15089082 DOI: 10.5435/00124635-200403000-00004]
- 4 **Hod N**, Levi Y, Fire G, Cohen I, Ayash D, Somekh M, Horne T. Scintigraphic characteristics of non-ossifying fibroma in military recruits undergoing bone scintigraphy for suspected stress fractures and lower limb pains. *Nucl Med Commun* 2007; **28**: 25-33 [PMID: 17159546 DOI: 10.1097/MNM.0b013e328012e3de]
- 5 **Nelson M**, Perry D, Ginsburg G, Sanger WG, Neff JR, Bridge JA. Translocation (1; 4)(p31; q34) in nonossifying fibroma. *Cancer Genet Cytogenet* 2003; **142**: 142-144 [PMID: 12699892 DOI: 10.1016/S0165-4608(02)00805-1]
- 6 **Tarkkanen M**, Kaipainen A, Karaharju E, Böhling T, Szymanska J, Heliö H, Kivioja A, Elomaa I, Knuutila S. Cytogenetic study of 249 consecutive patients examined for a bone tumor. *Cancer Genet Cytogenet* 1993; **68**: 1-21 [PMID: 8330278 DOI: 10.1016/0165-4608(93)90068-W]
- 7 **Ceroni D**, Dayer R, De Coulon G, Kaelin A. Benign fibrous histiocytoma of bone in a paediatric population: a report of 6 cases. *Musculoskelet Surg* 2011; **95**: 107-114 [PMID: 21409501 DOI: 10.1007/s12306-011-0115-x]
- 8 **Al-Jamali J**, Gerlach UV, Zajonc H. Benign fibrous histiocytoma of the distal radius: a report of a case and a review of the literature. *Hand Surg* 2010; **15**: 127-129 [PMID: 20672403 DOI: 10.1142/S0218810410004722]
- 9 **Easley ME**, Kneisl JS. Pathologic fractures through nonossifying fibromas: is prophylactic treatment warranted? *J Pediatr Orthop* 1997; **17**: 808-813 [PMID: 9591988 DOI: 10.1097/01241398-199711000-00021]

P- Reviewer: Demiroz SM **S- Editor:** Ji FF **L- Editor:** A
E- Editor: Wu HL





Published by **Baishideng Publishing Group Inc**
7901 Stoneridge Drive, Suite 501, Pleasanton, CA 94588, USA
Telephone: +1-925-223-8242
Fax: +1-925-223-8243
E-mail: bpgoffice@wjgnet.com
Help Desk: <http://www.f6publishing.com/helpdesk>
<http://www.wjgnet.com>

