

World Journal of *Orthopedics*

World J Orthop 2017 September 18; 8(9): 660-746



**DIAGNOSTIC ADVANCES**

- 660 Clinical applications of advanced magnetic resonance imaging techniques for arthritis evaluation
Martín Noguerol T, Luna A, Gómez Cabrera M, Riofrio AD

MINIREVIEWS

- 674 Mesenchymal stem cells for cartilage regeneration in osteoarthritis
Kristjánsson B, Honsawek S

ORIGINAL ARTICLE**Basic Study**

- 681 Electron probe microanalysis of experimentally stimulated osteoarthrosis in dogs
Stupina T, Shchudlo M, Stepanov M
- 688 Benefits of Ilizarov automated bone distraction for nerves and articular cartilage in experimental leg lengthening
Shchudlo N, Varsegova T, Stupina T, Shchudlo M, Saifutdinov M, Yemanov A

Retrospective Study

- 697 Lumbar ganglion cyst: Nosology, surgical management and proposal of a new classification based on 34 personal cases and literature review
Domenicucci M, Ramieri A, Marruzzo D, Missori P, Miscusi M, Tarantino R, Delfini R
- 705 Acetabular components with or without screws in total hip arthroplasty
Pepe M, Kocadal O, Erener T, Ceritoglu K, Aksahin E, Aktekin CN
- 710 Single-stage anterior debridement and reconstruction with tantalum mesh cage for complicated infectious spondylitis
Yang SC, Chen HS, Kao YH, Tu YK

Prospective Study

- 719 Association of adiponectin gene polymorphisms with knee osteoarthritis
Zhan D, Thumtecho S, Tanavalee A, Yuktanandana P, Anomasiri W, Honsawek S

SYSTEMATIC REVIEWS

- 726 Osteoarthritis action alliance consensus opinion - best practice features of anterior cruciate ligament and lower limb injury prevention programs
Trojan T, Driban J, Nuti R, Distefano L, Root H, Nistler C, LaBella C

CASE REPORT

- 735 Using humeral nail for surgical reconstruction of femur in adolescents with osteogenesis imperfecta
Sa-ngasoongsong P, Saisongcroh T, Angsanuntsukh C, Woratanarat P, Mulpruek P
- 741 Hernia mesh prevent dislocation after wide excision and reconstruction of giant cell tumor distal radius
Wiratnaya IGE, Budiarta IGBAM, Setiawan IGNU, Sindhughosa DA, Kawiya IKS, Astawa P

Contents

World Journal of Orthopedics
Volume 8 Number 9 September 18, 2017

ABOUT COVER

Editorial Board Member of *World Journal of Orthopedics*, Michel PJ van den Bekerom, MD, Staff Physician, Department of Orthopaedic Surgery, Shoulder and Elbow Unit, OLVG, Amsterdam 1090, The Netherlands

AIM AND SCOPE

World Journal of Orthopedics (*World J Orthop*, *WJO*, online ISSN 2218-5836, DOI: 10.5312) is a peer-reviewed open access academic journal that aims to guide clinical practice and improve diagnostic and therapeutic skills of clinicians.

WJO covers topics concerning arthroscopy, evidence-based medicine, epidemiology, nursing, sports medicine, therapy of bone and spinal diseases, bone trauma, osteoarthritis, bone tumors and osteoporosis, minimally invasive therapy, diagnostic imaging. Priority publication will be given to articles concerning diagnosis and treatment of orthopedic diseases. The following aspects are covered: Clinical diagnosis, laboratory diagnosis, differential diagnosis, imaging tests, pathological diagnosis, molecular biological diagnosis, immunological diagnosis, genetic diagnosis, functional diagnostics, and physical diagnosis; and comprehensive therapy, drug therapy, surgical therapy, interventional treatment, minimally invasive therapy, and robot-assisted therapy.

We encourage authors to submit their manuscripts to *WJO*. We will give priority to manuscripts that are supported by major national and international foundations and those that are of great basic and clinical significance.

INDEXING/ABSTRACTING

World Journal of Orthopedics is now indexed in Emerging Sources Citation Index (Web of Science), PubMed, PubMed Central and Scopus.

FLYLEAF

I-III Editorial Board

EDITORS FOR THIS ISSUE

Responsible Assistant Editor: *Xiang Li*
Responsible Electronic Editor: *Ya-Jing Lu*
Proofing Editor-in-Chief: *Lian-Sheng Ma*

Responsible Science Editor: *Fang-Fang Ji*
Proofing Editorial Office Director: *Jin-Lai Wang*

NAME OF JOURNAL
World Journal of Orthopedics

ISSN
ISSN 2218-5836 (online)

LAUNCH DATE
November 18, 2010

FREQUENCY
Monthly

EDITORS-IN-CHIEF
Quanjun (Trey) Cui, MD, Professor, Department of Orthopaedic Surgery, School of Medicine, University of Virginia, Charlottesville, VA 22908, United States

Bao-Gan Peng, MD, PhD, Professor, Department of Spinal Surgery, General Hospital of Armed Police Force, Beijing 100039, China

EDITORIAL BOARD MEMBERS
All editorial board members resources online at <http://www.wjgnet.com>

www.wjgnet.com/2218-5836/editorialboard.htm

EDITORIAL OFFICE
Xiu-Xia Song, Director
World Journal of Orthopedics
Baishideng Publishing Group Inc
7901 Stoneridge Drive, Suite 501, Pleasanton, CA 94588, USA
Telephone: +1-925-2238242
Fax: +1-925-2238243
E-mail: editorialoffice@wjgnet.com
Help Desk: <http://www.fgpublishing.com/helpdesk>
<http://www.wjgnet.com>

PUBLISHER
Baishideng Publishing Group Inc
7901 Stoneridge Drive,
Suite 501, Pleasanton, CA 94588, USA
Telephone: +1-925-2238242
Fax: +1-925-2238243
E-mail: bpgoffice@wjgnet.com
Help Desk: <http://www.fgpublishing.com/helpdesk>
<http://www.wjgnet.com>

PUBLICATION DATE
September 18, 2017

COPYRIGHT
© 2017 Baishideng Publishing Group Inc. Articles published by this Open-Access journal are distributed under the terms of the Creative Commons Attribution Non-commercial License, which permits use, distribution, and reproduction in any medium, provided the original work is properly cited, the use is non commercial and is otherwise in compliance with the license.

SPECIAL STATEMENT
All articles published in journals owned by the Baishideng Publishing Group (BPG) represent the views and opinions of their authors, and not the views, opinions or policies of the BPG, except where otherwise explicitly indicated.

INSTRUCTIONS TO AUTHORS
<http://www.wjgnet.com/bpg/gerinfo/204>

ONLINE SUBMISSION
<http://www.fgpublishing.com>

Retrospective Study

Lumbar ganglion cyst: Nosology, surgical management and proposal of a new classification based on 34 personal cases and literature review

Maurizio Domenicucci, Alessandro Ramieri, Daniele Marruzzo, Paolo Missori, Massimo Miscusi, Roberto Tarantino, Roberto Delfini

Maurizio Domenicucci, Daniele Marruzzo, Paolo Missori, Roberto Tarantino, Roberto Delfini, Department of Neurological and Psychiatric, Sapienza University of Rome, 00185 Rome, Italy

Alessandro Ramieri, Orthopedic Division, Don Gnocchi Foundation, 20148 Milan, Italy

Massimo Miscusi, Department of Medico-Surgical Sciences and Biotechnologies, Sapienza University of Rome, 04100 Latina, Italy

Author contributions: All the authors contributed to this manuscript.

Institutional review board statement: This study was exempt from the Institutional Review Board standards.

Conflict-of-interest statement: None.

Data sharing statement: None.

Open-Access: This article is an open-access article which was selected by an in-house editor and fully peer-reviewed by external reviewers. It is distributed in accordance with the Creative Commons Attribution Non Commercial (CC BY-NC 4.0) license, which permits others to distribute, remix, adapt, build upon this work non-commercially, and license their derivative works on different terms, provided the original work is properly cited and the use is non-commercial. See: <http://creativecommons.org/licenses/by-nc/4.0/>

Manuscript source: Invited manuscript

Correspondence to: Massimo Miscusi, MD, PhD, Department of Medico-Surgical Sciences and Biotechnologies, Sapienza University of Rome, Corso della Repubblica 79, 04100 Latina, Italy. massimo.miscusi@uniroma1.it
Telephone: +39-773-1757222

Received: January 23, 2017

Peer-review started: February 7, 2017

First decision: May 2, 2017

Revised: July 23, 2017

Accepted: August 2, 2017

Article in press: August 3, 2017

Published online: September 18, 2017

Abstract

AIM

To analyze different terms used in literature to identify lumbar extradural cysts and propose a common scientific terminology; to elaborate a new morphological classification of this pathology, useful for clinical and surgical purposes; and to describe the best surgical approach to remove these cysts, in order to avoid iatrogenic instability or treat the pre-existing one.

METHODS

We retrospectively reviewed 34 patients with symptomatic lumbar ganglion cysts treated with spinal canal decompression with or without spinal fixation. Microsurgical approach was the main procedure and spinal instrumentation was required only in case of evident pre-operative segmental instability.

RESULTS

The complete cystectomy with histological examination was performed in all cases. All patients presented an improvement of clinical conditions, evaluated by Visual Analogic Scale and Japanese Orthopaedic Association scoring.

CONCLUSION

Spinal ganglion cysts are generally found in the lumbar spine. The treatment of choice is the microsurgical cystectomy, which generally does not require stabilization.

The need for fusion must be carefully evaluated: Pre-operative spondylolisthesis or a wide joint resection, during the operation, are the main indications for spinal instrumentation. We propose the terms "ganglion cyst" to finally identify this spinal pathology and for the first time its morphological classification, clinically useful for all specialists.

Key words: Synovial cyst; Lumbar spine; Instability; Surgery; Ganglion

© **The Author(s) 2017.** Published by Baishideng Publishing Group Inc. All rights reserved.

Core tip: This paper is an original study that analyzes for the first time the many words and acronyms used in literature to describe lumbar extradural cysts, suggesting the term "ganglion cyst" in clinical practice. It also propose a morphological classification of these cysts, which could be useful for clinicians and surgeons. Finally, a description of microsurgical approaches to resect the cyst and avoid spinal instability is reported: As a guide to a common therapeutical strategy, we report a flow-chart, evaluating clinical conditions, mechanical stability and the most suitable treatment.

Domenicucci M, Ramieri A, Marruzzo D, Missori P, Miscusi M, Tarantino R, Delfini R. Lumbar ganglion cyst: Nosology, surgical management and proposal of a new classification based on 34 personal cases and literature review. *World J Orthop* 2017; 8(9): 697-704 Available from: URL: <http://www.wjgnet.com/2218-5836/full/v8/i9/697.htm> DOI: <http://dx.doi.org/10.5312/wjo.v8.i9.697>

INTRODUCTION

Ganglion cysts, more common in the hands and wrists^[1,2], have been described for more than 2 millennia^[3]. The Greek term "ganglion" indicates a knot of the tissues.

Ganglion cysts of the minor and major joints, especially at the level of the wrist and back of the hand, have been known since ancient times and were described by Hippocrates^[3] more than two millennia ago. These cysts have an high incidence: Burke *et al*^[1], reviewing the period 1990-2000, found between 44 and 55 new cases per 100000 inhabitants each year.

In the past century, similar cysts were also described as originated from lumbar zygapophyseal joints and occupying the spinal canal, most frequently in the lumbar spine and occasionally, in the cervical and thoracic spine^[4-6]. To define these spinal neoformations, many terms have been adopted in the literature, according to the site of development or to the supposed origin: Ganglion^[6], juxtafacet^[7], flavum^[8], cyfmos^[9] and synovial^[7,8,10-14].

The etiology of the cyst, not fully clear, could be strongly related to inflammatory phenomena secondary to facet hypermobility, which would produce modifications of the articular synovial membrane

leading to cyst formation^[13]. Microsurgical cystectomy is today the treatment of choice^[15], with or without arthrodesis: Generally, microsurgical approach does not produce vertebral instability and arthrodesis is required only in case of a clear pre-operative instability, such as spondylolisthesis.

Evaluating all etiological factors and all treatment options, we propose an original morphological classification of lumbar ganglion cysts, based on their relation with the other anatomical structures. Lastly, in order to clarify the confusing terminology that describes these particular cysts, we suggest "spinal ganglion cyst" (SGC) as definitive term to be applied in clinical practice.

MATERIALS AND METHODS

Thirty-four cases of symptomatic lumbar SGCs surgically treated from 1995 to 2011 were enrolled in this study. They include 18 previously published arthrodesis, with 3 hemorrhagic SGCs. All patients underwent preoperative magnetic resonance imaging (MRI) and computed tomography (CT) scan. To assess lumbar segmental instability, dynamic X-ray were also obtained in all patients but 4 cases, in which pain did not allow standing position.

Pain was evaluated by the Visual Analogic Scale (VAS score). Neurological examination was performed to assess signs of roots compression with any sensory and/or motor deficits.

All patients were operated through a microsurgical approach^[15], to maintain articular congruence and not jeopardize vertebral stability. Cystectomy was achieved through laminotomy or hemilaminectomy. In presence of demonstrated pre-operative or iatrogenic intraoperative segmental instability (wide resection of the articular process), instrumented arthrodesis was also performed.

Histological examination of the cyst was performed in all cases to confirm the diagnosis.

Average follow-up was 28.5 mo (range 12-60). All patients underwent MRI, plain X-rays and were evaluated by VAS and modified Japanese Orthopaedic Association score (JOA score) for neurological improvement in the lower limbs.

The Wilcoxon signed rank test was used for statistical analysis, considering *P* value equal to or less than 0.05 as significant.

Based on our experience and literature review, we were able to construct a new and original classification of the ganglion cysts. By some drawings, performed by the first author (Maurizio D), we reported for the first time the main locations of these cysts, summarizing and comparing our radiological and surgical data with those from the pertinent literature.

RESULTS

The data regarding our 34 cases are summarized in Table 1. Average age was 63 (range 50-76 years): 13 (38%)

Table 1 Data regarding our 34 cases

Case	Age and sex	Location (side)	Instability		Treatment		Other data
			Verified	Supposed	Type 1	Type 2	
1	68 M	L5-S1 (left internal)		a	y		Re
2	75 M	L4-L5 (right medium)		a, b, c	y		
3	50 F	L4-L5 (right medium-internal)		a, b	y		
4	63 F	L5-S1 (right medium)		b, c	y		
5	76 F	L4-L5 (left medium-internal)		a	y		
6	75 M	L5-S1 ¹ (right medium-lateral)		a, b, d	y		
7	75 F	L4-L5 (right medium-lateral)	y	b, c		y	
8	62 M	L4-L5 (right medium-internal)	y	a, b		y	
9	60 M	L4-L5 (right lateral)		a, b, c	y		
10	73 F	L5-S1 (right lateral)		a, b, d	y		
11	55 M	L2-L3 (left medium-lateral)		a	y		
12	55 M	L4-L5 (left medium)	y	a, b		y	
13	74 F	L3-L4 ¹ (right medium-lateral)		b, c	y		
14	56 F	L3-L4 (left medium-lateral)	y	a		y	
15	67 F	L4-L5 (left medium-lateral)		b	y		
16	56 F	L4-L5 (right medium-lateral)		b, c	y		
17	66 F	L4-L5 (left medium-internal)		b	y		IF
18	68 M	L4-L5 ¹ (left medium-lateral)		a	y		
19	73 F	L5-S1 ¹ (left medium)		a, b	y		
20	53 F	L5-S1 (left medium-lateral)		a, b, c, d		y	
21	60 F	L4-L5 (right internal)		a, b, c, d		y	
22	52 M	L4-L5 (right medium-internal)	y	a		y	
23	64 F	L5-S1 (left internal)	y	a, b		y	
24	53 M	L5-S1 (left medium)	y	a, b		y	
25	73 F	L4-L5 (left medium-lateral)		a, b, c		y	IF
26	54 F	L3-L4 (right medium-internal)	y	a, b		y	
27	61 M	L4-L5 (left medium)		a, b, c		y	
28	65 M	L5-S1 (left medium)		a, d	y		
29	71 M	L5-S1 (right medium-internal)		a	y		
30	52 F	L4-L5 (left medium-lateral)		a, b	y		
31	63 F	L4-L5 (right medium)		a, b	y		
32	72 F	L4-L5 (right lateral)		a, b, d	y		
33	56 F	L4-L5 (right lateral)		a	y		
34	62 F	L4-L5 (left medium-lateral)		a	y		

¹Hemorrhagic cyst; L: Left; R: Right; y: Yes; Type 1: Decompression; Type 2: Decompression with stabilization; Verified: Mobile olisthesis; a: Black disc; b: Interarticular liquid; c: Hyperintensity of the ligament on STIR MR images; d: Stable olisthesis; Re: Reoperated for postoperative instability with fusion; IF: Intraoperative fistula.

patients were males and 21 (62%) females. All patients had radicular pain, generally associated with lumbago. In 7 cases (21%), neurological deficits were also present. No cauda equina syndrome was detected. Duration of symptoms prior to surgical treatment varied from 1 to 3 years in 10 cases, whereas in the others average duration was 142 d (range 10-300 d). An acute onset, with a brief preoperative symptomatology, occurred in 4 hemorrhagic cysts.

Preoperative dynamic X-rays showed a mobile olisthesis in 8 cases (23%) and a stable one in 6 (18%). In all cases, preoperative CT and MRI showed signs of microinstability consisting of a reduced disc space and black disc (28 cases, 82%), increased interfacet synovial fluid (24 cases, 70%) and/or signal hyperintensity of the interspinous ligament on STIR sequences (10 cases, 29%).

All 14 pre-operative spondylolisthesis were submitted to arthrodesis. Instrumented fusion was achieved at the level of the cyst in 10 cases (Figure 1), while, in the remaining 4, it was extended to the level

above (Figure 2).

During surgery, we observed 2 dural laceration that were successfully repaired. Histology confirmed the nature of the lesions as ganglion or synovial cysts.

Based on neuroradiological investigations and operative findings, the lumbar SGCs were classified according to the scheme illustrated in Figures 3 and 4. Using this classification, 3 cysts were internal, 7 medium, 8 medium-internal, 12 medium-lateral and 4 lateral.

In the immediate post-operative period, all patients presented remission of pain, gradual recovery from radicular deficits or improvement of claudication. At 12-mo follow-up, one patient developed an olisthesis at the level of cystectomy with low back pain. Instability was correlated with an excessive demolition of the articular process. Therefore, stabilization and fusion achieved remission of pain and good long-term outcome. No recurrences or new contralateral or adjacent SGCs were observed.

At long-term follow-up, VAS reduced from $7.4 \pm$

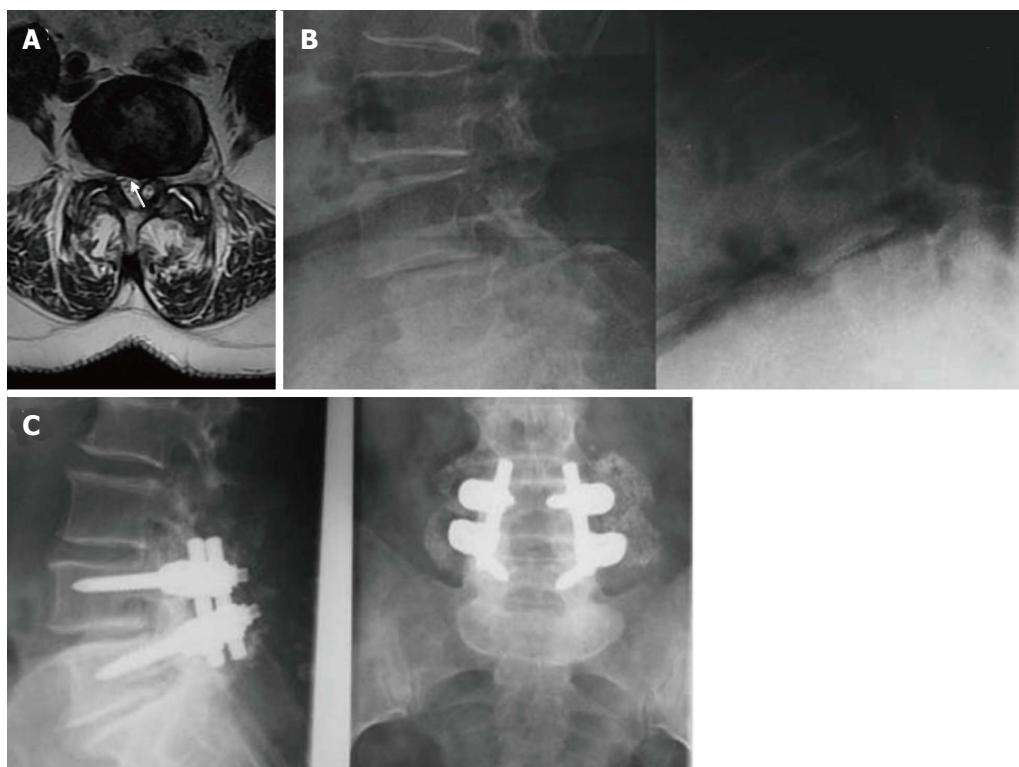


Figure 1 Case 2, Table 1. Preoperative axial T2-weighted MR image (A) showing a dehydrated and hypointense disk with a hyperintense cystic formation at right L4-L5 level (arrow). The cyst appeared to be of the internal or flavum type (see text for the classification). Sagittal dynamic images (B) 12 mo after the first surgical treatment showed an unstable olisthesis at L4-L5 level. Standard X-rays performed 1 year after surgical stabilization (C) showed the instrumentation to be well-positioned with an optimal profile and fusion at L4-L5.

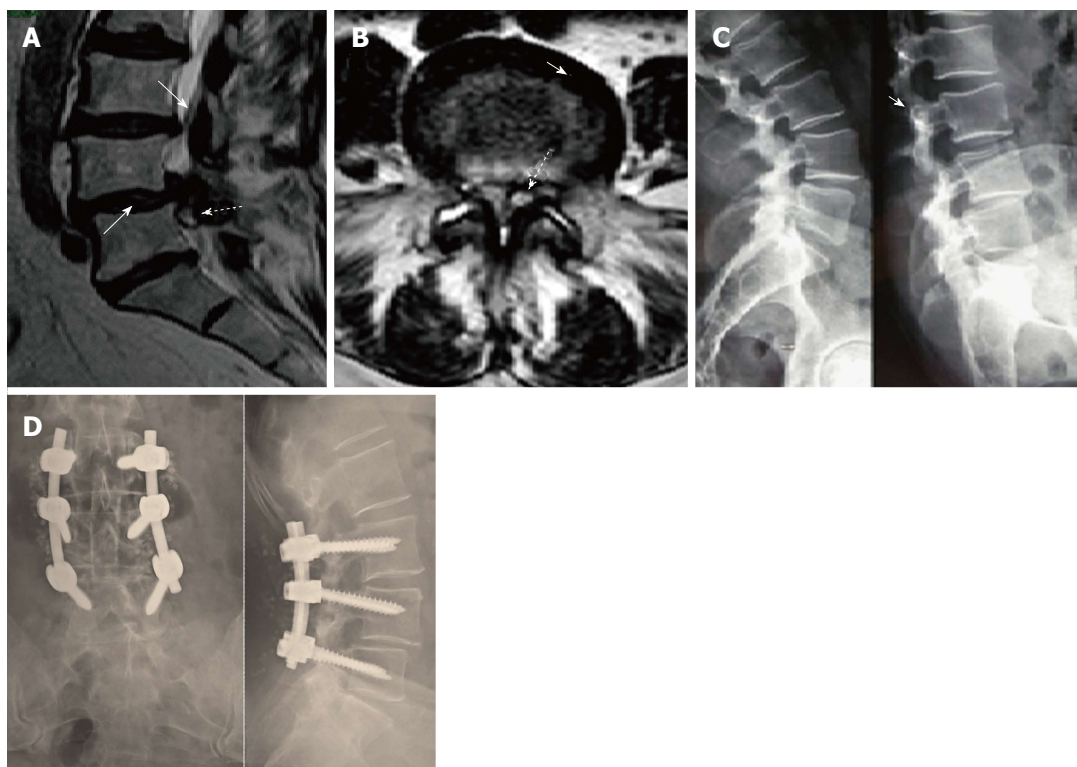


Figure 2 Case 12, Table 1. Preoperative sagittal T2-weighted MR image (A) showing a spinal ganglion cyst (dotted arrow) accompanied by olisthesis at L4/L5 with a dehydrated intervertebral disk (arrow), partially herniated into the spinal canal. On axial images (B) the cyst (dotted arrow) appeared to be of the medium or articular type (see text for classification). The interfacetal space contained an anomalous abundance of "sinovia" (commonly called synovial fluid), as the contralateral one did. Dynamic X-rays (C) showed an unstable olisthesis at L4/L5 and L3/L4. Postoperative outcome of the L3/L5 stabilization is documented by standard X-ray films (D) which confirmed good stability and fusion of the lumbar spine.

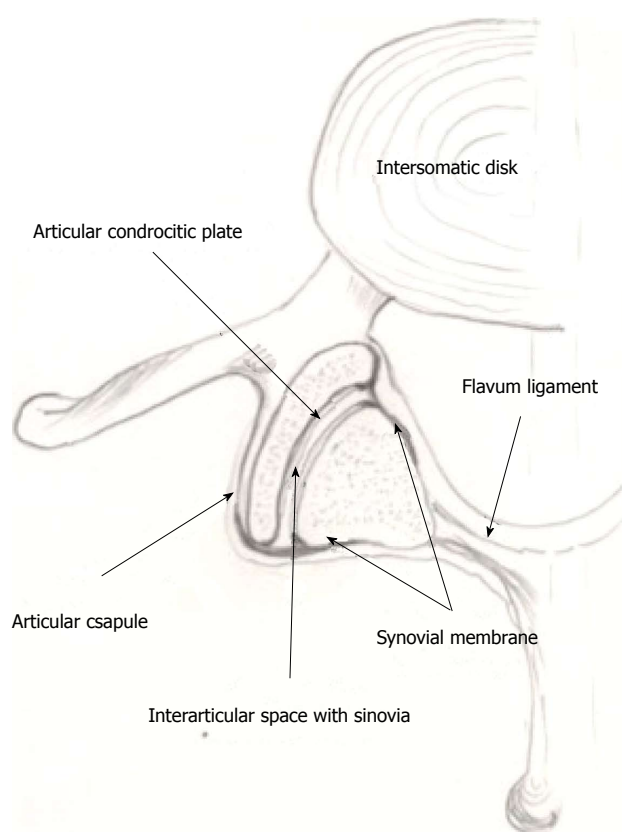


Figure 3 Schematic drawing of a lumbar facet joint showing the extension and distribution of the synovial membrane localized on the internal face of the articular capsule, extending to the external margins of the joint, up to the chondrocytic plates.

1.5 (6-10) to 1.3 ± 0.9 (0-2) ($P = 0.037$). JOA score improved from 7.6 ± 1.3 (7-9) to 2.5 ± 0.3 (0-3) ($P = 0.041$).

DISCUSSION

During the second half of the last century, articular cysts of the spine, prevalently lumbar, were likened to those of the wrist, hand, knee and hip and called, in the Greek language, γαγγλιον (ganglion). Hippocrate (460-377 a.C.), translated by Foesio *et al*^[3] in 1596, in the chapter "De Articulis" describes some cutaneous periarticular cysts as "...quae ganglia dominant, quaecunque fluida sunt, et mucosam carnem continent..." (... these so-called ganglion, that contains a fluid or a mucous substance...). In 1930, Elmslie^[16], during a knee surgery, observed a communication between the cyst and the synovial membrane, and used for the first time the term "synovial cyst". In 1968, Kao *et al*^[6] described the first two cases of lumbar intraspinal extradural cyst, calling it "ganglion". In 1973, Sybert *et al*^[10] referred the possible origin from the synovial cells of the lumbar zygapophyseal joints. In 1974, Kao *et al*^[7], trying to establish terminology and nosology, published a review on spinal ganglion and synovial cysts, grouping them under a single definition: "Juxtafacet synovial cysts". This term was subsequently adopted by several

authors^[13,17-22], while others proposed other terms such as "flavum cyst"^[8] or cyfmos^[9], according respectively to the site of pathology or biomechanics of the mobile spine. They are all essentially correct, in relation to the tissue of origin^[6,10], site^[7-9] or etiology, but, in our hands, create some confusion. In order to identify this specific pathology in terms of pathogenesis, symptomatology and treatment, we reconsidered the ancient term of "ganglion": Spinal ganglion cyst (SGC) may be the term of choice if the cyst originates from the articular process: The distinction between ganglion and synovial cyst is in fact purely histological. Psaila and Mansel^[23] defined that a ganglion cyst "...mainly consists of sheets of collagen fibers arranged in multidirectional strata" and "the ganglion tissue may be produced by the multifunctional mesenchymal cells". The main histological feature of the ganglion is the loss of continuity with the capsule of the facet joints, that makes it free inside and/or outside the spinal canal. On the contrary, the real and conserved synovial cyst is always in continuity with the capsule and recurrently presents synovial villi.

SGCs originate from the joint capsule, more precisely from the mesenchymal tissue^[23] that constitutes the synovial membrane. This tissue covers the internal face of the capsule and also the external portion of the joint: This extension can explain the intra-articular or extra-articular development of SGCs. On the basis of these considerations, we propose an original classification that distinguishes the cysts between anterior or endocanal and posterior or extra-canal. The anterior variety can be subdivided into lateral or foraminal, medium or articular and internal or flavum.

To the best of the authors' knowledge, a comprehensive classification of SGCs has never been reported. Papers from the literature distinguished between synovial, posterior longitudinal ligament or flavum ligament cysts based on their location, origin or histopathological features. Our paper suggests for the first time the distinction between endo-canal and extra-canal SGC: The last one is posterior, generally asymptomatic and do not require treatment^[24]. On the contrary, endo-canal SGC is frequently symptomatic and neurological impairment is closely related to its position within the spinal canal, explaining different disorders ranging from single radiculopathy to cauda equina syndrome.

Factor responsible for proliferation of the synovial cells seems to be repeated articular micro-trauma that induces chronic inflammation, increase of synovial fluid and development of the cyst. Different grades of instability up toolisthesis can favor the weakening of the capsule and ultimately the cystic formation.

We observed lumbar degenerative olisthesis and SGC in more than 40% of our cases. These associated pathologies are frequently reported in the literature, in varying percentages from 30%^[13] to 50%^[25] of cases. Recently, Boviatsis *et al*^[18], reviewing 499 SGCs, have found disc degeneration, osteoarthritis and spondylolisthesis. Many authors^[9,13,18,24-27] underlined that SGCs originate in the most mobile spinal segments,

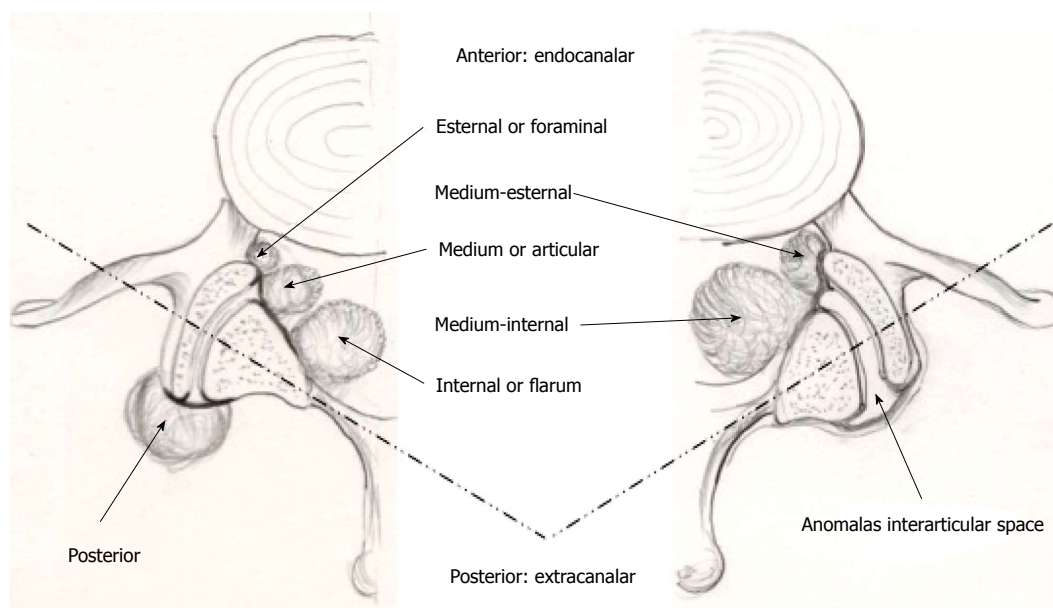


Figure 4 Localizations of lumbar spinal ganglion cysts (see text for the classification). The drawing on the right shows the joint with signs of instability (widened and misaligned interarticular space and increased amount of sinovia).

which are more susceptible to micro or macroinstability.

Cysts formation has been also presented in literature as consequence of an adjacent segment syndrome, due to the hypermobility of a segment just above or below other fixed vertebral segments; also in this case the mechanical stress would be the trigger necessary for mesenchymal tissue degeneration^[28].

In our series and in the literature^[9,13,18,24-26,29,30], SGCs were more frequent at L4-L5, which is notoriously the most mobile spinal level.

Clinical onset of SGCs is generally described as rapid and intense^[14,18,19,21,31], characterized by radicular type disturbances, severe impairment of deambulation due to painful symptoms or, less frequently, motor deficits. Occasionally, onset may be extremely acute and intractable due to intracystic hemorrhage. In agreement with other authors^[32-34], bleeding in such cysts is caused by neo-formed vessels following the repeated inflammations.

Radiological investigations mainly consist of MRI, which can visualize the SGC and relative degenerative phenomena, such as an increased quantity of "sinovia", more commonly described as interfascial fluid, or inflammatory processes involving the interspinous ligament, which appears "shiny" mainly on T2 and STIR sequences^[35]. In our series these phenomena were present in all cases, either singly or, more often, in combination.

Conventional radiography can play an important role. Standard load-bearing and flexion-extension X-rays may identify hypermobility or instability otherwise unrecognized: However, the severe painful symptoms sometimes make it impossible to perform this type of pre-operative investigation.

Once a diagnosis of SGC has been made, treatment depends on clinical conditions and neurological sym-

ptoms. In the literature^[21], outcomes of different conservative treatments are reported. Surgery is indicated in case of severe pain resistant to medical therapy or when neurological deficits are present.

Operative approach has to totally remove the neoformation, taking into account the degree of instability of the spinal level involved by the cyst. Only when one part of the capsule appears tenaciously adherent to the dura mater it is advisable to perform a subtotal excision, to avoid risks of a CSF fistula. Microsurgical cystectomy seems to be able to maintain vertebral stability: Only one case developed vertebral slippage at follow-up. Fusion can be planned on the basis of preoperative investigations in presence of clear instability, as spondylolisthesis, or can be decided during surgery, evaluating the degree of joint demolition in order to achieve nerve roots decompression and radical cystectomy.

We limited posterior instrumented fusion to about a third of our cases, all suffering from spondylolisthesis: In the literature, fusion varies from over 50% of patients^[29] to a percentage similar or lower than ours^[9,12,13,17,25], whereas in other series surgery was performed without fusion^[15,22,30,36,37]. This variability in surgical strategy illustrates how the indication for fusion do not follow common guidelines. As a guide to a common therapeutic strategy, we have laid out a flow-chart (Figure 5), evaluating clinical conditions, mechanical stability and the most suitable treatment.

The long-term outcomes in patients surgically treated are usually good, with complete remission from pre-operative disturbances, in our series as in others^[9,11,12,13, 17,20,22,25,29,30,36,37]. Only one of our patients presented a symptomatic olisthesis about 1 year after treatment. This iatrogenic deformity, due to an excessive bone demolition, required posterior fusion to achieve resolution of symptoms. In the literature^[11,13,19,20,25,30] a

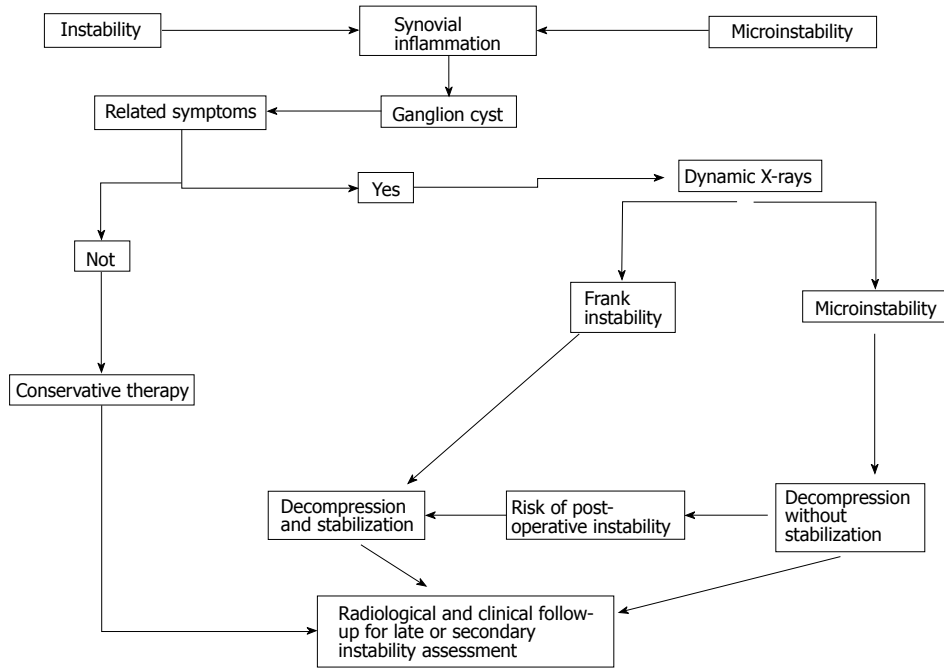


Figure 5 Flow-chart depicting options for the most appropriate approach to the lumbar spinal ganglion cysts.

similar complication was described with the same low incidence in the majority of the larger case series. A recurrence of an operated cyst is exceptional and only one case is described^[13]. The appearance of a new SGC, contralateral, higher or lower, is more frequent and occurred in 15 cases^[13,17,19,20,22,29,38]. No recurrences were observed in our case series.

In conclusion, spinal ganglion cysts are generally found in the lumbar spine. Over the past decades, a wide variety of terms used to describe them has generated confusion: For this reason, the authors decided to return to the ancient definition of "ganglion cyst". Their origin into the spine seems to be attributable to inflammatory phenomena, involving the synovial membrane and caused by repeated joint microtraumas, promoted by facet hypermobility or clear instability. The treatment of choice is microsurgical cystectomy, which generally does not require fusion. The need for fusion must be carefully evaluated: Pre-operative spondylolisthesis or a wide bone joint demolition are the main indications for fusion procedures. The proposal morphologic classification of SGCs is the first that clarifies different localizations of these cysts and may be clinically useful for radiologists and surgeons, together with the definition of ganglion, to speak the same scientific language.

COMMENTS

Background

Ganglion cysts of the minor and major joints, especially at the level of the wrist and back of the hand, have been known since ancient times. These cysts have a high incidence. In the past century, similar cysts were also described as originated from lumbar zygapophyseal joints and occupying the spinal canal, most frequently in the lumbar spine and occasionally, in the cervical and thoracic spine. To define these spinal neoformations, many terms have been adopted in the literature, according to the site of development or to the

supposed origin: Ganglion, juxtafacet, flavum, cyfmos and synovial.

Research frontiers

The etiology of the cyst was related to inflammatory phenomena secondary to facet hypermobility, which would produce modifications of the articular synovial membrane leading to cyst formation. Microsurgical cystectomy is today the treatment of choice. Generally, microsurgical approach does not produce vertebral instability and arthrodesis is required only in case of a clear pre-operative instability.

Innovations and breakthroughs

Evaluating all etiological factors and all treatment options, the authors propose an original morphological classification of lumbar ganglion cysts, based on their relation with the other anatomical structures. Lastly, in order to clarify the confusing terminology that describes these particular cysts, the authors suggest "spinal ganglion cyst" (SGC) as definitive term to be applied in clinical practice.

Applications

The proposal morphologic classification of SGCs is the first that clarifies different localizations of these cysts and may be clinically useful for radiologists and surgeons, together with the definition of ganglion, to speak the same scientific language.

Peer-review

The authors present a case series and a proposed standardized language for lumbar ganglion cysts. The paper is generally well-written and easy to read.

REFERENCES

- 1 Burke FD, Melikyan EY, Bradley MJ, Dias JJ. Primary care referral protocol for wrist ganglia. *Postgrad Med J* 2003; **79**: 329-331 [PMID: 12840121 DOI: 10.1136/pmj.79.932.329]
- 2 Carp L, Stout AP. Branchial Anomalies And Neoplasms: A Report Of Thirty-Two Cases With Follow-Up Results. *Ann Surg* 1928; **87**: 186-209 [PMID: 17865829]
- 3 Foessio A, De articulis. Magni hippocratis medicorum omnium facile principis, opera omnia quae extant in VIII sectiones ex Erotiani mente distributa. Francofurti, 1596: 840-841
- 4 Song JK, Musleh W, Christie SD, Fessler RG. Cervical juxtafacet

- cysts: case report and literature review. *Spine J* 2006; **6**: 279-281 [PMID: 16651221 DOI: 10.1016/j.spinee.2005.09.006]
- 5 **Graham E**, Lenke LG, Hannallah D, Laurysen C. Myelopathy induced by a thoracic intraspinal synovial cyst: case report and review of the literature. *Spine (Phila Pa 1976)* 2001; **26**: E392-E394 [PMID: 11568715 DOI: 10.1097/00007632-200109010-00024]
 - 6 **Kao CC**, Uihlein A, Bickel WH, Soule EH. Lumbar intraspinal extradural ganglion cyst. *J Neurosurg* 1968; **29**: 168-172 [PMID: 5673315 DOI: 10.3171/jns.1968.29.2.0168]
 - 7 **Kao CC**, Winkler SS, Turner JH. Synovial cyst of spinal facet. Case report. *J Neurosurg* 1974; **41**: 372-376 [PMID: 4416019 DOI: 10.3171/jns.1974.41.3.0372]
 - 8 **Vernet O**, Fankhauser H, Schnyder P, Déruaz JP. Cyst of the ligamentum flavum: report of six cases. *Neurosurgery* 1991; **29**: 277-283 [PMID: 1832212]
 - 9 **Christophis P**, Asamoto S, Kuchelmeister K, Schachenmayr W. "Juxtafacet cysts", a misleading name for cystic formations of mobile spine (CYFMOS). *Eur Spine J* 2007; **16**: 1499-1505 [PMID: 17203271 DOI: 10.1007/s00586-006-0287-5]
 - 10 **Sypert GW**, Leech RW, Harris AB. Posttraumatic lumbar epidural true synovial cyst. Case report. *J Neurosurg* 1973; **39**: 246-248 [PMID: 4719701 DOI: 10.3171/jns.1973.39.2.0246]
 - 11 **Freidberg SR**, Fellows T, Thomas CB, Mancall AC. Experience with symptomatic spinal epidural cysts. *Neurosurgery* 1994; **34**: 989-993; discussion 993 [PMID: 8084409 DOI: 10.1227/00006123-199406000-00006]
 - 12 **Howington JU**, Connolly ES, Voorhies RM. Intraspinal synovial cysts: 10-year experience at the Ochsner Clinic. *J Neurosurg* 1999; **91**: 193-199 [PMID: 10505504 DOI: 10.3171/spi.1999.91.2.0193]
 - 13 **Sabo RA**, Tracy PT, Weinger JM. A series of 60 juxtafacet cysts: clinical presentation, the role of spinal instability, and treatment. *J Neurosurg* 1996; **85**: 560-565 [PMID: 8814156 DOI: 10.3171/jns.1996.85.4.0560]
 - 14 **Yarde WL**, Arnold PM, Kepes JJ, O'Boynick PL, Wilkinson SB, Batnitzky S. Synovial cysts of the lumbar spine: diagnosis, surgical management, and pathogenesis. Report of eight cases. *Surg Neurol* 1995; **43**: 459-464; discussion 465 [PMID: 7660284]
 - 15 **Landi A**, Marotta N, Tarantino R, Ruggeri AG, Cappelletti M, Ramieri A, Domenicucci M, Delfini R. Microsurgical excision without fusion as a safe option for resection of synovial cyst of the lumbar spine: long-term follow-up in mono-institutional experience. *Neurosurg Rev* 2012; **35**: 245-253; discussion 253 [PMID: 22009492 DOI: 10.1007/s10143-011-0356-z]
 - 16 **Elmslie RC**. Cyst of Synovial Membrane in the Region of the Internal Semilunar Cartilage. *Proc R Soc Med* 1930; **23**: 1586-1587 [PMID: 19987788]
 - 17 **Banning CS**, Thorell WE, Leibrock LG. Patient outcome after resection of lumbar juxtafacet cysts. *Spine (Phila Pa 1976)* 2001; **26**: 969-972 [PMID: 11317123 DOI: 10.1097/00007632-200104150-00024]
 - 18 **Boviatsis EJ**, Stavrinos LC, Kouyialis AT, Gavra MM, Stavrinos PC, Themistokleous M, Selviaridis P, Sakas DE. Spinal synovial cysts: pathogenesis, diagnosis and surgical treatment in a series of seven cases and literature review. *Eur Spine J* 2008; **17**: 831-837 [PMID: 18389295 DOI: 10.1007/s00586-007-0563-z]
 - 19 **Epstein NE**. Lumbar laminectomy for the resection of synovial cysts and coexisting lumbar spinal stenosis or degenerative spondylolisthesis: an outcome study. *Spine (Phila Pa 1976)* 2004; **29**: 1049-1055; discussion 1056 [PMID: 15105680 DOI: 10.1097/00007632-200405010-00018]
 - 20 **Métellus P**, Fuentes S, Adetchessi T, Levrier O, Flores-Parra I, Talianu D, Dufour H, Bouvier C, Manera L, Grisoli F. Retrospective study of 77 patients harbouring lumbar synovial cysts: functional and neurological outcome. *Acta Neurochir (Wien)* 2006; **148**: 47-54; discussion 54 [PMID: 16258839 DOI: 10.1007/s00701-005-0650-z]
 - 21 **Shah RV**, Lutz GE. Lumbar intraspinal synovial cysts: conservative management and review of the world's literature. *Spine J* 2003; **3**: 479-488 [PMID: 14609693 DOI: 10.1016/S1529-9430(03)00148-7]
 - 22 **Trummer M**, Flaschka G, Tillich M, Homann CN, Unger F, Eustacchio S. Diagnosis and surgical management of intraspinal synovial cysts: report of 19 cases. *J Neurol Neurosurg Psychiatry* 2001; **70**: 74-77 [PMID: 11118251 DOI: 10.1136/jnnp.70.1.74]
 - 23 **Psaila JV**, Mansel RE. The surface ultrastructure of ganglia. *J Bone Joint Surg Br* 1978; **60-B**: 228-233 [PMID: 659471]
 - 24 **Doyle AJ**, Merrilees M. Synovial cysts of the lumbar facet joints in a symptomatic population: prevalence on magnetic resonance imaging. *Spine (Phila Pa 1976)* 2004; **29**: 874-878 [PMID: 15082987 DOI: 10.1097/00007632-200404150-00010]
 - 25 **Lyons MK**, Atkinson JL, Wharen RE, Deen HG, Zimmerman RS, Lemens SM. Surgical evaluation and management of lumbar synovial cysts: the Mayo Clinic experience. *J Neurosurg* 2000; **93**: 53-57 [PMID: 10879758 DOI: 10.3171/spi.2000.93.1.0053]
 - 26 **Choudhri HF**, Perling LH. Diagnosis and management of juxtafacet cysts. *Neurosurg Focus* 2006; **20**: E1 [PMID: 16599415 DOI: 10.3171/foc.2006.20.3.2]
 - 27 **Khan AM**, Girardi F. Spinal lumbar synovial cysts. Diagnosis and management challenge. *Eur Spine J* 2006; **15**: 1176-1182 [PMID: 16440202 DOI: 10.1007/s00586-005-0009-4]
 - 28 **Miscusi M**, Petrozza V, Polli FM, Forcato S, Rocca CD, Raco A. Symptomatic ganglion cyst of ligamentum flavum as a late complication of lumbar fixation. *Neurol Neurochir Pol* 2012; **46**: 82-86 [PMID: 22426766]
 - 29 **Khan AM**, Synnot K, Cammisa FP, Girardi FP. Lumbar synovial cysts of the spine: an evaluation of surgical outcome. *J Spinal Disord Tech* 2005; **18**: 127-131 [PMID: 15800428 DOI: 10.1097/01.bsd.0000156830.68431.70]
 - 30 **Sandhu FA**, Santiago P, Fessler RG, Palmer S. Minimally invasive surgical treatment of lumbar synovial cysts. *Neurosurgery* 2004; **54**: 107-111; discussion 111-112 [PMID: 14683546 DOI: 10.1227/01.NEU.0000097269.79994.2F]
 - 31 **Salmon B**, Martin D, Lenelle J, Stevenaert A. Juxtafacet cyst of the lumbar spine. Clinical, radiological and therapeutic aspects in 28 cases. *Acta Neurochir (Wien)* 2001; **143**: 129-134 [PMID: 11459083 DOI: 10.1007/s007010170117]
 - 32 **Ramieri A**, Domenicucci M, Seferi A, Paolini S, Petrozza V, Delfini R. Lumbar hemorrhagic synovial cysts: diagnosis, pathogenesis, and treatment. Report of 3 cases. *Surg Neurol* 2006; **65**: 385-390; discussion 390 [PMID: 16531204 DOI: 10.1016/j.surneu.2005.07.073]
 - 33 **Arantes M**, Silva RS, Romão H, Resende M, Moniz P, Honavar M, Costa M. Spontaneous hemorrhage in a lumbar ganglion cyst. *Spine (Phila Pa 1976)* 2008; **33**: E521-E524 [PMID: 18594451 DOI: 10.1097/BRS.0b013e31817b6206]
 - 34 **Tatter SB**, Cosgrove GR. Hemorrhage into a lumbar synovial cyst causing an acute cauda equina syndrome. Case report. *J Neurosurg* 1994; **81**: 449-452 [PMID: 8057153 DOI: 10.3171/jns.1994.81.3.0449]
 - 35 **Keorochana G**, Taghavi CE, Tzeng ST, Morishita Y, Yoo JH, Lee KB, Liao JC, Wang JC. Magnetic resonance imaging grading of interspinous ligament degeneration of the lumbar spine and its relation to aging, spinal degeneration, and segmental motion. *J Neurosurg Spine* 2010; **13**: 494-499 [PMID: 20887147 DOI: 10.3171/2010.4.SPI.NE09515]
 - 36 **Hsu KY**, Zucherman JF, Shea WJ, Jeffrey RA. Lumbar intraspinal synovial and ganglion cysts (facet cysts). Ten-year experience in evaluation and treatment. *Spine (Phila Pa 1976)* 1995; **20**: 80-89 [PMID: 7709284 DOI: 10.1097/00007632-199501000-00015]
 - 37 **Sehati N**, Khoo LT, Holly LT. Treatment of lumbar synovial cysts using minimally invasive surgical techniques. *Neurosurg Focus* 2006; **20**: E2 [PMID: 16599418 DOI: 10.3171/foc.2006.20.3.3]
 - 38 **Pirotte B**, Gabrovsky N, Massager N, Levivier M, David P, Brotschi J. Synovial cysts of the lumbar spine: surgery-related results and outcome. *J Neurosurg* 2003; **99**: 14-19 [PMID: 12859053 DOI: 10.3171/spi.2003.99.1.0014]

P- Reviewer: Petersen SMB **S- Editor:** Kong JX **L- Editor:** A
E- Editor: Lu YJ





Published by **Baishideng Publishing Group Inc**
7901 Stoneridge Drive, Suite 501, Pleasanton, CA 94588, USA
Telephone: +1-925-223-8242
Fax: +1-925-223-8243
E-mail: bpgoffice@wjgnet.com
Help Desk: <http://www.f6publishing.com/helpdesk>
<http://www.wjgnet.com>

