

World Journal of *Orthopedics*

World J Orthop 2017 September 18; 8(9): 660-746



**DIAGNOSTIC ADVANCES**

- 660 Clinical applications of advanced magnetic resonance imaging techniques for arthritis evaluation
Martín Noguerol T, Luna A, Gómez Cabrera M, Riofrio AD

MINIREVIEWS

- 674 Mesenchymal stem cells for cartilage regeneration in osteoarthritis
Kristjánsson B, Honsawek S

ORIGINAL ARTICLE**Basic Study**

- 681 Electron probe microanalysis of experimentally stimulated osteoarthrosis in dogs
Stupina T, Shchudlo M, Stepanov M
- 688 Benefits of Ilizarov automated bone distraction for nerves and articular cartilage in experimental leg lengthening
Shchudlo N, Varsegova T, Stupina T, Shchudlo M, Saifutdinov M, Yemanov A

Retrospective Study

- 697 Lumbar ganglion cyst: Nosology, surgical management and proposal of a new classification based on 34 personal cases and literature review
Domenicucci M, Ramieri A, Marruzzo D, Missori P, Miscusi M, Tarantino R, Delfini R
- 705 Acetabular components with or without screws in total hip arthroplasty
Pepe M, Kocadal O, Erener T, Ceritoglu K, Aksahin E, Aktekin CN
- 710 Single-stage anterior debridement and reconstruction with tantalum mesh cage for complicated infectious spondylitis
Yang SC, Chen HS, Kao YH, Tu YK

Prospective Study

- 719 Association of adiponectin gene polymorphisms with knee osteoarthritis
Zhan D, Thumtecho S, Tanavalee A, Yuktanandana P, Anomasiri W, Honsawek S

SYSTEMATIC REVIEWS

- 726 Osteoarthritis action alliance consensus opinion - best practice features of anterior cruciate ligament and lower limb injury prevention programs
Trojan T, Driban J, Nuti R, Distefano L, Root H, Nistler C, LaBella C

CASE REPORT

- 735 Using humeral nail for surgical reconstruction of femur in adolescents with osteogenesis imperfecta
Sa-ngasoongsong P, Saisongcroh T, Angsanuntsukh C, Woratanarat P, Mulpruek P
- 741 Hernia mesh prevent dislocation after wide excision and reconstruction of giant cell tumor distal radius
Wiratnaya IGE, Budiarta IGBAM, Setiawan IGNU, Sindhughosa DA, Kawiya IKS, Astawa P

Contents

World Journal of Orthopedics
Volume 8 Number 9 September 18, 2017

ABOUT COVER

Editorial Board Member of *World Journal of Orthopedics*, Michel PJ van den Bekerom, MD, Staff Physician, Department of Orthopaedic Surgery, Shoulder and Elbow Unit, OLVG, Amsterdam 1090, The Netherlands

AIM AND SCOPE

World Journal of Orthopedics (*World J Orthop*, *WJO*, online ISSN 2218-5836, DOI: 10.5312) is a peer-reviewed open access academic journal that aims to guide clinical practice and improve diagnostic and therapeutic skills of clinicians.

WJO covers topics concerning arthroscopy, evidence-based medicine, epidemiology, nursing, sports medicine, therapy of bone and spinal diseases, bone trauma, osteoarthropathy, bone tumors and osteoporosis, minimally invasive therapy, diagnostic imaging. Priority publication will be given to articles concerning diagnosis and treatment of orthopedic diseases. The following aspects are covered: Clinical diagnosis, laboratory diagnosis, differential diagnosis, imaging tests, pathological diagnosis, molecular biological diagnosis, immunological diagnosis, genetic diagnosis, functional diagnostics, and physical diagnosis; and comprehensive therapy, drug therapy, surgical therapy, interventional treatment, minimally invasive therapy, and robot-assisted therapy.

We encourage authors to submit their manuscripts to *WJO*. We will give priority to manuscripts that are supported by major national and international foundations and those that are of great basic and clinical significance.

INDEXING/ABSTRACTING

World Journal of Orthopedics is now indexed in Emerging Sources Citation Index (Web of Science), PubMed, PubMed Central and Scopus.

FLYLEAF

I-III Editorial Board

EDITORS FOR THIS ISSUE

Responsible Assistant Editor: *Xiang Li*
Responsible Electronic Editor: *Ya-Jing Lu*
Proofing Editor-in-Chief: *Lian-Sheng Ma*

Responsible Science Editor: *Fang-Fang Ji*
Proofing Editorial Office Director: *Jin-Lai Wang*

NAME OF JOURNAL
World Journal of Orthopedics

ISSN
ISSN 2218-5836 (online)

LAUNCH DATE
November 18, 2010

FREQUENCY
Monthly

EDITORS-IN-CHIEF
Quanjun (Trey) Cui, MD, Professor, Department of Orthopaedic Surgery, School of Medicine, University of Virginia, Charlottesville, VA 22908, United States

Bao-Gan Peng, MD, PhD, Professor, Department of Spinal Surgery, General Hospital of Armed Police Force, Beijing 100039, China

EDITORIAL BOARD MEMBERS
All editorial board members resources online at <http://www.wjgnet.com>

www.wjgnet.com/2218-5836/editorialboard.htm

EDITORIAL OFFICE
Xiu-Xia Song, Director
World Journal of Orthopedics
Baishideng Publishing Group Inc
7901 Stoneridge Drive, Suite 501, Pleasanton, CA 94588, USA
Telephone: +1-925-2238242
Fax: +1-925-2238243
E-mail: editorialoffice@wjgnet.com
Help Desk: <http://www.fjpublishing.com/helpdesk>
<http://www.wjgnet.com>

PUBLISHER
Baishideng Publishing Group Inc
7901 Stoneridge Drive,
Suite 501, Pleasanton, CA 94588, USA
Telephone: +1-925-2238242
Fax: +1-925-2238243
E-mail: bpgoffice@wjgnet.com
Help Desk: <http://www.fjpublishing.com/helpdesk>
<http://www.wjgnet.com>

PUBLICATION DATE
September 18, 2017

COPYRIGHT
© 2017 Baishideng Publishing Group Inc. Articles published by this Open-Access journal are distributed under the terms of the Creative Commons Attribution Non-commercial License, which permits use, distribution, and reproduction in any medium, provided the original work is properly cited, the use is non commercial and is otherwise in compliance with the license.

SPECIAL STATEMENT
All articles published in journals owned by the Baishideng Publishing Group (BPG) represent the views and opinions of their authors, and not the views, opinions or policies of the BPG, except where otherwise explicitly indicated.

INSTRUCTIONS TO AUTHORS
<http://www.wjgnet.com/bpg/gerinfo/204>

ONLINE SUBMISSION
<http://www.fjpublishing.com>

Basic Study

Electron probe microanalysis of experimentally stimulated osteoarthritis in dogs

Tatyana Stupina, Michael Shchudlo, Michael Stepanov

Tatyana Stupina, Michael Shchudlo, Michael Stepanov, Laboratory of Morphology, FSBI Russian Ilizarov Scientific Center "Restorative Traumatology and Orthopaedics", 640014 Kurgan, Russia

Author contributions: Stupina T, Shchudlo M and Stepanov M substantially contributed to the conception and design of the study, acquisition, analysis and interpretation of data; all authors drafted the article and made critical revisions related to the intellectual content of the manuscript, and approved the final version of the article to be published.

Supported by The RF Ministry of Health within government-mandated program for FSBI Russian Ilizarov Scientific Center "Restorative Traumatology and Orthopaedics" (RISC "RTO") for Scientific Research, No. 01201155770.

Institutional review board statement: The article was reviewed by RISC "RTO" Review Board and statement including: (1) the manuscript is not simultaneously being considered by other journals or already published elsewhere; (2) the manuscript has no redundant publication, plagiarism, or data fabrication or falsification; (3) experiments involving animal subjects were designed and performed in compliance with the relevant laws regarding the animal care and use of subjects; and (4) material contained within the manuscript is original, with all information from other sources appropriately referenced.

Institutional animal care and use committee statement: All animal studies are approved by RISC "RTO" Ethical Committee - excerpts from the minutes #4 (50) under date of December 13, 2016.

Conflict-of-interest statement: The authors declare no conflict of interest.

Data sharing statement: No additional data are available.

Open-Access: This article is an open-access article which was selected by an in-house editor and fully peer-reviewed by external reviewers. It is distributed in accordance with the Creative Commons Attribution Non Commercial (CC BY-NC 4.0) license, which permits others to distribute, remix, adapt, build upon this work non-commercially, and license their derivative works on different terms, provided the original work is properly cited and

the use is non-commercial. See: <http://creativecommons.org/licenses/by-nc/4.0/>

Manuscript source: Invited manuscript

Correspondence to: Dr. Tatyana Stupina, Senior Researcher, Laboratory of Morphology, FSBI Russian Ilizarov Scientific Center "Restorative Traumatology and Orthopaedics", M. Ulianova Street 6, 640014 Kurgan, Russia. stupinasta@mail.ru
Telephone: +7-890-58506789
Fax: +7-352-2454060

Received: January 25, 2017
Peer-review started: February 2, 2017
First decision: May 23, 2017
Revised: May 26, 2017
Accepted: July 14, 2017
Article in press: July 15, 2017
Published online: September 18, 2017

Abstract

AIM

To develop methods of articular cartilage preparation for X-ray-electron probe microanalysis and to study its elements content in experimental osteoarthritis.

METHODS

Twenty dogs aged 2-8 years were divided in research (aged 2 years, induction of osteoarthritis - IOA) and intact group. Intact group included three subgroups (aged 2, 5 and 8 years). Samples of cartilage after araldite saturation and pouring were partially cut into semithin sections stained with methylene blue and with methylene blue-basic fuchsin. Their smooth surfaces were investigated by X-ray-electron probe microanalysis. Spatial distribution of sulfur, calcium and phosphorus and their concentrations (weight %) were investigated.

RESULTS

X-ray electron probe microanalysis revealed non-uniform

sulfur distribution in cartilage of intact animals: Its content increases from superficial zone to deep one, this regularity was preserved in animals with IOA. Differences of IOA with spontaneous chondropathy were revealed. Spontaneous aging was characterized by calcium and phosphorus storage in deep and calcified zones and compensatory increase of sulfated glycosaminoglycans in intermediate and deep cartilage zones as evidenced by the metachromatic reaction and microanalysis data. Unlike spontaneous chondropathy connected with aging in experimentally stimulated osteoarthritis more intensive storage of calcium but minor phosphorus in intermediate zone were marked. In IOA the calcified cartilage thinning and osteoclastic resorption are apparent with few changes of elements composition; the only difference from control is minority phosphorus content.

CONCLUSION

The obtained results demonstrate specific tricks of X-ray electron probe microanalysis and its possibility in the research of mechanisms of articular cartilage alterations in osteoarthritis.

Key words: Osteoarthritis; Articular cartilage; Dog; X-ray electron probe microanalysis

© **The Author(s) 2017.** Published by Baishideng Publishing Group Inc. All rights reserved.

Core tip: In this basic study we present the development of methods of articular cartilage preparation for X-ray-electron probe microanalysis and elements content in articular cartilage in animal experimentally induced (IOA) osteoarthritis and during spontaneous animal aging (SA). SA was characterized by calcium and phosphorus storage in deep and calcified articular cartilage zones and compensatory increase of sulfated glycosaminoglycans in intermediate and deep zones. In IOA more intensive storage of calcium but few phosphorus in intermediate zone were marked. As for Sulphur content, all zones of uncalcified cartilage in two-year-old animals with IOA were comparable with cartilage of five-year-old intact animals.

Stupina T, Shchudlo M, Stepanov M. Electron probe microanalysis of experimentally stimulated osteoarthritis in dogs. *World J Orthop* 2017; 8(9): 681-687 Available from: URL: <http://www.wjgnet.com/2218-5836/full/v8/i9/681.htm> DOI: <http://dx.doi.org/10.5312/wjo.v8.i9.681>

INTRODUCTION

Osteoarthritis (OA) has great social impact in terms of disability, pain, illness and treatment costs. Pathogenesis of OA involves the structures of the whole joint especially subchondral bone and synovium but is characterized predominantly by articular cartilage destruction^[1]. Cartilaginous tissues possess relatively few amounts cells

(chondrocytes) that account 1%-5% of volume^[2] and large amounts of extracellular matrix that constitutes the bulk of tissue and protects chondrocytes from mechanical overloading.

Cartilage destruction in osteoarthritis is multifactorial cascade process in which participate both cells and extracellular matrix, especially sulfated glycosaminoglycans. These last are included in proteoglycans and play the leading role in support of tissue homeostasis, architectonics and mechanical stability, cellular mitogenic activity, receptive functions and intercellular relations^[3].

Mineralization of cartilage has been associated with OA progression and cartilage destruction^[4] but some authors consider it as primarily an effect of aging^[5].

A lot of biochemical and microscopical methods are used in modern researches of cartilage content and structure but X-ray-microprobe analysis was performed very rare though it permit to evaluate glycosaminoglycans and mineral content by corresponding chemical elements.

To develop the optimal methods of articular hyaline cartilage sample preparation for X-ray-electron probe microanalysis and to compare its elements content in intact animals and in animals with experimentally induced osteoarthritis.

MATERIALS AND METHODS

Twenty healthy adult mongrel dogs of either sex, aged 2-8 years, weighing 18-25 kg, were used in this study. All animals have received human care in compliance with the protocol approved by the Institutional Ethical Committee. The animals were acclimatized to laboratory conditions for one month prior experimentation. Dogs were housed in individual cages (floor area 4.5 m²) and were provided water three times daily and food two times daily with a measured volume. Animals were divided in research (aged 2 years) and intact group (control). Intact group included three subgroups (aged 2, 5 and 8 years). In research group modelling of primary gonarthrosis was performed by reduction of limb blood supply and knee immobilization^[6]. So, dogs of research group were operated. Anesthesia was first induced with intramuscular injections of atropine, dimedrol and xylazine and then maintained with intravenous injection sodium pentobarbital (30 mg/kg *i.v.*). Briefly, each femoral artery was freed from surrounding tissues and after proximal and distal ligation was resected. Each knee joint were immobilized with external fixation apparatus. After 28 d of immobilization dogs of research group were euthanized. Dogs of intact group were also euthanized by barbiturate overdose (intravenous injection, 150 mg/kg pentobarbital sodium) for tissue collection.

Samples of cartilage were harvested from lateral femoral condyles - presented in Figure 1A. Samples consisted of slices 2-3 mm thick, 5-6 mm long and 2-3 mm wide were cut with a scalpel tangentially within

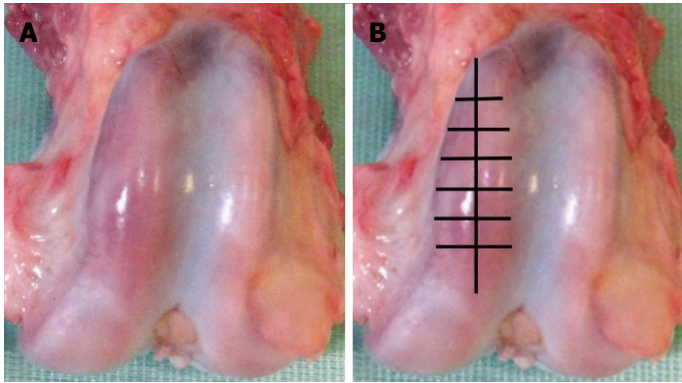


Figure 1 Condyles of canine thigh bone after experimental modelling of osteoarthritis (A), scheme of articular cartilage harvesting (B).




Figure 2 X-ray electron probe microanalysis of articular cartilage in intact dog. A: SEM micrograph of articular cartilage and subchondral zone; B: Scanning line regimen, graph shows calcium distribution on line; C: Scanning area regimen shows calcium distribution on the sample surface. Instrumental magnification $\times 110$.

articular cartilage - presented in Figure 1B. Samples were fixed in glutaraldehyde-paraformaldehyde mixture excluding postfixation in tetroxide osmium because X-ray peaks of heavy metals may mask and overlap on rays of analyzed elements^[7,8]. Taking into consideration very high water content in cartilage^[2] the specimens were dehydrated with smooth transition from ethanol to acetone according to known methods^[9] but with increasing of exposition in 70%-96% ethanol to within the hour. Stages of araldite saturation and pouring were performed according to recently described method^[10]. Increased density of cartilage matrix in araldite in comparison with native material decrease volume of X-ray excitation and provide the increase of microanalysis sensitivity.

Further investigation included two stages. At the first stage epoxy blocks were partially cut into semithin (1 mkm) sections with a glass knife using ultramicrotome "Nova" (LKB, Sweden). Slices were stained with methylene blue (metachromatic reaction for sulfated glycosaminoglycans) and with methylene blue-basic fuchsin (for detection of matrix basophilia). Histology slides were examined using the "Opton-3" photomicroscope (Germany).

At the second stage smooth surfaces of epoxy blocks resulting from semithin slices cutting were investigated by X-ray-electron probe microanalysis. This technique prevents artifacts and saves the sample preparation time excluding the stage of grinding and polishing.

Three blocks was selected randomly from each animal. They were attached to polished clean aluminium

discs with current-conducting adhesive. Surfaces of epoxy blocks were exposed to silver deposition using Eico IB-6 ion coater and JEOL JEE-4X vacuum evaporator. The investigation of element composition was performed using scanning electron microscope JSM-840 (JEOL, Japan) equipped with energy dispersive X-ray analyser (INCA 200, Oxford Instruments).

Results were obtained as smart maps, showing spatial distribution of elements and quantitative data in weight per cents. Spatial distribution of sulfur, calcium and phosphorus and their concentrations (ωS , ωCa , ωP - weight %) were investigated. For standard results equipment was calibrated by comparison templet made of wollastonite ($CaO: SiO_2$). Two regimens were used for collecting X-ray spectra: Scanning line and scanning area - presented in Figure 2. In the second regimen strict longitudinal alignment of parallel scanning rows without overlapping fields provided the most representative total sample.

Statistical analysis

For quantitative data analysis the unpaired Student *t* test and Mann-Whitney *U* test were used (software package Attestat Program, version 9.3.1, developed by I.P. Gaidyshev, Certificate of Rospatent official registration No. 2002611109). If the *P*-value was less than 0.05, the data was considered statistically significant.

RESULTS

In 2 years-aged intact group metachromatic reaction in

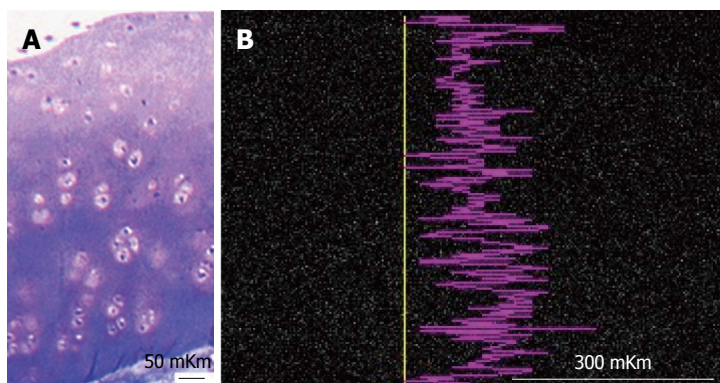


Figure 3 Articular cartilage of intact dog. A: Semithin section, methylene blue stain. Ob. -6.3 x; oc. -12.5 x; B: Smart map shows sulphur distribution on scanned line. Instrumental magnification 170.

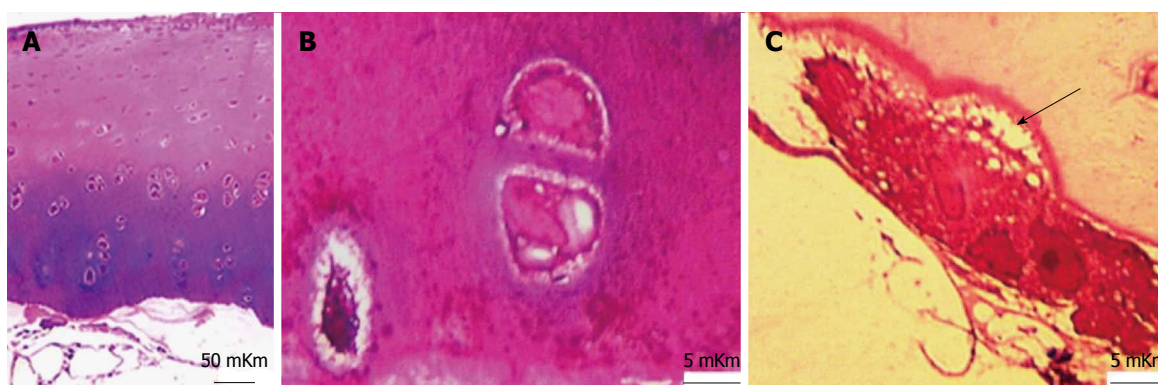

Figure 4 Articular cartilage in dog with experimentally induced osteoarthritis. Methylene blue - basic fuchsin staining. A: General appearance. Ob. - 6.3 x, oc. - 12.5 x; B: Focal basophilia of intercellular matrix in deep zone. Ob. - 100 Ol, oc. - 12.5 x; C: Osteoclast, resorbing the ground substance of calcified cartilage. Howship lacuna (arrow). Ob. - 100 Ol, oc. - 12.5 x.

interterritorial matrix of superficial zone was moderate but in territorial matrix of intermediate and deep zones it was highly intensive - presented in Figure 3A. X-ray electron probe microanalysis revealed nonuniformity of Sulphur zonal distribution - presented in Figure 3B.

In IOA (induced osteoarthritis) group metachromatic reaction was localized, its intensity was lowered and accompanied with fibrillation of matrix in superficial zone. Intensively basophilic matrix was revealed in intermediate and deep zones and presented in Figure 4A and B. The calcified cartilage zone was thinned or absolutely absent in some areas (Figures 4A and 5). At the borderline between calcified cartilage and subchondral bone the osteoclastic resorption was marked - presented in Figure 4C.

In 5 years-aged intact group histochemical reaction for sulfated glycosaminoglycans was weak, metachromasy was focal (Figure 6A), matrix of superficial zone was basophilic, many of cells had signs of destruction.

In 8 years-aged intact group metachromatic reaction was also focal, locuses of intensive metachromasy were revealed in intermediate and deep zones (Figure 6B), cartilaginous cells had increased sizes, light homogeneous nuclei and basophilic cytoplasm. Territorial matrix of deep zone was basophilic.

In IOA group ω S were decreased in all of cartilage zones besides calcified, but its distribution with maximal

meanings in intermediate and deep zones was the same as in two-year-old intact group. In five-year-old intact group in comparison with two-year-old intact group ω S was decreased in superficial, intermediate and deep zones, but increased in calcified cartilage. In eight-year-old intact group in comparison with two-year-old intact group ω S was increased in intermediate, deep and calcified cartilage zones, but not in superficial zone - presented in Table 1.

In IOA group in comparison with two-year-old intact group ω Ca was increased in all zones of cartilage besides the calcified. In five-year-old intact group ω Ca was increased only in superficial zone and in calcified cartilage. In eight-year-old intact group more expressed increase in deep and calcified zones were marked (Table 1).

Changes of ω P were differently directed. In IOA it was increased in intermediate and deep zones but decreased in calcified cartilage. In 5 years-aged and especially in 8 years-aged intact groups ω P was increased in all zones including calcified cartilage - presented in Figure 7 and Table 1.

DISCUSSION

So, X-ray electron probe microanalysis revealed non-uniform serum distribution in cartilage of intact animals: its content increases from superficial to deep zone,

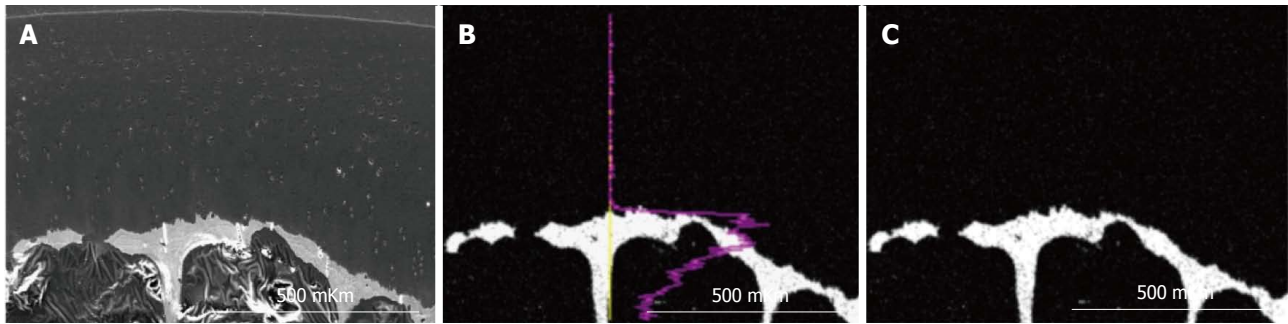


Figure 5 X-ray electron probe microanalysis of articular cartilage in dog with experimentally induced osteoarthritis. A: SEM micrograph of articular cartilage and subchondral zone; B: Scanning line regimen, graph shows calcium distribution on line; C: Scanning area regimen shows calcium distribution on the sample surface. Instrumental magnification 100.

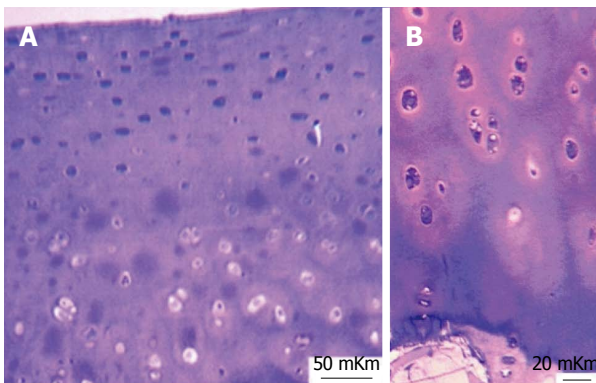


Figure 6 Age-related changes of articular cartilage in intact group. Semithin section. Methylene blue - basic fuchsin staining. A: Focal metachromasy of articular cartilage in five year old dog. Ob. - 6,3 x; oc. - 12,5 x; B: Intensive metachromasy in intermediate and deep zones of articular cartilage in eight year old dog. Ob. - 16 x; oc. - 12,5 x.

this regularity was preserved in animals with induced experimental osteoarthritis. The obtained data are in agreement with literature: The aggrecan content in superficial zone is lower than in others^[11]. It is known that metabolism of sulfated glycosaminoglycans changes in the early stages of articular cartilage damage^[12].

Recently we obtained histological characteristics of articular cartilage in experimentally induced osteoarthritis^[13,14] corresponding to grade 1-3 according to OARSI classification^[15]. It was revealed^[14] that in this experimental model chondrocytes of intermediate zone were the most vulnerable: More than 50% cells had signs of necrosis or apoptosis. It is known that apoptotic bodies contain alkaline phosphatase and precipitate calcium promoting cartilage calcification^[16].

According to other authors hypertrophic chondrocytes of osteoarthrotic cartilage produce large amounts of collagen X, matrix proteinase 12 and alkaline phosphatase influencing calcification^[17]. Ohira and Ishikawa^[18] (1986) found precipitates of hydroxiapatite crystals around degenerated chondrocytes.

In current research substantial difference of experimentally induced osteoarthritis from spontaneous chondropathy were revealed. Spontaneous aging characterizes by calcium and phosphorus storage in deep

and calcified zones and compensatory increase of sulfated glycosaminoglycans in intermediate and deep cartilage zones as evidenced by the metachromatic reaction and microanalysis data. Unlike spontaneous chondropathy connected with aging in experimentally reduced osteoarthritis more intensive storage of calcium but minor phosphorus in intermediate zone were marked. The revealed contradistinction is in agreement with research of human aging, which leads to suggest that phosphorus exuded from bones storages in arteries and cartilage tissue^[19].

In experimentally induced osteoarthritis the calcified cartilage thinning and osteoclastic resorption are apparent with few changes of elements composition; the only difference from control is minority phosphorus content.

Preparation of biologic samples for X-ray electron probe microanalysis perform according the same principles as preparation for electron microscopy but possess its own specific tricks; peculiar properties of research object also must be taken into consideration. The obtained results demonstrate definitely the possibility of X-ray electron probe microanalysis in the research of mechanisms of articular cartilage alteration in osteoarthritis, these changes is documented and assessed quantitatively.

ACKNOWLEDGMENTS

The authors would like to thank the members of the engineering group for their technical support and I.P. Gaidyshev for his help in statistical analysis.

COMMENTS

Background

Multiple biochemical and microscopic methods are used in modern researches of cartilage content and structure in normal and diseased human and animal beings but X-ray-microprobe analysis was performed very rare though it permit to evaluate glycosaminoglycans and mineral content by corresponding chemical elements. The optimal methods of articular hyaline cartilage sample preparation for X-ray-electron probe microanalysis and comparison of its elements content in intact animals of different ages and in animals with experimentally induced osteoarthritis were not investigated.




Figure 7 X-ray electron probe microanalysis of articular cartilage in intact five years old dog. A: SEM micrograph of articular cartilage and subchondral zone; B: Scanning line regimen, graph shows phosphorus distribution on line; C: Scanning area regimen shows phosphorus distribution on the sample surface. Instrumental magnification 120.

Table 1 Content of chemical elements in canine articular cartilage

Cartilage zones/groups	Superficial zone	Intermediate zone	Deep zone	Zone of calcified cartilage
ω S (mean \pm SD, weight%)				
IOA in 2 yr	0.18 ± 0.04^a	0.23 ± 0.02^a	0.28 ± 0.03^a	0.13 ± 0.02
Intact				
2 yr (control)	0.35 ± 0.01	0.42 ± 0.04	0.52 ± 0.02	0.14 ± 0.02
5 yr	0.20 ± 0.02^a	0.28 ± 0.04^a	0.34 ± 0.02^a	0.28 ± 0.04^a
8 yr	0.33 ± 0.03	0.52 ± 0.01^a	0.63 ± 0.04^a	0.41 ± 0.07^a
ω Ca (mean \pm SD, weight%)				
IOA in 2 yr	0.04 ± 0.02	0.08 ± 0.02^a	0.15 ± 0.02^a	9.72 ± 0.03
Intact				
2 yr (control)	< 0.01	0.04 ± 0.01	0.09 ± 0.01	13.93 ± 0.02
5 yr	0.04 ± 0.01	0.05 ± 0.03	0.10 ± 0.02	16.16 ± 1.04^a
8 yr	0.03 ± 0.02	0.05 ± 0.03	0.22 ± 0.02^a	21.16 ± 3.04^a
ω P (mean \pm SD, weight%)				
IOA in 2 yr	< 0.02	0.03 ± 0.01	0.08 ± 0.01	4.74 ± 0.02^a
Intact				
2 yr (control)	< 0.01	< 0.01	< 0.01	6.89 ± 0.01
5 yr	< 0.02	0.07 ± 0.01^a	0.09 ± 0.02^a	7.44 ± 1.47^a
8 yr	0.04 ± 0.02^a	0.09 ± 0.02^a	0.11 ± 0.02^a	9.44 ± 1.29^a

^a $P < 0.05$, *vs* control.

Research frontiers

Previous research have already proved that in this experimental model of primary osteoarthritis chondrocytes of intermediate zone were the most vulnerable and that apoptotic bodies promote cartilage calcification.

Innovations and breakthroughs

This is the first study evaluating substantial difference of experimental gonarthrosis induced by reduction of limb blood supply and knee immobilization from spontaneous age-related chondropathy. The optimized methods of articular hyaline cartilage sample preparation for X-ray-electron probe microanalysis are described.

Applications

In experimentally induced osteoarthritis the uncalcified cartilage was characterized with minority Sulphur content, calcium and phosphorus storage in comparison with intact animals of corresponding age. The calcified cartilage thinning and osteoclastic resorption in induction of osteoarthritis are apparent with few changes of elements composition; the only difference from control is minority phosphorus content.

Terminology

Experimentally stimulated osteoarthritis in used biological model histologically corresponds to grade 1-3 according to OARSI classification.

Peer-review

Stupina *et al* developed methods of articular cartilage preparation for X-ray-electron probe microanalysis and to study its elements content in experimental osteoarthritis. It is well designed and written manuscript. It is a potential important study to the fields of osteoarthritis research, diagnosis and therapy.

REFERENCES

- Hunter DJ, Felson DT. Osteoarthritis. *BMJ* 2006; **332**: 639-642 [PMID: 16543327 DOI: 10.1136/bmj.332.7542.639]
- Jerosch J. Effects of Glucosamine and Chondroitin Sulfate on Cartilage Metabolism in OA: Outlook on Other Nutrient Partners Especially Omega-3 Fatty Acids. *Int J Rheumatol* 2011; **2011**: 969012 [PMID: 21826146 DOI: 10.1155/2011/969012]
- Seidman AM, Korel AV. Structural and functional features of the plate human vertebral body growth during critical periods of growth. *Surg Vertebral* 2004; **2**: 113-120
- Fuerst M, Bertrand J, Lammers L, Dreier R, Echtermeyer F, Nitschke Y, Rutsch F, Schäfer FK, Niggemeyer O, Steinhagen J, Lohmann CH, Pap T, Rüther W. Calcification of articular cartilage in human osteoarthritis. *Arthritis Rheum* 2009; **60**: 2694-2703 [PMID: 19714647 DOI: 10.1002/art.24774]
- Mitsuyama H, Healey RM, Terkeltaub RA, Coutts RD, Amiel D. Calcification of human articular knee cartilage is primarily an effect

- of aging rather than osteoarthritis. *Osteoarthritis Cartilage* 2007; **15**: 559-565 [PMID: 17276093 DOI: 10.1016/j.joca.2006.10.017]
- 6 **Makushin VD**, Stepanov MA, Stupina TA, Inventors. Method of Simulating Osteoarthrosis of Knee. Russia patent RF 2452999. 2012. Jun 10
- 7 **Goldstein J**, Newbury D, Echlin P, Dzhoy D, Fiori C, Lifshin E. Raster electronic microscopy and x-rayed Microprobe Analysis. *M: World* 1984; **1**: 348
- 8 **Shahlamov VA**, Buravkov SV. Application of X-ray local microanalysis in biology and medicine. *Arkh Anat Histol Embriol* 1983; **4**: 95-107
- 9 **Weakley B**. A beginners handbook in biological electron microscopy. *M: World* 1975: 324
- 10 **Stupina TA**, Shchudlo MM. A method for making preparations from nondecalcified articular cartilage with sublying subchondral bone for multipurpose studies. *Bull Exp Biol Med* 2014; **157**: 388-390 [DOI: 10.1007/s10517-014-2576-z]
- 11 **Anderson HC**, Hodges PT, Aguilera XM, Missana L, Moylan PE. Bone morphogenetic protein (BMP) localization in developing human and rat growth plate, metaphysis, epiphysis, and articular cartilage. *J Histochem Cytochem* 2000; **48**: 1493-1502 [PMID: 11036092]
- 12 **Pavlova VN**, Pavlov GG, Shostak NA, Slutsky LI. Joint: The morphology, clinic, diagnostics, treatment. M: OOO "Publisher" Medical News Agency", 2011: 552
- 13 **Stupina TA**, Shchudlo NA, Stepanov MA. Structural reorganization of the main joint components during the experimental modeling of osteoarthrosis with reduced blood supply. *Morfologiya* 2014; **146**: 61-65
- 14 **Shevtsov VI**, Makushin VD, Stepanov MA, Stupina TA. The problem of the knee osteoarthrosis modeling in dogs for the purpose of pathogenesis studying (experimental morphological study). *Genius Orthop* 2012; **1**: 38-42
- 15 **Pritzker KP**, Gay S, Jimenez SA, Ostergaard K, Pelletier JP, Revell PA, Salter D, van den Berg WB. Osteoarthritis cartilage histopathology: grading and staging. *Osteoarthritis Cartilage* 2006; **14**: 13-29 [PMID: 16242352 DOI: 10.1016/j.joca.2005.07.014]
- 16 **Adams CS**, Shapiro IM. The fate of the terminally differentiated chondrocyte: evidence for microenvironmental regulation of chondrocyte apoptosis. *Crit Rev Oral Biol Med* 2002; **13**: 465-473 [PMID: 12499240]
- 17 **Tchetina EV**. The mechanisms of embryogenesis in osteoarthritis: the role of differentiation of chondrocytes in articular cartilage resorption. *Sci Practical Rheumatol* 2010; **3**: 65-77
- 18 **Ohira T**, Ishikawa K. Hydroxyapatite deposition in articular cartilage by intra-articular injections of methylprednisolone. A histological, ultrastructural, and x-ray-microprobe analysis in rabbits. *J Bone Joint Surg Am* 1986; **68**: 509-520 [PMID: 3007526]
- 19 **Tohno Y**, Tohno S, Minami T, Moriwake Y, Utsumi M, Yamada M. A possible balance of phosphorus accumulations among bone, cartilage, artery, and vein in single human individuals. *Biol Trace Elem Res* 1999; **69**: 241-248 [PMID: 10468161 DOI: 10.1007/BF02783876]

P- Reviewer: Zhou S **S- Editor:** Kong JX **L- Editor:** A
E- Editor: Lu YJ





Published by **Baishideng Publishing Group Inc**
7901 Stoneridge Drive, Suite 501, Pleasanton, CA 94588, USA
Telephone: +1-925-223-8242
Fax: +1-925-223-8243
E-mail: bpgoffice@wjgnet.com
Help Desk: <http://www.f6publishing.com/helpdesk>
<http://www.wjgnet.com>

