


World Journal of *Clinical Oncology*

World J Clin Oncol 2017 June 10; 8(3): 178-304





REVIEW

- 178 Histone deacetylases, microRNA and leptin crosstalk in pancreatic cancer
Tchio Mantho CI, Harbuzariu A, Gonzalez-Perez RR
- 190 Multidisciplinary approach of colorectal cancer liver metastases
Fiorentini G, Sarti D, Aliberti C, Carandina R, Mambrini A, Guadagni S
- 203 Evolving role of Sorafenib in the management of hepatocellular carcinoma
Ziogas IA, Tsoulfas G
- 214 Magnetic resonance imaging for diagnosis and neoadjuvant treatment evaluation in locally advanced rectal cancer: A pictorial review
Engin G, Sharifov R

MINIREVIEWS

- 230 Immunotherapy in pancreatic cancer: Unleash its potential through novel combinations
Guo S, Contratto M, Miller G, Leichman L, Wu J
- 241 Current state and controversies in fertility preservation in women with breast cancer
Taylan E, Oktay KH
- 249 Biological mesh reconstruction of the pelvic floor following abdominoperineal excision for cancer: A review
Schiltz B, Buchs NC, Penna M, Scarpa CR, Liot E, Morel P, Ris F
- 255 Potential prognostic biomarkers in pancreatic juice of resectable pancreatic ductal adenocarcinoma
Agrawal S

ORIGINAL ARTICLE

Case Control Study

- 261 Levels of neutrophil gelatinase-associated lipocalin in patients with head and neck squamous cell carcinoma in Indian population from Haryana state
Verma M, Dahiya K, Soni A, Dhankhar R, Ghalaat VS, Bansal A, Kaushal V

SYSTEMATIC REVIEWS

- 266 Recurrence-free survival as a putative surrogate for overall survival in phase III trials of curative-intent treatment of colorectal liver metastases: Systematic review
Araujo RLC, Herman P, Riechelmann RP

META-ANALYSIS

- 273** Robot-assisted laparoscopic *vs* open gastrectomy for gastric cancer: Systematic review and meta-analysis
Caruso S, Patriti A, Roviello F, De Franco L, Franceschini F, Ceccarelli G, Coratti A

CASE REPORT

- 285** Bilateral diffuse grade 5 radiation pneumonitis after intensity modulated radiation therapy for localized lung cancer
Osborn VW, Leaf A, Lee A, Garay E, Safdieh J, Schwartz D, Schreiber D
- 289** Prostatic adenocarcinoma, oncocytic variant: Case report and literature review
Klaimont MM, Zafar N
- 293** Pancreatic neuroendocrine tumor Grade 1 patients followed up without surgery: Case series
Sugimoto M, Takagi T, Suzuki R, Konno N, Asama H, Watanabe K, Nakamura J, Kikuchi H, Waragai Y, Takasumi M, Kawana S, Hashimoto Y, Hikichi T, Ohira H
- 300** Target migration from re-inflation of adjacent atelectasis during lung stereotactic body radiotherapy
Mao B, Verma V, Zheng D, Zhu X, Bennion NR, Bhurud AR, Poole MA, Zhen W

Contents

World Journal of Clinical Oncology
Volume 8 Number 3 June 10, 2017

ABOUT COVER

Editorial Board Member of *World Journal of Clinical Oncology*, Bin Wang, PhD, Assistant Professor, Department of Biomedical Engineering, Widener University, Chester, PA 19013, United States

AIM AND SCOPE

World Journal of Clinical Oncology (*World J Clin Oncol*, *WJCO*, online ISSN 2218-4333, DOI: 10.5306) is a peer-reviewed open access academic journal that aims to guide clinical practice and improve diagnostic and therapeutic skills of clinicians.

WJCO covers a variety of clinical medical topics, including etiology, epidemiology, evidence-based medicine, informatics, diagnostic imaging, endoscopy, tumor recurrence and metastasis, tumor stem cells, radiotherapy, chemotherapy, interventional radiology, palliative therapy, clinical chemotherapy, biological therapy, minimally invasive therapy, physiotherapy, psycho-oncology, comprehensive therapy, and oncology-related nursing. Priority publication will be given to articles concerning diagnosis and treatment of oncology diseases. The following aspects are covered: Clinical diagnosis, laboratory diagnosis, differential diagnosis, imaging tests, pathological diagnosis, molecular biological diagnosis, immunological diagnosis, genetic diagnosis, functional diagnostics, and physical diagnosis; and comprehensive therapy, drug therapy, surgical therapy, interventional treatment, minimally invasive therapy, and robot-assisted therapy.

We encourage authors to submit their manuscripts to *WJCO*. We will give priority to manuscripts that are supported by major national and international foundations and those that are of great clinical significance.

INDEXING/ABSTRACTING

World Journal of Clinical Oncology is now indexed in PubMed, PubMed Central and Scopus.

FLYLEAF

I-III Editorial Board

EDITORS FOR THIS ISSUE

Responsible Assistant Editor: *Xiang Li*
Responsible Electronic Editor: *Ya-Jing Lu*
Proofing Editor-in-Chief: *Lian-Sheng Ma*

Responsible Science Editor: *Fang-Fang Ji*
Proofing Editorial Office Director: *Ze-Mao Gong*

NAME OF JOURNAL
World Journal of Clinical Oncology

ISSN
ISSN 2218-4333 (online)

LAUNCH DATE
November 10, 2010

FREQUENCY
Bimonthly

EDITOR-IN-CHIEF
Godefridus J Peters, PhD, Professor, Department of Medical Oncology, Cancer Center Amsterdam, VU University Medical Center, Amsterdam 1081 HV, Netherlands

EDITORIAL BOARD MEMBERS
All editorial board members resources online at <http://www.wjgnet.com/2218-4333/editorialboard.htm>

EDITORIAL OFFICE
Xiu-Xia Song, Director

World Journal of Clinical Oncology
Baishideng Publishing Group Inc
7901 Stoneridge Drive, Suite 501, Pleasanton, CA 94588, USA
Telephone: +1-925-2238242
Fax: +1-925-2238243
E-mail: editorialoffice@wjgnet.com
Help Desk: <http://www.f6publishing.com/helpdesk>
<http://www.wjgnet.com>

PUBLISHER
Baishideng Publishing Group Inc
7901 Stoneridge Drive,
Suite 501, Pleasanton, CA 94588, USA
Telephone: +1-925-2238242
Fax: +1-925-2238243
E-mail: bpgoffice@wjgnet.com
Help Desk: <http://www.f6publishing.com/helpdesk>
<http://www.wjgnet.com>

PUBLICATION DATE
June 10, 2017

COPYRIGHT

© 2017 Baishideng Publishing Group Inc. Articles published by this Open-Access journal are distributed under the terms of the Creative Commons Attribution Non-commercial License, which permits use, distribution, and reproduction in any medium, provided the original work is properly cited, the use is non commercial and is otherwise in compliance with the license.

SPECIAL STATEMENT

All articles published in journals owned by the Baishideng Publishing Group (BPG) represent the views and opinions of their authors, and not the views, opinions or policies of the BPG, except where otherwise explicitly indicated.

INSTRUCTIONS TO AUTHORS

<http://www.wjgnet.com/bpg/gerinfo/204>

ONLINE SUBMISSION

<http://www.f6publishing.com>

Biological mesh reconstruction of the pelvic floor following abdominoperineal excision for cancer: A review

Boris Schiltz, Nicolas Christian Buchs, Marta Penna, Cosimo Riccardo Scarpa, Emilie Liot, Philippe Morel, Frederic Ris

Boris Schiltz, Nicolas Christian Buchs, Cosimo Riccardo Scarpa, Emilie Liot, Philippe Morel, Frederic Ris, Division of Visceral Surgery, Department of Surgery, University Hospitals of Geneva, 1205 Geneva, Switzerland

Marta Penna, Department of Colorectal Surgery, Churchill Hospital, Oxford University Hospitals, Headington, Oxford OX3 7LE, United Kingdom

Author contributions: Schiltz B, Buchs NC and Morel P designed the research; Schiltz B, Buchs NC, Scarpa CR and Liot E performed the research (local data and literature review); Schiltz B, Buchs NC, Penna M, Liot E and Ris F interpreted the data; Morel P and Ris F revised the article; all authors gave their final approval.

Conflict-of-interest statement: None of the authors have conflicts of interest to report.

Open-Access: This article is an open-access article which was selected by an in-house editor and fully peer-reviewed by external reviewers. It is distributed in accordance with the Creative Commons Attribution Non Commercial (CC BY-NC 4.0) license, which permits others to distribute, remix, adapt, build upon this work non-commercially, and license their derivative works on different terms, provided the original work is properly cited and the use is non-commercial. See: <http://creativecommons.org/licenses/by-nc/4.0/>

Manuscript source: Invited manuscript

Correspondence to: Boris Schiltz, MD, Division of Visceral Surgery, Department of Surgery, University Hospitals of Geneva, Rue Gabrielle-Perret-Gentil 4, 1205 Geneva, Switzerland. boris.schiltz@hcuge.ch
Telephone: +41-79-5534161
Fax: +41-22-3727707

Received: January 28, 2017

Peer-review started: February 10, 2017

First decision: March 28, 2017

Revised: April 12, 2017

Accepted: May 12, 2017

Article in press: May 14, 2017

Published online: June 10, 2017

Abstract

Extralevator abdominoperineal excision and pelvic exenteration are mutilating operations that leave wide perineal wounds. Such large wounds are prone to infection and perineal herniation, and their closure is a major concern to most surgeons. Different approaches to the perineal repair exist, varying from primary or mesh closure to myocutaneous flaps. Each technique has its own associated advantages and potential complications and the ideal approach is still debated. In the present study, we reviewed the current literature and our own local data regarding the use of biological mesh for perineal wound closure. Current evidence suggests that the use of biological mesh carries an acceptable risk of wound complications compared to primary closure and is similar to flap reconstruction. In addition, the rate of perineal hernia is lower in early follow-up, while long-term hernia occurrence appears to be similar between the different techniques. Finally, it is an easy and quick reconstruction method. Although more expensive than primary closure, the cost associated with the use of a biological mesh is at least equal, if not less, than flap reconstruction.

Key words: Biological mesh; Rectal cancer; Pelvic exenteration; Abdominoperineal resection; Primary perineal wound closure; Perineal wound infection; Perineal hernia

© The Author(s) 2017. Published by Baishideng Publishing Group Inc. All rights reserved.

Core tip: Current literature regarding the use of biological mesh reconstruction after pelvic exenteration and extralevator abdominoperineal excision is scarce. However, it does suggest that the use of biological mesh has a lower short-term perineal hernia rate, but is probably not superior to other approaches with regards to perineal wound complications.

Schiltz B, Buchs NC, Penna M, Scarpa CR, Liot E, Morel P, Ris

F. Biological mesh reconstruction of the pelvic floor following abdominoperineal excision for cancer: A review. *World J Clin Oncol* 2017; 8(3): 249-254 Available from: URL: <http://www.wjgnet.com/2218-4333/full/v8/i3/249.htm> DOI: <http://dx.doi.org/10.5306/wjco.v8.i3.249>

INTRODUCTION

Pelvic exenteration (PE) and extralevator abdominoperineal excision (ELAPE) are mutilating operations, leaving a large perineal incision. ELAPE for low rectal cancer was introduced to decrease the rate of positive resection margins and specimen perforation occurring during conventional abdominoperineal resection (cAPR)^[1,2]. In a recent retrospective study, Stelzner *et al*^[3] showed that the 5-year recurrence rate was 5.9% in the ELAPE group vs 18.2% in the cAPR group ($P = 0.153$). However, other units have not been able to reproduce such results^[4], nor could they demonstrate a statistically significant superiority of ELAPE in terms of CRM positivity and bowel perforation. Furthermore, they reported comparable perineal complication rates for the two APR approaches.

Vivid discussions continue to fuel the debate regarding the pros and cons of ELAPE. Overall, it is well accepted that larger wounds are independent risk factors for perineal wound complications. The combination of neoadjuvant chemoradiotherapy and ELAPE almost doubles the rate of perineal wound complications (31% for ELAPE vs 18% for cAPR)^[5]. While new techniques and approaches have attempted to reduce the size of the perineal incision (and therefore reduce the risk of wound complications)^[6], optimal management of perineal defects is still under investigation. The options include primary closure, myocutaneous flaps, and mesh reconstruction, including the use of a biological mesh.

We aimed to evaluate the outcomes of perineal reconstruction with biological mesh following ELAPE and PE in our center and to review the current literature.

CURRENT STATUS

Perineal wound complications are a major concern following PE and ELAPE leading to increased morbidity, longer hospital stay, and delayed chemotherapy. Different reconstruction methods are currently used in practice with the aim of reducing the rates of wound complications and avoiding perineal herniation.

Risk factors for major perineal wound complications following APR are well known: Preoperative radiotherapy, patients with anal cancer, flap reconstruction, tumor size, obesity, and diabetes^[7]. Minor wound complications appear more commonly in patients with inflammatory bowel disease or anal cancer than in those with rectal cancer^[8].

Most patients with locally advanced rectal cancer, recurrent rectal cancer, and recurrent or persistent squamous cell carcinoma receive neoadjuvant radio-

chemotherapy or radiotherapy alone^[9,10]. The poor healing ability of irradiated wounds has been attributed to local endarteritis and damaged fibroblasts^[11]. It has been clearly demonstrated that preoperative radiotherapy increases the rate of major wound complications^[5,12]. For example, Aldulaymi *et al*^[13] reported a significantly increased risk of major perineal wound complications in patients undergoing APR for rectal cancer with primary closure of the perineum (26% in non-irradiated vs 71% in irradiated patients). Chadwick *et al*^[14] found that the risk of developing a wound complication was 10 times higher after previous irradiation. This substantial problem with wound healing calls for the need to consider alternative closure techniques of the perineum.

Different methods have been described ranging from direct/primary closure to mesh reconstruction, gluteal and rectus abdominis flaps or combinations of these techniques. Currently, there is no consensus on which is the most ideal technique^[15]. The vertical rectus abdominis flap (VRAM) is indicated to bring non-irradiated tissue into the perineal defect^[16]. After VRAM, perineal wound complications have been reported to range from 0% to 28%^[17-20]. The use of laparoscopy for the abdominal part of the resection is almost impossible because of the donor site. In addition, in cases of PE (with a right sided urostomy and left sided end colostomy), VRAM is often contra-indicated. A potential solution is the use of a wet double-barreled colostomy^[21].

Other myocutaneous flaps can potentially be used, such as the gracilis flap and the gluteus maximus flap, which have a perineal wound complication rate of 12%^[22] and 10%^[2] respectively. However, these flaps are typically smaller than the VRAM flap and unlikely to provide adequate cover of large defects.

In addition, authors argue that myocutaneous flaps carry significant risks of donor site morbidity, flap necrosis, prolonged operative time, and usually require co-ordination with plastic surgeons^[2,23,24]. Mesh reconstruction is another technique, which has attracted a lot of interest in the last few years, especially with the adoption of ELAPE. Briefly, the biological mesh is sutured directly to the pelvic side wall (Figures 1-3). The size of the mesh is adapted to the size of the defect. A perineal drain is routinely left at the end of the procedure, in order to avoid a perineal collection.

Both allogenic and xenogenic biological meshes are available for the reconstruction of the perineum. These types of meshes were initially used for abdominal wall reconstructions^[25,26]. The allogenic mesh is predominantly made of human acellular dermis (e.g., HADM® Ruinuo, Qingyuanweiyue Bio-Tissue Engineering Ltd, Beijing, China) as used by Han *et al*^[27,28]. The xenogenic mesh consists of bovine pericardium or porcine dermis and intestinal mucosa. Similar to Musters *et al*^[29] in the BIOPEX-study, we used the Strattice® mesh (LifeCell, Acelity Company, Branchburg, NJ) which is composed of non-reticulated porcine dermis. Jensen *et al*^[30] and Christensen *et al*^[24] used the Permacol® mesh (Tissue Science Laboratories plc, Covington, GA, United States) derived from reticulated

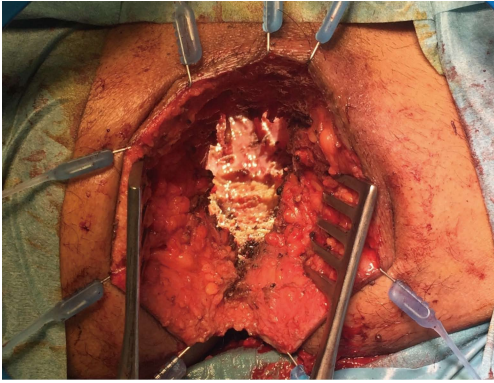


Figure 1 Perineal view before reconstruction in pelvic exenteration patient.

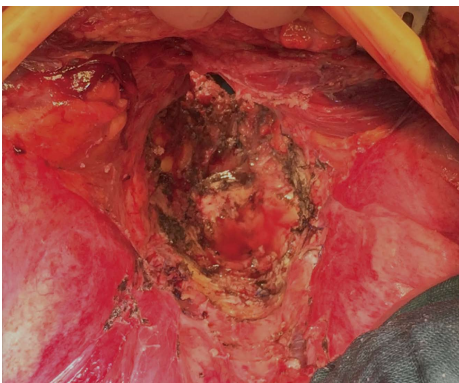


Figure 2 Abdominal view before reconstruction in pelvic exenteration patient.

porcine dermis^[24,30]. Surgisis® Biodesign™ (Cook Medical, Bloomington, IN, United States) created using porcine intestinal mucosa was used by Peacock *et al.*^[31] for their pelvic reconstruction.

Reconstruction using a mesh is relatively simpler and faster compared to flap reconstruction^[24]. When considering cost, meshes are expensive, especially if biological. However, with a potentially shorter operative time and length of hospital stay, overall costs can be controlled and even reduced in comparison to VRAM-flaps^[32]. Biological meshes also have the advantage of being absorbable and can be used in infected environments^[33].

On the other hand, perineal mesh reconstruction is not without its risks. Internal hernias following mesh repair have been reported. Melich *et al.*^[34] described resecting ischemic small bowel loops incarcerated in a pelvic hernia along the mesh in three patients. Jensen *et al.*^[30] reported a hole in the biological mesh in a patient with an infected perineal wound, who subsequently required mesh removal. These reports clearly raise concerns and highlight the risk of small bowel incarceration and necrosis associated with the use of a perineal mesh.

Table 1 summarizes the largest studies focusing on the use of biological mesh for perineal reconstruction. Interestingly, only one mesh was removed^[30]. The overall safety profile appears to be good.

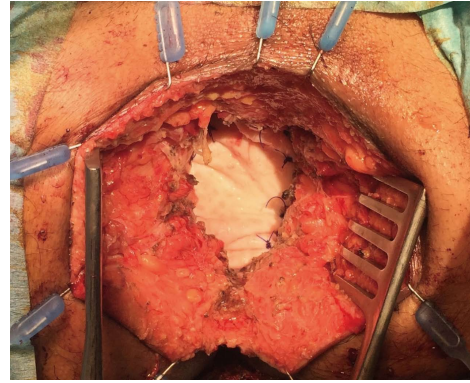


Figure 3 Perineal view after reconstruction using a biological mesh.

Perineal wound complications

The clinical consequences of perineal wound complications are wide and range from a simple redness of the skin to a persistent perineal fistula, and perineal sepsis. Perineal wound complications are often subdivided into two subgroups: Early and delayed wound dehiscence. The delayed (> 4 wk) perineal healing can occur in approximately 25% of cases. Importantly, up to 50% of these cases will develop long-term and persistent perineal symptoms such as pain, chronic sinus, sitting disability or tension between buttocks. All of which can seriously impact the patient's quality of life. Delayed perineal healing may therefore be a risk factor for persistent symptoms providing yet another reason why surgeons must strive to identify the best repair method possible^[35,36].

Primary closure leads to perineal wound complications in 18%-34%^[27,29,37]. Moreover, one third of patients after PE will develop perineal wound dehiscence^[38]. As a corollary, persistent presacral sinus was found in 10% of the patients following APR^[39].

As mentioned in Table 1, 17%-37% of patients with biological mesh presented some degree of perineal wound dehiscence/infection. A Danish retrospective study reported that 15% of patients with biological mesh had a surgical re-intervention for perineal infection. In addition, 21% of the patients had a perineal fistula with 9% requiring surgical excision^[30]. Similarly, Peacock *et al.*^[31] reported an overall perineal wound complication rate of 32%. Vacuum assisted wound therapy and surgical debridement were needed in up to 9% of cases.

Christensen *et al.*^[24] compared gluteal flap reconstruction with biological mesh repair. Seventeen percent of patients in the mesh group had a wound infection compared to 6% in the flap group ($P = 0.26$). At 3 mo, all wounds healed with one persistent sinus in each group^[24].

Han *et al.*^[28] found similar results and subsequently conducted a randomized controlled trial evaluating ELAPE vs cAPR. Interestingly, in the ELAPE group, patients had biological mesh reconstruction. Overall, the perineal wound infection rate (11.4%) after ELAPE was lower than in the cAPR group where 18.8% of patients developed a perineal complication. However, seromas were more frequent in the mesh group (11.4% vs 0%)^[27].

Table 1 Perineal reconstruction with biological mesh

Ref.	Study type	Operation	No. of patients	Average age (median years)	Perineal complications (%)	Surgical perineal debridement n	Perineal hernias	Follow up	Comments
Musters BIOPEX-study 2016 ^[29]	RCT	ELAPE	50	65	37% overall perineal wound complications	4% surgical drainage of perineal abscess, 6% percutaneous drainage of perineal abscess	13% at 1 yr	12 mo	
Jensen <i>et al</i> ^[30] , 2014	Cohort, prospective	ELAPE	53	NR	21% perineal fistula, 7.5% superficial perineal abscess, 7.5% deep perineal abscess	5 (9%) fistulectomy, 8 (15%) surgical debridements	5.60%	Median 36 mo	1 mesh removed (infection), 1 mesh failure (hole) replacement of a new mesh
Christensen <i>et al</i> ^[24] , 2011	Cohort, retrospective	ELAPE	24	69.7	17%, with one fistula after 3 mo	0	0	Median 1.7 yr	-
Han <i>et al</i> ^[28] , 2010	Cohort, retrospective	ELAPE	12	68	16% infection, 8% seroma	0	NR	Median 8 mo	-
Han <i>et al</i> ^[27] , 2012	Derived from RCT	ELAPE	32	68	11.4% wound infections 11% seroma	NR	14%	NR	-
Peacock <i>et al</i> ^[31] , 2014	Cohort, prospective	ELAPE	34	62	32% overall; 9% superficial wound infections, 14% perineal fistula; 9% perineal abscess	3 (9%) surgical debridement/VAC therapy	0	Median 21 mo	-
Schiltz present study	Cohort, retrospective	ELAPE + PE	11	63	Overall 27% wound infections with 1 superficial	2 (18%) surgical debridement	0	Mean 18 mo	-

NR: Not reported; ELAPE: Extralevator abdominoperineal excision; PE: Pelvic exenteration.

Seroma formation can be problematic, pushing most of the authors to recommend the routine use of a perineal drain.

Adding to the present literature, we conducted a retrospective study of our local data. From January 2012 to December 2015, all patients undergoing ELAPE or PE with biological mesh reconstruction were analyzed. Eleven patients were found; all of whom had preoperative radiochemotherapy. Overall, perineal complications were found in 3 (27%) of the patients. In 2 (18%) patients, perineal abscesses were surgically drained and treated with a vacuum assisted wound closure system. One superficial wound infection was treated conservatively. No meshes were removed.

The relatively poor quality of the available studies in the literature remains an issue. These are mainly retrospective or simple cohort studies designed to analyze oncological outcomes. Very few of them focus specifically on perineal complications. Additionally, the severity and grading system of wound complications can differ between reports, and thus it is difficult to draw definitive conclusions.

The only multicenter randomized controlled trial focusing on perineal reconstruction using biological mesh after ELAPE, the BIOPEX study^[29], was recently published. Patients were randomized into two groups, one with perineal mesh reconstruction and the other with

primary closure only (control group). Regular blinded wound follow-up, using the Southampton wound healing score, did not show a significant difference between the two groups at 30 d. In the control group, 34% of perineal wound complications occurred vs 37% in the mesh group ($P = 0.7177$). At 12-mo follow-up, the healing rates did not differ between groups (52% vs 54%). Omentoplasty or use of perineal drains did not affect the results in this study^[29].

In summary, current evidence suggests that biological mesh reconstruction does not appear to reduce the risk of perineal wound complications. Results are similar between primary closure, flap and biological mesh.

Perineal hernia

The incidence of perineal hernia after APR ranges from 0.6% to 27% in the literature^[5,29,40], occurring on average 8 to 22 mo after surgery^[41,42] (Table 1). Such a wide range can partly be explained by the definition of a perineal hernia itself. Indeed, a clinical hernia is quite different from an asymptomatic radiologically identified perineal hernia. Smoking and chemoradiotherapy are well reported risk factors^[42].

Given that recurrence rates following perineal hernia repair are high (up to 37%), prevention is certainly the best strategy^[15]. Perineal hernia occurs significantly less often after biological mesh reconstruction (0%) than

following gluteal flap surgery (21%) ($P < 0.01$)^[24]. Thus suggesting that biological mesh repair can be a good option in order to avoid herniation.

The BIOPEX-study showed that 13% of perineal hernias (diagnosed on CT scan) occurred after biological mesh repair vs 27% in the primary closure group at one-year follow-up ($P = 0.036$)^[29]. The hernias occurred nearer the end of the 12-mo follow-up in the mesh group. The long-term follow-up results are still pending. Interestingly, this delay in the hernia presentation is also described in patients without mesh reconstruction. However, this seems to occur after a median of 8 mo^[41]. A possible explanation is that perineal hernias occur later in the mesh group due to the slower degradation of the biological mesh^[43].

In our own data, no perineal hernia was found, neither clinically or radiologically, even after a mean follow-up of 18 mo.

Overall, biological mesh seems to protect, at least in early follow up, from the occurrence of perineal hernias in comparison to flap reconstruction or primary closure.

CONCLUSION

Perineal reconstruction following ELAPE, APE or PE remains a major problem and challenge. No ideal solution currently exists but various approaches have been attempted with more or less success. Primary closure remains the most frequent technique, carrying a significant risk of perineal hernia formation. On the other hand, the use of flap or mesh reconstruction could help reduce the risk of herniation. Biological mesh appears to be a valid option, at least in terms of hernia prevention, which can be reduced by up to 50%.

Yet, the role of mesh reconstruction in reducing wound infections is less clear. Whilst perineal infection is frequent in irradiated patients, the use of biological mesh seems logical, even if the evidence is scarce to draw definitive recommendations. On the other hand, perineal wound infection remains frequent and a perineal drain should be routinely used.

REFERENCES

- Nagtegaal ID, van de Velde CJ, Marijnen CA, van Krieken JH, Quirke P. Low rectal cancer: a call for a change of approach in abdominoperineal resection. *J Clin Oncol* 2005; **23**: 9257-9264 [PMID: 16361623 DOI: 10.1200/JCO.2005.02.9231]
- Holm T, Ljung A, Häggmark T, Jurell G, Lagergren J. Extended abdominoperineal resection with gluteus maximus flap reconstruction of the pelvic floor for rectal cancer. *Br J Surg* 2007; **94**: 232-238 [PMID: 17143848 DOI: 10.1002/bjs.5489]
- Stelzner S, Hellmich G, Sims A, Kittner T, Puffer E, Zimmer J, Bleyl D, Witzigmann H. Long-term outcome of extralevator abdominoperineal excision (ELAPE) for low rectal cancer. *Int J Colorectal Dis* 2016; **31**: 1729-1737 [PMID: 27631643 DOI: 10.1007/s00384-016-2637-z]
- Zhou X, Sun T, Xie H, Zhang Y, Zeng H, Fu W. Extralevator abdominoperineal excision for low rectal cancer: a systematic review and meta-analysis of the short-term outcome. *Colorectal Dis* 2015; **17**: 474-481 [PMID: 25704132 DOI: 10.1111/codi.12921]
- Musters GD, Buskens CJ, Bemelman WA, Tanis PJ. Perineal wound healing after abdominoperineal resection for rectal cancer: a systematic review and meta-analysis. *Dis Colon Rectum* 2014; **57**: 1129-1139 [PMID: 25101610 DOI: 10.1097/DCR.0000000000000182]
- Buchs NC, Kraus R, Mortensen NJ, Cunningham C, George B, Jones O, Guy R, Ashraf S, Lindsey I, Hompes R. Endoscopically assisted extralevator abdominoperineal excision. *Colorectal Dis* 2015; **17**: 0277-0280 [PMID: 26454256 DOI: 10.1111/codi.13144]
- Matsuda K, Hotta T, Takifuji K, Yokoyama S, Higashiguchi T, Tominaga T, Oku Y, Nasu T, Tamura K, Yamaue H. Long-term comorbidity of diabetes mellitus is a risk factor for perineal wound complications after an abdominoperineal resection. *Langenbecks Arch Surg* 2009; **394**: 65-70 [PMID: 18607625 DOI: 10.1007/s00423-008-0381-8]
- Christian CK, Kwaan MR, Betensky RA, Breen EM, Zinner MJ, Bleday R. Risk factors for perineal wound complications following abdominoperineal resection. *Dis Colon Rectum* 2005; **48**: 43-48 [PMID: 15690656 DOI: 10.1007/s10350-004-0855-x]
- De Caluwé L, Van Nieuwenhove Y, Ceelen WP. Preoperative chemoradiation versus radiation alone for stage II and III resectable rectal cancer. *Cochrane Database Syst Rev* 2013; **(2)**: CD006041 [PMID: 23450565 DOI: 10.1002/14651858.CD006041.pub3]
- Steele SR, Varma MG, Melton GB, Ross HM, Rafferty JF, Buie WD. Practice parameters for anal squamous neoplasms. *Dis Colon Rectum* 2012; **55**: 735-749 [PMID: 22706125 DOI: 10.1097/DCR.0b013e318255815e]
- Miller SH, Rudolph R. Healing in the irradiated wound. *Clin Plast Surg* 1990; **17**: 503-508 [PMID: 2199141]
- Bullard KM, Trudel JL, Baxter NN, Rothenberger DA. Primary perineal wound closure after preoperative radiotherapy and abdominoperineal resection has a high incidence of wound failure. *Dis Colon Rectum* 2005; **48**: 438-443 [PMID: 15719190 DOI: 10.1007/s10350-004-0827-1]
- Aldulaymi BH, Mohammad WA, Jess P. [Perineal wound complications following preoperative radiotherapy for rectal cancer]. *Ugeskr Laeger* 2008; **170**: 1225-1227 [PMID: 18433575]
- Chadwick MA, Vieten D, Pettitt E, Dixon AR, Roe AM. Short course preoperative radiotherapy is the single most important risk factor for perineal wound complications after abdominoperineal excision of the rectum. *Colorectal Dis* 2006; **8**: 756-761 [PMID: 17032320 DOI: 10.1111/j.1463-1318.2006.01029.x]
- Butt HZ, Salem MK, Vijaynagar B, Chaudhri S, Singh B. Perineal reconstruction after extra-levator abdominoperineal excision (eLAPE): a systematic review. *Int J Colorectal Dis* 2013; **28**: 1459-1468 [PMID: 23440362 DOI: 10.1007/s00384-013-1660-6]
- Buchel EW, Finical S, Johnson C. Pelvic reconstruction using vertical rectus abdominis musculocutaneous flaps. *Ann Plast Surg* 2004; **52**: 22-26 [PMID: 14676694 DOI: 10.1097/01.sap.0000099820.10065.2a]
- Butler CE, Gündeslioglu AO, Rodriguez-Bigas MA. Outcomes of immediate vertical rectus abdominis myocutaneous flap reconstruction for irradiated abdominoperineal resection defects. *J Am Coll Surg* 2008; **206**: 694-703 [PMID: 18387476 DOI: 10.1016/j.jamcollsurg.2007.12.007]
- Tei TM, Stolzenburg T, Buntzen S, Laurberg S, Kjeldsen H. Use of transpelvic rectus abdominis musculocutaneous flap for anal cancer salvage surgery. *Br J Surg* 2003; **90**: 575-580 [PMID: 12734865 DOI: 10.1002/bjs.4073]
- Barker T, Branagan G, Wright E, Crick A, McGuinness C, Chave H. Vertical rectus abdominis myocutaneous flap reconstruction of the perineal defect after abdominoperineal excision is associated with low morbidity. *Colorectal Dis* 2013; **15**: 1177-1183 [PMID: 23672636 DOI: 10.1111/codi.12286]
- Lefevre JH, Parc Y, Kernéis S, Shields C, Touboul E, Chaouat M, Tiret E. Abdomino-perineal resection for anal cancer: impact of a vertical rectus abdominis myocutaneous flap on survival, recurrence, morbidity, and wound healing. *Ann Surg* 2009; **250**: 707-711 [PMID: 19801930 DOI: 10.1097/SLA.0b013e3181bce334]
- Bloemendaal AL, Kraus R, Buchs NC, Hamdy FC, Hompes R, Cogswell L, Guy RJ. Double-barrelled wet colostomy formation after pelvic exenteration for locally advanced or recurrent rectal

- cancer. *Colorectal Dis* 2016; **18**: O427-O431 [PMID: 27620339 DOI: 10.1111/codi.13512]
- 22 **Shibata D**, Hyland W, Busse P, Kim HK, Sentovich SM, Steele G, Bleday R. Immediate reconstruction of the perineal wound with gracilis muscle flaps following abdominoperineal resection and intraoperative radiation therapy for recurrent carcinoma of the rectum. *Ann Surg Oncol* 1999; **6**: 33-37 [PMID: 10030413 DOI: 10.1007/s10434-999-0033-4]
 - 23 **Singh B**, Lloyd G, Nilsson PJ, Chaudhri S. Laparoscopic extralevator abdominal perineal excision of the rectum: the best of both worlds. *Tech Coloproctol* 2012; **16**: 73-75 [PMID: 22170251 DOI: 10.1007/s10151-011-0797-y]
 - 24 **Christensen HK**, Nerstrøm P, Tei T, Laurberg S. Perineal repair after extralevator abdominoperineal excision for low rectal cancer. *Dis Colon Rectum* 2011; **54**: 711-717 [PMID: 21552056 DOI: 10.1007/DCR.0b013e3182163e89]
 - 25 **Cavallaro A**, Lo Menzo E, Di Vita M, Zanghi A, Cavallaro V, Veroux PF, Cappellani A. Use of biological meshes for abdominal wall reconstruction in highly contaminated fields. *World J Gastroenterol* 2010; **16**: 1928-1933 [PMID: 20397274]
 - 26 **Poussier M**, Denève E, Blanc P, Boulay E, Bertrand M, Nedelcu M, Herrero A, Fabre JM, Nocca D. A review of available prosthetic material for abdominal wall repair. *J Visc Surg* 2013; **150**: 52-59 [PMID: 23137644 DOI: 10.1016/j.jvisurg.2012.10.002]
 - 27 **Han JG**, Wang ZJ, Wei GH, Gao ZG, Yang Y, Zhao BC. Randomized clinical trial of conventional versus cylindrical abdominoperineal resection for locally advanced lower rectal cancer. *Am J Surg* 2012; **204**: 274-282 [PMID: 22920402 DOI: 10.1016/j.amjsurg.2012.05.001]
 - 28 **Han JG**, Wang ZJ, Gao ZG, Xu HM, Yang ZH, Jin ML. Pelvic floor reconstruction using human acellular dermal matrix after cylindrical abdominoperineal resection. *Dis Colon Rectum* 2010; **53**: 219-223 [PMID: 20087098 DOI: 10.1007/DCR.0b013e3181b715b5]
 - 29 **Musters GD**, Klaver CE, Bosker RJ, Burger JW, van Duijvendijk P, van Etten B, van Geloven AA, de Graaf EJ, Hoff C, Leijtens JW, Rutten HJ, Singh B, Vuylsteke RJ, de Wilt JH, Dijkgraaf MG, Bemelman WA, Tanis PJ. Biological Mesh Closure of the Pelvic Floor After Extralevator Abdominoperineal Resection for Rectal Cancer: A Multicenter Randomized Controlled Trial (the BIOPEX-study). *Ann Surg* 2017; **265**: 1074-1081 [PMID: 27768621 DOI: 10.1097/SLA.0000000000002020]
 - 30 **Jensen KK**, Rashid L, Pilsgaard B, Møller P, Wille-Jørgensen P. Pelvic floor reconstruction with a biological mesh after extralevator abdominoperineal excision leads to few perineal hernias and acceptable wound complication rates with minor movement limitations: single-centre experience including clinical examination and interview. *Colorectal Dis* 2014; **16**: 192-197 [PMID: 24251666 DOI: 10.1111/codi.12492]
 - 31 **Peacock O**, Simpson JA, Tou SI, Hurst NG, Speake WJ, Tierney GM, Lund JN. Outcomes after biological mesh reconstruction of the pelvic floor following extra-levator abdominoperineal excision of rectum (APER). *Tech Coloproctol* 2014; **18**: 571-577 [PMID: 24435472 DOI: 10.1007/s10151-013-1107-7]
 - 32 **Peacock O**, Pandya H, Sharp T, Hurst NG, Speake WJ, Tierney GM, Lund JN. Biological mesh reconstruction of perineal wounds following enhanced abdominoperineal excision of rectum (APER). *Int J Colorectal Dis* 2012; **27**: 475-482 [PMID: 22006494 DOI: 10.1007/s00384-011-1325-2]
 - 33 **FitzGerald JF**, Kumar AS. Biologic versus Synthetic Mesh Reinforcement: What are the Pros and Cons? *Clin Colon Rectal Surg* 2014; **27**: 140-148 [PMID: 26106284 DOI: 10.1055/s-0034-1394155]
 - 34 **Melich G**, Lim DR, Hur H, Min BS, Baik SH, Arena GO, Gordon PH, Kim NK. Prevention of perineal hernia after laparoscopic and robotic abdominoperineal resection: review with illustrative case series of internal hernia through pelvic mesh. *Can J Surg* 2016; **59**: 54-58 [PMID: 26812410 DOI: 10.1503/cjs.003115]
 - 35 **Asplund D**, Prytz M, Bock D, Haglund E, Angenete E. Persistent perineal morbidity is common following abdominoperineal excision for rectal cancer. *Int J Colorectal Dis* 2015; **30**: 1563-1570 [PMID: 26245948 DOI: 10.1007/s00384-015-2328-1]
 - 36 **Welsch T**, Mategakis V, Contini P, Kulu Y, Büchler MW, Ulrich A. Results of extralevator abdominoperineal resection for low rectal cancer including quality of life and long-term wound complications. *Int J Colorectal Dis* 2013; **28**: 503-510 [PMID: 23178992 DOI: 10.1007/s00384-012-1611-7]
 - 37 **Rothenberger DA**, Wong WD. Abdominoperineal resection for adenocarcinoma of the low rectum. *World J Surg* 1992; **16**: 478-485 [PMID: 1589984]
 - 38 **Wydra D**, Emerich J, Sawicki S, Ciach K, Marciniak A. Major complications following exenteration in cases of pelvic malignancy: a 10-year experience. *World J Gastroenterol* 2006; **12**: 1115-1119 [PMID: 16534855 DOI: 10.3748/wjg.v12.i7.1115]
 - 39 **Musters GD**, Sloothaak DA, Roodbeen S, van Geloven AA, Bemelman WA, Tanis PJ. Perineal wound healing after abdominoperineal resection for rectal cancer: a two-centre experience in the era of intensified oncological treatment. *Int J Colorectal Dis* 2014; **29**: 1151-1157 [PMID: 25064389 DOI: 10.1007/s00384-014-1967-y]
 - 40 **Martijnse IS**, Holman F, Nieuwenhuijzen GA, Rutten HJ, Nienhuijs SW. Perineal hernia repair after abdominoperineal rectal excision. *Dis Colon Rectum* 2012; **55**: 90-95 [PMID: 22156873 DOI: 10.1097/DCR.0b013e3182334121]
 - 41 **Mjoli M**, Sloothaak DA, Buskens CJ, Bemelman WA, Tanis PJ. Perineal hernia repair after abdominoperineal resection: a pooled analysis. *Colorectal Dis* 2012; **14**: e400-e406 [PMID: 22308975 DOI: 10.1111/j.1463-1318.2012.02970.x]
 - 42 **Aboian E**, Winter DC, Metcalf DR, Wolff BG. Perineal hernia after proctectomy: prevalence, risks, and management. *Dis Colon Rectum* 2006; **49**: 1564-1568 [PMID: 16946992 DOI: 10.1007/s10350-006-0669-0]
 - 43 **Pascual G**, Sotomayor S, Pérez-López P, Buján J, Bellón JM. Long term behavior of biological prostheses used as abdominal wall substitutes. *Histol Histopathol* 2014; **29**: 139-149 [PMID: 23868096 DOI: 10.14670/HH-29.139]

P- Reviewer: Niu ZS, Tomizawa M S- Editor: Ji FF L- Editor: A
E- Editor: Lu YJ





Published by **Baishideng Publishing Group Inc**
7901 Stoneridge Drive, Suite 501, Pleasanton, CA 94588, USA
Telephone: +1-925-223-8242
Fax: +1-925-223-8243
E-mail: bpgoffice@wjgnet.com
Help Desk: <http://www.f6publishing.com/helpdesk>
<http://www.wjgnet.com>

