


# World Journal of *Gastrointestinal Endoscopy*

*World J Gastrointest Endosc* 2017 August 16; 9(8): 346-427



### REVIEW

- 346 Terahertz endoscopic imaging for colorectal cancer detection: Current status and future perspectives  
*Doradla P, Joseph C, Giles RH*

### MINIREVIEWS

- 359 Use and barriers to chromoendoscopy for dysplasia surveillance in inflammatory bowel disease  
*Shukla R, Salem M, Hou JK*
- 368 Evolution of stereoscopic imaging in surgery and recent advances  
*Schwab K, Smith R, Brown V, Whyte M, Jourdan I*
- 378 Endoscopic ultrasonography - emerging applications in hepatology  
*Magalhães J, Monteiro S, Xavier S, Leite S, de Castro FD, Cotter J*

### ORIGINAL ARTICLE

#### Retrospective Cohort Study

- 389 Clinical impact of confocal laser endomicroscopy in the management of gastrointestinal lesions with an uncertain diagnosis  
*Robles-Medrand C, Vargas M, Ospina J, Puga-Tejada M, Valero M, Soria M, Bravo G, Robles-Jara C, Lukashok HP*
- 396 Impact of laparoscopic liver resection on bleeding complications in patients receiving antithrombotics  
*Fujikawa T, Kawamoto H, Kawamura Y, Emoto N, Sakamoto Y, Tanaka A*

#### Retrospective Study

- 405 Correlation of abnormal histology with endoscopic findings among mycophenolate mofetil treated patients  
*Izower MA, Rahman M, Molmenti EP, Bhaskaran MC, Amin VG, Khan S, Sultan K*
- 411 Usefulness of the Hook knife in flexible endoscopic myotomy for Zenker's diverticulum  
*Rouquette O, Abergel A, Mulliez A, Poincloux L*

### CASE REPORT

- 417 Russell body gastritis with Dutcher bodies evaluated using magnification endoscopy  
*Yorita K, Iwasaki T, Uchita K, Kuroda N, Kojima K, Iwamura S, Tsutsumi Y, Ohno A, Kataoka H*
- 425 Simultaneous Courvoisier's and double duct signs  
*Agrawal S, Vohra S*

## Contents

*World Journal of Gastrointestinal Endoscopy*  
Volume 9 Number 8 August 16, 2017

### ABOUT COVER

Editorial Board Member of *World Journal of Gastrointestinal Endoscopy*, Jorg G Albert, MD, PhD, Associate Professor, Department of Internal Medicine I, Johann Wolfgang Goethe-University Hospital, D-60590 Frankfurt, Germany

### AIM AND SCOPE

*World Journal of Gastrointestinal Endoscopy* (*World J Gastrointest Endosc*, *WJGE*, online ISSN 1948-5190, DOI: 10.4253) is a peer-reviewed open access (OA) academic journal that aims to guide clinical practice and improve diagnostic and therapeutic skills of clinicians.

*WJGE* covers topics concerning gastroscopy, intestinal endoscopy, colonoscopy, capsule endoscopy, laparoscopy, interventional diagnosis and therapy, as well as advances in technology. Emphasis is placed on the clinical practice of treating gastrointestinal diseases with or under endoscopy.

We encourage authors to submit their manuscripts to *WJGE*. We will give priority to manuscripts that are supported by major national and international foundations and those that are of great clinical significance.

### INDEXING/ABSTRACTING

*World Journal of Gastrointestinal Endoscopy* is now indexed in Emerging Sources Citation Index (Web of Science), PubMed, and PubMed Central.

### FLYLEAF

#### I-III Editorial Board

### EDITORS FOR THIS ISSUE

Responsible Assistant Editor: *Xiang Li*  
Responsible Electronic Editor: *Ya-Jing Lu*  
Proofing Editor-in-Chief: *Lian-Sheng Ma*

Responsible Science Editor: *Fang-Fang Ji*  
Proofing Editorial Office Director: *Jin-Lai Wang*

NAME OF JOURNAL  
*World Journal of Gastrointestinal Endoscopy*

ISSN  
ISSN 1948-5190 (online)

LAUNCH DATE  
October 15, 2009

FREQUENCY  
Monthly

EDITORS-IN-CHIEF  
**Atsushi Imagawa, PhD, Director, Doctor**, Department of Gastroenterology, Mitoyo General Hospital, Kan-onji, Kagawa 769-1695, Japan

**Juan Manuel Herrerias Gutierrez, PhD, Academic Fellow, Chief Doctor, Professor**, Unidad de Gestión Clínica de Aparato Digestivo, Hospital Universitario Virgen Macarena, Sevilla 41009, Spain

EDITORIAL BOARD MEMBERS  
All editorial board members resources online at <http://www.wjnet.com>

[www.wjnet.com/1948-5190/editorialboard.htm](http://www.wjnet.com/1948-5190/editorialboard.htm)

EDITORIAL OFFICE  
Xiu-Xia Song, Director  
*World Journal of Gastrointestinal Endoscopy*  
Baishideng Publishing Group Inc  
7901 Stoneridge Drive, Suite 501, Pleasanton, CA 94588, USA  
Telephone: +1-925-2238242  
Fax: +1-925-2238243  
E-mail: [editorialoffice@wjnet.com](mailto:editorialoffice@wjnet.com)  
Help Desk: <http://www.fj6publishing.com/helpdesk>  
<http://www.wjnet.com>

PUBLISHER  
Baishideng Publishing Group Inc  
7901 Stoneridge Drive, Suite 501, Pleasanton, CA 94588, USA  
Telephone: +1-925-2238242  
Fax: +1-925-2238243  
E-mail: [bpgoffice@wjnet.com](mailto:bpgoffice@wjnet.com)  
Help Desk: <http://www.fj6publishing.com/helpdesk>  
<http://www.wjnet.com>

PUBLICATION DATE  
August 16, 2017

COPYRIGHT  
© 2017 Baishideng Publishing Group Inc. Articles published by this Open-Access journal are distributed under the terms of the Creative Commons Attribution Non-commercial License, which permits use, distribution, and reproduction in any medium, provided the original work is properly cited, the use is non commercial and is otherwise in compliance with the license.

SPECIAL STATEMENT  
All articles published in journals owned by the Baishideng Publishing Group (BPG) represent the views and opinions of their authors, and not the views, opinions or policies of the BPG, except where otherwise explicitly indicated.

INSTRUCTIONS TO AUTHORS  
<http://www.wjnet.com/bpg/gerinfo/204>

ONLINE SUBMISSION  
<http://www.fj6publishing.com>

Retrospective Cohort Study

# Clinical impact of confocal laser endomicroscopy in the management of gastrointestinal lesions with an uncertain diagnosis

Carlos Robles-Medranda, Maria Vargas, Jesenia Ospina, Miguel Puga-Tejada, Manuel Valero, Miguel Soria, Gladys Bravo, Carlos Robles-Jara, Hannah Pitanga Lukashok

Carlos Robles-Medranda, Maria Vargas, Jesenia Ospina, Miguel Puga-Tejada, Manuel Valero, Miguel Soria, Gladys Bravo, Carlos Robles-Jara, Hannah Pitanga Lukashok, Gastroenterology and Endoscopy Division, Instituto Ecuatoriano de Enfermedades Digestivas, University Hospital OMNI, Guayaquil 090505, Ecuador

**Author contributions:** Robles-Medranda C and Vargas M wrote the paper; Bravo G collected data; Ospina J, Puga-Tejada M, Soria M and Robles-Jara C collected and analyzed the data; Valero M analyzed the data; Robles-Medranda C and Lukashok HP designed the study, analyzed the data, revised the manuscript for important intellectual content and provided final approval the version of the article to be published.

**Institutional review board statement:** This study was approved by the Ecuadorian Institute of Digestive Disease Institutional Review Board.

**Informed consent statement:** Informed written consent was obtained from all study participants or their legal guardians prior to study enrollment.

**Conflict-of-interest statement:** The authors have no conflict of interests.

**Data sharing statement:** No additional unpublished data are available.

**Open-Access:** This article is an open-access article which was selected by an in-house editor and fully peer-reviewed by external reviewers. It is distributed in accordance with the Creative Commons Attribution Non Commercial (CC BY-NC 4.0) license, which permits others to distribute, remix, adapt, build upon this work non-commercially, and license their derivative works on different terms, provided the original work is properly cited and the use is non-commercial. See: <http://creativecommons.org/licenses/by-nc/4.0/>

**Manuscript source:** Invited manuscript

**Correspondence to:** Carlos Robles-Medranda, MD, Head of the

Endoscopy Division, Gastroenterology and Endoscopy Division, Instituto Ecuatoriano de Enfermedades Digestivas, University Hospital OMNI, Av. Abel Romeo Castillo y Av. Juan Tanca Marengo, Torre Vitalis, Mezanine 3, Guayaquil 090505, Ecuador. [carlosoakm@ieced.com.ec](mailto:carlosoakm@ieced.com.ec)  
Telephone: +593-4-2109180  
Fax: +593-4-2109180

**Received:** February 27, 2017

**Peer-review started:** February 28, 2017

**First decision:** March 28, 2017

**Revised:** April 10, 2017

**Accepted:** May 3, 2017

**Article in press:** May 5, 2017

**Published online:** August 16, 2017

## Abstract

### AIM

To evaluate the clinical impact of confocal laser endomicroscopy (CLE) in the diagnosis and management of patients with an uncertain diagnosis.

### METHODS

A retrospective chart review was performed. Patients who underwent CLE between November 2013 and October 2015 and exhibited a poor correlation between endoscopic and histological findings were included. Baseline characteristics, indications, previous diagnostic studies, findings at the time of CLE, clinical management and histological results were analyzed. Interventions based on CLE findings were also analyzed. We compared the diagnostic accuracy of CLE and target biopsies of surgical specimens.

### RESULTS

A total of 144 patients were included. Of these, 51% (74/144) were female. The mean age was 51 years old.



In all, 41/144 (28.4%) lesions were neoplastic (13 bile duct, 10 gastric, 8 esophageal, 6 colonic, 1 duodenal, 1 rectal, 1 ampulloma and 1 pancreatic). The sensitivity, specificity, positive predictive value, negative predictive value, and observed agreement when CLE was used to detect N-lesions were 85.37%, 87.38%, 72.92%, 93.75% and 86.81%, respectively. Cohen's Kappa was 69.20%, thus indicating good agreement. Changes in management were observed in 54% of the cases.

### CONCLUSION

CLE is a new diagnostic tool that has a significant clinical impact on the diagnosis and treatment of patients with uncertain diagnosis.

**Key words:** Confocal laser endomicroscopy; *In vivo* microscopy; Barret esophagus; Gastrointestinal cancer; Pancreatic cyst; Biliary strictures

© The Author(s) 2017. Published by Baishideng Publishing Group Inc. All rights reserved.

**Core tip:** Endoscopic and histopathological findings are not always certain, thus potentially leading to inaccurate diagnoses and inappropriate therapeutics. The use of confocal laser endomicroscopy has a significant clinical impact on the diagnosis and treatment of patients with uncertain diagnoses.

Robles-Medranda C, Vargas M, Ospina J, Puga-Tejada M, Valero M, Soria M, Bravo G, Robles-Jara C, Lukashok HP. Clinical impact of confocal laser endomicroscopy in the management of gastrointestinal lesions with an uncertain diagnosis. *World J Gastrointest Endosc* 2017; 9(8): 389-395 Available from: URL: <http://www.wjgnet.com/1948-5190/full/v9/i8/389.htm> DOI: <http://dx.doi.org/10.4253/wjge.v9.i8.389>

## INTRODUCTION

Conventional histology is the gold standard procedure in evaluating lesions in the gastrointestinal tract. However, endoscopic and histological findings are sometimes poorly correlated, thus hindering accurate diagnosis and subsequent clinical management<sup>[1-5]</sup>. The probability of sampling error has been found to be 20%-30% and is affected by several factors, such as inadequate macroscopic interpretation and minimal biopsy acquisition<sup>[6]</sup>.

Confocal laser endomicroscopy (CLE) is a technique that is used *in vivo* during endoscopy to evaluate the mucosal epithelium of the gastrointestinal tract, the bile duct and pancreatic cysts<sup>[5,7]</sup>. Furthermore, it provides dynamic information including blood flow and contrast up-take<sup>[8]</sup>.

Multiple studies have shown that CLE has a diagnostic accuracy above 90% when standardized parameters are used to evaluate specific lesion features<sup>[9-17]</sup>. However, there is minimal information in the literature regarding

the influence of CLE on the evaluation and management of patients with GI lesions of uncertain diagnosis. The aim of this study was to evaluate the clinical impact of CLE in this group of patients.

## MATERIALS AND METHODS

### Study design

This study was an observational, analytical, retrospective, cross-sectional single-center study. Prospective data from November 2013 to September 2015 were collected at the Ecuadorian Institute of Digestive Diseases (IECED) Omni Hospital Academic Tertiary Care Center, Guayaquil, Ecuador. The study protocol was approved by the Institutional Ethical and Review Board and conducted according to the guidelines in the declaration of Helsinki.

Demographic data, indications, previous diagnostic findings, CLE findings, clinical management and histological results are described. Records from previous endoscopies [*i.e.*, upper endoscopy (UE), colonoscopy with high definition magnification and digital chromoendoscopy, endoscopic retrograde cholangiopancreatography (ERCP) with brushing sample and endoscopic ultrasound (EUS)], computed tomography (CT), magnetic resonance imaging (MRI) cholangiopancreatography and tests for tumor markers were analyzed.

### Population selection

**Inclusion criteria:** Patients who underwent CLE (Cellvizio®, Mauna Kea Technology, France) as a result of an uncertain diagnosis (an absence of correlation between endoscopic and histological findings) in gastrointestinal diseases, including neoplastic (N) or non-neoplastic (NN) lesions (Table 1). Patients ≥ 18 years old; Patients who agreed to participate; Patients with no previous p-CLE.

**Exclusion criteria:** Pregnant patients and patients with allergies and/or contraindication to fluorescein.

### Endoscopy and CLE procedures

All participants underwent CLE according to the standard protocol. Sedation was accomplished with propofol in UE and colonoscopy and general anesthesia in ERCP and EUS. In UE and colonoscopy, the CLE was performed with Gastroflex® and Coloflex® probes (Cellvizio®, Mauna Kea Technology, France) through the working channel of a standard video-endoscope. In ERCP procedures, CLE was performed through cholangioscopy (SpyGlass® system, Boston Scientific®), and in EUS, CLE was performed through a 19G needle (Expect® needle, Boston Scientific) with Cholangioflex® and AQ-flex® probes (Cellvizio®, Mauna Kea Technology, France).

After the GI mucosa was inspected, the areas with suspected pathology were further examined. The probe was carefully advanced to the mucosa, and *in vivo* microscopy images were scanned at 1000 ×

**Table 1** Baseline characteristics *n* (%)

	Biopsy/surgical specimen diagnosis			<i>P</i> value
	Total ( <i>n</i> = 144)	Neoplastic lesions ( <i>n</i> = 41)	Non-neoplastic lesions ( <i>n</i> = 103)	
Sex (female)	74 (51.4)	19 (46.3)	55 (53.4)	0.445
Age, yr, mean ± SD	51.33 ± 16.5	56.73 ± 17.1	49.19 ± 15.8	0.014
Initial endoscopy indication				< 0.001
Suspected tumor	70 (48.6)	32 (78.0)	38 (36.9)	
Other	74 (51.4)	9 (22.0)	65 (63.1)	
Location				0.187
Vater ampulla	2 (1.4)	1 (2.4)	1 (1.0)	
Colon	14 (9.7)	6 (14.6)	8 (7.8)	
Duodenum	4 (2.8)	1 (2.4)	3 (2.9)	
Esophagus	24 (16.7)	8 (19.5)	16 (15.5)	
Stomach	59 (41.0)	10 (24.4)	49 (47.6)	
Ileum	1 (0.7)	0 (0.0)	1 (1.0)	
Pancreas	8 (5.6)	1 (2.4)	7 (6.8)	
Rectum	3 (2.1)	1 (2.4)	2 (1.9)	
Bile duct	29 (20.1)	13 (31.7)	16 (15.5)	

SD: Standard deviation.

magnification by using CLE. These video images were transmitted in a real-time onto a screen situated next to the endoscopy monitor. For tissue contrast, 5 mL of 10% fluorescein was injected in all patients.

All lesions were analyzed in real-time after an endoscopic assessment. Micrographs and videos obtained during CLE were stored for further examination. The images were interpreted according to methods previously published in esophageal<sup>[18,19]</sup>, gastric<sup>[14,20,21]</sup> and colonic<sup>[22-24]</sup> lesions. The Miami<sup>[25,26]</sup>, Paris<sup>[13]</sup>, and CONTACT<sup>[11]</sup> study criteria for using CLE were used in bilio-pancreatic tract and cystic pancreatic lesions.

### Definitions

An uncertain diagnosis in a case of gastrointestinal lesions was defined as a lack of correlation between a histological report and findings on initial endoscopy (*e.g.*, UE, colonoscopy, ERCP, EUS). Neoplastic (N) lesions included dysplasia, adenomas and carcinomas that were located at any level of the GI tract, pancreas or biliary duct. Any other lesion was defined as a non-neoplastic (NN) lesion (Figures 1 and 2).

We defined a "change in management" resulting from CLE in cases of uncertain diagnosis when the results of CLE changed the management strategy that was initially based on the original biopsy or when no further diagnostic methods were used.

### Statistical analysis

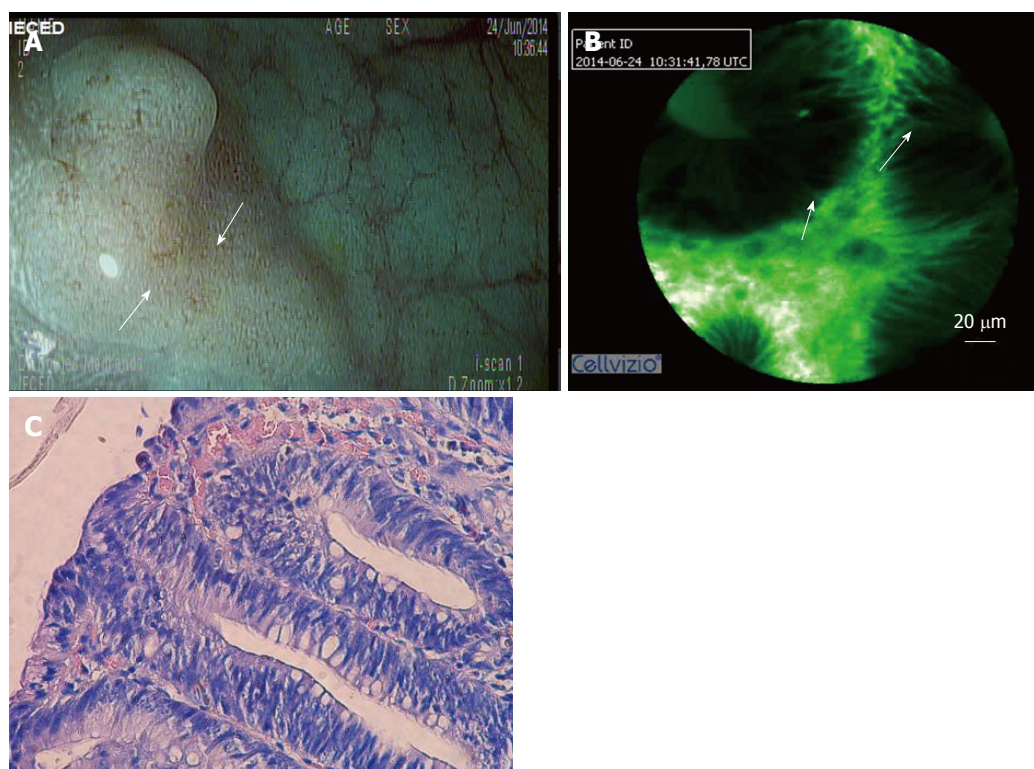
Baseline characteristics, including demographic data, indications, CLE findings, histological results and changes in management, were described as percentages and ranges or means and standard deviations, as appropriate. The overall diagnostic accuracy of CLE in an N-lesion was determined by comparing the CLE findings to the final post-CLE histopathological report (*e.g.*, biopsy or surgical specimen). The following measurements were used for this purpose: Sensitivity, specificity, positive predictive value (PPV), negative

predictive value (NPV), simple percentage agreement (observed agreement) and inter-rater agreement (Cohen's Kappa). Cohen's Kappa was interpreted by using Landis and Koch-Kappa's Benchmark Scale. Changes in management and redirected biopsy samples were described as percentages. The characteristics of N-lesions and NN-lesions groups were compared using Student's *t*-test for continuing variables and  $\chi^2$  and Fisher's test for categorical variables. A *P* value < 0.05 was considered to be statistically significant. The statistical methodology used in this study was reviewed by the IECED institutional Biostatistician. Statistical calculations were performed in SPSS software suite v.22.

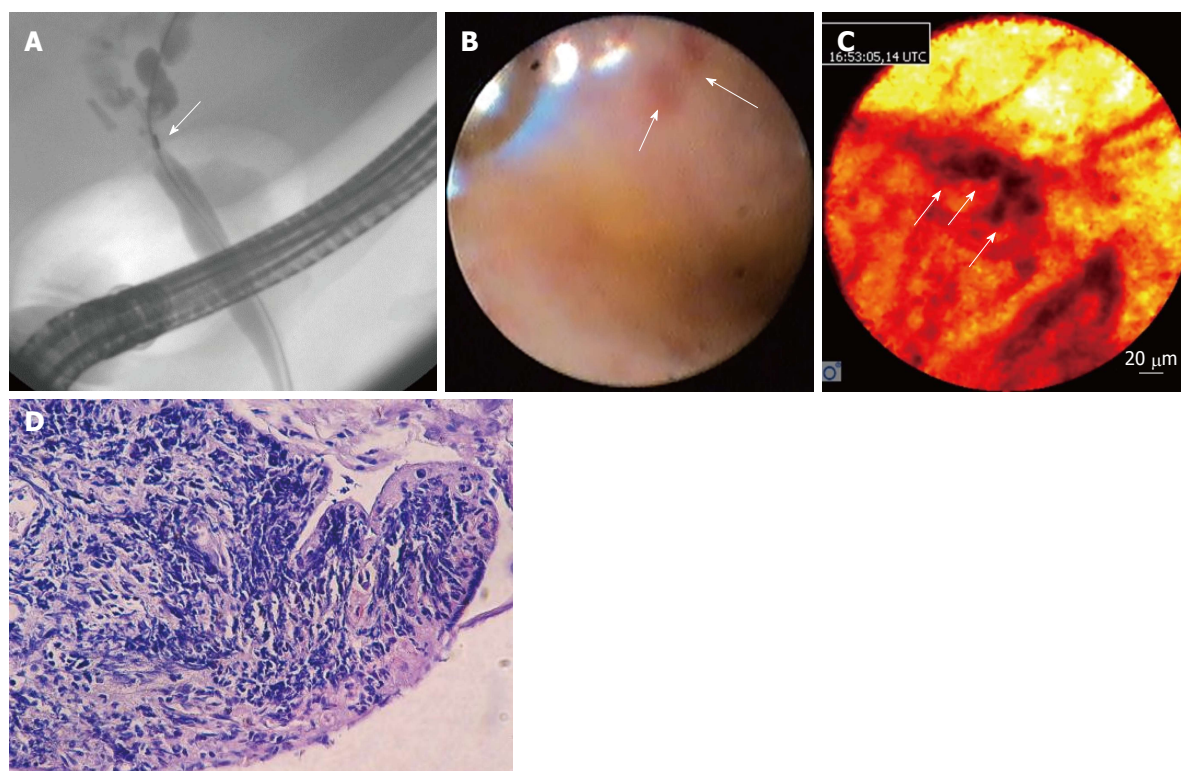
### RESULTS

A total of 144 patients were included. The mean age of the patients was 51.33 years old (range 18-86), and 51.4% (74/144) were female. There were 41/144 N-lesions, including 13 bile duct, 10 gastric, 8 esophageal, 6 colonic, 1 duodenal, 1 rectal, 1 ampulloma and 1 pancreatic lesion (Table 1). The findings included Barrett's esophagus with or without dysplasia, adenocarcinomas and mucosal inflammation in different segments of the digestive tract, gastric metaplasia and dysplasia, carcinoid tumors, ampulloma, mucinous and serous pancreatic cysts, pseudocysts, adenoma and adenocarcinoma of the biliary tract and inflammation related to parasites.

The sensitivity, specificity, PPV and NPV for detecting N-lesions between CLE and target biopsies or surgical specimens were 85.37%, 87.38%, 72.92% and 93.75%, respectively. The observed agreement was 86.81%, and Cohen's Kappa value was 69.20%, thus indicating good agreement (Table 2). Changes in management were noted in 78/144 (54.2) cases (Table 3). These changes resulted from the improved ability of CLE to acquire targeted biopsies, which avoided the need for further diagnostic methods.



**Figure 1 Colonic polyp.** A: A sigmoid flat polyp was viewed using digital chromoendoscopy with high definition by i-scan, which revealed a pit pattern suggestive of a hyperplastic lesion in a patient with cirrhosis and important coagulation disorders; B: CLE showing dysplasia (image optimized by using a green-white image color palette in Cellvizio® viewer software); C: A histological analysis of the specimen confirmed the dysplasia. CLE: Confocal laser endomicroscopy.



**Figure 2 Undetermined stenosis of the biliary tract.** A: ERCP was performed in a patient with undetermined stenosis who was cytobrush-negative for malignancy; B: Spyglass cholangioscopy showing a reddish area that was not suspected of malignancy; C: CLE showing dark clumps that were suspected of malignancy (image optimized using the "black-red-yellow" image color palette in Cellvizio® viewer software); D: The histological results of a target biopsy confirmed a diagnosis of cholangiocarcinoma. CLE: Confocal laser endomicroscopy; ERCP: Endoscopic retrograde cholangiopancreatography.



**Table 2** Confocal laser endomicroscopy overall diagnostic accuracy with either confocal laser endomicroscopy target biopsy or surgical specimens as the Gold Standard *n* (%)

	Biopsy/surgical specimen diagnosis			<i>P</i> value
	Total ( <i>n</i> = 144)	Neoplastic lesions ( <i>n</i> = 41)	Non-neoplastic lesions ( <i>n</i> = 103)	
CLE diagnosis				< 0.001
Neoplastic lesion	48 (33.3)	35 (85.4)	13 (12.6)	
Non-Neoplastic lesion	96 (66.7)	6 (14.6)	90 (87.4)	
CLE overall diagnostic accuracy				
Sensitivity, <i>n</i> /T (%; 95%CI)		35/41	(85.37; 70.83-94.43)	
Specificity, <i>n</i> /T (%; 95%CI)		90/103	(87.38; 79.38-93.11)	
PPV, <i>n</i> /T (%; 95%CI)		35/48	(72.92; 61.46-81.97)	
NPV, <i>n</i> /T (%; 95%CI)		90/96	(93.75; 87.71-96.93)	
Observed agreement, <i>n</i> /T (%)		125/144	-86.81	
Cohen's Kappa, % (95%CI)		69.2	(56.50-81.90)	

PPV: Positive predictive value; NPV: Negative predictive value; CI: Confidence interval; CLE: Confocal laser endomicroscopy.

**Table 3** Patients with changes in management following biopsy/surgical specimen diagnosis, listed according to organ *n* (%)

	Biopsy/surgical specimen diagnosis			<i>P</i> value
	Total ( <i>n</i> = 78)	Neoplastic lesions ( <i>n</i> = 30)	Non-neoplastic lesions ( <i>n</i> = 48)	
Location				0.707
Vater ampulla	1 (1.3)	1 (3.3)	0	
Colon	9 (11.5)	4 (13.3)	5 (10.4)	
Duodenum	4 (5.1)	1 (3.3)	3 (6.3)	
Esophagus	10 (12.8)	5 (16.7)	5 (10.4)	
Stomach	17 (21.8)	5 (16.7)	12 (25)	
Ileum	1 (1.3)	0	1 (2.1)	
Pancreas	6 (7.7)	1 (3.3)	5 (10.4)	
Rectum	3 (3.8)	1 (3.3)	2 (4.2)	
Bile duct	27 (34.6)	12 (40)	15 (31.3)	

## DISCUSSION

CLE is an imaging method that has demonstrated substantial benefit for diagnosing GI tract, bile duct and pancreatic lesions. Several previous reports have supported CLE's efficacy by showing CLE and histological findings are well correlated<sup>[15-17]</sup>. Recent studies<sup>[11,18]</sup> have demonstrated that CLE has high accuracy in differentiating benign from malignant lesions in bile duct and pancreas pathology (mean accuracy, 81%)<sup>[21]</sup>, malignant gastric lesions (94%-96%)<sup>[20]</sup> and polyps (82%)<sup>[22]</sup>. In addition, the American Society for Gastrointestinal Endoscopy has reported that CLE has at least 90% sensitivity and 98% NPV when it is used to detect Barrett's esophagus-associated dysplasia<sup>[18]</sup>. The Miami classification criteria for bile duct lesions have been demonstrated to have a higher accuracy when they are used to diagnose malignant strictures rather than biopsy samples (81% vs 75%, respectively)<sup>[12]</sup>. However, these criteria have some limitations when they are used to differentiate inflammatory from malignant strictures, thus leading to false positives. On the basis of this finding, Caillol *et al.*<sup>[13]</sup> have developed the Paris Classification, which has increased sensitivity and specificity in characterizing indeterminate bile duct strictures<sup>[13,27]</sup>. Additionally, in colonoscopy, CLE has been demonstrated to be very useful. Neumann *et al.*<sup>[23,24]</sup> have found that CLE, when used in inflammatory

bowel disease (IBD) surveillance, is a simple technique that facilitates the accurate and early detection of related lesions.

Our study focused on the clinical impact and management changes resulting from the use of CLE to evaluate GI (upper and lower) lesions, including bile duct pathology and pancreatic cysts, in a subgroup of patients with uncertain diagnoses due to non-conclusive previous tests.

CLE was found to have a high accuracy in detecting neoplastic bilio-pancreatic lesions, which accounted for 80% of all lesions found in the bile ducts and pancreas. In 54% of such cases, the use of CLE resulted in a change in the diagnostic and therapeutic approach. However, 71% of all lesions in patients with an inconclusive diagnosis were NN benign lesions, and CLE resulted in an observed agreement, PPV and NPV of 86%, 72% and 93%, respectively. These results were similar to those reported in previous publications that have explored lesions in the upper and lower portions of the gastrointestinal tract<sup>[1,22-30]</sup>.

The main advantages of using CLE include its ability to differentiate *in vivo* lesions and guide targeted biopsies, thereby avoiding the potential complications associated with endoscopic mucosal resections (*e.g.*, perforation or bleeding). Additionally, using CLE prevents a need for further unnecessary invasive and noninvasive diagnostic methods (*e.g.*, repeated endo-



scopy, ERCP, EUS, or other imaging modalities, such as CT and MRI), thus decreasing patient risk and economic burden associated with such procedures. However, our study has limitations, including its single-center retrospective design and lack of randomization.

## Conclusion

The results of this study suggest that CLE is a valuable diagnostic tool for patients with an uncertain diagnosis (neoplastic or non-neoplastic). CLE can be used to perform real-time evaluation of the GI mucosa, thus allowing endoscopists to target biopsies and having a significant clinical impact when it is used to improve and modify diagnoses and treatment strategies.

## COMMENTS

### Background

Confocal laser endomicroscopy (CLE) is a technique that can be used *in vivo* during endoscopy to evaluate the mucosal epithelium of the gastrointestinal tract, the bile duct and pancreatic cysts.

### Research frontiers

The authors evaluated the clinical impact of CLE in patients with an uncertain diagnosis in gastrointestinal lesions.

### Innovations and breakthroughs

The observed agreement was 86.81% and had a Cohen's Kappa value of 69.20%, thus indicating good agreement. Changes in management were noted in 78/144 (54.2) cases and were associated with the improved acquisition of targeted biopsies, thus avoiding the need for further diagnostic tests.

### Applications

CLE is a new diagnostic tool that can be used in patients with uncertain diagnosis, in whom it has a significant clinical impact on diagnosis and treatment.

### Terminology

Confocal laser endomicroscopy; *in vivo* microscopy.

### Peer-review

Overall the paper is interesting and points out discrepancy between endoscopic and histopathologic findings.

## REFERENCES

- Bartels F, Hahn HJ, Stolte M, Schmidt-Wilcke HA. [Quality of diagnostic procedures and frequency of endoscopically defined diseases of the upper gastrointestinal tract]. *Z Gastroenterol* 2003; **41**: 311-318 [PMID: 12695936 DOI: 10.1055/s-2003-38645]
- Isaacs KL. Upper gastrointestinal tract endoscopy in inflammatory bowel disease. *Gastrointest Endosc Clin N Am* 2002; **12**: 451-462, vii [PMID: 12486938 DOI: 10.1016/S1052-5157(02)00006-5]
- Aydin O, Egilmez R, Karabacak T, Kanik A. Interobserver variation in histopathological assessment of *Helicobacter pylori* gastritis. *World J Gastroenterol* 2003; **9**: 2232-2235 [PMID: 14562384 DOI: 10.3748/wjg.v9.i10.2232]
- Sharma P, Hawes RH, Bansal A, Gupta N, Curvers W, Rastogi A, Singh M, Hall M, Mathur SC, Wani SB, Hoffman B, Gaddam S, Fockens P, Bergman JJ. Standard endoscopy with random biopsies versus narrow band imaging targeted biopsies in Barrett's oesophagus: a prospective, international, randomised controlled trial. *Gut* 2013; **62**: 15-21 [PMID: 22315471 DOI: 10.1136/gutjnl-2011-300962]
- Calhoun BC, Gomes F, Robert ME, Jain D. Sampling error in the standard evaluation of endoscopic colonic biopsies. *Am J Surg Pathol* 2003; **27**: 254-257 [PMID: 12548174 DOI: 10.1097/0000478-20030-00016]
- Deutsch JC. The optical biopsy of small gastric lesions. *Gastrointest Endosc* 2014; **79**: 64-65 [PMID: 24342587 DOI: 10.1016/j.gie.2013.07.035]
- Swager A, Curvers WL, Bergman JJ. Diagnosis by endoscopy and advanced imaging. *Best Pract Res Clin Gastroenterol* 2015; **29**: 97-111 [PMID: 25743459 DOI: 10.1016/j.bpg.2014.11.011]
- Wani S, Shah RJ. Probe-based confocal laser endomicroscopy for the diagnosis of indeterminate biliary strictures. *Curr Opin Gastroenterol* 2013; **29**: 319-323 [PMID: 23507916 DOI: 10.1097/MOG.0b013e32835fee9f]
- Tafreshi MK, Joshi V, Meining A, Lightdale CJ, Giovannini M, Dauguet J, Ayache N, André B. Su1662 Smart Atlas for Supporting the Interpretation of Probe-Based Confocal LASER Endomicroscopy (pCLE) of Biliary Strictures: First Classification Results of a Computer-Aided Diagnosis Software Based on Image Recognition. 2014: Digestive Disease Week (DDW 2014). *Gastrointest Endosc* 2017; **79** Supplement: AB357-AB358 [DOI: 10.1016/j.gie.2014.02.406]
- Kahaleh M, Turner BG, Bezak K, Sharaiha RZ, Sarkaria S, Lieberman M, Jamal-Kabani A, Millman JE, Sundararajan SV, Chan C, Mehta S, Widmer JL, Gaidhane M, Giovannini M. Probe-based confocal laser endomicroscopy in the pancreatic duct provides direct visualization of ductal structures and aids in clinical management. *Dig Liver Dis* 2015; **47**: 202-204 [PMID: 25499063 DOI: 10.1016/j.dld.2014.11.006]
- Napoléon B, Lemaistre AI, Pujol B, Caillol F, Lucidarme D, Bourdariat R, Morellon-Mialhe B, Fumex F, Lefort C, Lepilliez V, Palazzo L, Monges G, Filoche B, Giovannini M. A novel approach to the diagnosis of pancreatic serous cystadenoma: needle-based confocal laser endomicroscopy. *Endoscopy* 2015; **47**: 26-32 [PMID: 25325684 DOI: 10.1055/s-0034-1390693]
- Meining A, Shah RJ, Slivka A, Pleskow D, Chuttani R, Stevens PD, Becker V, Chen YK. Classification of probe-based confocal laser endomicroscopy findings in pancreaticobiliary strictures. *Endoscopy* 2012; **44**: 251-257 [PMID: 22261749 DOI: 10.1055/s-0031-1291545]
- Caillol F, Filoche B, Gaidhane M, Kahaleh M. Refined probe-based confocal laser endomicroscopy classification for biliary strictures: the Paris Classification. *Dig Dis Sci* 2013; **58**: 1784-1789 [PMID: 23314855 DOI: 10.1007/s10620-012-2533-5]
- Zhang JN, Li YQ, Zhao YA, Yu T, Zhang JP, Guo YT, Liu H. Classification of gastric pit patterns by confocal endomicroscopy. *Gastrointest Endosc* 2008; **67**: 843-853 [PMID: 18440377 DOI: 10.1016/j.gie.2008.01.036]
- Goetz M, Kiesslich R. Confocal endomicroscopy: in vivo diagnosis of neoplastic lesions of the gastrointestinal tract. *Anticancer Res* 2008; **28**: 353-360 [PMID: 18383869]
- Kiesslich R, Goetz M, Lammersdorf K, Schneider C, Burg J, Stolte M, Vieth M, Nafe B, Galle PR, Neurath MF. Chromoscopy-guided endomicroscopy increases the diagnostic yield of intraepithelial neoplasia in ulcerative colitis. *Gastroenterology* 2007; **132**: 874-882 [PMID: 17383417 DOI: 10.1053/j.gastro.2007.01.048]
- Sorokina A, Danilevskaya O, Averyanov A, Zabozaev F, Sazonov D, Yarmus L, Lee HJ. Comparative study of ex vivo probe-based confocal laser endomicroscopy and light microscopy in lung cancer diagnostics. *Respirology* 2014; **19**: 907-913 [PMID: 24909555 DOI: 10.1111/resp.12326]
- Sharma P, Savides TJ, Canto MI, Corley DA, Falk GW, Goldblum JR, Wang KK, Wallace MB, Wolfsen HC; ASGE Technology and Standards of Practice Committee. The American Society for Gastrointestinal Endoscopy PIVI (Preservation and Incorporation of Valuable Endoscopic Innovations) on imaging in Barrett's Esophagus. *Gastrointest Endosc* 2012; **76**: 252-254 [PMID: 22817781 DOI: 10.1016/j.gie.2012.05.007]
- Gaddam S, Mathur SC, Singh M, Arora J, Wani SB, Gupta N, Overhiser A, Rastogi A, Singh V, Desai N, Hall SB, Bansal A, Sharma P. Novel probe-based confocal laser endomicroscopy criteria and interobserver

- agreement for the detection of dysplasia in Barrett's esophagus. *Am J Gastroenterol* 2011; **106**: 1961-1969 [PMID: 21946283 DOI: 10.1038/ajg.2011.294]
- 20 **Kitabatake S**, Niwa Y, Miyahara R, Ohashi A, Matsuura T, Iguchi Y, Shimoyama Y, Nagasaka T, Maeda O, Ando T, Ohmiya N, Itoh A, Hirooka Y, Goto H. Confocal endomicroscopy for the diagnosis of gastric cancer in vivo. *Endoscopy* 2006; **38**: 1110-1114 [PMID: 17111332 DOI: 10.1055/s-2006-944855]
  - 21 **Lim LG**, Yeoh KG, Srivastava S, Chan YH, Teh M, Ho KY. Comparison of probe-based confocal endomicroscopy with virtual chromoendoscopy and white-light endoscopy for diagnosis of gastric intestinal metaplasia. *Surg Endosc* 2013; **27**: 4649-4655 [PMID: 23892761 DOI: 10.1007/s00464-013-3098-x]
  - 22 **Shahid MW**, Buchner AM, Heckman MG, Krishna M, Raimondo M, Woodward T, Wallace MB. Diagnostic accuracy of probe-based confocal laser endomicroscopy and narrow band imaging for small colorectal polyps: a feasibility study. *Am J Gastroenterol* 2012; **107**: 231-239 [PMID: 22068663 DOI: 10.1038/ajg.2011.376]
  - 23 **Neumann H**, Vieth M, Günther C, Neufert C, Kiesslich R, Grauer M, Atreya R, Neurath MF. Virtual chromoendoscopy for prediction of severity and disease extent in patients with inflammatory bowel disease: a randomized controlled study. *Inflamm Bowel Dis* 2013; **19**: 1935-1942 [PMID: 23839228 DOI: 10.1097/MIB.0b013e318290550e]
  - 24 **Neumann H**, Vieth M, Atreya R, Neurath MF, Mudter J. Prospective evaluation of the learning curve of confocal laser endomicroscopy in patients with IBD. *Histol Histopathol* 2011; **26**: 867-872 [PMID: 21630216]
  - 25 **Slivka A**, Gan I, Jamidar P, Costamagna G, Cesaro P, Giovannini M, Caillol F, Kahaleh M. Validation of the diagnostic accuracy of probe-based confocal laser endomicroscopy for the characterization of indeterminate biliary strictures: results of a prospective multicenter international study. *Gastrointest Endosc* 2015; **81**: 282-290 [PMID: 25616752 DOI: 10.1016/j.gie.2014.10.009]
  - 26 **Meining A**, Chen YK, Pleskow D, Stevens P, Shah RJ, Chuttani R, Michalek J, Slivka A. Direct visualization of indeterminate pancreaticobiliary strictures with probe-based confocal laser endomicroscopy: a multicenter experience. *Gastrointest Endosc* 2011; **74**: 961-968 [PMID: 21802675 DOI: 10.1016/j.gie.2011.05.009]
  - 27 **Kahaleh M**, Giovannini M, Jamidar P, Gan SI, Cesaro P, Caillol F, Filoche B, Karia K, Smith I, Gaidhane M, Slivka A. Probe-based confocal laser endomicroscopy for indeterminate biliary strictures: refinement of the image interpretation classification. *Gastroenterol Res Pract* 2015; **2015**: 675210 [PMID: 25866506 DOI: 10.1155/2015/675210]
  - 28 **Hart R**, Classen M. Complications of diagnostic gastrointestinal endoscopy. *Endoscopy* 1990; **22**: 229-233 [PMID: 2147002 DOI: 10.1055/s-2007-1010734]
  - 29 **Green J**. Complications of gastrointestinal endoscopy. BSG Guidelines in Gastroenterology 2006; 1-30. Available from: URL: [http://www.bsg.org.uk/pdf\\_word\\_docs/complications.pdf](http://www.bsg.org.uk/pdf_word_docs/complications.pdf)
  - 30 **Warren JL**, Klabunde CN, Mariotto AB, Meekins A, Topor M, Brown ML, Ransohoff DF. Adverse events after outpatient colonoscopy in the Medicare population. *Ann Intern Med* 2009; **150**: 849-857, W152 [PMID: 19528563 DOI: 10.7326/0003-4819-150-12-200906160-00008]

**P- Reviewer:** Arcidiacono PG, Fogli L, Tarnawski AS **S- Editor:** Ji FF  
**L- Editor:** A **E- Editor:** Lu YJ





Published by **Baishideng Publishing Group Inc**  
7901 Stoneridge Drive, Suite 501, Pleasanton, CA 94588, USA  
Telephone: +1-925-223-8242  
Fax: +1-925-223-8243  
E-mail: [bpgoffice@wjgnet.com](mailto:bpgoffice@wjgnet.com)  
Help Desk: <http://www.f6publishing.com/helpdesk>  
<http://www.wjgnet.com>

