

## Trans-umbilical endoscopic cholecystectomy with a water-jet hybrid-knife: A pilot animal study

Sheng-Jun Jiang, Hong Shi, Gyanendra Swar, Hai-Xia Wang, Xiao-Jing Liu, Yong-Guang Wang

Sheng-Jun Jiang, Gyanendra Swar, Hai-Xia Wang, Xiao-Jing Liu, Yong-Guang Wang, Department of Minimally Invasive Surgery, Beijing Chuiyangliu Hospital, Beijing 100022, China

Hong Shi, Department of Gastrointestinal Endoscopy, Fujian Provincial Tumor Hospital, Teaching Hospital of Fujian Medical University, Fuzhou 350014, Fujian Province, China

Yong-Guang Wang, Institute of Minimally Invasive Medicine, Tongji University, Beijing 100022, China

Author contributions: Shi H, Jiang SJ and Wang YG proposed the study; Jiang SJ and Shi H wrote the first draft; all the authors contributed to the design and interpretation of the study and to final manuscript; Jiang SJ is the guarantor.

Correspondence to: Yong-Guang Wang, MD, PhD, Institute of Minimally Invasive Medicine, Tongji University, No.2, Chuiyangliu South Street, Chaoyang District, Beijing 100022, China. [endowang@vip.sina.com](mailto:endowang@vip.sina.com)

Telephone: +86-10-87712135 Fax: +86-10-87712135

Received: May 1, 2013 Revised: August 29, 2013

Accepted: September 3, 2013

Published online: October 28, 2013

**RESULTS:** Transumbilical endoscopic cholecystectomy was successfully completed in the first and third pig, with minor bleedings. The dissection times were 137 and 42 min, respectively. The total operation times were 167 and 69 min, respectively. And the lengths of resected specimen were 6.5 and 6.1 cm, respectively. Instillation of the fluid into the gallbladder bed produced edematous, distended tissue making separation safe and easy. Reliable ligation using double nylon loops insured the safety of cutting between the loops. There were no intraoperative complications or hemodynamic instability. Uncontrolled intraoperative bleeding occurred in the second case, leading to the operation failure.

**CONCLUSION:** Pure NOTES trans-umbilical cholecystectomy with a water-jet hybrid-knife appears to be feasible and safe. Further investigation of this technique with long-term follow-up in animals is needed to confirm the preliminary observation.

© 2013 Baishideng. All rights reserved.

### Abstract

**AIM:** To investigate the feasibility and safety of Natural orifice trans-umbilical endoscopic cholecystectomy with a water-jet hybrid-knife in a non-survival porcine model.

**METHODS:** Pure natural orifice transluminal endoscopic surgery (NOTES) cholecystectomy was performed on three non-survival pigs, by transumbilical approach, using a water-jet hybrid-knife. Under general anesthesia, the following steps detailed the procedure: (1) incision of the umbilicus followed by the passage of a double-channel flexible endoscope through an overtube into the peritoneal cavity; (2) establishment of pneumoperitoneum; (3) abdominal exploration; (4) endoscopic cholecystectomy: dissection of the gallbladder performed using water jet equipment, ligation of the cystic artery and duct conducted using nylon loops; and (5) necropsy with macroscopic evaluation.

**Key words:** Natural orifice transluminal endoscopic surgery; Cholecystectomy; Water-jet; Hybrid-knife; Triangulation

**Core tip:** Flexible single-incision surgery (FSIS), one of recent advances in endoscopic surgery, is a promising single-incision approach, which has exploited the advantages of single-incision laparoscopy and narrow sense of natural orifice transluminal endoscopic surgery (NOTES). Compared to NOTES, FSIS uses the navel to facilitate the extraction of the specimen and the umbilical closure is quick and easy. Compared to SILS, FSIS does not need any specialized device for the entry ports. Furthermore, water-jet hybrid knife technology enables a quick switch between blunt and sharp dissection. This study assessed the feasibility and safety of endoscopic cholecystectomy using transumbilical approach and water jet hybrid knife technology.

Jiang SJ, Shi H, Swar G, Wang HX, Liu XJ, Wang YG. Trans-umbilical endoscopic cholecystectomy with a water-jet hybrid-knife: A pilot animal study. *World J Gastroenterol* 2013; 19(40): 6857-6862 Available from: URL: <http://www.wjgnet.com/1007-9327/full/v19/i40/6857.htm> DOI: <http://dx.doi.org/10.3748/wjg.v19.i40.6857>

## INTRODUCTION

Laparoscopic cholecystectomy (LC)<sup>[1]</sup> remains the gold standard for the treatment of benign gallbladder diseases, showing superiority such as better cosmetic results, less postoperative pain, and shorter recovery time compared with open cholecystectomy. Under the guidance of the Holy Grail of minimal invasive surgery, namely, scarless surgery, natural orifice transluminal endoscopic surgery (NOTES) has made substantial progress. However, it is also technically difficult due to lack of appropriate devices and loss of triangulation. To achieve both minimal invasiveness and effectiveness, we proposed the following technique for pure NOTES cholecystectomy, by transumbilical approach, using an endoscopic water jet system applied to perform blunt and sharp dissection without accessory switch.

## MATERIALS AND METHODS

### Animals

Natural Orifice Trans-umbilical Cholecystectomy with a new water-jet dissector Erbejet 2 was performed on three non-survival TiBet experimental pigs (two were female weighing 30 kg, the other was male weighing 35 kg).

### Experimental site

Experimental site: Olympus training center for animal experimental study in Peking, China.

### Animal preparation and post-operative management

Animal preparation and post-operative management: fasting 48 h pre-operation and took polyethylene glycol 4 g/kg orally for intestinal preparation before procedure. Preoperative intramuscular ketamine 20 mg/kg and Xylazine 2 mg/kg mixture induced anesthesia, retaining animal on the operating table in a supine position and performing endotracheal intubation, connecting anaesthesia apparatus following inhalational anesthesia by 4%-5% isoflurane. When the animals entered into complete general anesthesia condition, regulating gas concentration to 1%-2% for anesthesia maintenance and intraoperative intravenous management with 5% glucose-saline. After the operation ended, intravenous pentobarbital sodium 100 mg/kg was injected to the porcine, along with the autopsy to observe the wound and adjacent organs for any damages.

### Instruments and devices

Instruments and devices: forward-looking double channel

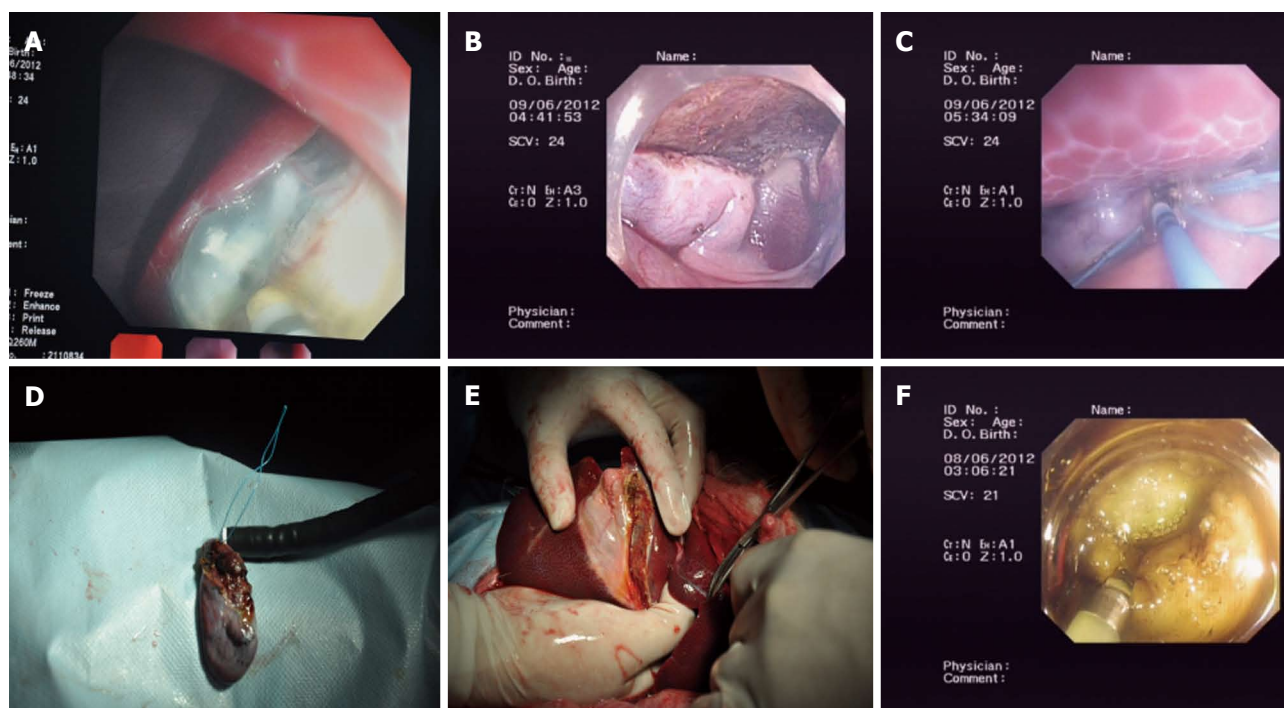
gastroscope (GIF-2TQ260M, olympus), non-invasive forceps (FQ-46L-1, olympus), thermal hemostatic forceps (endoscopic hemostatic forceps FD-410LR, olympus), nylon cord snare (MAJ-340, olympus) and ligation device (HX-20L-1, olympus), overtube (overtubeMD48618, Sumitomo Bakelite, Tokyo Japan), Trocar, co2 air pump, digestive endoscopic surgery workstation (ERBE VIO-300D, Germany), T-type Erbejet2 (ERBEjet2; ERBE Elektromedizin, Germany), endoscopic clips and trip gear (endoclips, HX-610-135OLYMPUS, olympus), methylene blue, normal saline.

### Experimental procedure

**Establishment of pneumoperitoneum:** Porcines were placed under supine position, routine preoperative skin disinfection, spread towel, making a 1.5 cm longitudinal incision through the umbilicus, puncturing into abdominal cavity with trocar then overtube was inserted. Surrounding skin was clamped by using towel clamp in order to avoid air leakage, so endoscope can be inserted into peritoneal cavity through overtube, (being unable to gear co2 air pump directly), the latter is connected to endoscopic air supply device to maintain pneumoperitoneum which can be adjusted by endoscopic inspiration button.

**Abdominal exploration:** After the establishment of pneumoperitoneum, exploration of intra-abdominal viscera from epigastrium to hypogastrium was done. Stomach, diaphragm, gallbladder, spleen, small intestine and large intestine can be viewed meanwhile retroperitoneal organs kidney, pancreas for instance cannot be explored. A swollen light blue gallbladder can be seen from endoscope due to abrasion. Sometimes gallbladder is covered by the lobes of liver that requires removing the lobes of liver to reveal cholecyst by operating endoscope.

**Cholecystectomy:** The assistant manipulated overtube to advance the endoscope to the surgery field and to reveal cholecyst and liver bed. High-pressure injection of methylene blue solution dyed normal saline by using T-type ERBEjet2 through endoscopic work channel into fibrous tissue between gallbladder and liver bed. The water-injection pressure was set to 30-50 bar. Blue cushion formation taking place following the local injection (Figure 1A), demarcates the liver parenchyma. Then the dissection of fibrous tissue was done between gallbladder's serous membrane and liver parenchyma by T-type ERBEjet2 (coagulation-cut hybrid model, power 45w, effect 2) starting from fundus or neck of gallbladder from left to right side. Every separation was done following the cushion formation and was operated in the raised or lift cushion. Once catching the sight of small blood vessels or encountering haemorrhage, prophylactic hemostasis with electrotome or hemostatic forceps would be required. The gallbladder would fall off liver bed while dissected carefully up to the neck or fundus of gallbladder (Figure 1B). Dissected clearly and completely to reveal calot's triangle and cystic duct, cystic artery, hepatic duct and common bile duct has been identified. Ligation of



**Figure 1** Picture demonstrating a concept of a novel method of cholecystectomy. A: Methylene blue mixed with normal saline solution injected into fibrous tissues between gallbladder and liver bed; B: The gallbladder falling off liver bed; C: Cystic duct and artery cut using the water-jet hybrid-knife between loops; D: The resected gallbladder grasped by forceps; E: Macroscopic view of the liver fossa on necropsy; F: Clipped gallbladder perforation.

cystic duct and cystic artery with nylon cord snare instead of endoclips for fast ligation. During the procedure, non-invasive forceps and ligation device were introduced into abdominal cavity through endoscopic double channels respectively. Cholecyst was clamped and empocketed into nylon cord snare and then ligation of the cystic duct and cystic artery together was done on the distal end of cystic duct, three snares placed in all; the proximal and distal end of cystic duct and then cut in the middle of snares (Figure 1C). Confirmed no active haemorrhage and no biliary fistula. Consequently, cholecyst retracted through overtube applying forceps or basket (Figure 1D). Ultimately, autopsy was performed to check the dissection wound and adjacent viscera for injury.

## RESULTS

Transumbilical endoscopic cholecystectomy was successfully completed in the first and third pig, with minor bleedings (Tables 1, 2). The dissection times were 137 and 42 min, respectively. The total operation times were 167 and 69 min, respectively. The time required decreased with experience. And the lengths of resected specimen were 6.5 and 6.1 cm, respectively. Instillation of the fluid into the gallbladder bed produced edematous, distended tissue making separation safe and easy. Reliable ligation using double nylon loops insured the safety of cutting between the loops. There were no intraoperative complications or hemodynamic instability. At necropsy, the loops on the cystic duct and artery were secure and that neither bile nor blood leakage was observed from this site. Both the gallbladder bed and the liver bed were dry

(Figure 1E).

During the dissection in the second pig (Tables 1 and 2), unexpected gallbladder rupture occurred, and the perforation site was quickly clipped (Figure 1) after being identified. Subsequently, uncontrolled intraoperative bleeding occurred in the second case, leading to the operation failure.

## DISCUSSION

To date, most of pure NOTES procedures are still performed only in animals<sup>[2-4]</sup> due to several technical barriers. NOTES cholecystectomy has been successfully introduced into clinical application based on preliminary animal experimental researches. Several approaches have been reported in the literatures such as transgastric, transvaginal and transcolonic route, but most finished cholecystectomy with the assistance of laparoscopic instruments in humans<sup>[5-7]</sup>. Meanwhile, pure NOTES only has several case reports<sup>[8-10]</sup>. Transvaginal approach is the most widely used in the clinical practices and is considered<sup>[5]</sup> to be the best approach for NOTES surgery. However, it only applies to females with underlying complications like dyspareunia, infertility and pelvic adhesions<sup>[11,12]</sup>. Pugliese *et al*<sup>[5]</sup> showed no above-mentioned discomfort and incision related complications. Transgastric approach was originally studied<sup>[13,14]</sup>, but rarely applied to clinical practices because of technical difficulties<sup>[13,15,16]</sup>, to overcome these difficulties, the innovation of new technology and use of new devices has been reported in several literatures<sup>[9]</sup>. Furthermore, Marescaux *et al*<sup>[16]</sup> considered this approach for NOTES surgery would be

**Table 1** Transumbilical endoscopic cholecystectomy was successfully completed in the first and third pig, with minor bleedings

Animal	Sex	Weight (kg)	Time of pneumoperitoneum (min)	Time of dissection (min)	Time of ligation and resection (min)	Total time (min)
1	Female	30	2	137	28	167
2	Male	35	2	61 (incomplete)	-	-
3	Female	33	2	42	25	69

**Table 2** Experimental indicators in transumbilical endoscopic cholecystectomy

Animal	Blood loss (mL)	Perforation	Adjacent viscera injury	Size of specimen	Postoperative management
1	10	No	No	6.5 cm × 3.4 cm × 1.2 cm	Autopsy
2	50	Yes	Vascular injury	-	Autopsy
3	5	No	No	6.1 cm × 3.3 cm × 1.8 cm	Autopsy

the major route in future. Transcolonic NOTES similar to transvaginal approach has an advantage for upper abdominal organs, however, its major problem lies in potential contamination as a result of bacterial colonization. In this study, we performed cholecystectomy through umbilicus similar to single-port laparoscopic surgery. Truly speaking, to some extent it does not follow the true concept of NOTES. This approach compared to other approaches has no blind region in enterocoelia, in the other hand, it cannot support stable platform due to soft abdominal wall resulting in difficulties in manipulating endoscope<sup>[17]</sup>. Perforation occurred in our study owing to unstable platform. Therefore, experienced surgeon and endoscopist would be needed to cooperate with each other to complete cholecystectomy by using endoscope *via* umbilical approach. Any surgery require an appropriate and clear operative field vision achieved by manipulating overtube. We realized in practice that overtube was easy to displace because of its smoothness and flexibility which results in the lost operative field and had to re-reveal the gallbladder. So operator and assistant must keep tacit cooperation, the latter also plays a very important role who needs to regulate overtube from time to time in accordance with the procedure to support clear vision for operator which is significant in reducing operation time, avoiding accidental injury involving viscera, blood vessels and smoothly completing surgery. In a sentence, not a single perfect approach for the NOTES has been established till now. The development of endoscopic instruments and the evolution of technology have to be explored. Whether pure NOTES achieves full approval and advocacy from clinical practice depends on how the related challenges can be resolved practically.

The mechanism of water-jet is to employ high-pressure jet of water to cut materials fine, primarily used in manufacture. In 1982, water-jet was firstly introduced to medical application and performed liver resection<sup>[18,19]</sup>. German RAU firstly introduced professional designed water-jet into clinical application in 1990. From then on, its applications gradually extended to maxillofacial surgery, plastic surgery, urinary surgery, ophthalmosurgery, *etc*<sup>[20]</sup>. To date, its use is limited to the dissection of mesenchymal tissue and parenchymal organs<sup>[21,22]</sup>. In this field, German company ERBE is always ahead. Its

Helix-Hydro-jet device can perform precise, controllable tissue-selective (indicating water-rich tissue such as liver parenchyma) with minimal injury to the surrounding fibrous structures and has achieved favorable results in open and laparoscopic operations<sup>[18,23,24]</sup>. However, the above-mentioned Helix-Hydro-jet device cannot be passed through a standard working channel of the current flexible endoscope because its outer-diameter is larger than endoscopic operative channel, so do not match with NOTES procedures. ERBEJet2 water-jet system incorporates high-pressure water-jet with high-frequency electrocautery function with the characteristics of more flexibility, smaller size, easier handling, more precision and less foam formation compared with the precursor model Helix-Hydro-jet<sup>[25]</sup>. This new technology is mainly used to perform endoscopic submucosal dissection for gastrointestinal tumors. Studies showed that water-jet hybrid-knife could effectively shorten operation time and avoid endoscopic accessory-switch with lower haemorrhage and perforation rate, consequently improve the safety and efficiency of resection compared with conventional endoscopic knife<sup>[26-30]</sup>. Isayama *et al*<sup>[29]</sup> reported that transgastric pure NOTES successfully performed cholecystectomy using injection-dissection technology in the animal experiment with long operation time because the procedure of injection and dissection required the need of different instruments and keeps on frequently changing.

The work pressure of water-jet ranges from 30 to 80 bar. If lower than 30 bar, it cannot produce valid cushion, acting on mucous layer when more than 70 bar. While exceeding 100 bar may cause injury to deeper layer such as muscular layer<sup>[24,31]</sup>. Selective-tissue injection results in a selective deposition of mixed solution in the submucosa followed by mucosal elevation when the dissector placed directly on the mucous layer. High-pressure injection of solution into loose connective tissue between gallbladder and liver bed can produce a fluid lift cushion avoid the thermal damage to surrounding tissues, making dissection easier and safer<sup>[29]</sup>. In our study, neither uncontrolled hemorrhage of the liver fossa nor perforation of the gallbladder occurred, indicating the superiority of the ERBEJet2 water-jet system. What is worth mentioning, the lack of surgical triangulation, an important adjunct for

pure NOTES procedure, becomes less important, since the fluid lift cushion produced by the ERBEjet2 water-jet system facilitates dissection even there is no satisfactory traction or countertraction.

Refer to the selection of injecting Solution, perfect solution should have following advantages of being non-toxic to health, no injury to the injection site, low dispersion velocity, easy to access and cheap. Currently, normal saline solution is the most commonly employed with the drawback of being fast absorption, other selective solutions include hyaluronic acid, plasma expanders, gelatin, *etc.* Among them, hyaluronic acid is considered to be the best selection but most expensive<sup>[21,31,32]</sup>. Adding optimal adrenaline can delay solution absorption speed, prolong elevation time and decrease injection times. In our study, injection solution we used was saline solution that is easy to get and cheap. Furthermore, we had added methylene blue dye into saline solution in order to make the solution blue. Furthermore, it had helped clearing the boundaries between gallbladder's serosal layer and liver parenchyma by using high pressure injection with more precise and safe dissection along with maintaining prophylactic hemostasis. This can be seen from blood loss during the operation in our study.

In the functional cholecystectomy performed by Liu *et al.*<sup>[33]</sup>, the cystic duct was isolated and closed with an endoscopic clip. Since standard endoscopic clip may not be safe for use on the cystic duct as it has a hinge gap between the arms of the clip when deployed, in our study, the Olympus ligating device (Polyloop-detachable loop ligating device) was used to tie off the base of the gallbladder once exposed and isolated, and then the gallbladder was cut between the loops using the endoscopic polypectomy snare.

Calot's triangle complete exposure is very important for both the ligation of cystic duct, cystic artery and the avoidance of damage to biliary duct. Although double-channel endoscope has elevator, parallel correlation of double-channel cannot produce surgical triangulation resulting in limited orientation to manipulate. It is still difficult to ligate the cystic duct and cystic artery for pure NOTES that need more attention during the operation. The exposure of CVS (critical view of safety) can decrease the possibility of bile duct injury before ligating the cyst duct and artery<sup>[6]</sup>. We successfully performed pure NOTES cholecystectomy without laparoscopic support.

In conclusion, this study demonstrated the feasibility and safety of trans-umbilical NOTES cholecystectomy using the water-jet hybrid-knife. Due to absence of control study, the advantages of ERBEjet2 cannot be highlighted but possesses potential superiority. Therefore, further study will be designed to compare this new dissector with other endoscopic knife.

## COMMENTS

### Background

Laparoscopic cholecystectomy remains the gold standard for the treatment of benign gallbladder diseases, showing superiority such as better cosmetic

results, less postoperative pain, and shorter recovery time compared with open cholecystectomy. Under the guidance of the Holy Grail of minimal invasive surgery, namely, scarless surgery, natural orifice transluminal endoscopic surgery (NOTES) has made substantial progress. However, it is also technically difficult due to lack of appropriate devices and loss of triangulation.

### Research frontiers

To achieve a nonvisible scar, transumbilical endoscopic/laparoscopic cholecystectomy, single-incision laparoscopic surgery were proposed early or late.

### Innovations and breakthroughs

This is the first study evaluating feasibility and safety of a new method of cholecystectomy using NOTES transumbilical approach and water jet hybrid knife technology. The study demonstrated that the endoscopic water jet system can create a fine stream of unidirectional high-pressure saline solution to penetrate tissue, and instillation of the fluid into the gallbladder bed can produce edematous, distended tissue making separation safe and easy.

### Applications

Generally, transumbilical endoscopic cholecystectomy using a water-jet hybrid-knife is feasible and safe. How to avoid the injury of the cystic artery requires further investigation.

### Terminology

Hydraulic energy from pressurized fluid has been widely used in medical procedures. Instillation of fluid under high pressure into closed spaces can produce edematous, distended tissue, and the resulting increased weight and gravity force is enough to separate filmy avascular tissue without sharp dissection (electrosurgery).

### Peer review

This is a very interesting study about the feasibility and safety of Natural orifice trans-umbilical endoscopic cholecystectomy with a water-jet hybrid-knife in a non-survival porcine model. In this study, pure NOTES cholecystectomy was performed on three non-survival pigs, by transumbilical approach, with a double-channel flexible endoscope, and a water-jet hybrid-knife. The authors found that pure NOTES trans-umbilical cholecystectomy with a water-jet hybrid-knife appear to be feasible and safe.

## REFERENCES

- 1 **Hu H**, Xu AA, Huang A. Towards scarless surgery: a novel laparoscopic cholecystectomy by using 2-mm needle-shape instruments without trocar. *J Laparoendosc Adv Surg Tech A* 2013; **23**: 698-701 [PMID: 23781953]
- 2 **Linke GR**, Tarantino I, Hoetzel R, Warschkow R, Lange J, Lachat R, Zerz A. Transvaginal rigid-hybrid NOTES cholecystectomy: evaluation in routine clinical practice. *Endoscopy* 2010; **42**: 571-575 [PMID: 20432208 DOI: 10.1055/s-0029-1244159]
- 3 **Kantsevov SV**, Jagannath SB, Niiyama H, Isakovitch NV, Chung SS, Cotton PB, Gostout CJ, Hawes RH, Pasricha PJ, Kalloo AN. A novel safe approach to the peritoneal cavity for per-oral transgastric endoscopic procedures. *Gastrointest Endosc* 2007; **65**: 497-500 [PMID: 17321254 DOI: 10.1016/j.gie.2006.08.029]
- 4 **Park PO**, Bergström M, Ikeda K, Fritscher-Ravens A, Swain P. Experimental studies of transgastric gallbladder surgery: cholecystectomy and cholecystogastric anastomosis (videos). *Gastrointest Endosc* 2005; **61**: 601-606 [PMID: 15812420 DOI: 10.1016/S0016-5107(04)02774-9]
- 5 **Pugliese R**, Forgione A, Sansonna F, Ferrari GC, Di Lernia S, Magistro C. Hybrid NOTES transvaginal cholecystectomy: operative and long-term results after 18 cases. *Langenbecks Arch Surg* 2010; **395**: 241-245 [PMID: 19588162 DOI: 10.1007/s00423-009-0528-2]
- 6 **Auyang ED**, Hungness ES, Vaziri K, Martin JA, Soper NJ. Human NOTES cholecystectomy: transgastric hybrid technique. *J Gastrointest Surg* 2009; **13**: 1149-1150 [PMID: 19198959 DOI: 10.1007/s11605-009-0813-y]
- 7 **Zorron R**, Maggioni LC, Pombo L, Oliveira AL, Carvalho GL, Filgueiras M. NOTES transvaginal cholecystectomy: preliminary clinical application. *Surg Endosc* 2008; **22**: 542-547 [PMID: 18027043 DOI: 10.1007/s00464-007-9646-5]

- 8 **Bessler M**, Gumbs AA, Milone L, Evanko JC, Stevens P, Fowler D. Video. Pure natural orifice transluminal endoscopic surgery (NOTES) cholecystectomy. *Surg Endosc* 2010; **24**: 2316-2317 [PMID: 20177936 DOI: 10.1007/s00464-010-0918-0]
- 9 **de Sousa LH**, de Sousa JA, de Sousa Filho LH, de Sousa MM, de Sousa VM, de Sousa AP, Zorron R. Totally NOTES (T-NOTES) transvaginal cholecystectomy using two endoscopes: preliminary report. *Surg Endosc* 2009; **23**: 2550-2555 [PMID: 19343424 DOI: 10.1007/s00464-009-0453-z]
- 10 **Abramov Y**, Gandhi S, Botros SM, Goldberg RP, Sherman W, Rurak M, Sand PK. Do alterations in vaginal dimensions after reconstructive pelvic surgeries affect the risk for dyspareunia? *Am J Obstet Gynecol* 2005; **192**: 1573-1577 [PMID: 15902160 DOI: 10.1016/j.ajog.2004.10.628]
- 11 **Helström L**, Nilsson B. Impact of vaginal surgery on sexuality and quality of life in women with urinary incontinence or genital descensus. *Acta Obstet Gynecol Scand* 2005; **84**: 79-84 [PMID: 15603572]
- 12 **Kalloor AN**, Singh VK, Jagannath SB, Niiyama H, Hill SL, Vaughn CA, Magee CA, Kantsevov SV. Flexible transgastric peritoneoscopy: a novel approach to diagnostic and therapeutic interventions in the peritoneal cavity. *Gastrointest Endosc* 2004; **60**: 114-117 [PMID: 15229442 DOI: 10.1016/S0016-5107(04)01309-4]
- 13 **Abe N**, Takeuchi H, Ueki H, Matsuoka H, Yanagida O, Masaki T, Mori T, Sugiyama M, Atomi Y. Cholecystectomy by a combined transgastric and transparietal approach using two flexible endoscopes. *J Hepatobiliary Pancreat Surg* 2009; **16**: 25-30 [PMID: 19089313 DOI: 10.1007/s00534-008-0011-4]
- 14 **Astudillo JA**, Sporn E, Bachman S, Miedema B, Thaler K. Transgastric cholecystectomy using a prototype endoscope with 2 deflecting working channels (with video). *Gastrointest Endosc* 2009; **69**: 297-302 [PMID: 19013569 DOI: 10.1016/j.gie.2008.05.035]
- 15 **Sumiyama K**, Gostout CJ, Rajan E, Bakken TA, Knipschild MA, Chung S, Cotton PB, Hawes RH, Kalloor AN, Kantsevov SV, Pasricha PJ. Transgastric cholecystectomy: transgastric accessibility to the gallbladder improved with the SEMF method and a novel multibending therapeutic endoscope. *Gastrointest Endosc* 2007; **65**: 1028-1034 [PMID: 17531637 DOI: 10.1016/j.gie.2007.01.010]
- 16 **Marescaux J**, Dallemagne B, Perretta S, Wattiez A, Mutter D, Coumaros D. Surgery without scars: report of transluminal cholecystectomy in a human being. *Arch Surg* 2007; **142**: 823-826; discussion 823-826 [PMID: 17875836 DOI: 10.1001/archsurg.142.9.823]
- 17 **Shi H**, Jiang SJ, Li B, Fu DK, Xin P, Wang YG. Natural orifice transluminal endoscopic wedge hepatic resection with a water-jet hybrid knife in a non-survival porcine model. *World J Gastroenterol* 2011; **17**: 926-931 [PMID: 21412502 DOI: 10.3748/wjg.v17.i7.926]
- 18 **Papachristou DN**, Barters R. Resection of the liver with a water jet. *Br J Surg* 1982; **69**: 93-94 [PMID: 7059775 DOI: 10.1002/bjs.1800690212]
- 19 **Zheng W**, Zhang XZ. Application and Realization of Medical Water-jet. *Yiliao Weisheng Zhuangbei* 2011; **32**: 82-84
- 20 **Lesser T**. [Atypical lung parenchyma resection with the Hydro-Jet--initial experimental and clinical experiences]. *Chirurg* 2000; **71**: 592 [PMID: 10875022]
- 21 **Sold MG**, Grobholz R, Post S, Enderle MD, Kaehler GF. Submucosal cushioning with water jet before endoscopic mucosal resection: Which fluids are effective? *Surg Endosc* 2008; **22**: 443-447 [PMID: 17593436 DOI: 10.1007/s00464-007-9449-8]
- 22 **Kaehler GF**, Sold MG, Fischer K, Post S, Enderle M. Selective fluid cushion in the submucosal layer by water jet: advantage for endoscopic mucosal resection. *Eur Surg Res* 2007; **39**: 93-97 [PMID: 17299266 DOI: 10.1159/000099597]
- 23 **Tschan CA**, Tschan K, Krauss JK, Oertel J. First experimental results with a new waterjet dissector: Erbejet 2. *Acta Neurochir (Wien)* 2009; **151**: 1473-1482 [PMID: 19404573 DOI: 10.1007/s00701-009-0333-2]
- 24 **Kähler GF**, Sold MS, Post S, Fischer K, Enderle MD. Selective tissue elevation by pressure injection (STEP) facilitates endoscopic mucosal resection (EMR). *Surg Technol Int* 2007; **16**: 107-112 [PMID: 17429777]
- 25 **Schumacher B**, Neuhaus H, Enderle MD. Experimental use of a new device for mucosectomy. *Acta Endoscopica* 2007; **37**: 673-678 [DOI: 10.1007/BF02962004]
- 26 **Takeuchi Y**, Uedo N, Ishihara R, Iishi H, Kizu T, Inoue T, Chatani R, Hanaoka N, Taniguchi T, Kawada N, Higashino K, Shimokawa T, Tatsuta M. Efficacy of an endo-knife with a water-jet function (Flushknife) for endoscopic submucosal dissection of superficial colorectal neoplasms. *Am J Gastroenterol* 2010; **105**: 314-322 [PMID: 19773749 DOI: 10.1038/ajg.2009.547]
- 27 **Yahagi N**, Neuhaus H, Schumacher B, Neugebauer A, Kaehler GF, Schenk M, Fischer K, Fujishiro M, Enderle MD. Comparison of standard endoscopic submucosal dissection (ESD) versus an optimized ESD technique for the colon: an animal study. *Endoscopy* 2009; **41**: 340-345 [PMID: 19340739 DOI: 10.1055/s-0029-1214473]
- 28 **Neuhaus H**, Wirths K, Schenk M, Enderle MD, Schumacher B. Randomized controlled study of EMR versus endoscopic submucosal dissection with a water-jet hybrid-knife of esophageal lesions in a porcine model. *Gastrointest Endosc* 2009; **70**: 112-120 [PMID: 19286176 DOI: 10.1016/j.gie.2008.10.042]
- 29 **Isayama H**, Kogure H, Koike K. Endoscopic transgastric pure NOTES cholecystectomy with naso-gallbladder drainage tube placement and injection of a hyaluronic acid mixture (with Video). *J Hepatobiliary Pancreat Sci* 2011; **18**: 106-111 [PMID: 20556622 DOI: 10.1007/s00534-010-0295-z]
- 30 **Lingenfelder T**, Fischer K, Sold MG, Post S, Enderle MD, Kaehler GF. Combination of water-jet dissection and needle-knife as a hybrid knife simplifies endoscopic submucosal dissection. *Surg Endosc* 2009; **23**: 1531-1535 [PMID: 19343433 DOI: 10.1007/s00464-009-0433-3]
- 31 **Fujishiro M**, Yahagi N, Kashimura K, Mizushima Y, Oka M, Enomoto S, Kakushima N, Kobayashi K, Hashimoto T, Iguchi M, Shimizu Y, Ichinose M, Omata M. Comparison of various submucosal injection solutions for maintaining mucosal elevation during endoscopic mucosal resection. *Endoscopy* 2004; **36**: 579-583 [PMID: 15243878 DOI: 10.1055/s-2004-814517]
- 32 **Hyun JJ**, Chun HR, Chun HJ, Jeon YT, Baek CW, Yu SK, Kim YS, Lee HS, Um SH, Lee SW, Choi JH, Kim CD, Ryu HS, Hyun JH. Comparison of the characteristics of submucosal injection solutions used in endoscopic mucosal resection. *Scand J Gastroenterol* 2006; **41**: 488-492 [PMID: 16635919 DOI: 10.1080/00365520500325994]
- 33 **Liu BR**, Kong LJ, Song JT, Liu W, Yu H, Dou QF. Feasibility and safety of functional cholecystectomy by pure NOTES: a pilot animal study. *J Laparoendosc Adv Surg Tech A* 2012; **22**: 740-745 [PMID: 22970657 DOI: 10.1089/lap.2012.0154]

**P- Reviewers** Aubert A, Nagafuchi Y, Shea JA

**S- Editor** Song XX **L- Editor** A **E- Editor** Zhang DN





Published by **Baishideng Publishing Group Co., Limited**

Flat C, 23/F., Lucky Plaza,

315-321 Lockhart Road, Wan Chai, Hong Kong, China

Fax: +852-65557188

Telephone: +852-31779906

E-mail: [bpgoffice@wjgnet.com](mailto:bpgoffice@wjgnet.com)

<http://www.wjgnet.com>



ISSN 1007-9327

