

**Name of Journal:** *World Journal of Gastroenterology*

**Manuscript NO:** 34892

**Manuscript Type:** CASE REPORT

**Gastric adenocarcinoma of fundic gland type spreading to heterotopic gastric glands**

Shigeo Manabe, Kenichi Mukaisho, Takayuki Yasuoka, Fumitaka Usui, Tatsuzo

Matsuyama, Ikuhiro Hirata, Yoshio Boku, Shuji Takahashi

## Match Overview

1	<b>Crossref</b> 39 words Hagiwara, Tomoko, Naomi Kakushima, Kenichiro Imai, Masaki Tanaka, Toshitatsu Takao, Kinichi Hotta, Yuichiro Yam	2%
2	<b>Internet</b> 13 words crawled on 01-Jan-2017 <a href="http://www.wjgnet.com">www.wjgnet.com</a>	1%
3	<b>Crossref</b> 13 words Kato, Motohiko, Toshio Uraoka, Yoh Isobe, Keiichiro Abe, Tetsu Hirata, Yoshiaki Takada, Michiko Wada, Yusaku Takato	1%

Gastric adenocarcinoma of fundic gland type spreading to heterotopic gastric gla

全部 图片 视频 新闻 地图 图书

找到约 116,000 条结果

时间不限

过去 1 小时内  
过去 24 小时内  
过去 1 周内  
过去 1 个月内  
过去 1 年内

所有结果

精确匹配

**[PDF] Gastric Polyps: Classification and Management**

[www.archivesofpathology.org/.../1543-](http://www.archivesofpathology.org/.../1543-2165%282008%29132%5B633%3AGPCAM%5D2.0.CO%3B2)

[2165%282008%29132%5B633%3AGPCAM%5D2.0.CO%3B2](http://www.archivesofpathology.org/.../1543-2165%282008%29132%5B633%3AGPCAM%5D2.0.CO%3B2)

of gastric polyp after fundic gland polyps.2-5 They are sessile or pedunculated and ...  
Heterotopic gastric gland polyp ... thelium, although pyloric-type glands, chief cells, parietal  
cells, and ... reports of gastric carcinoma in Peutz-Jeghers polyposis are described ...  
metastatic spread from an intramucosal polypoid adeno-

**Gastric adenocarcinoma of fundic gland type: Endoscopic and ...**

<https://www.ncbi.nlm.nih.gov/pmc/articles/PMC4766258/>

25 Feb 2016 ... Gastric adenocarcinoma of fundic gland type (GA-FG) with chief cell ... No  
evidence of metastasis was observed on computed tomography. ... MUC6 (a marker of mucous  
neck cells and pyloric glands), CD10 (a marker of the ...

**Gastric Polyps: A Review of Clinical, Endoscopic, and ... - NCBI - NIH**

<https://www.ncbi.nlm.nih.gov/pmc/articles/PMC3992058/>

They include fundic gland polyps (FGPs), hyperplastic polyps, and ... tumors (formerly  
carcinoids), ectopic pancreatic tissue, and pyloric gland adenomas. ... a stalk.8 On  
microscopy, they contain dilated glands lined by gastric body mucosa. 4 Most ... Whereas  
type I and type II tumors arise predominantly in the gastric body ...

**Gastric adenocarcinoma of fundic gland type (chief cell predominant ...**

<https://www.ncbi.nlm.nih.gov/pubmed/21699569>


Gastric adenocarcinoma of fundic gland type (chief cell predominant type) treated with ... highly  
differentiated columnar cells in irregularly anastomosing glands.

**Twelve-year natural history of a gastric adenocarcinoma of fundic ...**

[paperity.org/.../twelve-year-natural-history-of-a-gastric-adenocarcinoma-of-fundic-](http://paperity.org/.../twelve-year-natural-history-of-a-gastric-adenocarcinoma-of-fundic-gland-type)  
gland-type

[全部](#)[图片](#)[视频](#)[新闻](#)[购物](#)[更多](#)[设置](#)[工具](#)

找到约 30,700 条结果 (用时 0.54 秒)

**'Pyloric gland-type adenoma' arising in heterotopic gastric mucosa of ...**[link.springer.com/content/pdf/10.1007/s004280050425.pdf](https://link.springer.com/content/pdf/10.1007/s004280050425.pdf)  翻译此页

Key words Pyloric gland-type adenoma - Heterotopic gastric mucosa ... testinal-type carcinoma [13].  
However, we ... of the duodenum, with dysplastic progression of the gastric type ... mucosa. The  
mucosa is composed of organized fundic tissue with ... glands lined by cuboidal to columnar cells with  
eosinophilic cyto- plasm.

**Gastric adenocarcinoma of fundic gland type: Endoscopic and ...**<https://www.ncbi.nlm.nih.gov> > NCBI > Literature > PubMed Central (PMC) - 翻译此页

作者: G Tohda - 2016 - 被引用次数: 3 - 相关文章

2016年2月25日 - Gastric adenocarcinoma of fundic gland type (GA-FG) with chief cell ... No evidence of  
metastasis was observed on computed tomography. ... MUC6 (a marker of mucous neck cells and  
pyloric glands), CD10 (a marker of the ...

缺少字词: heterotopic

**Gastric Adenocarcinoma of Fundic Gland Type: Report of Three Cases**<https://www.ncbi.nlm.nih.gov> > NCBI > Literature > PubMed Central (PMC) - 翻译此页

作者: ES Park - 2012 - 被引用次数: 25 - 相关文章

2012年6月22日 - Recently, fundic gland type gastric adenocarcinoma (GA-FG) has been reported as a  
... findings in GA-FG suggesting differentiation toward fundic glands. ... Lymph node metastasis was  
assessed in two of the three surgically ...

缺少字词: heterotopic

**Gastric adenocarcinoma of fundic gland ... 的图片搜索结果**



[全部](#)[图片](#)[新闻](#)[视频](#)[购物](#)[更多](#)[设置](#)[工具](#)

找到约 30,800 条结果 (用时 0.49 秒)

### 'Pyloric gland-type adenoma' arising in heterotopic gastric mucosa of ...

[link.springer.com/content/pdf/10.1007/s004280050425.pdf](https://link.springer.com/content/pdf/10.1007/s004280050425.pdf) - 翻译此页

Key words Pyloric gland-type adenoma - Heterotopic gastric mucosa ... testinal-type carcinoma [13]. However, we ... of the duodenum, with dysplastic progression of the gastric type ... mucosa. The mucosa is composed of organized fundic tissue with ... glands lined by cuboidal to columnar cells with eosinophilic cyto- plasm.

### Gastric Adenocarcinoma of Fundic Gland Type: Report of Three Cases

<https://www.ncbi.nlm.nih.gov> - NCBI - Literature - PubMed Central (PMC) - 翻译此页

作者: ES Park - 2012 - 被引用次数: 26 - 相关文章

2012年6月22日 - Recently, fundic gland type gastric adenocarcinoma (GA-FG) has been reported as a ... findings in GA-FG suggesting differentiation toward fundic glands. ... Lymph node metastasis was assessed in two of the three surgically ...

缺少字词: heterotopic

### Gastric adenocarcinoma of fundic gland type: Endoscopic and ...

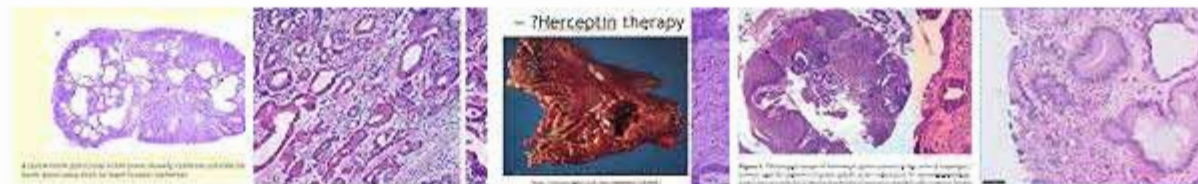
<https://www.ncbi.nlm.nih.gov> - NCBI - Literature - PubMed Central (PMC) - 翻译此页

作者: G Tohda - 2016 - 被引用次数: 3 - 相关文章

2016年2月25日 - Gastric adenocarcinoma of fundic gland type (GA-FG) with chief cell ... No evidence of metastasis was observed on computed tomography. ... MUC6 (a marker of mucous neck cells and pyloric glands), CD10 (a marker of the ...

缺少字词: heterotopic

### Gastric adenocarcinoma of fundic gland ... 的图片搜索结果



→ 有关"Gastric adenocarcinoma of fundic gland type spreading to heterotopic gastric glands"的更多图片

[举报图片](#)